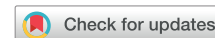

Sinus node dysfunction characterized by reduction only in maximum heart rate during exercise after superior vena cava isolation in atrial fibrillation catheter ablation—A potential complication



Tatsuya Hayashi, MD,^{*†} Akira Mizukami, MD,[†] Shunsuke Kuroda, MD,[†]
Akihiko Matsumura, MD,[†] Masahiko Goya, MD,^{*} Tetsuo Sasano, MD, PhD^{*}

From the ^{*}Department of Cardiovascular Medicine, Tokyo Medical and Dental University, Tokyo, Japan, and [†]Department of Cardiology, Kameda Medical Center, Kamogawa, Chiba, Japan.

Introduction

The superior vena cava (SVC) is one of the most common sites of non-pulmonary vein (PV) foci in atrial fibrillation (AF), and SVC isolation is an established ablation strategy for AF patients who have foci arising from the SVC.^{1,2} While iatrogenic sick sinus syndrome requiring pacemaker implantation is known as a possible complication of SVC isolation,³ sinus node dysfunction characterized by preserved heart rate (HR) at rest but inability to increase HR during exercise (chronotropic incompetence) has never been reported.

Case report

A 70-year-old male exercise enthusiast was referred to our hospital for the recurrence of AF after catheter ablation. He had received PV isolation 5 years before, but had recently begun to feel palpitations. Antiarrhythmic drugs failed to maintain sinus rhythm, so a repeat catheter ablation was performed.

Despite isolation of the no longer isolated PV at the second procedure, administration of isoproterenol (ISP) spontaneously provoked AF when maximum HR reached 130 beats per minute (bpm) under deep sedation with propofol and dexmedetomidine. Paroxysmal atrial contraction in the SVC inducing AF was detected. Because AF kept being provoked after repeated restoration of sinus rhythm with internal defibrillation shocks even well after wash-out of ISP, we decided to perform SVC isolation during AF rather than attempt ablation of individual foci within the SVC. To avoid sinus node injury, the line of isolation was put about 5 mm above the earliest normal sinus activation site, which was

KEY TEACHING POINTS

- Sinus node dysfunction characterized by reduced maximum heart rate (HR) with preserved HR at rest can be observed after superior vena cava (SVC) isolation.
- Aggressive evaluation of sinus node function including maximum HR should be considered if patients have dyspnea during exercise after SVC isolation.
- SVC isolation should be performed carefully, especially if a patient needs the preserved maximum heart rate for hard exercise.

initially recorded by the electrode catheter placed at the right atrium (RA) and SVC before the “AF storm.”

After achieving two-thirds encircling ablation at the SVC with a Navistar Thermocool Smarttouch SF (Biosense-Webster, Diamond Bar, CA) catheter at 25 W power, leaving the lateral site unablated, we delivered a defibrillation shock, which resulted in restoration of sinus rhythm. There was no junctional rhythm, and the HR showed slight bradycardia (53 bpm) (Figure 1). RA mapping after sinus rhythm restoration showed atrial activation propagating from the lower RA, a site obviously lower than that before SVC isolation, suggesting emergence of a lower non-sinus pacemaker (Figure 2). After completing SVC isolation, we administered ISP again. AF was not provoked this time, but we noticed that maximum HR was approximately 110 bpm, lower than the 130 bpm recorded before SVC isolation under the same amount of ISP administration. After the procedure in the absence of ISP, the patient’s HR was around 50 bpm and was associated with slightly low blood pressure, so we temporarily administered catecholamine (dopamine) until the next day. A shorter PR interval was observed just after

KEYWORDS Atrial fibrillation; Catheter ablation; Chronotropic incompetence; Sinus node dysfunction; SVC isolation (Heart Rhythm Case Reports 2020;6:206–209)

Address reprint requests and correspondence: Dr Tatsuya Hayashi, Department of Cardiovascular Medicine, Tokyo Medical and Dental University, 1-5-45 Yushima Bunkyo-ku Tokyo 113-8519, Japan. E-mail address: tatsuya.hayashi77@gmail.com.

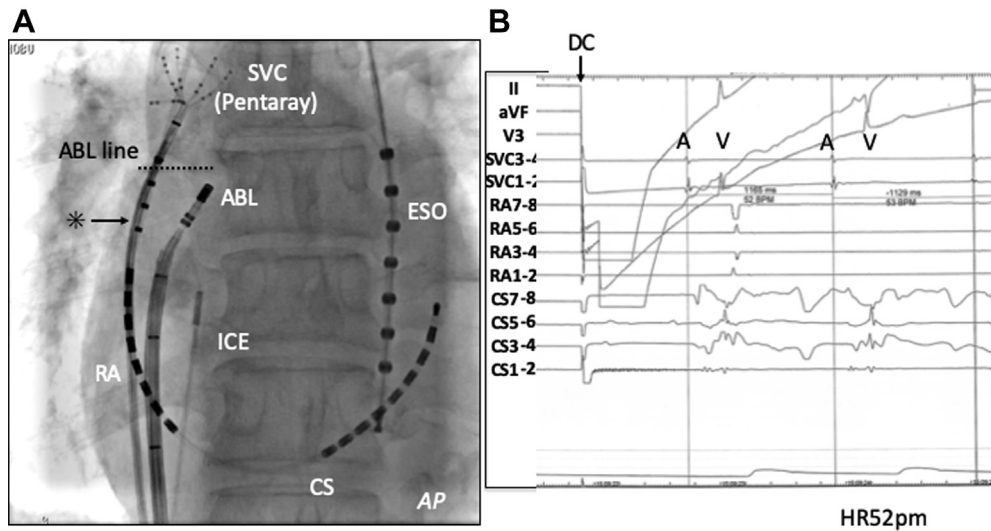


Figure 1 A: Anatomical location of the superior vena cava (SVC) isolation line is shown. Earliest sinus node activation site is indicated by asterisk (*). ABL = ablation catheter; AP = anterior-posterior view; CS = coronary sinus; ESO = esophageal thermo catheter; ICE = intracardiac echocardiogram; RA = right atrium. B: Sinus recovery observed after defibrillation with no sign of junctional rhythm. A = atrial contraction; V = ventricular contraction.

the ablation, likely owing to reliance on secondary atrial pacemakers, but recovered the next day (Figure 3). Right phrenic nerve palsy was also observed on the day of ablation, but fully recovered the next day. The patient was discharged 3 days later with resting HR of 50 bpm without any symptoms.

A week later, the patient returned to the outpatient clinic complaining of dyspnea, which appeared only during his daily exercise routine. His 12-lead electrocardiogram showed

normal sinus rhythm of 70 bpm at rest, and no abnormalities were noted in blood tests, radiograph, or echocardiography. Holter monitoring revealed that his maximum HR during exercise was reduced to around 110 bpm, compared to the 150 bpm he used to achieve according to the HR monitor at the gym. A treadmill test 1 month later confirmed his reduced maximum HR (110 bpm), which was the same as the HR observed during the ablation procedure after SVC isolation under ISP infusion.

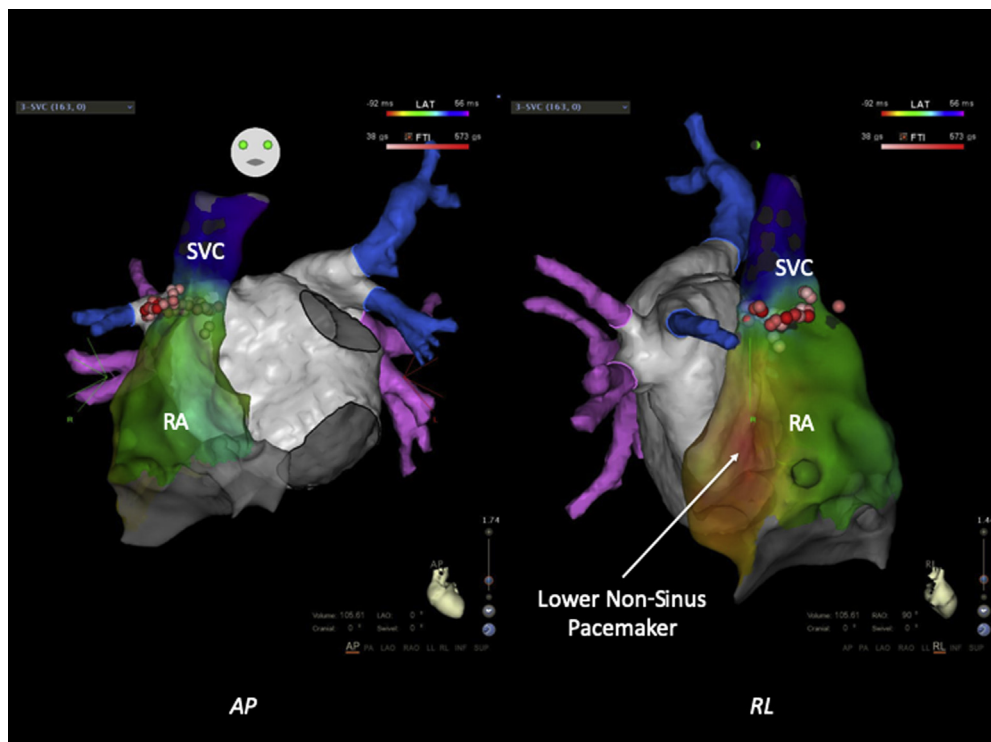



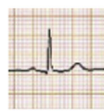



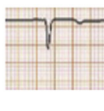






Figure 2 A lower non-sinus pacemaker appeared after superior vena cava (SVC) isolation as demonstrated by CARTO 3D mapping (CARTO 3, Biosense-Webster, Diamond Bar, CA). RL = right-left view.

	Before ABL	Just after ABL	Next day	3 days after ABL (discharge)	10 days after ABL	380 days after ABL
Symptom	palpitation at exercise				DOE at exercise	DOE at exercise
II						
V1						
HR (at rest)	67	48 (dopamine)	58	64	69	84
HR (Maximum)	150 (exercise)				106 (TMT)	110 (exercise)

(bpm)

Figure 3 The timeline of heart rate (HR), symptoms, and electrocardiogram morphology (II and V₁) before and after ablation (ABL) is shown. After the ablation, reduced maximum HR caused dyspnea during exercise in spite of preserved HR at rest. DOE = dyspnea on effort; TMT = treadmill test.

At 1-year follow up, the patient's P-wave morphology in lead II shows a positive but slightly decreased amplitude compared to the one before the second ablation procedure. He remains free from AF recurrence as demonstrated by Holter monitoring, with HR at rest of about 70 bpm without any symptoms, but maximum HR has not recovered and his ability to exercise remains impaired.

Discussion

This case report demonstrates atypical sinus node dysfunction, which emerged after SVC isolation for AF characterized by preserved HR at rest and reduced maximum HR during exercise leading to dyspnea.

Sinus node dysfunction after ablation

Sinus node dysfunction after SVC isolation has been reported in previous publications.⁴ Chen and colleagues⁴ reported that 6 of 132 (4.5%) patients showed sinus node injury after SVC isolation. Of these 6 patients, sinus rhythm recovered in 5 (3.5 hours to 2 days after ablation), but the remaining patient needed pacemaker implantation for symptomatic bradycardia (junctional rhythm, HR 38 with dizziness). It is interesting that a short PR interval was observed in 1 patient with sinus node injury in their report, similar to our patient. Electroanatomical mapping in our patient demonstrated that his short PR interval was due to a lower non-sinus pacemaker (Figure 2). Though it is still unknown why the lower non-sinus pacemaker appeared after sinus node dysfunction, a short PR, which occurs after SVC isolation, can be a sign of temporary or permanent sinus node damage; and for those patients, aggressive validation of sinus node function should be considered using exercise electrocardiogram and/or Holter monitoring.

Possible causes of chronotropic incompetence not due to direct injury to the sinus node by catheter ablation include atrial fibrosis, coronary artery disease, injury to the sinus node artery by ablation, serum electrolyte abnormalities, antiarrhythmic drugs, and sympathetic nerve injury. However, our patient had no structural heart disease, was found to have normal coronary arteries by computed tomography (CT) angiography, normal left atrium and RA dimensions by cardiac ultrasound, no significant low voltage areas in either atrium by 3D mapping suggesting fibrosis, no serum electrolyte abnormalities before or after the procedure, and no indication of sympathetic nerve/cardiac ganglion plexus injury such as changes in HR during ablation around the PV. The patient did receive bepridil, a class III antiarrhythmic drug unavailable in the United States, for 2 months as insurance against AF recurrence after the procedure, but sinus bradycardia is not a known side effect of this drug. In summary, the differential diagnosis points to catheter ablation damage to the sinus node in the case of our patient. While iatrogenic sick sinus syndrome after SVC isolation is usually diagnosed by reduced HR at rest, impaired maximum HR after SVC isolation has never been reported. Patients receiving catheter ablation for AF are often older, and it is unclear how many of those patients exercise vigorously. Our case shows that sinus node dysfunction featuring decreased maximum HR can potentially occur after SVC isolation and demonstrates diversity in iatrogenic sick sinus syndrome. This patient happened to be an exercise enthusiast and symptomatic reduced maximum HR (from 150 to 110 bpm) was found during exercise. We should keep in mind that if patients complain of dyspnea after catheter ablation including SVC isolation with preserved HR at rest, more aggressive validation for maximum HR may be needed. In our case, a treadmill test was useful in confirming that his dyspnea was associated with reduced maximum HR. For patients who need preservation of

maximum HR, such as athletes, SVC isolation should be performed very carefully, with aggressive validation of sinus node function postprocedurally.

At 1 year follow-up, maximum HR has not recovered. Implantation of a pacemaker with rate response function or prescribing oral cilostazol are among possible treatment options for patients with sick sinus syndrome, but these therapies are not guaranteed to meet the HR demands of our patient.⁵ Our patient continues to exercise and is trying to increase exercise tolerance by improving cardiopulmonary function without resorting to medical treatment.

Optimal ablation strategy for SVC isolation

Careful ablation is needed for SVC isolation because it is estimated that the sinus node is located within the SVC with 10% probability.⁶ To avoid injuring the sinus node, it is safer to perform SVC isolation during sinus rhythm to allow faster recognition of sinus node dysfunction, which usually manifests as HR reduction and is often preceded by reactive ectopic beats from the sinus node. In our case, incessant AF provocation despite defibrillation shocks required ablation during AF, so it is unknown whether or not this patient had any ectopy during radiofrequency (RF) applications. In SVC isolation, if “AF storms” are provoked by ISP, one should wait a sufficient time for ISP to wash out before starting ablation under sinus rhythm.

The sinus node artery (SNA) can arise from the left circumflex coronary artery, and it is reported that catheter ablation to the left superior PV or left atrial appendage can cause sinus node dysfunction, although those are reported as reversible complications.^{7,8} Ablation at the septal side of the SVC can also injure the SNA.^{9,10} In our patient, CT angiography showed a typical configuration of SNA anatomy arising from the right coronary artery, and it was less likely that the artery had been injured during SVC isolation compared to the artery arising from the left circumflex artery. Obtaining preoperative coronary CT images may be useful for determining the course of the SNA to avoid injury.

Tanaka and colleagues¹⁰ reported that approximately half of patients with AF had a diagonal line of block at the RA-SVC junction that could be utilized to isolate the SVC with less RF delivery. Recognizing sinus node location and the RA-SVC gap also helps reduce unnecessary ablation injury to the sinus node.¹¹ Adequate isolation-line selection with less RF delivery can help to avoid ablation complication in SVC isolation. In the current case, we set the isolation line

above the earliest activation site, which was recorded by the electrode catheter placed at the RA and SVC. However, it is known that the sinus node can extend about 13.5 mm (range, 8–21.5 mm),¹² and as well that the location of the pacemaker can shift according to autonomic tone, which is generally a cranial shift with sympathetic stimulation and a caudal shift with parasympathetic stimulation.^{13,14} In our case, the “safe margin” of 5 mm we employed from the earliest sinus activation site at the deployed electrode catheter to the isolation line had been enough to protect HR at rest, but was insufficient to preserve maximum HR. Sinus node injury by RF application, which disturbed the cranial shift of the pacemaker, may be the cause of dropped maximum HR after SVC isolation in our patient.

References

- Goya M, Ouyang F, Ernst S, et al. Electroanatomic mapping and catheter ablation of breakthroughs from the right atrium to the superior vena cava in patients with atrial fibrillation. *Circulation* 2002;106:1317–1320.
- Higuchi K, Yamauchi Y, Hiraio K, et al. Superior vena cava as initiator of atrial fibrillation: factors related to its arrhythmogenicity. *Heart Rhythm* 2010; 7:1186–1191.
- Miranda-Arboleda AF, Munro J, Srivathsan K. Sinus node injury during adjunctive superior vena cava isolation in a patient with triggered atrial fibrillation. *Indian Pacing Electrophysiol J* 2016;16:96–98.
- Chen G, Dong JZ, Liu XP, et al. Sinus node injury as a result of superior vena cava isolation during catheter ablation for atrial fibrillation and atrial flutter. *Pacing Clin Electrophysiol* 2011;34:163–170.
- Sonoura T, Kodera S, Shakya S, et al. Efficacy of cilostazol for sick sinus syndrome to avoid permanent pacemaker implantation: a retrospective case-control study. *J Cardiol* 2019;74:328–332.
- Ong MG, Tai C-T, Lin Y-J, et al. Sinus node injury as a complication of superior vena cava isolation. *J Cardiovasc Electrophysiol* 2005;16:1243–1245.
- Choi E-K, Lee W, Oh S. Reversible sinus node dysfunction after multiple ablations along the course of sinus nodal artery in patient with paroxysmal atrial fibrillation. *Europace* 2013;15:1388–1388.
- Kitamura T, Fukamizu S, Arai K, et al. Transient sinus node dysfunction following sinus node artery occlusion due to radiofrequency catheter ablation of the septal superior vena cava–right atrium junction. *J Electrocardiol* 2016; 49:18–22.
- Killu AM, Fender EA, Deshmukh AJ, et al. Acute sinus node dysfunction after atrial ablation: incidence, risk factors, and management. *Pacing Clin Electrophysiol* 2016;39:1116–1125.
- Tanaka Y, Takahashi A, Takagi T, et al. Novel ablation strategy for isolating the superior vena cava using ultra high-resolution mapping. *Circ J* 2018; 82:2007–2015.
- Yamashita S, Tokuda M, Isogai R, et al. Spiral activation of the superior vena cava: the utility of ultra-high-resolution mapping for caval isolation. *Heart Rhythm* 2018;15:193–200.
- Sanchez-Quintana D, Cabrera JA, Farré J, et al. Sinus node revisited in the era of electroanatomical mapping and catheter ablation. *Heart* 2005;91:189–194.
- Boineau JP, Schuessler RB, Roeske WR, et al. Quantitative relation between sites of atrial impulse origin and cycle length. *Am J Physiol* 1983; 245:H781–H789.
- Glukhov AV, Fedorov VV, Anderson ME, et al. Functional anatomy of the murine sinus node: high-resolution optical mapping of ankyrin-B heterozygous mice. *Am J Physiol* 2010;299:H482–H491.