

# How Should Cancer Surveillance in Primary Sclerosing Cholangitis Be Performed?

Hanno Ehken Christoph Schramm

University Medical Center Hamburg-Eppendorf, Hamburg, Germany

## Keywords

Primary sclerosing cholangitis · Cholangiocarcinoma · Gallbladder cancer · Colon cancer

## Summary

**Background:** Primary sclerosing cholangitis (PSC) is a chronic inflammatory disease affecting the intra- and extrahepatic bile duct system that can ultimately cause liver cirrhosis. Apart from the risk of progression to end-stage liver disease the prognosis of PSC is primarily determined by the risk to develop hepatobiliary or extrahepatic malignancies. A reasonable surveillance strategy for PSC patients must allow the detection of early cancer that will permit a potentially curative therapy. **Methods:** Current guidelines on malignancy within the context of PSC as well as the primary literature were reviewed for this article. **Results:** Here, we focus on a concise review of the three tumors most commonly associated with PSC: cholangiocellular carcinoma (CCA), gallbladder cancer, and colorectal carcinoma. For cancer surveillance in this patient group, endoscopy, cholangiography, cross-sectional imaging, and the use of serum tumor markers are principally available. Furthermore, for the diagnosis of CCA novel approaches were recently suggested to improve sensitivity and specificity to detect this malignancy. **Conclusion:** We review different aspects of cancer surveillance in patients with PSC. Since prospective data on the surveillance of malignant tumors is unavailable, we discuss a rational approach on how to perform cancer surveillance in patients with PSC.

## Introduction

Primary sclerosing cholangitis (PSC) is a chronic inflammatory liver disease leading to stricturing scars of the intra- and extrahepatic bile ducts. In most cases, PSC progresses to end-stage liver disease. In the absence of effective medical treatments liver transplantation is the only option in advanced disease. The prevalence of PSC has been described to follow a north-south gradient – with the highest numbers in Scandinavia and northern Europe and significantly lower numbers in southern Europe and Asia. While the incidence of PSC was described as relatively stable, there is data from a Swedish cohort reporting an increased incidence over the period of 1992–2005 [1].

PSC is associated with inflammatory bowel disease (IBD) in about two thirds of the patients. While the intestinal disease most often resembles ulcerative colitis, PSC cases associated with Crohn's disease are found less frequently. Although the etiology of PSC still remains unknown and its pathogenesis is only partially understood, it is generally accepted that PSC is an immune-mediated, if not autoimmune disease. The contribution of genetic predisposition and environmental factors to PSC is just at the beginning of being understood [2–5].

Importantly, PSC patients bear an increased risk to develop hepatobiliary as well as extrahepatic malignancies. In a Swedish cohort study, PSC patients were predisposed to develop cholangiocellular carcinoma (CCA), hepatocellular carcinoma (HCC), and gallbladder cancer (GBC). Moreover, in this study pancreatic cancer and colon cancer were also more common in PSC patients [1, 6]. While we could confirm the increased risk for CCA, GBC, and colon carcinoma in patients with PSC, the risk for HCC was low enough that surveillance for this tumor may not be warranted [7].

In this article we will focus on a brief overview of the three most common malignancies associated with PSC: CCA, GBC, and colorectal cancer (CRC). Given the rarity of PSC, there is a lack of prospective clinical studies on the surveillance of these tumors. We will therefore present the current diagnostic access to these malignancies and discuss a pragmatic approach to cancer surveillance in PSC.

## Diagnosis of CCA in PSC Patients

CCA can be considered as the most important comorbidity of PSC. The lifetime risk to develop a CCA was estimated to be in the range of 10–15%, and the annual incidence was found to be 0.6–1.2% in larger studies [8, 9]. Since it has been reported that approximately one third of all CCAs will be detected within the first year after diagnosing PSC, it is prudent to try to exclude the presence of CCA at diagnosis of PSC, with all the limitations of current diagnostics discussed in detail below. CCA can be classified as intrahepatic, perihilar, and distal whereas GBC should be regarded as an entity of its own (see below). In PSC, the majority of the tumors will develop at the liver hilum and are mostly associated with a stricture of the bile duct, i.e. a dominant stenosis. Considering that at least half of the patients will develop dominant bile duct strictures over the years [10], the differentiation between benign and malignant dominant stenoses is a major clinical challenge.

In this regard, a common scenario the clinician encounters is the question about the dignity of a stenosis within the context of cholestasis, jaundice, and pruritus. Dominant stenoses will develop in more than half of the patients during the course of the disease, and CCA not being associated with dominant strictures is rare [11–13]. Hence, most strictures are of benign nature, and the sensitivity to detect malignancy using the combination of imaging modalities including computed tomography (CT) and magnetic resonance imaging (MRI), endoscopy with biliary brush cytology or biopsy, and the analysis of tumor markers in the serum is below 50–60%.

For a sensitive detection of CCA in patients with PSC it is crucial to combine complementing diagnostic modalities. Since the positive predictive value of imaging studies alone is poor, a definite diagnosis in patients with suspicious findings in the screening procedure warrants further procedures with endoscopic examinations including brush cytology and/or biopsy. It has been demonstrated that there is a strong association of dysplasia with the development of CCA [14]. Brush cytology offers the advantage of a very good specificity and positive predictive value but it only comes with a poor sensitivity for the detection of CCA within the range of 40–50%. The clinician consequently faces a dilemma once there is a suspicious finding upon cross-sectional imaging but a failure to make a definite diagnosis of CCA by means of complementing tests. In these cases, repeated endoscopic retrograde cholangiopancreatographies (ERCPs) with brush cytology, biopsy, and – if technically feasible – cholangioscopy are usually needed. For this patient group, we would also strongly argue for repeated cross-sectional imaging studies in shorter intervals, e.g. within 12 weeks.

For PSC patients with suspicion of CCA, it has been suggested to additionally make a cytological analysis using the fluorescent in situ hybridization (FISH) method [15, 16]. Sensitivity and specificity of FISH polysomy for the detection of CCA were 46 and 88%, respectively. The detection of trisomy or tetrasomy lowered the sensitivity and specificity for CCA to 25 and 67%, respectively. Of note, patients with trisomy or tetrasomy findings in FISH analysis had a similar outcome to patients with negative FISH results

whereas, in contrast, detection of polysomy in FISH analysis was associated with an outcome similar to patients with CCA [16].

Furthermore, the addition of digital imaging analysis or intra-ductal ultrasound could further increase the poor sensitivity of the established diagnostic tools [13]. Using novel technologies such as proteome analysis of bile [17] or urine [18] or the detection of the methylation status of a defined panel of genes [19], the sensitivity and specificity of diagnosing CCA could be further improved. Though very promising, these approaches will need further independent validation prior to becoming routinely applied in the management of PSC patients.

## Surveillance of PSC Patients for the Development of CCA

For a potentially curative treatment such as resection or the combination of neoadjuvant therapy and liver transplantation, CCA needs to be detected at an early stage. Therefore, optimal surveillance and diagnostic workup would be essential for these patients. Given the unavailability of prospective studies on the surveillance of CCA in PSC patients, a rational approach is needed that allows the clinician to identify bile duct lesions warranting further evaluation. The American Association for the Study of Liver Diseases as well as the British Society of Gastroenterology propose guidelines for the surveillance and diagnosis of CCA in this patient group [20, 21].

Principally, liver neoplasia presenting as a mass lesion can be detected by using a combination of cross-sectional imaging and cholangiography technology [9, 22]. However, it is of importance that it can become extremely challenging to detect early carcinoma with these methods. While CT and MRI imaging achieved a better sensitivity in detecting malignancy, ultrasound was shown to provide a better accuracy in distinguishing CCA from PSC alone in a retrospective study in a tertiary care center [9]. Combining MRI with magnetic resonance cholangiopancreatography (MRCP) technology raised the sensitivity to 89% while the specificity was not majorly changed. The non-invasive diagnostics of MRI plus MRCP thus yielded a similar sensitivity as ERCP and provided a better accuracy in distinguishing CCA from PSC alone [9]. In the light of possible complications due to the invasive ERCP and the radiation exposure of repeated CT scans, we recommend screening PSC patients without the need for endoscopic intervention either with MRI plus MRCP or with an ultrasonography performed by experienced personnel.

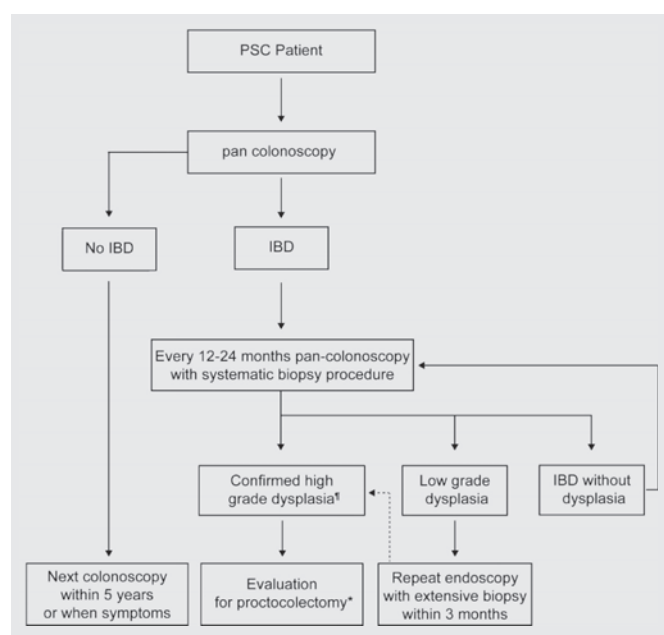
Adding the test of serum levels of carbohydrate antigen 19-9 (CA 19-9) to cross-sectional imaging and cholangiographic diagnostics, the sensitivity to detect CCA was found to be increased up to 100% [9]. For CCA in PSC patients, CA 19-9 is the only tumor marker that has been shown to be of diagnostic value and is therefore used in many centers. Again, however, prospective data for screening PSC patients is unavailable. When using CA 19-9, it is important to note that it can be elevated within the context of other hepatic and extrahepatic conditions and also in bacterial cholangitis

and cholestasis induced by benign bile duct stenoses. In a retrospective study of 79 PSC patients it was shown that more than one third of patients presenting with CA 19-9 elevations of more than 129 U/ml did not have CCA after a median follow-up of 30 months [23]. Moreover, it is important to note that CA 19-9 is not expressed in people without the Lewis antigen (5–10%) which makes this marker useless in patients with this trait [24]. Other serum markers such as CYFRA 21-1 [25] or trypsinogen-2 [26] may be more suitable for this population but prospective data is missing for PSC patients.

If the primary aim is to detect as many early CCAs as possible, defining the cut-off value at 20 U/ml offered the best test performance when applied in conjunction with imaging modalities. Combining CA 19-9 with a cut-off of 20 U/ml with ultrasonography, CT or MRI, a sensitivity of 91, 100 or 96%, a specificity of 62, 38 or 37%, and a negative predictive value of 98, 100 or 98% were accomplished if at least one method was positive [9]. In the same study, when CA 19-9 was combined with ERCP or MRI plus MRCP, a sensitivity of 100% could also be achieved when at least one method offered a positive finding. However, this strategy comes at the price of a lower positive predictive value and, consequently, a need for invasive tests for the confirmation of diagnosis; many patients will need a workup by conceivably undergoing repeated invasive diagnostics which might eventually turn out as unnecessary. From the data available it remains unclear whether the addition of CA 19-9 in a CCA surveillance program is beneficial. Within the current guidelines of the European Association for the Study of the Liver (EASL) for the management of cholestatic liver disease the use of CA 19-9 as a biochemical marker for early detection of CCA is not recommended; however, it is mentioned that it might be useful as a screening strategy when combined with a cross-sectional imaging modality [27]. We would therefore not recommend the use of CA 19-9 as a surveillance tool in PSC outside of clinical studies.

### Surveillance of PSC Patients for the Development of GBC

GBC in PSC patients does not fall into the classification of CCA and should be regarded as an entity of its own. Ultrasound examination has a high spatial resolution and will detect tumors in the gallbladder at least as reliably as CT or MRI, is not associated with radiation exposure, and will be more cost-effective. Consequently, regular ultrasound exams seem to be an ideal means for gallbladder tumor surveillance. According to the current guidelines, surgery is recommended for patients with gallbladder polyps regardless of size [28]. It has been suggested that for gallbladder lesions below the size of 0.8 cm repeated imaging every 3–6 months is an alternative strategy because most cancers will arise from polyps well above that size [29]. In our experience, gallbladder tumors in PSC patients may grow rapidly [12], and we therefore believe that cholecystectomy should not be delayed. Annual surveillance as suggested in the current guidelines may not be sufficient in this high-risk patient group; thus, we would argue for ultrasound examinations every 6 months [12]. Once a mass lesion of the gallbladder is diagnosed by cross-



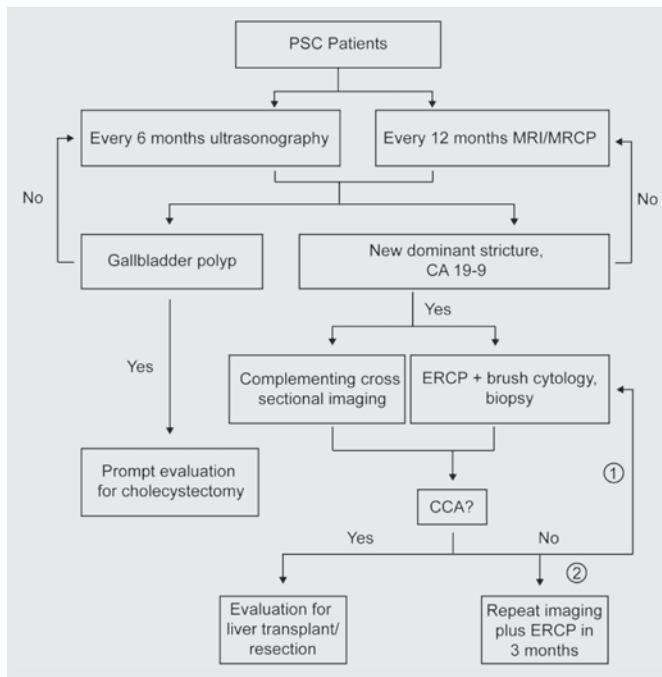
**Fig. 1.** Surveillance strategy for the development of hepatobiliary malignancy in PSC patients performed at our center. \*Patients with PSC and liver cirrhosis should be evaluated for liver transplantation before undergoing proctocolectomy. High-grade dysplasia should be confirmed by two independent pathologists.

sectional imaging, we would adhere to the guidelines and recommend cholecystectomy – regardless of the size of the lesion unless the surgical risk outweighs potential benefits.

In our institution, PSC patients are evaluated by ultrasound every 6 months. Additionally, as long as no suspicious results are found, patients will receive a contrast-enhanced MRI plus MRCP every 1–2 years, depending on the degree of bile duct pathology (fig. 1). If a new dominant stricture is detected, the patient will be referred to ERCP with brush cytology and additional cross-sectional imaging. In case of a confirmed CCA, the patient will ideally be evaluated for liver transplantation after neoadjuvant therapy or in ongoing clinical studies or for resection of the tumor if the liver disease is not too advanced or in selected cases of distal CCA. Patients who develop a dominant stricture that cannot be confirmed to have CCA by means of brush cytology or biopsy will undergo repeated ERCP within 3 months if clinical suspicion remains. Otherwise the patients return to the regular surveillance program.

### Surveillance of PSC Patients for the Development of CRC

Approximately two thirds of PSC patients are also affected by an associated IBD, which often presents as mild pancolitis. Therefore, colonoscopy should be performed in patients with newly diagnosed PSC in order to exclude subclinical IBD. Patients with proven IBD bear an increased risk of developing CRC. Compared to patients with IBD alone, patients with IBD and PSC seem to have an even greater risk of developing dysplasia or CRC [30].



**Fig. 2.** Surveillance strategy for the development of CRC in PSC patients performed at our center.

Pan-colonoscopy every 1–2 years is part of the recommendation of the current EASL guidelines [27] for patients with PSC and IBD. In our institution, patients with PSC and IBD will be counselled to undergo colonoscopy annually (fig. 2). PSC patients without prior evidence of colitis will be advised to repeat endoscopic evaluation every 5 years also in the absence of clinical symptoms.

The goal of CRC surveillance must be to detect dysplasia as the definitive premalignant condition. If high-grade dysplasia or cancer is detected, patients will usually be recommended to undergo proctocolectomy. High-grade dysplasia should be confirmed by an independent pathologist. High-grade dysplasia in a conventional polyp without evidence for colitis-associated risk lesions, such as dysplasia-associated lesions or mass, may be treated endoscopically under continued surveillance. In patients with PSC as well as evi-

dence for low-grade dysplasia, a repeated endoscopy with extensive collection of tissue samples within a few months is warranted. If only low-grade dysplasia keeps getting diagnosed, endoscopic re-evaluation with a systematic biopsy procedure at intervals of 6–12 months can be justified.

Given the risk of hepatic decompensation after abdominal surgery, we recommend that any PSC patient with advanced disease (i.e. liver cirrhosis) should be counselled accordingly and undergo evaluation for possible liver transplantation before proctocolectomy.

## Conclusion

Apart from the progression of intra- and extrahepatic stricturing of the biliary system ultimately leading to end-stage liver disease, malignancy can be regarded as the most dreadful comorbidity of PSC. Only the early detection of small CCA, GBC, and CRC will offer a potentially curative therapy. In order to detect premalignant dysplasia or early CRC, regular pan-colonoscopy every 1–2 years with a systematic biopsy regimen is the best current strategy. For CCA and GBC, in the absence of prospective data on the surveillance of this patient group, the combination of imaging with ultrasonography every 6–12 months and MRI/MRCP every 1–2 years seems a reasonable approach. CA 19-9 may be determined in patients with suspected CCA but its role in cancer surveillance is unclear. Diagnostic ERCP including brush cytology and biopsy should be reserved for patients with suspected CCA as confirmatory means of diagnostics. Novel methods for the diagnosis of CCA seem promising; however, they have not been evaluated for the surveillance of patients with PSC.

## Disclosure Statement

The authors declare that there are no competing interests regarding this work.

## References

- Lindkvist B, Benito de Valle M, Gullberg B, Björnsson E: Incidence and prevalence of primary sclerosing cholangitis in a defined adult population in Sweden. *Hepatology* 2010;52:571–577.
- Folseraas T, Melum E, Rausch P, et al: Extended analysis of a genome-wide association study in primary sclerosing cholangitis detects multiple novel risk loci. *J Hepatol* 2012;57:366–375.
- Karlsen TH, Franke A, Melum E, et al: Genome-wide association analysis in primary sclerosing cholangitis. *Gastroenterology* 2010;138:1102–1111.
- Janse M, Lamberts LE, Franke L, et al: Three ulcerative colitis susceptibility loci are associated with primary sclerosing cholangitis and indicate a role for IL2, REL, and CARD9. *Hepatology* 2011;53:1977–1985.
- Melum E, Franke A, Schramm C, et al: Genome-wide association analysis in primary sclerosing cholangitis identifies two non-HLA susceptibility loci. *Nat Genet* 2011;43:17–19.
- Bergquist A, Ekblom A, Olsson R, et al: Hepatic and extrahepatic malignancies in primary sclerosing cholangitis. *J Hepatol* 2002;36:321–327.
- Zenouzi R, Weismüller TJ, Hübener P, et al: Low risk of hepatocellular carcinoma in patients with primary sclerosing cholangitis with cirrhosis. *Clin Gastroenterol Hepatol* 2014;12:1733–1738.
- Burak K, Angulo P, Pasha TM, Egan K, Petz J, Lindor KD: Incidence and risk factors for cholangiocarcinoma in primary sclerosing cholangitis. *Am J Gastroenterol* 2004;99:523–526.
- Charatcharoenwitthaya P, Enders FB, Halling KC, Lindor KD: Utility of serum tumor markers, imaging, and biliary cytology for detecting cholangiocarcinoma in primary sclerosing cholangitis. *Hepatology* 2008;48:1106–1117.
- Buckles DC, Lindor KD, Larusso NF, Petrovic LM, Gores GJ: In primary sclerosing cholangitis, gallbladder polyps are frequently malignant. *Am J Gastroenterol* 2002;97:1138–1142.
- Lewis JT, Talwalkar JA, Rosen CB, Smyrk TC, Abraham SC: Prevalence and risk factors for gallbladder neoplasia in patients with primary sclerosing cholangitis: evidence for a metaplasia-dysplasia-carcinoma sequence. *Am J Surg Pathol* 2007;31:907–913.

- 12 Schramm C, Lohse AW: Gallbladder polyps in primary sclerosing cholangitis: indication for early intervention. *Hepatology* 2012;56:396, author reply 396.
- 13 Levy MJ, Baron TH, Clayton AC, et al: Prospective evaluation of advanced molecular markers and imaging techniques in patients with indeterminate bile duct strictures. *Am J Gastroenterol* 2008;103:1263–1273.
- 14 Blechacz B, Gores GJ: Cholangiocarcinoma: advances in pathogenesis, diagnosis, and treatment. *Hepatology* 2008;48:308–321.
- 15 Bangarulingam SY, Björnsson E, Enders F, et al: Long-term outcomes of positive fluorescence in situ hybridization tests in primary sclerosing cholangitis. *Hepatology* 2010;51:174–180.
- 16 Barr Fritcher EG, Kipp BR, Voss JS, et al: Primary sclerosing cholangitis patients with serial polysomy fluorescence in situ hybridization results are at increased risk of cholangiocarcinoma. *Am J Gastroenterol* 2011;106:2023–2028.
- 17 Lankisch TO, Metzger J, Negm AA, et al: Bile proteomic profiles differentiate cholangiocarcinoma from primary sclerosing cholangitis and choledocholithiasis. *Hepatology* 2011;53:875–884.
- 18 Metzger J, Negm AA, Plentz RR, et al: Urine proteomic analysis differentiates cholangiocarcinoma from primary sclerosing cholangitis and other benign biliary disorders. *Gut* 2013;62:122–130.
- 19 Andresen K, Boberg KM, Vedeld HM, et al: Four DNA methylation biomarkers in biliary brush samples accurately identify the presence of cholangiocarcinoma. *Hepatology* 2015;61:1651–1659.
- 20 Khan SA, Davidson BR, Goldin RD, et al: Guidelines for the diagnosis and treatment of cholangiocarcinoma: an update. *Gut* 2012;61:1657–1669.
- 21 Chapman R, Fevery J, Kalloo A, et al: Diagnosis and management of primary sclerosing cholangitis. *Hepatology* 2010;51:660–678.
- 22 Campbell WL, Ferris JV, Holbert BL, Thaete FL, Baron RL: Biliary tract carcinoma complicating primary sclerosing cholangitis: evaluation with CT, cholangiography, US, and MR imaging. *Radiology* 1998;207:41–50.
- 23 Sinakos E, Saenger AK, Keach J, Kim WR, Lindor KD: Many patients with primary sclerosing cholangitis and increased serum levels of carbohydrate antigen 19-9 do not have cholangiocarcinoma. *Clin Gastroenterol Hepatol* 2011;9:434–439.e1.
- 24 Ballehaninna UK, Chamberlain RS: The clinical utility of serum CA 19-9 in the diagnosis, prognosis and management of pancreatic adenocarcinoma: an evidence based appraisal. *J Gastrointest Oncol* 2012;3:105–119.
- 25 Chapman MH, Sandanayake NS, Andreola F, et al: Circulating CYFRA 21-1 is a specific diagnostic and prognostic biomarker in biliary tract cancer. *J Clin Exp Hepatol* 2011;1:6–12.
- 26 Alvaro D: Serum and bile biomarkers for cholangiocarcinoma. *Curr Opin Gastroenterol* 2009;25:279–284.
- 27 European Association for the Study of the Liver: EASL Clinical Practice Guidelines: management of cholestatic liver diseases. *J Hepatol* 2009;51:237–267.
- 28 Wiencke K, Boberg KM: Current consensus on the management of primary sclerosing cholangitis. *Clin Res Hepatol Gastroenterol* 2011;35:786–791.
- 29 Razumilava N, Gores GJ, Lindor KD: Cancer surveillance in patients with primary sclerosing cholangitis. *Hepatology* 2011;54:1842–1852.
- 30 Boonstra K, Weersma RK, van Erpecum KJ, et al: Population-based epidemiology, malignancy risk, and outcome of primary sclerosing cholangitis. *Hepatology* 2013;58:2045–2055.