



# Imaging characteristics, misdiagnosis and microsurgical outcomes of patients with spinal dural arteriovenous fistula: a retrospective study of 32 patients

Han-Bing Zhang<sup>1#^</sup>, Xiao-Lei Zhai<sup>2#</sup>, Lu Li<sup>1</sup>, De-Shen Wu<sup>1</sup>, Guang-Liang Zhuang<sup>1</sup>, Qi-Wu Xu<sup>3</sup>, Hui Guo<sup>1</sup>, Jie Wang<sup>1</sup>

<sup>1</sup>Department of Neurosurgery, Shanghai Deji Hospital, Qingdao University, Shanghai, China; <sup>2</sup>Department of Neurosurgery, Shuyang Hospital, Xuzhou Medical University, Xuzhou, China; <sup>3</sup>Department of Neurosurgery, Huashan Hospital, Fudan University, Shanghai, China

**Contributions:** (I) Conception and design: HB Zhang; (II) Administrative support: H Guo; (III) Provision of study materials or patients: L Li; (IV) Collection and assembly of data: DS Wu; (V) Data analysis and interpretation: HB Zhang, XL Zhai; (VI) Manuscript writing: All authors; (VII) Final approval of manuscript: All authors.

<sup>#</sup>These authors contributed equally to this work.

**Correspondence to:** Jie Wang. Department of Neurosurgery, Shanghai Deji Hospital, Qingdao University, Shanghai, China. Email: wangjiejunying@126.com.

**Background:** Spinal dural arteriovenous fistula (SDAVF) is an extremely rare spinal vascular malformation. As SDAVF exhibits no specific clinical manifestations nor diverse imaging results, it is easily misdiagnosed, resulting in delayed treatment and irreversible neurological damage. Most patients were initially misdiagnosed, but there were few reports on reducing misdiagnosis.

**Methods:** A total of 32 consecutive patients, who presented to our institution (Shanghai Deji Hospital) with SDAVF between June 2013 and January 2016 were retrospectively analyzed. Data were collected on demographics, clinical presentation, imaging findings, follow-up, and clinical outcomes. The Aminoff-Logue scale (ALS) was used to assess clinical outcomes.

**Results:** Of the 32 enrolled patients (3 females, mean age 59.1±3.8 years), 23 patients (71.9%) were misdiagnosed as acute myelitis (11 patients), intramedullary tumors (6 patients), lumbar disc herniation (4 patients), and other conditions (2 patients). All patients underwent surgical procedures under electrophysiological monitoring. Fistulas were found in all 32 patients and were successfully occluded. The mean follow-up period was 19.22±8.21 months (ranging from 2 weeks to 30 months). One year later, 20 patients underwent magnetic resonance imaging (MRI), and 14 showed no T2 edema, and the edema was relieved in 6 patients. A total of 10 patients underwent enhancement MRI and no enhancement signs were detected. Among the 27 patients with long-time follow-up, the fistula had no residual or recurrence, 21 patients showed decreased ALS scores ( $P<0.05$ ). Six patients exhibited nonsignificant improvement. No aggravating patient was found. Prognosis differed significantly between patients with ALS <6 and those with ALS ≥6 ( $P<0.05$ ).

**Conclusions:** Spinal angiography should be performed with full intubation, and microcatheter angiography can reduce misdiagnosis. SDAVF must be differentiated from acute myelitis, intramedullary tumor, and other spinal vascular malformations. Microsurgical treatment is effective with a low recurrence rate.

**Keywords:** Spinal dural arteriovenous fistula (SDAVF); microsurgery; electrophysiology; misdiagnosis

Submitted Jun 15, 2022. Accepted for publication Aug 04, 2022.

doi: 10.21037/atm-22-3568

**View this article at:** <https://dx.doi.org/10.21037/atm-22-3568>

<sup>^</sup> ORCID: 0000-0003-0183-9986.

## Introduction

Spinal dural arteriovenous fistula (SDAVF) refers to the dural branch of the radicular artery, which passes through the intervertebral foramen at the proximal dura of the spinal nerve root and communicates abnormally with the root vein of the spinal cord (1,2). SDAVF is the most common type of vascular malformation of the spinal cord and tends to occur during middle and older age. The ratio of males to females with SDAVF ranges from 5:1 to 9:1. The expected annual incidence is 5–10 new cases per million individuals, accounting for 70–80% of the arteriovenous shunt diseases of the spinal cord (3-8).

The main pathological changes in SDAVF, including chronic medullary venous hypertension, blood stasis, spinal cord edema, ischemia, and hypoxia, lead to venous congestive spinal cord disease (2,3), which in turn results in a series of clinical manifestations such as limb sensory abnormalities, as well as decreased muscle strength and sphincter dysfunction. However, if SDAVF is correctly diagnosed in a timely manner, it can be treated effectively by blocking the fistula and interrupting the pathological changes in the spinal vein hypertension before any irreversible changes to spinal nerve function occur.

However, SDAVF, especially in the early stages of the disease, is often misdiagnosed as acute encephalomyelitis, intramedullary spinal cord tumors, and other spinal arteriovenous shunt diseases due to the lack of specific and atypical imaging findings. Some patients cannot be clearly diagnosed for a prolonged period of time, which can delay their treatment, resulting in irreversible spinal nerve function injury (9,10).

This study summarized our experience of diagnosing and treating spinal dural arteriovenous fistulas, especially the atypical and misdiagnosed cases. We have formulated an explorative diagnostic process for these unique cases. The misdiagnosis was significantly reduced. We present the following article in accordance with the STROBE reporting checklist (available at <https://atm.amegroups.com/article/view/10.21037/atm-22-3568/rc>).

## Methods

### *General information*

A retrospective analysis of consecutive patients with angiographic-confirmed dural arteriovenous fistulas admitted from June 2013 to January 2016. A total of

32 patients, including 29 males and 3 females, with an average age of  $59.1 \pm 3.8$  years (range, 32–75 years) were enrolled. The disease course ranged from 4 days to 60 months, with an average duration of  $14.7 \pm 5.16$  months. The clinical manifestations included defecation dysfunction in 27 cases (84.4%), weakness in 25 cases (78.1%), numbness in 23 cases (71.9%), pain in 9 cases (28.1%), paraplegia in 3 cases (9.4%), constrictive band sensation around the waist in 3 cases (9.4%), and subarachnoid hemorrhage (headache, nausea, and vomiting) in 2 cases (6.2%). The most common complaints were urinary dysfunction, sensory dysfunction, and limb weakness. Symptoms in 5 of the patients were exacerbated after embolization in the external hospital, and recurrence was found after imaging examination. Spinal cord neurological function was assessed by the modified Aminoff-Logue scale (ALS) (11) and the patients were divided into 2 groups depending on their ALS, namely the excellent group with ALS <6 points and the moderate group with ALS  $\geq 6$  points. We found that patients with ALS <6 points had better postoperative improvement than those with ALS  $\geq 6$  points before surgery. The study was conducted following the Declaration of Helsinki (as revised in 2013). This study was approved by the Ethics Committee of Shanghai Deji Hospital (No. 2016-05). Written informed consent was obtained from the patient.

### *Imaging evaluation*

All 32 patients underwent magnetic resonance imaging (MRI) before the operation, and 28 (87.5%) patients had the T2-weighted continuous hyperintense signals. There were 20 patients of ventral and dorsal sulcus observed on the T2-weighted images (T2WI) and fat suppression (FATSAT). The T2WI and FATSAT images showed “wormlike” cavitation of blood vessels on the ventral and dorsal sides of the spinal cord in 20 cases and tortuous and disorderly striated blood vessels on the surface of the coronal spinal cord in 6 cases. Enhanced MRI was performed on 20 patients before surgery, including 10 patients with focal and linear enhancement on the surface of the spinal cord and 6 patients with patchy enhancement of the spinal cord. A total of 15 patients underwent magnetic resonance angiography (MRA) before the operation, and all showed abnormal vascular shadows in the spinal canal. Occasionally, the proximal drainage vein was displayed, which may indicate a fistula. A spinal vascular digital subtraction angiography (DSA) examination was performed

before the operation. The drainage vein could ascend or descend for a long distance, the venous blood flow was slow, and the circulation time was prolonged. The fistula was located in the middle thoracic segment in 11 patients (34.4%), the lower thoracic segment in 8 patients (25.0%), the lumbar segment in 7 patients (21.9%), and the cranial-cervical junction area in 6 patients (18.8%). There were 21 patients (65.6%) on the left side and 11 patients (34.4%) on the right side. There were 29 patients of a single blood supply artery, 2 patients of double-branch arteries, and 1 patient of triple-branch arteries.

### *Microsurgical treatment and intraoperative monitoring*

According to the position of the fistula determined by DSA, a spine X-ray was performed before the operation to identify the vertebral body segment where the fistula was located. Microsurgery under general anesthesia was performed with the patient lying prone. From the lesion side of the hemilaminectomy, the fistula was explored in the dura mater near the nerve root sheath sleeve, and the drainage vein was identified by Doppler ultrasound. If the proximal drainage vein at the fistula was temporarily blocked, all of the drainage vessels on the surface of the spinal cord collapsed, which decreased the tension, darkened the color, and cause the noise to disappear. By applying bipolar cauterization, the drainage vein at the proximal end of the fistula was disconnected, and electrocoagulation was used to cauterize the two ends of the drainage vein. The potential collateral branch vessels of the SDAVF were occluded by electrocoagulation of the dura mater near the fistula. Injury to the spinal cord, spinal nerves, and their supply of blood vessels and drainage veins was avoided during the surgery.

All patients underwent surgical procedures under electrophysiological monitoring, including measurement of somatosensory evoked potentials (SEP), motor evoked potentials (MEP), and electromyography (EMG). After successful anesthesia, a set of waveforms was recorded as a baseline for comparison with the monitoring results during and after surgery. The SEP alarm was typically set to indicate a >50% decrease in amplitude and a >10% increase in latency. The standard MEP warning was “all” or “none”. A high-frequency burst-type electrical activity waveform prompted the EMG alarm. During the operation, if the SEP, MEP, or EMG prompted an early warning, the surgeon suspended the operation and observed the change in the waveform. The surgeon would then determine the presence of a spinal cord or nerve injury, correct the

operation mode, and continue the operation when the waveform reached the baseline level.

### *Follow-up*

During the follow-up, neurological function was evaluated using the ALS score as follows: if the score was unchanged or increased by >1, there was no improvement; if the score was reduced by >1, there was improvement. The MRI and MRA results were reviewed and compared with preoperative images in terms of spinal edema and abnormal blood vessels. Some patients were hospitalized to undergo DSA to determine the presence of any residual or recurrence of the fistula. However, most patients who showed improved symptoms, including dissipation of spinal cord edema and disappearance of abnormal vascular flow on MRI, refused to undergo a repeat DSA.

### *Statistical analysis*

Data were statistically analyzed using IBM SPSS software (version 19; IBM Corp., Armonk, New York, USA). Measurement data are expressed as the mean± standard deviation (SD). Paired *t*-tests were used to compare variables before and after surgery in each group. The difference was scored before normal comparisons were performed. The correlation between preoperative disease severity and prognosis was analyzed by Fisher's exact probability test, and the significance level was  $\alpha=0.05$ .

## **Results**

### *Diagnosis and misdiagnosis*

A total of 32 patients were enrolled in this study and all were diagnosed with spinal fistula according to their clinical manifestations, MRI, and DSA results, and later by surgical confirmation. During the course of diagnosis and treatment, 23 patients were misdiagnosed, resulting in a misdiagnosis rate of 71.9%. Patients were initially assessed by a neurologist (70%), an orthopedic surgeon (22%), a Urologist (4%), and another specialist (4%). Of these, 11 patients were misdiagnosed with myelitis (increased clinical severity after hormone therapy), 6 patients were misdiagnosed with intramedullary spinal cord tumors, 4 patients were misdiagnosed with lumbar disc herniation (2 patients received orthopedic surgery, without any improvement), 2 patients were misdiagnosed

with other diseases.

### **Results of surgery and electrophysiological monitoring**

All 32 patients had a definite preoperative diagnosis, and a fistula was detected in all patients during surgery. During the operation, the fistula was closed, and the proximal drainage vein was severed by electrocoagulation. Additionally, electrocoagulation was used to cauterize the dura mater around the fistula and the nerve roots.

All operations were performed under electrophysiological monitoring. No significant change was observed in the baseline of the SEP during the operation, and the repeatability of multiple recordings was good. MEP warnings occurred in 10 cases, which were caused by pulling the spinal cord when exploring the fistula, resulting in separation of the drainage vessels and nerve roots. The MEP amplitude was gradually improved after the electrophysiologic technician reminded the surgeon to stop the operation, reduce the traction and adjust the operation mode. During the operation, EMG records showed that 9 patients had transient bursts of high-amplitude myoelectric activity during the separation of the proximal drainage vein and cauterization of the epidural membrane. However, after adjusting the operation mode, no further alarms occurred during the operations.

### **Long-term treatment outcomes**

The 32 patients were followed up for 2 weeks to 30 months, with an average follow-up duration of  $19.22 \pm 8.21$  months. During the short-term and long-term follow-up (5 patients underwent long-term follow-up), the ALS scores decreased to varying degrees (*Table 1*). Among the 23 misdiagnosed patients, the average of ALS score was 6.5 before surgery, but one year after surgery the score was 3.6. The spinal cord function before surgery had a direct impact on postoperative recovery (*Table 2*) and patients with a lower ALS score achieved better postoperative recovery.

At the 1-year follow-up, 20 patients underwent spinal MRI examinations, and no vascular flow shadow was observed on the surface of the spinal cord. The edema disappeared in 14 patients, and 6 patients exhibited significant reduction in the levels of edema. No signs of enhancement were observed in 10 patients on spinal cord enhanced MRI. Eight patients were hospitalized to undergo DSA, and no residual or recurrence of the fistula was observed.

## **Discussion**

It is more common in middle-aged man, most patients present with myelopathy symptoms. Given the age and sex of presentation, many patients have associated clinical and imaging findings, such as spinal disc protrusion, hyperplasia of the prostate, previous surgery, and even trauma, that can confuse the diagnosis. Patients were initially assessed by a neurologist, a Urologist, an orthopedic surgeon, or another specialist. As a result, the misdiagnosis rate was quite high (30–76%) (12–14). In our series, the misdiagnosis rate was 71.9%.

### **Imageology**

Due to the nonspecific nature of the presentation and the slow onset, diagnosis of SDAVF depends on imaging examination findings. Spinal cord edema, thickening, and “worm-like” vascular flow shadows are observed on MRI. After enhancement, the visible points, linear enhanced vascular shadow, and sometimes the spinal cord can show patch-like enhancement (15,16). MRA can better reveal the tortuosity of drainage vessels, and some images can show the location of a fistula, which can provide the basis for DSA screening (17,18). In this group of patients, 32 underwent MRI before the operation, 28 had spinal edema, and 20 had a “worm-like” vascular flow shadow. Twenty patients underwent enhanced MRI before the operation, with 10 patients showing spinal surface points and linear enhancement, and 6 patients exhibiting patchy enhancement. The 15 patients who underwent MRA showed abnormal blood vessels, suggesting spinal cord vascular malformation. According to the typical manifestations on MRI and MRA, it is possible to determine the presence of spinal vascular lesions.

DSA can be used to identify the origin of the blood supply artery of the SDAVF, the location of the fistula, and the route of the drainage vein, and is the gold standard for the diagnosis of SDAVF and a determinant of recurrence after surgery (6,19,20). However, to avoid missed diagnoses and misdiagnoses, DSA examinations should be conducted while considering the following points. The area showing edema may not be the location of the fistula. Therefore, total spinal vascular DSA should be performed for suspected fistula cases. In addition to the segmental arteries that supply the spinal cord, the vertebral artery, thyrocervical trunk, costocervical trunk, internal and external iliac arteries, internal and external carotid arteries, and even

**Table 1** Comparison of ALS scores before and after surgery

No.	Preoperative				2 weeks after the operation				1 year after the operation				Follow-up (months)
	Total	Gait	Urinate	Defecate	Total*	Gait <sup>△</sup>	Urinate <sup>△</sup>	Defecate <sup>△△</sup>	Total*	Gait <sup>△</sup>	Urinate <sup>△</sup>	Defecate <sup>△△</sup>	
1	4	2	1	1	3	1	1	1	0	0	0	0	30
2	8	5	2	1	6	4	1	1	5	2	2	1	28
3	10	5	3	2	9	4	3	2	6	3	2	1	12
4	7	4	2	1	6	3	2	1	6	3	2	1	19
5	5	4	1	0	5	4	1	0	2	2	0	0	18
6	9	5	2	2	9	5	2	2	9	5	2	2	17
7	9	5	2	2	9	5	2	2	6	3	1	2	20
8	1	0	1	0	1	0	1	0	0	0	0	0	19
9	6	3	2	1	3	1	1	1	2	0	1	1	17
10	8	5	2	1	5	3	1	1	–	–	–	–	0.5
11	7	4	2	1	5	2	2	1	4	2	1	1	16
12	7	2	3	2	4	0	3	1	–	–	–	–	0.5
13	6	4	1	1	4	4	0	0	3	3	0	0	22
14	5	2	2	1	4	1	2	1	–	–	–	–	0.5
15	10	5	3	2	7	5	1	1	6	4	1	1	12
16	7	4	2	1	4	3	1	0	–	–	–	–	0.5
17	6	4	2	0	4	2	2	0	4	2	1	1	15
18	0	0	0	0	0	0	0	0	0	0	0	0	20
19	0	0	0	0	0	0	0	0	0	0	0	0	23
20	3	3	0	0	0	0	0	0	0	0	0	0	21
21	6	3	2	1	3	0	2	1	1	0	0	1	15
22	6	3	2	1	4	2	1	1	5	2	1	2	13
23	9	5	3	1	7	4	2	1	6	4	1	1	21
24	7	3	2	2	8	4	2	2	–	–	–	–	0.5
25	4	3	0	1	0	0	0	0	0	0	0	0	24
26	10	5	2	3	4	3	0	1	5	2	1	1	15
27	9	5	2	2	9	5	2	2	9	5	2	2	24
28	8	5	2	1	10	5	3	2	8	4	2	2	17
29	9	5	2	2	8	4	2	2	6	3	2	1	13
30	5	3	1	1	0	0	0	0	0	0	0	0	18
31	5	3	1	1	2	0	1	1	0	0	0	0	26
32	5	3	1	1	4	2	1	1	2	1	0	1	24

A paired *t*-test was used to compare the preoperative and postoperative ALS scores in each group. \*, comparison of total postoperative ALS score and total preoperative ALS score,  $P < 0.05$ ;  $\Delta$ , compared to the corresponding score before surgery,  $P < 0.05$ ;  $\Delta\Delta$ , compared to the corresponding score before surgery,  $P > 0.05$  (not statistically significant). –, missed the long-term follow-up visit. ALS, Aminoff-Logue scale.

**Table 2** The relationship between preoperative neurological status and postoperative improvement

Preoperative neurological status	Follow-up		
	Improvement (patients)	No improvement (patients)	Total (patients)
Good (ALS <6)	10	0	10
Moderate (ALS ≥6)	12	5	17
Total	22	5	27

Statistical analysis was performed using Fisher's exact probability calculation. Patients with ALS <6 were compared with patients with ALS ≥6, and the improvement was statistically significant ( $P < 0.05$ ). ALS, Aminoff-Logue scale.

the central sacral artery should be included. In our study, 1 patient initially had negative DSA results, and neurological treatment was recommended. However, the symptoms continued to worsen, and a lumbosacral spinal vascular malformation was highly suspected upon re-examination by MRI. When repeat angiography was performed, the lumbosacral vessels were individually superselected, and the blood supply to the SDAVF was determined to be the right internal iliac artery branch. The SDAVF sometimes had multiple blood supply artery branches, and the dose of contrast agent entering the associated vessels was insufficient. Therefore, if the catheter location is too deep or shallow, the lesion will not be visible. It may be necessary to adjust the catheter direction and depth to visualize the lesion. Based on these facts, DSA cannot exclude the presence of a lesion. When MRI signs cannot completely exclude spinal vascular diseases, DSA should be reviewed multiple times (21). If necessary, superselective microcatheter angiography should be applied to establish an accurate diagnosis (22). We encountered one case of SDAVF with preoperative MRI showing spinal edema. On conventional DSA imaging, we could not identify the fistula, and only abnormal blood vessels were displayed due to the co-trunks of the T3, T4, T5, and T6 intercostal arteries, indicating an arteriovenous fistula (AVF), but the fistula and blood supply artery could not be clearly displayed. Microcatheterization was then applied during angiography with intubation, which clearly showed that the blood was supplied by the R-T4 intercostal artery, and the fistula was located at the level of the T5 vertebra.

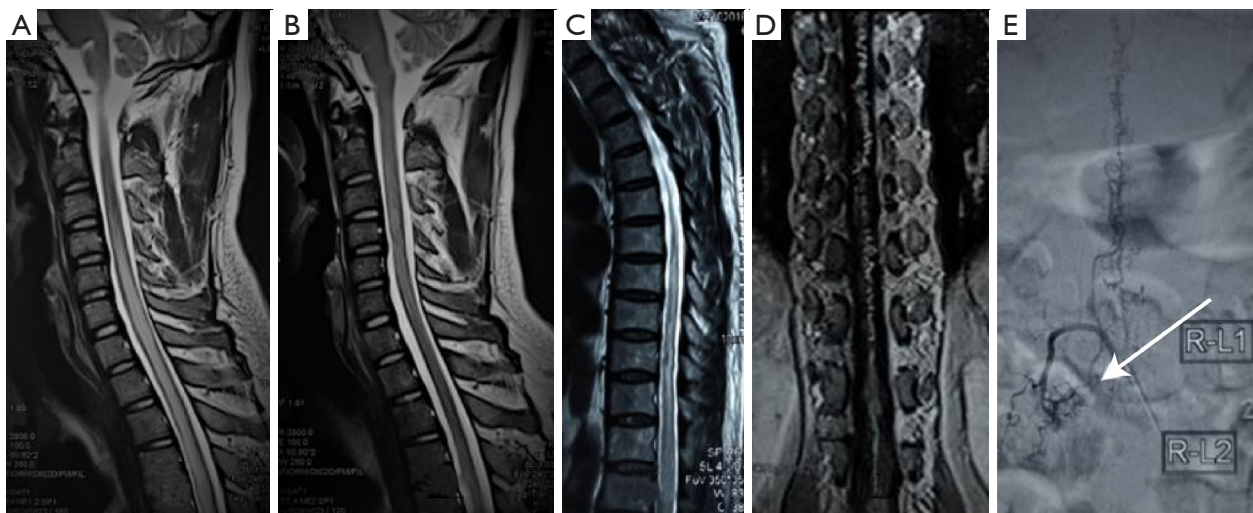### Differential diagnosis

Due to the nonspecific nature of the presenting symptoms, SDAVF often go clinically undiagnosed or are misdiagnosed as acute myelitis (23), intramedullary tumors, spinal arteriovenous malformation (SAVM), or perimedullary

arteriovenous fistula (PMAVF). They are occasionally confused with Cognard type V dural arteriovenous fistula (DAVF) when MRI shows only spinal edema and DSA fails to show abnormal blood vessels due to technical factors or shows atypia. Therefore, careful identification should be performed during the diagnosis and treatment process.

### Acute myelitis

SDAVF has an acute onset with acute spinal nerve dysfunction, and when MRI only shows signs of spinal edema, it can easily be misdiagnosed as acute myelitis (24). Acute myelitis is a transverse spinal cord injury caused by a series of immune responses due to various factors. It is more common in young women. Immunological examination of blood and cerebrospinal fluid can show positive central nervous system demyelinating disease antibodies, and spinal MRI shows no vascular shadow (*Figure 1A*). In such cases, treatment with corticosteroids and high-dose immunoglobulin was effective, and spinal cord edema subsided on follow-up MRI (*Figure 1B*). If spinal cord MRA and/or spinal cord vascular DSA are performed, no abnormal blood vessels will be observed in the spinal canal. SDAVF is more common in middle-aged and older men and is often caused by strenuous exercise and other factors. No positive change in laboratory tests occurred. In contrast, spinal MRI showed that the spinal cord edema consisted of a thin strip that was pointed at both ends (*Figure 1C*). Very few vascular flow shadows were found. If corticosteroids are given, symptoms can be aggravated, and spinal cord edema will persist on MRI (25-27). The diagnosis can be confirmed by spinal MRA and DSA (*Figure 1D,1E*). During the diagnosis and treatment of this group of patients, 15 were misdiagnosed with myelitis, which was confirmed as SDAVF by MRA and DSA. Clinically, for cases of spinal cord edema on MRI and negativity on MRA and/or DSA, close clinical observation or careful use of hormone treatment should be performed if the clinical manifestations



**Figure 1** Myelitis and R-L2 SDAVF. (A,B) Cervical myelitis. MRI shows cervical spinal cord edema without a vascular shadow (A). Re-examination of the cervical MRI after 3 months showed the disappearance of cervical segment edema (B). (C-E) R-L1 SDAVF image changes. The MRI demonstrates that the thoracic spinal cord edema was increased, without an obvious abnormal vascular shadow (C). To observe the progressive aggravation of symptoms at 4 months, a spinal MRA was conducted, which shows abnormal blood vessels (D). The DSA shows that the blood supply to the SDAVF is the right L1 segmental artery. The white arrow indicates the position of the fistula (E). SDAVF, spinal dural arteriovenous fistula; MRI, magnetic resonance imaging; MRA; magnetic resonance angiography; DSA, digital subtraction angiography.

are aggravated or if spinal cord edema persists on MRI after several months. The DSA results should be reviewed to confirm the diagnosis. If the clinical manifestations are improved and the spinal cord edema subsides, acute myelitis can be diagnosed.

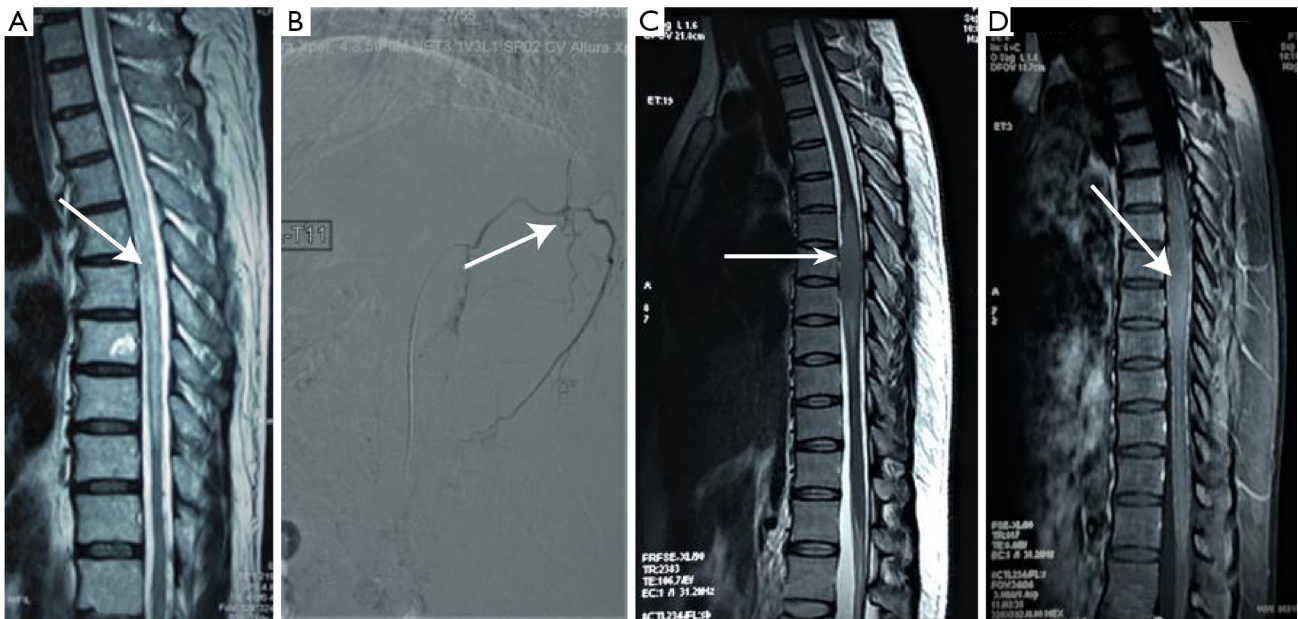### Intramedullary tumor

When SDAVF patients have chronic disease, the MRI only shows localized spinal edema or thickening (*Figure 2*), and enhanced MRI of the spinal cord shows irregular (28,29), spotty enhancement (*Figure 3*), and thus, SDAVF can be misdiagnosed as an intramedullary tumor. Conversely, a small number of high-grade intramedullary tumors can be mistaken for SDAVF due to swelling of the spinal cord (*Figure 4A,4B*) and a point-like enhancement of vascular shadows on the surface of the spinal cord (*Figure 4C*). Therefore, an SDAVF can be confused with a spinal cord intramedullary tumor. The edema of the spinal cord consists of a thin strip with a pointed shape at both ends (*Figures 2A,3C*). A close examination of the imaging data may reveal a small amount of vascular emptying, but the severity of the clinical manifestations is difficult to explain by the degree of swelling in the spinal cord. SDAVF can be confirmed by abnormal blood vessels and the presence

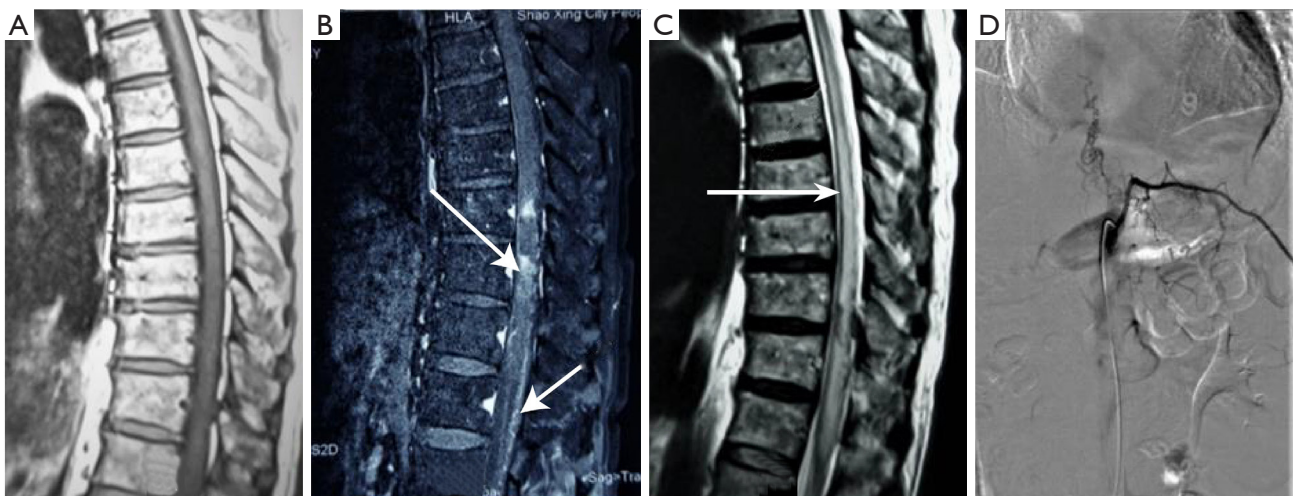
of a fistula on MRA and DSA examination (*Figures 2B,3D*). However, for low-grade glioma, the lesion is relatively limited on T2WI, and both ends of the lesion are usually round and obtuse (*Figure 2C*). Abnormal vessels with tortuosity are usually not found on MRA or DSA. Even for high-grade glioma, when abnormal vascular shadows can be seen on MRI and MRA, DSA is still negative. If the disease progresses rapidly, MRI examination is more conducive to the diagnosis of high-level glioma when a suspected cava or cava lesions are present. We encountered a patient with a C2-5 intramedullary glioblastoma [World Health Organization (WHO) class IV], whom we had planned to diagnose with SDAVF, and the DSA was negative (*Figure 4D-4G*). Due to the rapid progression of the disease, we considered intramedullary high-grade glioma and conducted surgical exploration, which was confirmed by pathology. Based on this case, the most important differential measure is spinal vascular DSA. For SDAVF, DSA can show abnormal blood vessels and a fistula, but these are not found for intramedullary tumors.

### Other spinal vascular malformations

The differentiation of SDAVF from PMAVF and SAVM is also very important because if the diagnosis is incorrect, the

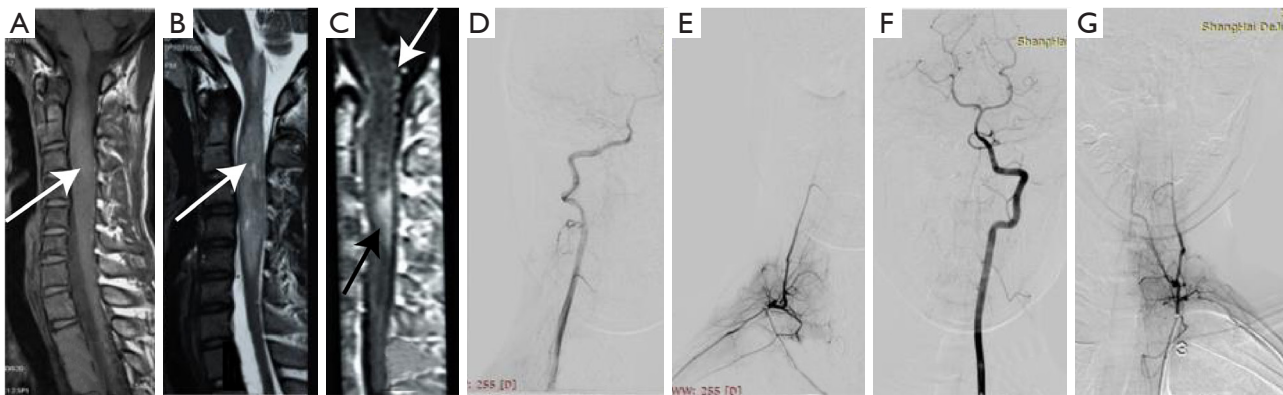


**Figure 2** L-T11 SDAVF and low-grade glioma. (A,B) L10 SDAVF. (A) The MRI shows spinal edema and thickening white arrow, and no “worm-like” vascular flow voids were observed. (B) SDAVF was angiographically confirmed, the white arrow indicates the position of the fistula. (C,D) Low-grade glioma. (C) The MRI shows a limited lesion, obvious swelling of the spinal cord, round and obtuse ends, and obvious narrowing of the subarachnoid cavity (white arrow). (D) Enhanced MRI shows mild enhancement, and the diagnosis was confirmed as low-grade glioma (arrow). SDAVF, spinal dural arteriovenous fistula; MRI, magnetic resonance imaging.



**Figure 3** L-T11 SDAVF. (A,B) The MRI shows mild irregular lamellar enhancement of the spinal cord (long arrow), which was reported as an intramedullary tumor (after review of the image data, an abnormal vascular shadow was observed on the surface of the spinal cord of the lower thoracic segment, short arrow). (C) The T2WI shows middle and lower thoracic edema and mild spinal cord thickening (white arrow). (D) The spinal cord DSA shows an L-T11 SDAVF. SDAVF, spinal dural arteriovenous fistula; MRI, magnetic resonance imaging; T2WI, T2 weighted image; DSA, digital subtraction angiography.





**Figure 4** Imaging changes of the C2–5 intramedullary glioblastoma. (A,B) Cervical spinal MRI shows “spindle” thickening of the cervical spinal cord (white arrow), with an irregular high signal on T2 (white arrow). (C) Enhanced MRI shows lamellar enhancement of the spinal cord (black arrow). A vascular shadow was observed on the surface of the spinal cord (white arrow). (D–G) The DSA shows no tortuosity or abnormal vessels. MRI, magnetic resonance imaging; DSA, digital subtraction angiography.

determination of lesion position and design of the treatment plan will be incorrect, resulting in adverse consequences. In most cases, the DSA manifestations of these lesions have unique characteristics and can be identified. SDAVF refers to the dural branch of the spinal cord root artery, which communicates directly with the root vein at the dura mater near the nerve root sheath cuff, forming a fistula, which is usually only supplied by a single artery. PMAVF involves direct communication between the spinal cord soft spinal artery and the vein on the surface of the spinal cord. It is usually supplied by the anterior and posterior spinal arteries. SAVM refers to arteriovenous shunt vascular disease with an abnormal vascular network between the blood supply artery and the drainage vein, and multiple arteries often supply blood.

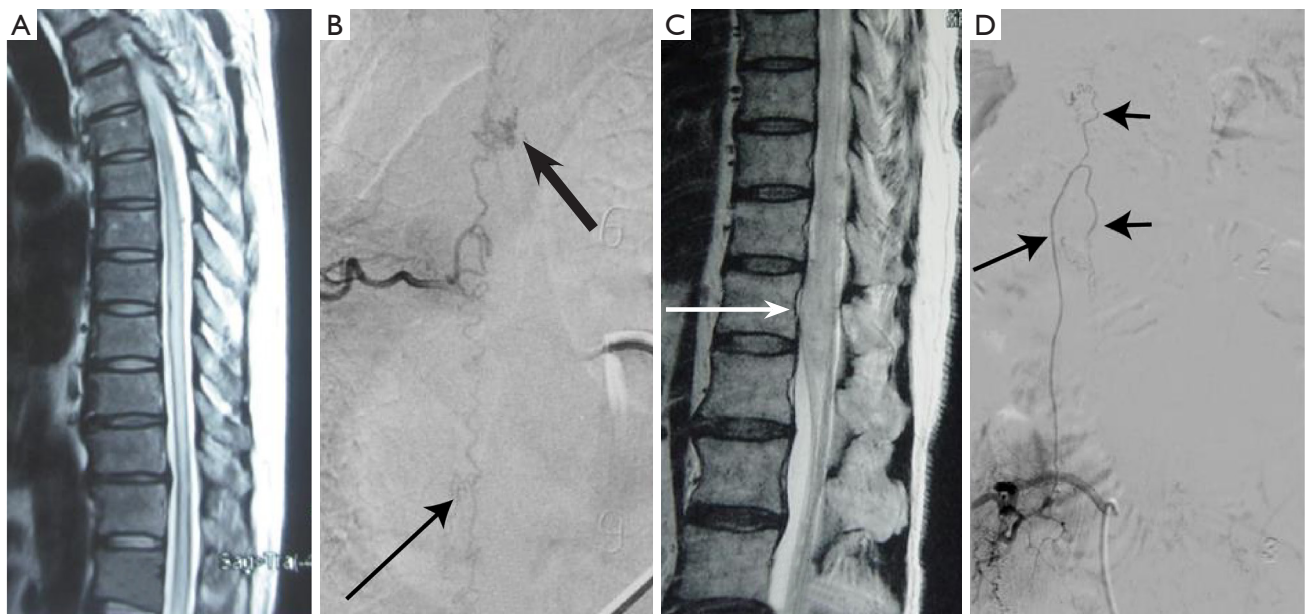
However, when DSA shows abnormal vascular masses, SDAVF could be misdiagnosed as SAVM. We encountered an SDAVF patient with a right T7 intercostal artery blood supply. DSA showed an abnormal vascular mass in the upper part of the T6 vertebral body, which was reported as an AVM. However, because this patient was a middle-aged male with chronic onset, no lesions were present on MRI (*Figure 5A*). Unlike SAVM, which is more common in young women and has an acute onset, MRI showed abnormal vascular lesions, and DSA showed only a single arterial blood supply, while abnormal blood vessels were present at the T9 vertebral body level (*Figure 5B*). The rod-shaped vessels between the abnormal blood vessel mass of T6 and the intercostal artery

of T7 were thick and curved, unlike the hairpin type of the anterior root medullary artery (*Figure 5B*), and could be reasonably explained by the proximal drainage vein of an SDAVF, which was later confirmed by surgery.

When the proximal drainage vein of an SDAVF resembles the anterior medullary artery, it can be mistaken for PMAVF. We encountered a case of SDAVF at the level of the R-L2 vertebral body. The lumbar MRI (T2WI) shows spinal edema (*Figure 5C*). The proximal drainage vein was straight, resembling the anterior root medullary artery, and the drainage vein was drained vertically, apparently by the upper and lower branches of the anterior spinal artery (*Figure 5D*). Therefore, this case was initially considered PMAVF. However, in this case, the “rod-shaped” blood vessels deviated from the midline on DSA, and the abnormal blood vessels in the spinal canal failed to show a fistula. It was also unreasonable to suggest that the upper and lower anterior spinal cord artery were used to supply two fistulas. Therefore, the diagnosis was SDAVF, which was confirmed by surgery.

### Dural arteriovenous fistula

Cognard type V DAVF causes spinal cord dysfunction due to its drainage into the venous system of the spine, leading to venous congestive cervical myelopathy (30). MRI can show increased cervical spinal cord edema and the cavitation of blood vessels in the spinal canal; therefore,



**Figure 5** R-T7 and R-L2 SDAVF. (A,B) R-T7 segmental arterial blood supply to the SDAVF. (A) Thoracic vertebral MRI (T2WI) shows spinal edema. (B) The DSA shows an abnormal vascular mass in the upper part of the T6 vertebral body (thick arrow), reported as an AVM, but in view of the absence of malformation on MRI and the fact that DSA seemed to show abnormal blood vessels (thin arrow) at T9, it was considered an SDAVF, which was confirmed by surgery. (C,D) R-L2 blood supply of the SDAVF. (C) The lumbar MRI (T2WI) shows spinal edema (white arrow). (D) The spinal cord vascular DSA shows that the proximal drainage vein had a similar appearance to the anterior root artery (long arrow). Its upper and lower branches deviates from the midline (short arrows), and no fistula was present. It was clear that the lesion was an SDAVF supplied by R-L2. SDAVF, spinal dural arteriovenous fistula; MRI, magnetic resonance imaging; T2WI, T2 weighted image; DSA, digital subtraction angiography.

it can be confused with C1 SDAVF. Clinically, if there is insufficient understanding of this phenomenon, even DSA cannot be used for diagnosis, and patients can only be followed up and treated according to protocols for cervical spinal cord lesions. Surgical exploration of cervical spinal cord lesions can lead to serious consequences. MRI can identify abnormal vascular and venous sinus embolisms in the skull. Once the spinal vascular DSA is complete, angiography should also include the internal and external carotid and the vertebral arteries to indicate the presence of type V DAVF. We had encountered a patient with Cognard type V DAVF that was mistaken for SDAVF. Whole-spinal angiography was negative on two occasions, but the abnormal vascular shadow persisted on follow-up MRI. In the DSA examination, internal and external carotid artery cannulation was confirmed, and the DAVF was confirmed in the petroclival region.

### *Surgery and electrophysiological monitoring*

Currently, SDAVF treatment includes microsurgery, interventional embolization, or a combination of the two. It is generally believed that compared to surgical treatment, interventional therapy is less traumatic, and relapse is more likely to occur due to inadequate embolization, open collateral circulation, and the formation of a vascular network around the fistula (31,32). We also had similar experiences and therefore, we believe that interventional embolization is suitable for patients with advanced age, poor physical condition, unwillingness to undergo open surgery, or thicker and straighter blood supply arteries because this procedure is expected to reach the fistula and allow embolization of the proximal drainage vein (4,33). Most patients are candidates for microsurgery (34-36).

SDAVF should be treated as soon as possible upon

diagnosis (2,37,38). Emergency surgery should be conducted for patients with acute changes or even paraplegia caused by various factors. The location of the fistula should be accurately identified before surgery to avoid multisegment incision and exploration and increased injury (21). Microsurgery is performed under direct vision, and ideal surgical results can be achieved after a clear and closed fistula is explored (19,39). Koch *et al.* reported a 88% rate of improvement for 47 patients with SDAVF after surgery (39). Schuss *et al.* also found that 22 patients (76%) achieved improvement in neurologic symptoms after surgical treatment (40). In the present series, 32 patients were diagnosed preoperatively and underwent microsurgery. At the 1-year follow-up, 21 patients (77.8%) had ALS score reduction compared with preoperative, which is similar to that reported in the literature (3,37,41). Compared to preoperative treatment, the improvement of spinal cord function, especially exercise and urine function, was significant ( $P<0.05$ ; *Table 2*). No recurrence or residual of fistula was found during follow-up, and the rate of fistula occlusion was 100%.

Intraoperative electrophysiological monitoring can reduce iatrogenic damage to the spinal cord and nerve roots (42,43). It is more commonly used in the treatment of intramedullary tumors (44,45) and has rarely been reported for SDAVF microsurgery. In these patients who had given intraoperative electrophysiological monitoring, the MEP early warning appeared in 10 cases of spinal cord injury caused by pulling of the spinal cord when exploring the fistula and separating the drainage vessels and nerve roots. After the reduction of traction and adjustment, the amplitude of the wave was improved, and postoperative recovery was good. Intraoperative electrophysiological monitoring can warn the surgeon of invasive manipulations of the spinal cord, especially for untrained surgeons who are unfamiliar regarding the degree of pulling of the spinal cord. Thus, the application of electrophysiological monitoring can decrease unnecessary spinal cord injury.

### *Prognostic factors*

#### **Preoperative neurological function**

Intervention at an early stage is essential for a preferable

outcome of SDAVF treatment. Treatment should be performed before an irreversible change to spinal neurological function occurs (46). The preoperative functional status has an important effect on the prognosis (7,35,47,48). Cecchi *et al.* performed a long-term follow-up of 29 patients and found that preoperative neurological status was the only factor that affected the prognosis of patients (49). In a meta-analysis of 1,112 cases of SDAVF in 2015, Bakker *et al.* noted that the degree of postoperative recovery depended mainly on the preoperative neurological status (3). In this study, a significant correlation was found between the preoperative ALS score and the ALS score at 1 year postoperatively ( $P<0.05$ ; *Table 1*), indicating that microsurgery was effective. After 1 year of follow-up, the improvement in the excellent group was significantly greater than that of the moderate group ( $P<0.05$ ; *Table 2*), indicating that worse preoperative neurological function reflects more severe spinal cord injury and a more difficult postoperative recovery.

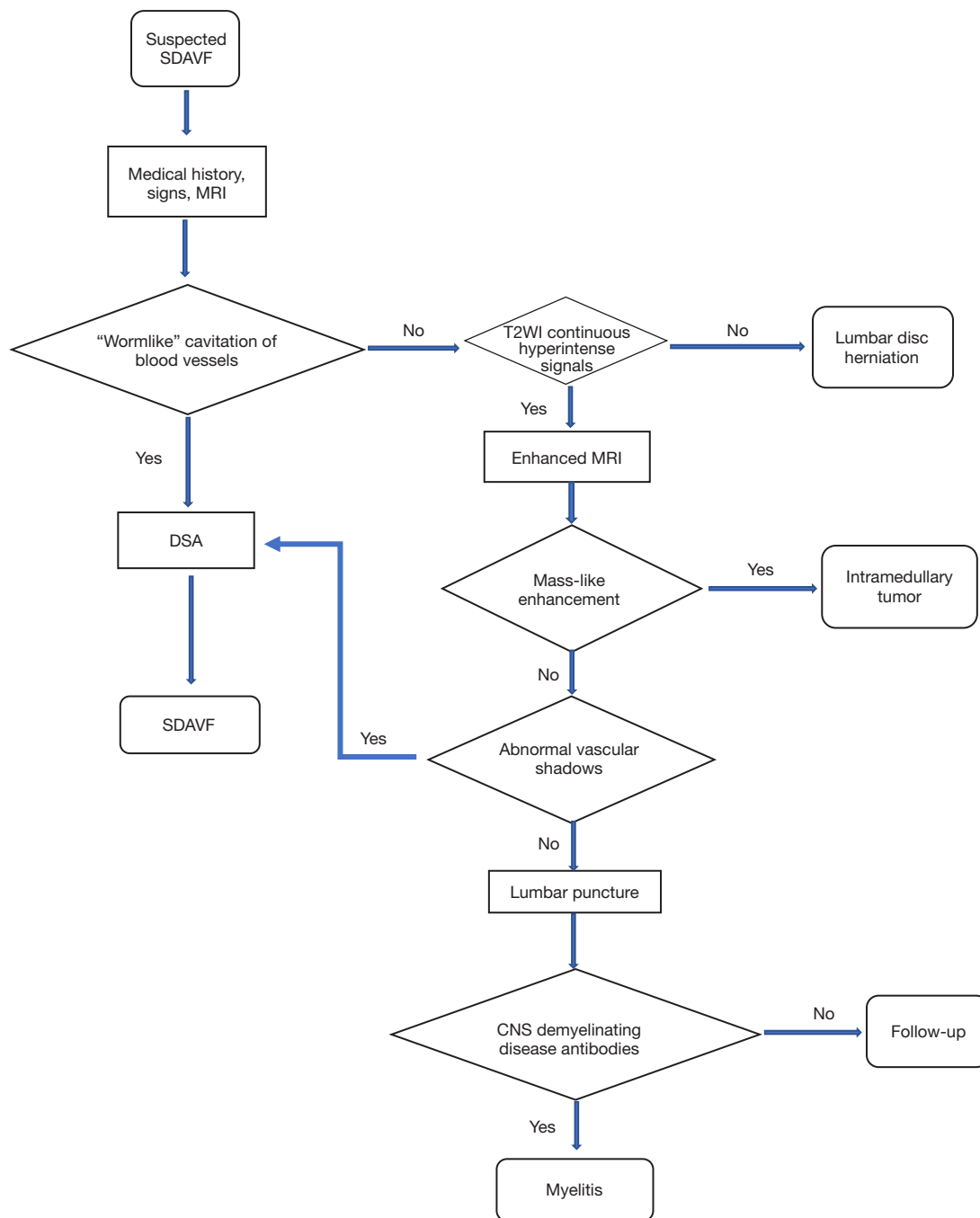
According to the history, clinical manifestations, neurological examination, MRI and DSA, the misdiagnosis rate of 32 patients was significantly reduced at the time of operation, which was confirmed by operation. We have formulated an explorative diagnostic process for these unique cases (*Figure 6*).

### **Conclusions**

The misdiagnosis rate of SDAVF is high, and spinal cord DSA should be performed with full intubation. The application of microcatheter angiography can reduce or avoid missed diagnoses and misdiagnoses. When diagnosing SDAVF, it is necessary to differentiate it from acute spinal cord inflammation, spinal intramedullary tumors, SAVM, PMAVF, and type V DAVF. Microsurgical treatment of SDAVF exhibits a good effect and a low recurrence rate. The application of electrophysiological monitoring during microsurgery can facilitate spinal cord surgery and reduce unnecessary spinal cord injury.

### *Limitations*

The study has some limitations. This study was a retrospective analysis, with few cases, and a short follow-up



**Figure 6** Flow diagram of the diagnostic modalities in the current case series. SDAVF, spinal dural arteriovenous fistula; MRI, magnetic resonance imaging; T2WI, T2 weighted image; MRA, magnetic resonance angiography; DSA, digital subtraction angiography; CNS, central nervous system.

time, making it difficult to produce more convincing results. Retrospective analysis of patient clinical data may also lead to under-estimation or overestimation of neurological deficits at presentation. Our innovative application of

the diagnostic process significantly reduces the rate of misdiagnosis, and most patients recover to satisfaction. Prospective comparative studies may be required in the future to understand more efficient diagnostic patterns.

## Acknowledgments

*Funding:* None.

## Footnote

*Reporting Checklist:* The authors have completed the STROBE reporting checklist. Available at <https://atm.amegroups.com/article/view/10.21037/atm-22-3568/rc>

*Data Sharing Statement:* Available at <https://atm.amegroups.com/article/view/10.21037/atm-22-3568/dss>

*Conflicts of Interest:* All authors have completed the ICMJE uniform disclosure form (available at <https://atm.amegroups.com/article/view/10.21037/atm-22-3568/coif>). The authors have no conflicts of interest to declare.

*Ethical Statement:* The authors are accountable for all aspects of the work in ensuring that questions related to the accuracy or integrity of any part of the work are appropriately investigated and resolved. The study was conducted following the Declaration of Helsinki (as revised in 2013). This study was approved by the Ethics Committee of Shanghai Deji Hospital (No. 2016-05). Written informed consent was obtained from all the patients.

*Open Access Statement:* This is an Open Access article distributed in accordance with the Creative Commons Attribution-NonCommercial-NoDerivs 4.0 International License (CC BY-NC-ND 4.0), which permits the non-commercial replication and distribution of the article with the strict proviso that no changes or edits are made and the original work is properly cited (including links to both the formal publication through the relevant DOI and the license). See: <https://creativecommons.org/licenses/by-nc-nd/4.0/>.

## References

- Hetts SW, Mofitakhar P, English JD, et al. Spinal dural arteriovenous fistulas and intrathecal venous drainage: correlation between digital subtraction angiography, magnetic resonance imaging, and clinical findings. *J Neurosurg Spine* 2012;16:433-40.
- Jeng Y, Chen DY, Hsu HL, et al. Spinal Dural Arteriovenous Fistula: Imaging Features and Its Mimics. *Korean J Radiol* 2015;16:1119-31.
- Bakker NA, Uyttenboogaart M, Luijckx GJ, et al. Recurrence Rates After Surgical or Endovascular Treatment of Spinal Dural Arteriovenous Fistulas: A Meta-analysis. *Neurosurgery* 2015;77:137-44; discussion 144.
- Ruiz-Juretschke F, Perez-Calvo JM, Castro E, et al. A single-center, long-term study of spinal dural arteriovenous fistulas with multidisciplinary treatment. *J Clin Neurosci* 2011;18:1662-6.
- Thron A. Spinal dural arteriovenous fistulas. *Radiologe* 2001;41:955-60.
- Clark S, Powell G, Kandasamy J, et al. Spinal dural arteriovenous fistulas--presentation, management and outcome in a single neurosurgical institution. *Br J Neurosurg* 2013;27:465-70.
- Cenzato M, Versari P, Righi C, et al. Spinal dural arteriovenous fistulae: analysis of outcome in relation to pretreatment indicators. *Neurosurgery* 2004;55:815-22; discussion 822-3.
- Özkan N, Kreitschmann-Andermahr I, Goerike SL, et al. Single center experience with treatment of spinal dural arteriovenous fistulas. *Neurosurg Rev* 2015;38:683-92.
- Brinjikji W, Nasr DM, Morris JM, et al. Clinical Outcomes of Patients with Delayed Diagnosis of Spinal Dural Arteriovenous Fistulas. *AJNR Am J Neuroradiol* 2016;37:380-6.
- Iovtchev I, Hiller N, Ofra Y, et al. Late diagnosis of spinal dural arteriovenous fistulas resulting in severe lower-extremity weakness: a case series. *Spine J* 2015;15:e39-44.
- Aminoff MJ, Logue V. Clinical features of spinal vascular malformations. *Brain* 1974;97:197-210.
- Muralidharan R, Mandrekar J, Lanzino G, et al. Prognostic value of clinical and radiological signs in the postoperative outcome of spinal dural arteriovenous fistula. *Spine (Phila Pa 1976)* 2013;38:1188-93.
- Murphy OC, Hedjoudje A, Salazar-Camelo A, et al. Clinical characteristics, misdiagnosis and outcomes of patients with low-flow spinal arteriovenous fistulas. *J Neurol Sci* 2020;413:116863.
- Zhang L, Qiao G, Shang A, et al. Long-term surgical outcomes of patients with delayed diagnosis of spinal dural arteriovenous fistula. *J Clin Neurosci* 2020;77:25-30.
- Morris JM. Imaging of dural arteriovenous fistula. *Radiol Clin North Am* 2012;50:823-39.
- Krings T, Geibprasert S. Spinal dural arteriovenous fistulas. *AJNR Am J Neuroradiol* 2009;30:639-48.
- Mull M, Nijenhuis RJ, Backes WH, et al. Value and limitations of contrast-enhanced MR angiography in spinal arteriovenous malformations and dural

- arteriovenous fistulas. *AJNR Am J Neuroradiol* 2007;28:1249-58.
18. Saindane AM, Boddu SR, Tong FC, et al. Contrast-enhanced time-resolved MRA for pre-angiographic evaluation of suspected spinal dural arterial venous fistulas. *J Neurointerv Surg* 2015;7:135-40.
  19. Atkinson JL, Miller GM, Krauss WE, et al. Clinical and radiographic features of dural arteriovenous fistula, a treatable cause of myelopathy. *Mayo Clin Proc* 2001;76:1120-30.
  20. Marcus J, Schwarz J, Singh IP, et al. Spinal dural arteriovenous fistulas: a review. *Curr Atheroscler Rep* 2013;15:335.
  21. Harel R, Kimchi G, Yaniv G, et al. Surgical Management of Failed Endovascular Treatment for Spinal Dural Arteriovenous Fistulas. *World Neurosurg* 2021;147:e354-62.
  22. Barreras P, Heck D, Greenberg B, et al. Analysis of 30 Spinal Angiograms Falsely Reported as Normal in 18 Patients with Subsequently Documented Spinal Vascular Malformations. *AJNR Am J Neuroradiol* 2017;38:1814-9.
  23. DiSano MA, Cerejo R, Mays M. Acute paraparesis and sensory loss following intravenous corticosteroid administration in a case of longitudinally extensive transverse myelitis caused by spinal dural arteriovenous fistula: case report and review of literature. *Spinal Cord Ser Cases* 2017;3:17025.
  24. Alhendawy I, Homapour B, Chandra RV, et al. Acute paraplegia in patient with spinal dural arteriovenous fistula after lumbar puncture and steroid administration: A case report. *Int J Surg Case Rep* 2021;81:105797.
  25. Nasr DM, Brinjikji W, Rabinstein AA, et al. Clinical outcomes following corticosteroid administration in patients with delayed diagnosis of spinal arteriovenous fistulas. *J Neurointerv Surg* 2017;9:607-10.
  26. Strowd RE, Geer C, Powers A, et al. A unique presentation of a spinal dural arteriovenous fistula exacerbated by steroids. *J Clin Neurosci* 2012;19:466-8.
  27. O'Keeffe DT, Mikhail MA, Lanzino G, et al. Corticosteroid-Induced Paraplegia-A Diagnostic Clue for Spinal Dural Arterial Venous Fistula. *JAMA Neurol* 2015;72:833-4.
  28. Kiwan R, Wade K, Pandey S, et al. Spinal Dural Arteriovenous Fistula with Unusual Tract Enhancement. *Can J Neurol Sci* 2021;48:857-8.
  29. Miranda AM, Rodrigues MG, Araujo A, et al. Teaching NeuroImages: MRI Abnormalities of Spinal Dural Arteriovenous Fistula in the Absence of Flow Voids. *Neurology* 2021. [Epub ahead of print]. pii: 10.1212/WNL.0000000000012053. doi: 10.1212/WNL.0000000000012053.
  30. Cognard C, Gobin YP, Pierot L, et al. Cerebral dural arteriovenous fistulas: clinical and angiographic correlation with a revised classification of venous drainage. *Radiology* 1995;194:671-80.
  31. Sherif C, Gruber A, Bavinski G, et al. Long-term outcome of a multidisciplinary concept of spinal dural arteriovenous fistulae treatment. *Neuroradiology* 2008;50:67-74.
  32. Takai K, Komori T, Taniguchi M. Microvascular anatomy of spinal dural arteriovenous fistulas: arteriovenous connections and their relationships with the dura mater. *J Neurosurg Spine* 2015;23:526-33.
  33. Kirsch M, Berg-Dammer E, Musahl C, et al. Endovascular management of spinal dural arteriovenous fistulas in 78 patients. *Neuroradiology* 2013;55:337-43.
  34. Wojciechowski J, Kunert P, Nowak A, et al. Surgical treatment for spinal dural arteriovenous fistulas: Outcome, complications and prognostic factors. *Neurol Neurochir Pol* 2017;51:446-53.
  35. Wakao N, Imagama S, Ito Z, et al. Clinical outcome of treatments for spinal dural arteriovenous fistulas: results of multivariate analysis and review of the literature. *Spine (Phila Pa 1976)* 2012;37:482-8.
  36. Oh Y, Heo Y, Jeon SR, et al. Microsurgery Versus Endovascular Treatment - Which Is Adequate for Initial Treatment of Spinal Dural Arteriovenous Fistula: A Case Series. *Neurospine* 2021;18:344-54.
  37. Fugate JE, Lanzino G, Rabinstein AA. Clinical presentation and prognostic factors of spinal dural arteriovenous fistulas: an overview. *Neurosurg Focus* 2012;32:E17.
  38. Lee J, Lim YM, Suh DC, et al. Clinical presentation, imaging findings, and prognosis of spinal dural arteriovenous fistula. *J Clin Neurosci* 2016;26:105-9.
  39. Koch MJ, Stapleton CJ, Agarwalla PK, et al. Open and endovascular treatment of spinal dural arteriovenous fistulas: a 10-year experience. *J Neurosurg Spine* 2017;26:519-23.
  40. Schuss P, Daher FH, Greschus S, et al. Surgical Treatment of Spinal Dural Arteriovenous Fistula: Management and Long-Term Outcome in a Single-Center Series. *World Neurosurg* 2015;83:1002-5.
  41. Steinmetz MP, Chow MM, Krishnaney AA, et al. Outcome after the treatment of spinal dural arteriovenous fistulae: a contemporary single-institution series and meta-analysis.

- Neurosurgery 2004;55:77-87; discussion 87-8.
42. Jin SH, Chung CK, Kim CH, et al. Multimodal intraoperative monitoring during intramedullary spinal cord tumor surgery. *Acta Neurochir (Wien)* 2015;157:2149-55.
  43. Maslehaty H, Barth H, Petridis AK, et al. Symptomatic spinal cavernous malformations: indication for microsurgical treatment and outcome. *Eur Spine J* 2011;20:1765-70.
  44. Kothbauer KF. Intraoperative neurophysiologic monitoring for intramedullary spinal-cord tumor surgery. *Neurophysiol Clin* 2007;37:407-14.
  45. Hyun SJ, Rhim SC. Combined motor and somatosensory evoked potential monitoring for intramedullary spinal cord tumor surgery: correlation of clinical and neurophysiological data in 17 consecutive procedures. *Br J Neurosurg* 2009;23:393-400.
  46. Luo M, Li J, Wu C, et al. Prognostic factors in patients with spinal dural arteriovenous fistulas treated surgically. *Clin Neurol Neurosurg* 2021;207:106740.
  47. Vukić M, Barić H, Ozretić D, et al. Spinal dural arteriovenous fistulas: a report on outcomes in a single-center retrospective cohort treated surgically and/or endovascularly. *Croat Med J* 2021;62:347-52.
  48. Yang C, Ma Y, Tian A, et al. Long-term outcomes and prognostic factors in patients with treated spinal dural arteriovenous fistulas: a prospective cohort study. *BMJ Open* 2022;12:e047390.
  49. Cecchi PC, Musumeci A, Faccioli F, et al. Surgical treatment of spinal dural arterio-venous fistulae: long-term results and analysis of prognostic factors. *Acta Neurochir (Wien)* 2008;150:563-70.

**Cite this article as:** Zhang HB, Zhai XL, Li L, Wu DS, Zhuang GL, Xu QW, Guo H, Wang J. Imaging characteristics, misdiagnosis and microsurgical outcomes of patients with spinal dural arteriovenous fistula: a retrospective study of 32 patients. *Ann Transl Med* 2022;10(15):832. doi: 10.21037/atm-22-3568