



Since January 2020 Elsevier has created a COVID-19 resource centre with free information in English and Mandarin on the novel coronavirus COVID-19. The COVID-19 resource centre is hosted on Elsevier Connect, the company's public news and information website.

Elsevier hereby grants permission to make all its COVID-19-related research that is available on the COVID-19 resource centre - including this research content - immediately available in PubMed Central and other publicly funded repositories, such as the WHO COVID database with rights for unrestricted research re-use and analyses in any form or by any means with acknowledgement of the original source. These permissions are granted for free by Elsevier for as long as the COVID-19 resource centre remains active.



Case report

Atypical presentations of fungal osteomyelitis during post COVID-19 outbreak – Case series



Ankita Chugh^a, Akhilesh Kumar Pandey^{a,*}, Amit Goyal^b, Kapil Soni^b, Vidhi Jain^c, Balamurugan Thirunavukkarasu^d, Deepak Vedant^d, Deepak Kumar^e, Pravin Kumar^f

^a Department of Dentistry, Oral and Maxillofacial Surgery, All India Institute of Medical Sciences, Jodhpur, India

^b Department of Otorhinolaryngology, All India Institute of Medical Sciences, Jodhpur, India

^c Department of Microbiology, All India Institute of Medical Sciences, Jodhpur, India

^d Department of Pathology and Lab Medicine, All India Institute of Medical Sciences, Jodhpur, India

^e Department of General Medicine, All India Institute of Medical Sciences, Jodhpur, India

^f Department of Dentistry, Endodontics, All India Institute of Medical Sciences, Jodhpur, India

ARTICLE INFO

Key words:

Fungal osteomyelitis
Mucormycosis
Aspergillosis
COVID-19
Antifungal therapy

ABSTRACT

Introduction: Mucormycosis and Aspergillosis are opportunistic fungal infections causing significant morbidity and mortality. Post the outbreak of COVID-19, these fungal osteomyelitis have seen a global rise with few atypical presentations noted.

Case report: Current case series reports three such atypical presentations of fungal osteomyelitis including mandibular fungal osteomyelitis in two patients, fungal osteomyelitis mimicking space infection in a middle aged male, and suspected mixed fungal osteomyelitis involving maxillary sinus. Aggressive surgical debridement was indicated along with institution of antifungal therapy (Liposomal Amphotericin B, and Posaconazole). The fungal osteomyelitis was successfully treated with surgical and medical management with no recurrence.

Discussion: The injudicious use of corticosteroids in COVID-19 patients along with their immunocompromised status increases their susceptibility to opportunistic fungal osteomyelitis. Prompt and aggressive surgical intervention along with antifungal therapy is important after diagnosing fungal osteomyelitis, as a delay could increase the mortality rate considerably.

1. Introduction

The outbreak of the global pandemic COVID-19 since March 2020 has engendered breeding grounds for many opportunistic bacterial and fungal infections such as Mucormycosis and Aspergillosis. Mucormycosis is caused by an ubiquitous fungal pathogen which belongs to the phylum Zygomycota, family Mucoraceae, with *Rhizopus* being the most common genera. Paltauf in 1885 first documented the case of upper airway mucormycosis [1]. This aggressive saprophytic fungal infection, aptly described as a ‘phoenix’ has been on a global rise since the pandemic began [2,3]. The prevalence of the coronavirus associated mucormycosis (CAM) was 0.27% among the hospitalized COVID-19 patients, and by July 2021 the CAM cases reached around 40,000 in India [4].

Having a male predisposition (78.9%), mucormycosis commonly

involves the nose and sinuses (88.9%) followed by rhino-orbital involvement (56.7%) and then rhino-orbito-cerebral (22.2%) with a significant rise in mortality rates in these cases. The mucorales gain access to the nose and paranasal sinuses via inhaled spores, causing high morbidity and mortality and in absence of prompt and urgent intervention. They gain access to the cavernous sinus through retrograde infection, and the brain parenchyma through cribriform plate, orbital apex or orbital vessels [5].

Metabolic states such as diabetes mellitus and diabetic ketoacidosis (DKA) lead to an hypoxic acidic environment which is the key necessity for mucorales spread, owing to the presence of ketone reductase enzymes, which makes such acidic environment suitable for their growth. (or helps them thrive in such acidic environment). The rampant use of corticosteroids to combat COVID-19 infection, has significantly contributed to the prevailing immunosuppression (neutropenia) found in

* Correspondence to: Department of Dentistry, Oral and Maxillofacial Surgery, OPD Block, 2A, All India Institute of Medical Sciences, Jodhpur, Rajasthan 342008, India.

E-mail address: akhileshkp31@gmail.com (AK. Pandey).

<https://doi.org/10.1016/j.ajoms.2022.03.007>

Received 4 January 2022; Received in revised form 6 March 2022; Accepted 11 March 2022

Available online 04 April 2022

2212-5558/© 2022Asian AOMS, ASOMP, JSOP, JSOMS, JSOM, and JAMI. Published by Elsevier Ltd. All rights reserved. All rights reserved.

these patients. Factors such as long term hospitalization, prolonged invasive or non-invasive ventilation due to hypoxia, poor hygiene status (prolonged wearing of old unclean mask), hematological malignancies, solid organ or haematopoietic cell transplantation, chemotherapeutic drugs and iron chelating agents such as deferoxamine [6], have surfaced as the highest risk association with mucormycosis.

Treatment involves aggressive surgical debridement along with concomitant antifungal therapy like Liposomal Amphotericin B and Posaconazole.

Despite the Rhino-sino-orbital being the most common involvement reported in literature, and seen in clinical practice as well, a few atypical locations have recently emerged amidst COVID 19 pandemic. Here we report three such atypical presentations of mucormycosis.

2. Case report

Patient's data was reviewed and collected from the Electronic Medical Record system. From May 2021 to June 2021, four patients diagnosed with atypical mucormycosis reported to All India Institute of Medical Sciences, Jodhpur. Records of all these patients were collected and analyzed clinically and radiologically. We herein report those individual cases' presentation and treatment procedures.

Case 1 & 2. – Mandibular fungal osteomyelitis.

A 64 old male reported to the department of tertiary care hospital with pain in relation to (i.r.t) lower right back tooth region since 1 month with numbness in relation to lower lip right side not crossing midline. The patient was admitted in ICU after contracting COVID-19 infection 2 months prior when he had difficulty in breathing and his SpO2 dropped down below 85%. The patient was put on NIV and administered steroids for the same for 21 days. He reported to the OMFS department with dentoalveolar abscess associated with 44,45,46,47; and recently diagnosed diabetes mellitus. The patient gave history of cardiac stent placement in 2019 and was under antiplatelet dugs (tablet Rosulip gold 75/20), also the patient was under medications for hypertension (tablet Telma 40 mg) and hypothyroidism (tablet Thyroxine 50 mcg). A screening orthopantomogram (OPG) was done, which was not suggestive of obvious bony changes. Extraction was done under local anesthesia and patient was advised peroral antibiotics and analgesics. However due to persistent pain in alveolus and numbness in lower lip the patient reported back to department after 2 weeks, and a CT scan was done which was suggestive of osteomyelitis of the mandible (Figs. 1,2). On admission the Hb was 11.9 g/dl, WBC 11,250/ul, Procalcitonin A < 0.1 ng/ml, and HbA1c 6.7%.

2.1. Treatment

Debridement of necrotic alveolus and soft tissue in relation to 44,45,46,47 was done along with preservation of mental nerve and inferior alveolar nerve under general anesthesia, and iodoform pack was placed in the posterior alveolus. The bone specimen was sent for KOH mount and histopathological evaluation, which confirmed the presence of broad aseptate hyaline ribbon like right angled branching fungal hyphae in relation to right lower posterior alveolus. The patient was started on injection liposomal amphotericin B 200 mg in 500 ml D5 with 6 units HIR OD and discharged on syrup posaconazole loading dose of 300 mg BD followed by 300 mg OD; and tablet Neurobion forte OD.

Another 35-year-old male reported to emergency room of tertiary care hospital with pain in lower back tooth region since 1 month. Pain was moderate in intensity, continuous in nature, radiating to neck region. Mild extraoral tenderness was present on left body of mandible region, along with subjective paresthesia over left side lower lip region. Intraoral examination revealed sinus on buccal gingiva i.r.t left mandible region with active pus discharge. 35,36,37 teeth were grade II mobile.

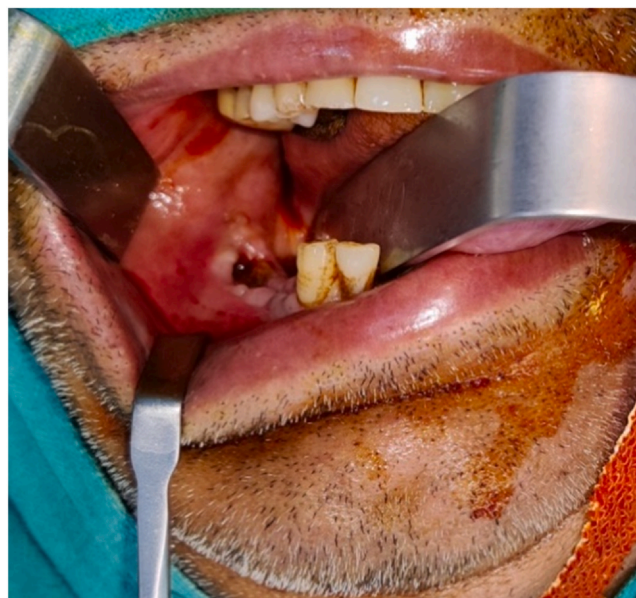

Fig. 1. Fungal osteomyelitis in relation to right lower posterior alveolus.

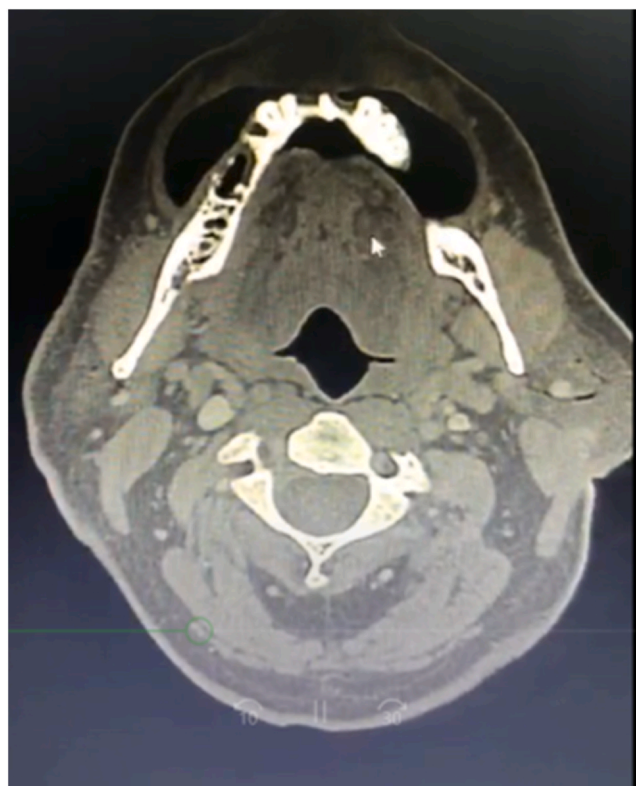


Fig. 2. Axial section of contrast enhanced computed tomography scan showing osteomyelitis of right hemi mandible.

The patient had no associated comorbidities, however the patient was COVID-19 positive 2 months back and was started on tablet Dexamethasone for 15 days and Prednisolone for 3 days. CT Scan revealed cortical thinning and erosions of left lower alveolar processes of mandible with soft tissue thickening in left bucco-masseteric space.

Patient presented with Hb 14.5 g/dl, WBC 11,730/ul, AST 65.5IU/L, ALT 95.9 IU/L.

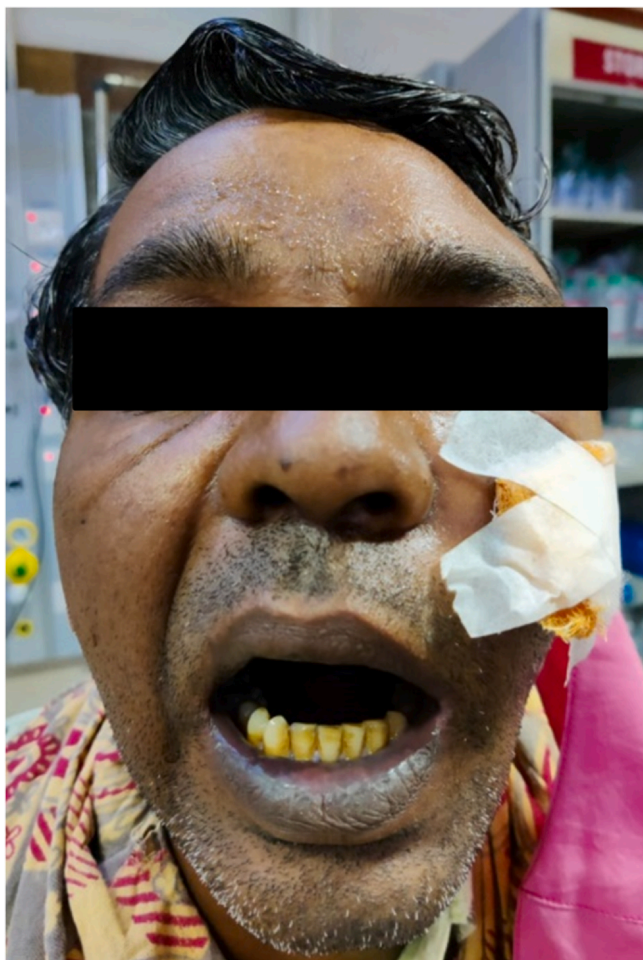

Fig. 3. Left temporal and canine space infection.

2.2. Treatment

Extraction of 35,36,37,38 and debridement of necrotic bone and infected soft tissue was done along with preservation of mental, and inferior alveolar nerve under general anesthesia. Healthy bony margins were visualized, after achieving hemostasis iodoform pack was placed and closure done with 4–0 vicryl sutures. The bone specimen was sent for KOH mount and histopathological evaluation, which confirmed the presence of fungal osteomyelitis in relation to left lower posterior alveolus. The patient was started on loading dose of Posaconazole 300 mg BD followed by 300 mg OD, as injection liposomal amphotericin B was not available.

Case 3. – Fungal osteomyelitis mimicking space infection.

A 35 year old male reported to emergency room of tertiary care hospital with pain and swelling over left temporal and periorbital region (Fig. 3.). Active pus drainage was associated with extraoral incision over the infraorbital region which was given elsewhere and he was prescribed antibiotics and analgesics. The patient had no comorbidities, negative COVID19 history. CECT, MRI face and neck was done, abscess measuring 3.3 × 1 × 1.7 cm was seen overlying left maxillary sinus with mild cortical erosion and left maxillary sinusitis (Fig. 4.); another collection was seen ~3 × 1.4 × 3.3 cm with surrounding soft tissue thickening i.r.t left infra-temporal fossa. Ipsilateral soft tissue swelling was seen i.r.t periorbital region. On admission Procalcitonin 0.0680 ng/ml, HbA1c 13.4%, ESR 56 mm/1 h, HsCRP 2.29 mg/L.

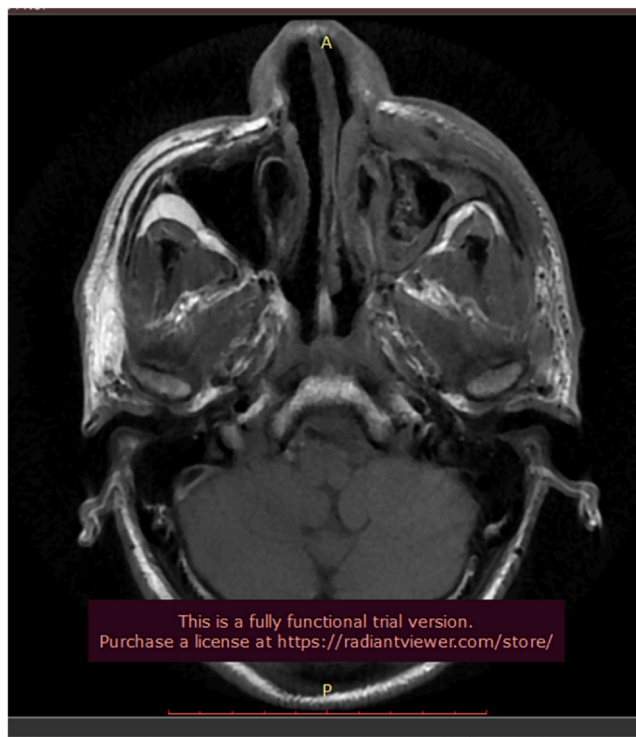


Fig. 4. Axial section of magnetic resonance imaging showing fungal osteomyelitis of left maxillary sinus.

2.3. Treatment

The patient was started on antibiotics based on the pus culture and sensitivity report. Incision and drainage was done i.r.t left superficial and deep temporal spaces, and infraorbital region; and 15 cc pus was drained. Pus drained from temporal space was positive for fungal culture. Debridement of left maxillary sinus was done via Caldwell-luc approach (Fig. 5). The maxillary sinus lining sent for histopathological analysis (Fig. 6. A,B) and KOH mount confirmed the presence of mucormycosis infection (Fig. 7). Patient was started on Injection Liposomal Amphotericin B 200 mg in 500 ml D5 with 6 HIR and discharged on Posaconazole.

Case 4. – Suspected mixed fungal osteomyelitis.

A 35 year old male reported to emergency room of tertiary care hospital with pain in upper left back teeth region since 1 month. Multiple sinuses with pus discharge was associated with maxillary left labial gingiva, along with mobility of dentoalveolar complex (Fig. 8.). The patient had no comorbidities, positive COVID19 history along with

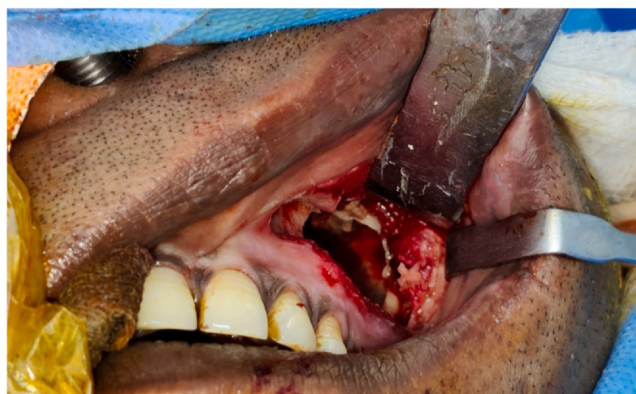

Fig. 5. Debridement of left maxillary sinus via Caldwell-luc approach.

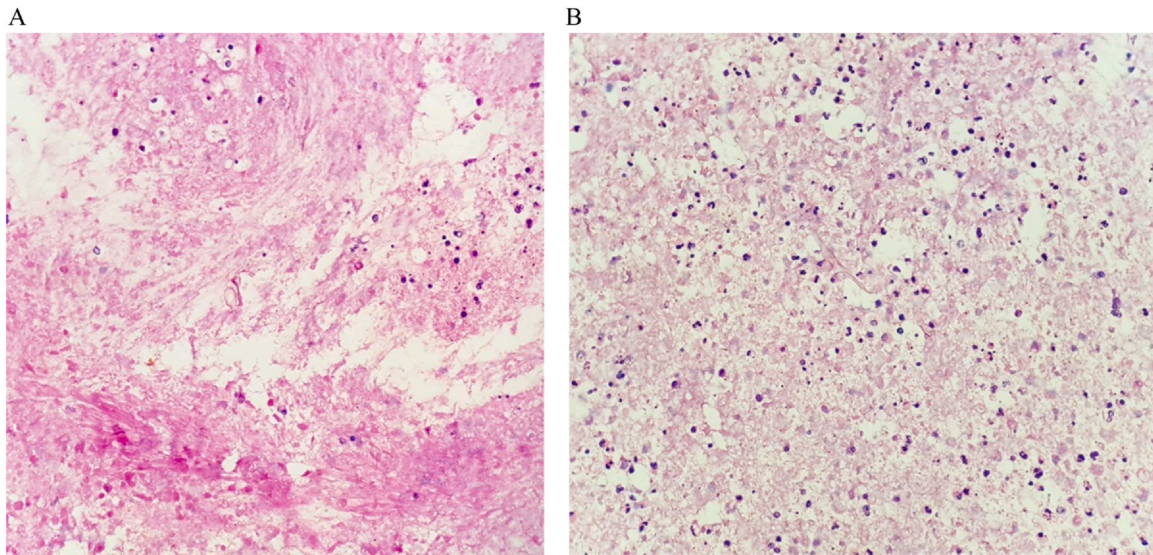


Fig. 6. (A),(B). H&E stained images are at 40x magnification and show aseptate, foldable ribbon like fungal hyphae with right angle branching in a necrotic background.

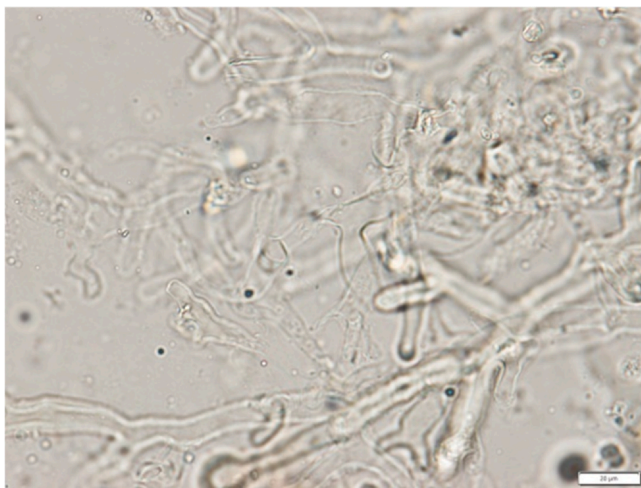


Fig. 7. 20% KOH mount showing few broad, hyaline aseptate hyphae with right angled branching.

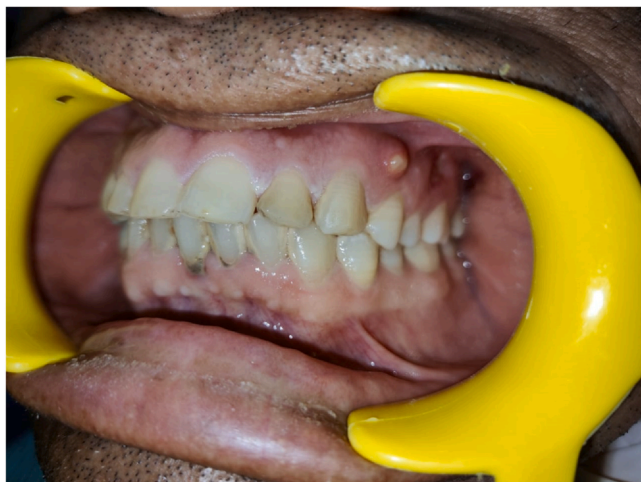

Fig. 8. Multiple sinus present irt maxillary left gingiva with pus discharge.

steroid use. CECT demonstrated mucosal thickening in left maxillary sinus with extension in retroantral space suggestive of invasive

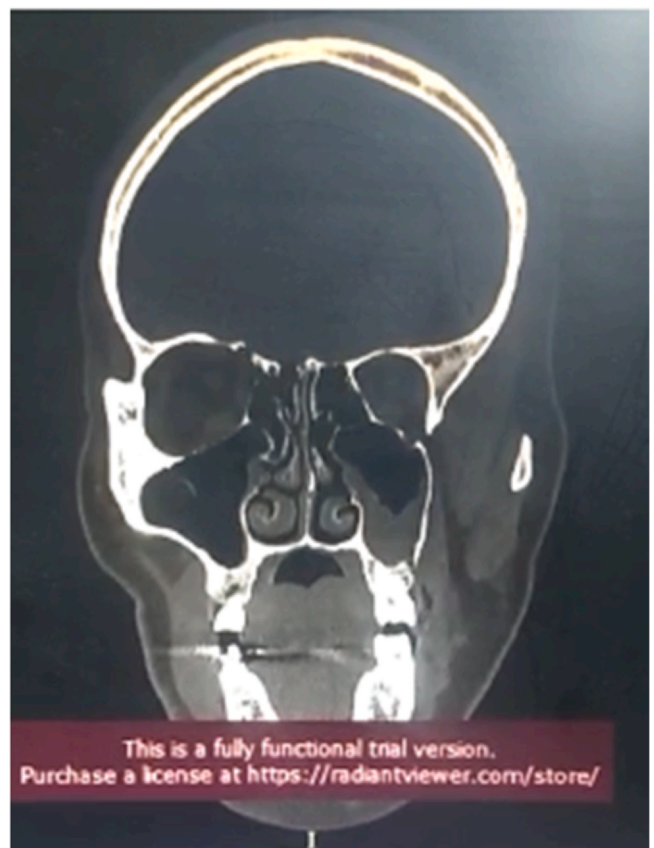


Fig. 9. Coronal section of contrast enhanced computed tomography scan showing mucosal thickening in left maxillary sinus and extension in retroantral space.

mucormycosis (Fig. 9.).

The patient presented with D-Dimer 1.16Ug/ml, ESR 56 mm/Hr, Hs CRP 26.26 mg/L, HbA1c 5.8%.

2.4. Treatment

Debridement of left maxillary sinus with extraction of involved teeth and alveolectomy with necrosed palate was removed. Maxillary sinus

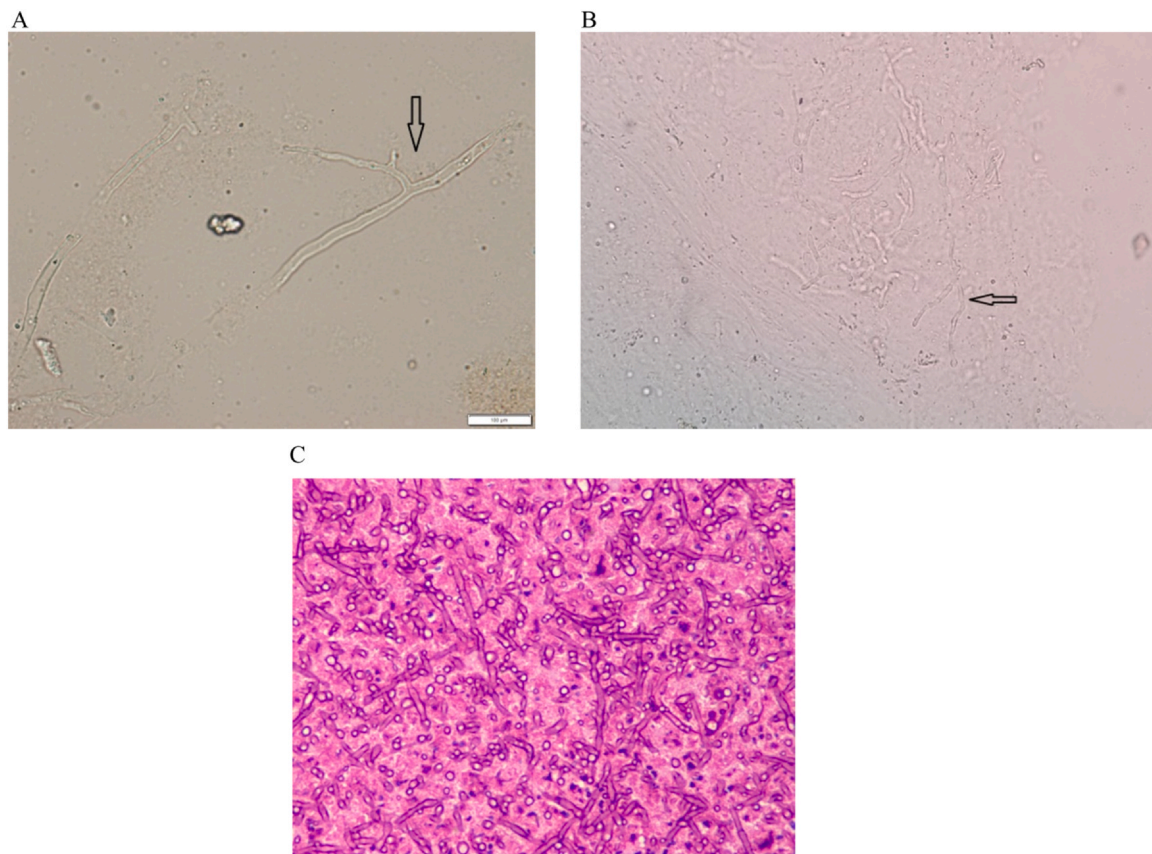


Fig. 10. 20% KOH mount showing (A). Broad hyaline aseptate right-angle branched fungal hyphae confirming to morphology of *Mucor* (400x magnification) (B). Thin hyaline septate acute-angle branched fungal hyphae confirming morphology of *Aspergillus* (400x magnification) (C). Septate, acute angle branching hyphae conforming to morphology of *Aspergillus* sp. (400x).

on right side was debrided via Caldwell-Luc approach. Despite surgery patient had persistent fever and all other causes of fever were ruled out after work up. The initial biopsy from lining of right maxillary sinus showed both broad and thin hyphae, raising the possibility of mixed mucor and aspergillus infection on both histopathology and KOH wet mount (Fig. 10. A,B,C). However, intra-operative specimens clearly revealed only broad hyphae, suggestive of mucormycosis as the true invasive pathogen. Post debridement the patient was started on injection liposomal amphotericin B 200 mg and tablet posaconazole 300 mg OD, to which he responded well.

3. Discussion

The ongoing pandemic COVID-19 has led to the upsurge of the previously less prevalent opportunistic fungal infection- mucormycosis. It has caught the focus of attention as being a super infection in immunocompromised and debilitated patients, who have either recovered from or are still suffering from COVID-19 infection [7]. However, strangely there are a few reported fungal osteomyelitis cases who never had proven COVID-19 or any hospitalization.

The fungal infection most commonly involves the nose and paranasal sinuses, which may extend to intracranial involvement, if not treated promptly. Based on the system it involves, it is classified as: Rhinocerebral Mucormycosis (RCM), Cutaneous, Pulmonary, Gastrointestinal, Renal, and Hepatic Mucormycosis [8]. The sinuses (39%), pulmonary (24%), disseminated (23%), skin and soft tissue infection (19%) are the most prevalent sites of mucormycosis infections in India [9]. The classical signs and symptoms of RCM as described by Smith and Krichner (1950) include [10]: soft peri-nasal or peri-orbital swelling with discoloration and induration, ptosis of the eyeball and complete ophthalmoplegia, black necrotic turbinates, blood-tinged

nasal discharge and ipsilateral facial pain, and multiple cranial nerve palsies [11]. The Mucorales spores show a remarkable ability of angioinvasion [12] and hematogenous dissemination, which leads to thrombosis, ischemic infarction of blood vessels and necrosis of the involved tissues. Aspergillosis on the other hand cause tissue necrosis due to action of inflammatory cells recruited to the affected sites.

Diagnosis of mucormycosis and aspergillosis is achieved based on the clinical features, DNE (diagnostic nasal endoscopy) radiology (CE-MRI/CECT) [13], histopathological and microbiological analysis. The bacterial and fungal osteomyelitis don't differ in their radiology (CE-MRI/CECT) imaging findings; however according to a study by Deeksha Bhalla et al., the bacterial skull base osteomyelitis (SBO) presents with bone erosion in the later stage along with lesser extent of bony erosion compared to fungal SBO [14]. Other advanced aids include Immunohistochemistry, In-situ hybridization, Polymerase chain reaction (PCR) based molecular identification of DNA sequencing based on bar codes 18S, ITS, 28S, rDNA, MALDI-TOF [15]. Further investigations for aspergillosis includes detection of galactomannan, beta-D-glucan.

Even the slightest suspicion of mucormycosis warrants immediate evaluation and intervention, as the fatality rate is seen as high as 90% in intracranial involvement [16] and a delay of 3–6 days in initiating aggressive intervention could raise the thirty days mortality rate from 35% to 66% [17]. After establishing the aforesaid diagnosis, aggressive surgical debridement should commence along with the administration of first line Antifungals [18] viz. Injection Liposomal Amphotericin B (5 mg/kg/day), if Amphotericin B is contraindicated, Posaconazole IV as induction therapy [10] (300 mg BD loading dose at day 1 followed by 300 mg OD) or Posaconazole oral as step down therapy (300 mg BD loading dose at day 1 followed by 300 mg OD) and Voriconazole (6 mg/kg q 12 hr on day 1 followed by 4 mg/kg q12hr from day 2) for aspergillosis till clinical/radiological resolution of the disease. According

to Code Mucor, Posaconazole oral is used as step down therapy for 3–6 months[4]. It's safety and efficacy was studied in Rhino-orbito-cerebral Mucormycosis patients of South India, the study reported no morbidity and disease clearance in about 66.6% of patients [9].

In the literature only 15 cases of isolated mandibular mucormycosis have been documented[19]. The portal of entry for mandibular fungal osteomyelitis could be post extraction or ulceration which leads to inoculation of the infection in the soft tissue followed by bone in the immunocompromised patients. These lead to rapid tissue necrosis and osteomyelitis in mandible because of angioinvasive nature of the fungus. However in both our cases the lesions were denovo as there was no evidence of localized surgical trauma. Mucormycosis exhibit high mortality depending upon the stage of presentation and the underlying immune status, however the fungal infection involving the mandible presents with better prognosis because of poor dissemination of the disease[19,20].

The second case presented with active pus discharge which did not subside with incision and drainage. Except maxillary sinus mucosal thickening other classic signs of maxillary mucormycosis like other sinus involvement were missing. None of the teeth or alveolus exhibited any pain, mobility or draining sinus. The persistent pus discharge even after initiating drainage along with aggressive antibiotic therapy and fever lead to suspicion of fungal osteomyelitis. His total leucocyte counts, Procalcitonin were within normal range. Antifungal therapy was initiated even though confirmed histopathological and culture report for fungus was delayed, leading to better clinical recovery of the patient.

Concomitant mixed fungal infection involving mucormycosis and aspergillosis is rare, invasive and associated with high mortality rate. In the literature review by Chermetz et al., out of 51 reported concomitant mucormycosis and aspergillosis infection, only 9 had sino-orbito-oral involvement, and the rest 42 had systemic involvement (predominantly cutaneous and pulmonary). In our setup also out of 48 patients admitted during this outbreak three had suspected mixed mucormycosis and aspergillosis species isolated from sinus mucosa specimens, without frank systemic involvement which was ruled out by CT thorax and abdomen. Suspected mixed fungal infections should always be correlated clinically and through additional tests (especially galactomannan antigen positivity). Microscopic visualization of two or more fungi on sinus mucosa may be a result of surface colonization. True invasive pathogens must be confirmed by consistent visualization on direct microscopy and fungal culture, both from sinuses as well as from deep tissue (intra-operative) biopsies. The usual route of dissemination involves inhalation of spores, invasion through extraction socket wounds, or breached cutaneous surfaces. The mortality rate of aspergillosis is 30% even after instituting antifungal therapy, and is as high as 85% in pediatric immunocompromised patients[21]. In developing country like ours this sudden outbreak was faced with scarcity of adequate antifungal therapy. Amphotericin which is advocated as the first line therapy could not be administered to all patients or in adequate doses. Prioritization for amphotericin based on extent of involvement of the disease was followed. Amphotericin was reserved for intracranial, orbital extension or mixed invasive fungal infection. Posaconazole which a second line therapy was used commonly in less extensive cases due to its better availability. Early surgical management was considered the best method to improve prognosis in this situation of lack of logistic issues with pharmacotherapy dependence. However to our surprise even Posaconazole along with adequate surgical debridement controlled the disease considerably well.

In the present case series we have documented three atypical presentations of mucormycosis, mandibular fungal osteomyelitis, fungal osteomyelitis mimicking space infection, and suspected mixed fungal osteomyelitis.

All these cases are rare presentations, and very little literature evidence has been documented so far.

Funding

No funding was received for this study.

Ethical approval

Not required.

Patient consent

Written patient consent was obtained to publish the clinical photographs.

Declaration of Competing Interest

The authors report no declarations of interest.

Acknowledgements

We acknowledge the Department of Otorhinolaryngology, Microbiology, Pathology and Lab Medicine, and General Medicine.

References

- [1] Manjunatha BS, Das N, Sutariya RV, Ahmed T. Mucormycosis of the hard palate masquerading as carcinoma. *Clin Pract* 2012;2:e28.
- [2] Singh Awadhesh Kumar, Singh Ritu, Joshi Shashank R, Misra Anoop. Mucormycosis in COVID-19: a systematic review of cases reported worldwide and in India. *Diabetes Meta Syndr* 2021;15:102146.
- [3] Wael M, Said Ahmed Amira M, Elsherbini Nehal M, Elsherbiny Mohamed, El-Sherbiny Nevine I, Ramzy. Maxillary Mucormycosis Osteomyelitis In Post COVID-19 Patients: A Series of Fourteen Cases. *Diagnostics (Basel)* 11. 2021. p. 2050.
- [4] Aranjani Jesil Mathew, Manuel Atulya, Razack Habeeb Ibrahim Abdul, Mathew Sam T. COVID-19-associated mucormycosis: Evidence-based critical review of an emerging infection burden during the pandemic's second wave in India. *PLoS Negl Trop Dis* 2021;15:e0009921.
- [5] Maini A, Tomar G, Khanna D, Kini Y, Mehta H, Bhagyashree V. Sino-orbital mucormycosis in a COVID-19 patient: a case report. *Int J Surg Case Rep* 2021;82:105957.
- [6] Boelaert Johan R, de Locht Marielle, Van Cutsem Jan, Kerrels Veronique, Cantinieaux Brigitte, Verdonck Ann, et al. Mucormycosis during deferoxamine therapy is a siderophore-mediated infection: in vitro and in vivo animal studies. *J Clin Invest* 1993;91:1979–86.
- [7] Skiada A, Pavleas I, Drogari-Apiranthitou M. Epidemiology and diagnosis of mucormycosis: an update. *J Fungi (Basel)* 2020;6:265.
- [8] Spellberg B, Edwards J, Ibrahim A. Novel perspectives on mucormycosis: pathophysiology, presentation, and management. *Clin Microbiol Rev* 2005;18:556–69.
- [9] Fathima AS, Lakshmi Mounika Vakada, Udaya Kumar V, Kumar Gupta Ashok, Garapati Pavan, Ravichandiran V, et al. Mucormycosis: a triple burden in patients with diabetes during COVID-19 pandemic. *Health Sci Rev (Oxf)* 2021:1.
- [10] Smith HW, Kirchner JA. Cerebral mucormycosis; a report of three cases. *AMA Arch Otolaryngol* 1958;68:715–26.
- [11] Honavar SG. Code mucor: guidelines for the diagnosis, staging and management of rhino-orbito-cerebral mucormycosis in the setting of COVID-19. *Indian J Ophthalmol* 2021;69:1361–5.
- [12] Baldin C, Ibrahim AS. Molecular mechanisms of mucormycosis- the bitter and the sweet. *PLoS Pathog* 2017;13:e1006408.
- [13] Therakathu J, Prabhu S, Irodi A, Sudhakar SV, Yadav VK, Rupa V. Imaging features of rhinocerebral mucormycosis: a study of 43 patients. *Egypt J Radiol Nucl Med* 2018;49:447–52.
- [14] Bhalla Deeksha, Bhalla Ashu S, Manchanda Smita. Can imaging suggest the aetiology in skull base osteomyelitis? A systematic literature review. *Pol J Radio* 2021;86:e309–21.
- [15] Gupta S, Goyal R, Kaore NM. Rhino-orbital-cerebral mucormycosis: battle with the deadly enemy. *Indian J Otolaryngol Head Neck Surg* 2020;72:104–11.
- [16] Deutsch PG, Whittaker J, Prasad S. Invasive and non-invasive fungal rhinosinusitis—a review and update of the evidence. *Medicina (Kaunas)* 2019:55.
- [17] Werthman-Ehrenreich A. Mucormycosis with orbital compartment syndrome in a patient with COVID-19. *Am J Emerg Med* 2021;42(264):e5–264. e8.
- [18] Rawson Timothy M, Moore Luke SP, Zhu Nina, Ranganathan Nishanthi, Skolimowska Keira, Gilchrist Mark, et al. Bacterial and fungal coinfection in individuals with coronavirus: a rapid review to support COVID-19 antimicrobial prescribing. *Clin Infect Dis* 2020;71:2459–68.
- [19] Agarwala Shubham, Ananda Abhishek, Ranjana Piyush, Meena Ved Prakash, Raya Animesh, Dutta Rimlee, et al. Case of mucormycosis of mandible after self-extraction of teeth incidentally detected to have chronic granulomatous disease: case report and literature review. *Med Mycol Case Rep* 2020;28:55–9.
- [20] Aras MH, Kara MI, Erkişç S, Ay S. Mandibular mucormycosis in immunocompromised patients: report of 2 cases and review of the literature. *J Oral Maxillofac Surg* 2012;70:1362–8.
- [21] Chermetz Maddalena, Gobbo Margherita, Rupel Katia, Ottaviani Giulia, Tirelli Giancarlo, Bussani Rossana, et al. Combined orofacial aspergillosis and mucormycosis: fatal complication of a recurrent paediatric glioma—case report and review of literature. *Mycopathologia* 2016;181:723–33.