



Case Report

Skull base osteomyelitis by *Pandoraea apista*: An unusual pathogen at unusual location – A case report

Ninad Ramesh Patil¹, Manjul Tripathi¹, Kshitij Charaya², Archana Angrup³, Chirag Ahuja⁴, Sandeep Mohindra¹

¹Department of Neurosurgery, Postgraduate Institute of Medical Education and Research, Chandigarh, ²Department of Otorhinolaryngology, Indus Hospital, Sahibzada Ajit Singh Nagar, Punjab, ³Department of Medical Microbiology, Postgraduate Institute of Medical Education and Research, Chandigarh, ⁴Department of Neuroradiodiagnosis, Postgraduate Institute of Medical Education and Research, Chandigarh, India.

E-mail: Ninad Ramesh Patil - drninadpatil05@gmail.com; *Manjul Tripathi - drmanjultripathi@gmail.com; Kshitij Charaya - isurgeon@live.com; Archana Angrup - archanaangrup@yahoo.com; Chirag Ahuja - chiragahuja@rediffmail.com; Sandeep Mohindra - sandeepneuro@gmail.com



*Corresponding author:

Manjul Tripathi,
Department of Neurosurgery,
Postgraduate Institute of
Medical Education and
Research, Chandigarh, India.

drmanjultripathi@gmail.com

Received : 12 May 2021

Accepted : 12 July 2021

Published : 06 September 2021

DOI

10.25259/SNI_472_2021

Quick Response Code:



ABSTRACT

Background: *Pandoraea apista* is predominantly recovered from the respiratory tract of patients with cystic fibrosis (CF). Authors report first case of central nervous system infection by *P. apista* in the form of skull base osteomyelitis.

Case Description: A 67-year-old male presented with complaints of earache and hearing deficit for few months. The radiology was suggestive of skull base osteomyelitis and polypoidal soft tissue extending from the middle cranial fossa to the infratemporal fossa. The sample from the targeted area revealed *P. apista* on matrix-assisted laser desorption ionization-time-of-flight mass spectrometry. With adequate antibiotic therapy, there was clinicoradiologic improvement. *P. apista* is an infection exclusively seen in pulmonary infection in patients with CF. We identified its intracranial involvement in a patient for the 1st time in the literature. The serendipitous diagnosis needs evaluation on specific PCR and matrix-assisted laser desorption spectrometry. The treatment with antibiotics provides a definite cure.

Conclusion: We report a rare opportunistic infection with central nervous system involvement which can be cured by accurate diagnosis and appropriate antibiotic treatment.

Keywords: Cystic fibrosis, Infection, Matrix-assisted laser desorption ionization-time-of-flight mass spectrometry, *Pandoraea apista*, PCR

INTRODUCTION

Pandoraea genus is a relatively new genus first described by Coenye *et al.* in 2000. The name *Pandoraea* was given to this genus to refer to Pandora's box (from Greek mythology which was considered as the origin of diseases to the mankind), because of surprising diversity amongst the members of this genus.^[3,6] The authors report first ever case of *Pandoraea* pathogen with a central nervous system involvement.

CASE REPORT

A 67-year-old male presented with complaint of severe pain in the left ear along with decreased hearing for few months. Examination revealed a bulge in the external auditory canal making the

This is an open-access article distributed under the terms of the Creative Commons Attribution-Non Commercial-Share Alike 4.0 License, which allows others to remix, tweak, and build upon the work non-commercially, as long as the author is credited and the new creations are licensed under the identical terms.

©2021 Published by Scientific Scholar on behalf of Surgical Neurology International

tympenic membrane visualization impossible. The patient had nonserviceable conductive and sensorineural hearing loss in the left ear. His systemic and other neurological examination was nonremarkable. CT scan revealed poorly defined heterogeneous enhancing soft-tissue mass involving external auditory canal, pterygoid space, masticator space, nasopharynx, and infratemporal fossa. CT scan of skull base revealed polypoidal soft tissue occluding the left external auditory canal [Figure 1a] having contiguous extension inferiorly and medially along nasopharynx and infratemporal fossa. The muscles of mastication showed heterogeneous enhancement with diffuse increase in bulk [Figure 1b]. There was associated erosion of the bones forming the base of skull [Figure 1c and d].

The positron emission tomography scan neither revealed any other pathology nor showed any metabolic activity. Considering clinical and radiologic considerations, the possibilities of skull base osteomyelitis or a neoplastic lesion were considered. Biopsy from nasopharynx was inconclusive while CT-guided FNAC from skull base was sent for bacterial culture. The sample was inoculated on blood agar and MacConkey agar and incubated at 37°C overnight under aerobic conditions as a part of routine processing for aerobic isolates. The culture revealed monomicrobial growth of a nonlactose fermenting colony on MacConkey agar which was identified as *Pandoraea apista* on matrix-assisted laser desorption ionization-time-of-flight mass spectrometry (MALDI-TOF, MS, Bruker Daltonik GmbH, Germany)

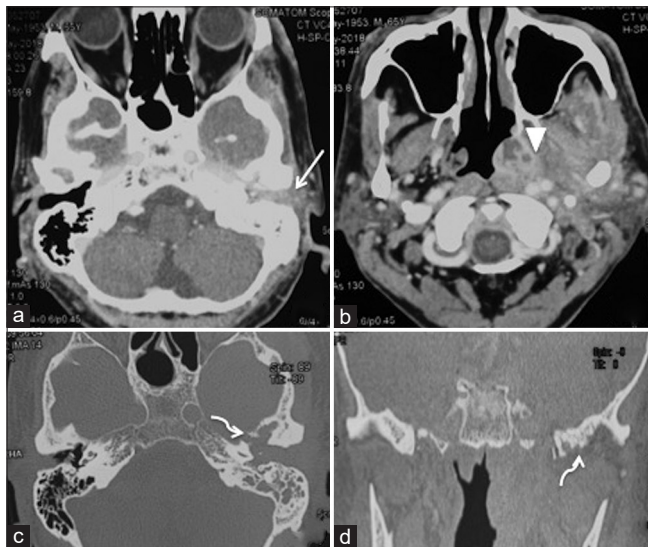


Figure 1: Contrast-enhanced CT scan axial soft-tissue window (a and b), axial (c) and coronal bone window (d) sections revealing polypoidal soft tissue occluding the external auditory meatus (arrow) with increased bulk and heterogeneous enhancement (arrowhead) of the nasopharynx, base of skull, and masticator muscles signifying inflammatory soft tissue. Bone window sections showing erosive changes in the bones of the skull base (curved arrows) signifying osteomyelitis.

using the MALDI BioTyper database. The patient was then kept on ciprofloxacin 750 mg twice a day for 1-month duration. This led to relief from pain and subsequent imaging showed gradual resolution of lesion over many months with disappearance of the bulge of the ear canal. Follow-up CT and MRI performed after 1 year showed near-complete resolution of the lesion [Figure 2].

DISCUSSION

At present, *Pandoraea* genus consists of 10 exclusive human clinical species. These include *P. apista*, *Pandoraea pulmonicola*, *Pandoraea sputorum*, *Pandoraea anapnoica*, *Pandoraea anhela*, *Pandoraea bronchicola*, *Pandoraea captiosa*, *Pandoraea morbifera*, *Pandoraea nosoerga*, and *Pandoraea pneumonica*. Nonclinical species are mainly isolated from soil, water, animal feces, and powdered milk.^[12] These are environmental organisms found in water, soil, and on plants. Because of their ability to survive in aqueous environments, these organisms have become particularly problematic as opportunistic nosocomial pathogens in health-care settings.

Pathogenesis and virulence factor

Human *Pandoraea* species are primarily isolated from respiratory secretions of patients of cystic fibrosis (CF).

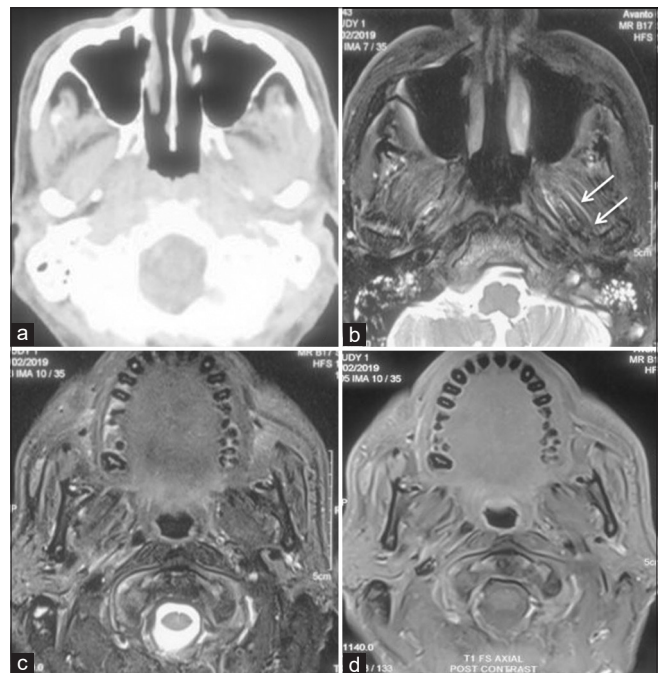


Figure 2: Axial CECT (a) showing near complete resolution of the inflammation in the base of skull region and masticator space. MRI (axial T2 FS-[b and c] and contrast-enhanced T1-[d]) of the corresponding area confirms these findings with minimal inflammation along the muscle fibers (arrows) with no contrast enhancement.

Seldom, from non-CF patients, has also been reported [Table 1].^[3,6-8,10,11,14,15] The growth of organism from blood and urine samples indicates their potential to invade lung epithelial cells. However, the ability to invade lung epithelial cells is not common and is unlikely to be the major virulence factor of these strains.^[2]

All *Pandoraea* species stimulate release of pro-inflammatory cytokines, particularly IL-6 and IL-8. Upregulation of these two interleukins is the primary virulence factor which is largely responsible for the chronic lung inflammation. Chronic colonization of *Pandoraea* further leads to *in vivo* point mutations and strain evolution overtime.^[2,9]

Table 1: Reports of *Pandoraea* infection with antibiotic susceptibility in non-CF patients.

Reference	Species	Strain	Country	Source	Age/Sex	Underlying condition/diagnosis	Sensitive to	Resistant to
Coenye et al., ^[3] 2000	<i>P. norimbergensis</i>	LMG 13019	Belgium	Blood	NA	NA	NA	NA
	<i>P. norimbergensis</i>	LMG 16603	Sweden	BAL	NA	NA	NA	NA
Daneshvar et al., ^[6] 2001	<i>P. apista</i>	G3307	USA	Blood	66 yr/F	COPD	Imipenem, Amikacin, tetracycline, ciprofloxacin	Ampicillin, amoxicillin-clavulanate, cefotaxime, cefazolin, meropenem, piperacillin, gentamycin
	<i>P. apista</i>	G3308	USA	BAL	75 yr/F	NA	Imipenem	Ampicillin, amoxicillin-clavulanate, amikacin, gentamycin, cefotaxime, cefazolin, meropenem, piperacillin, ciprofloxacin
	<i>P. pnomenusa</i>	G5056	USA	Blood	46 yr/M	Septicaemia	Imipenem, tetracycline	Ampicillin, amoxicillin-clavulanate, amikacin, gentamycin, cefotaxime, cefazolin, meropenem, piperacillin, ciprofloxacin
	<i>P. pnomenusa</i>	G7835	USA	Blood	76 yr/M	Bacteraemia	Imipenem	Ampicillin, amoxicillin-clavulanate, amikacin, gentamycin, cefotaxime, cefazolin, meropenem, piperacillin, ciprofloxacin

(Contd...)

Table 1: (Continued)

Reference	Species	Strain	Country	Source	Age/Sex	Underlying condition/diagnosis	Sensitive to	Resistant to
	<i>P. pnomenusa</i>	G8107	USA	BLOOD	49/M	NA	Imipenem	Ampicillin, amoxicillin-clavulanate, amikacin, gentamycin, cefotaxime, cefazolin, meropenem, piperacillin, ciprofloxacin
	Genomospecies 2* (<i>P. sputorum</i>)	G5084	USA	Maxillary sinus	NA/F	NA	Imipenem	Ampicillin, amoxicillin-clavulanate, amikacin, gentamycin, cefotaxime, cefazolin, meropenem, piperacillin, ciprofloxacin
	Genomospecies 3* (<i>P. capi</i>)	G9805	USA	Sputum	71 yr/M	Pneumonia	None	Imipenem, Ampicillin, amoxicillin-clavulanate, amikacin, gentamycin, cefotaxime, cefazolin, meropenem, piperacillin, ciprofloxacin
Stryjewski et al., ^[14] 2003	<i>P. pnomenusa</i>	NA	USA	Blood and BAL	30 yr/M	lung transplant for pulmonary sarcoidosis	Imipenem	Aminoglycosides, ceftazidime, ciprofloxacin, piperacillin-tazobactam, cotrimoxazole
Falces-Romero et al., ^[7] 2016	<i>P. pnomenusa</i>	NA	Spain	Blood	10 months/M	PRE-B ALL	Minocycline and Imipenem	Ampicillin, cephalothin, aminoglycosides, aztreonam, meropenem, piperacillin, ciprofloxacin
Monzón et al., ^[11] 2018	<i>P. sputorum</i>	NA	Spain	Hemodialysis catheter	79 yr/M	IgA Multiple myeloma, TYPE2 DM, ESRD, HTN, AF	NA	NA
Gao et al., ^[8] 2018	<i>Pandoraea species</i>	NA	China	Blood	23 days/M	Neonatal jaundice	Imipenem, cotrimoxazole, ampicillin-sulbactam, tetracycline	Amikacin, gentamycin, ceftazidime, aztreonam, meropenem, piperacillin, ciprofloxacin

(Contd...)

Table 1: (Continued)

Reference	Species	Strain	Country	Source	Age/Sex	Underlying condition/diagnosis	Sensitive to	Resistant to
Lin et al., ^[10] 2019	<i>P. apista</i>	NA	China	Sputum	44 yr/M	HI, postneurosurgery, pneumonia	NA	NA
Xiao et al., ^[15] 2019	<i>P. sputorum</i>	NA	China	Blood	43yr/M	Liver transplant, immunosuppressants	Imipenem, ceftriaxone, ciprofloxacin, levofloxacin, minocycline, piperacillin, tetracycline, tigecycline, ticarcillin-clavulanateb	Meropenem, aztreonam, cefepime, ceftazidime, gentamicin, tobramycin

*Genomospecies 2 and genomospecies 3 later grouped into species *Pandoraea sputorum* and *Pandoraea capi*, respectively, by Peeters et al.^[12]
P. norimbergensis: *Pandoraea norimbergensis*, *P. apista*: *Pandoraea apista*, *P. pnomenusa*: *Pandoraea pnomenusa*, *P. sputorum*: *Pandoraea sputorum*,
P. capi: *Pandoraea capi*

In CF, lung infection is polymicrobial in nature with *Pseudomonas aeruginosa* as the most commonly colonizing pathogen. *P. aeruginosa* and *Burkholderia multivorans* have growth suppressing effects on *Pandoraea* species, that is, why *Pandoraea* is more virulent in the absence of co-colonization with these pathogens and is more likely to cause bacteremia in non-CF patients than CF patients. Therefore, younger patients who had higher pathogen diversity showed lower incidence of permanent lung damage than older patients.^[5] Plasmids of nonclinical strain contain more virulence genes than clinical strains and if transmitted into clinical environment they may prove pathogenic. Antibiotic resistance genes were present in plasmids of nonclinical strains only and aid them in acclimatizing to their environment.^[16]

Diagnosis

Routine diagnostic tests are not sufficient for the diagnosis of *Pandoraea* species and molecular studies are required for their identification.^[15] 16S rRNA, *gyr B*, *gltB* gene sequencing, and genus-specific PCR all allow identification of *Pandoraea* species from its closely associated genera, but high level of identity among its species requires further analysis to identify individual members of *Pandoraea* species.^[4]

Recently, the use of MALDI-TOF, MS has shown good results. MALDI-TOF MS designates an organic matrix compound, which helps in the soft desorption and ionization of highly abundant bacterial or fungal proteins using laser energy. Subsequently, accurate identification relies on the availability of well-curated, extensive databases preferably encompassing the full spectrum of microbes encountered in clinical specimens.^[13]

With its use, early identification of the bacteria is possible. The use of MALDI-TOF MS for the routine identification of most microbes has largely replaced conventional biochemical and phenotypic tests in clinical laboratories, since it is 1.45 days faster, less expensive, and does not involve a labor-intensive protocol.^[1] Imaging may help in mapping out the disease process, however, as this is the 1st time imaging of this entity has ever been presented, it is near impossible to detail the specifics of the lesions on CT or MRI. Nevertheless, in the index case, the skull base lesion with its characteristic heterogeneous enhancement amidst the native structures around the nasopharynx and bone destruction pattern resembled an inflammatory process more than a neoplastic one.

Antibiotic susceptibility

Multidrug resistance is because of enzyme production and efflux pumps. Oxacillinase-62 plays an important role against imipenem resistance. All show resistance to meropenem, aminoglycosides, quinolones, and most β -lactam antibiotics while they are susceptible to imipenem, tetracycline, and trimethoprim-sulfamethoxazole. Its greatly variable antibiotic susceptibility necessitates accurate diagnosis and antibiotic sensitivity for its treatment.^[10]

There is no report so far for the intracranial invasion of *P. apista*. Authors present the very first case of this pathogen showing involvement of central nervous system. We are not able to identify the source of this pathogen in the patient. There is no case reported so far from our region. Surprisingly, the patient has no host factor to suggest any predicament or susceptibility for this extremely rare pathogen. The identification of the pathogen in our case is a serendipity

and we could manage the case only after going through the available literature.

CONCLUSION

Pandoraea is responsible for opportunistic pulmonary infections predominantly affecting CF patients. Although it can also affect non-CF patients, in whom it may be more virulent because of absence of polymicrobial environment. It requires molecular analysis for its accurate diagnosis. Because of its multidrug resistance, antibiotic sensitivity is necessary for the treatment. This pathogen may present with primary involvement of central nervous system and a high index of suspicion is necessary for its diagnosis and management.

Ethical approval

All procedures performed in studies involving human participants were in accordance with the ethical standards of the institutional and/or national research committee and with the 1964 Helsinki Declaration and its later amendments or comparable ethical standards.

Declaration of patient consent

The authors certify that they have obtained all appropriate patient consent.

Financial support and sponsorship

Publication of this article was made possible by the James I. and Carolyn R. Ausman Educational Foundation.

Conflicts of interest

There are no conflicts of interest.

REFERENCES

- Almuzara M, Barberis C, Traglia G, Famiglietti A, Ramirez MS, Vay C. Evaluation of matrix-assisted laser desorption ionization-time-of-flight mass spectrometry for species identification of non-fermenting Gram-negative bacilli. *J Microbiol Methods* 2015;112:24-7.
- Caraher E, Collins J, Herbert G, Murphy PG, Gallagher CG, Crowe MJ, et al. Evaluation of *in vitro* virulence characteristics of the genus *Pandoraea* in lung epithelial cells. *J Med Microbiol* 2008;57:15-20.
- Coenye T, Falsen E, Hoste B, Ohlén M, Goris J, Govan JR, et al. Description of *Pandoraea* gen. nov. with *Pandoraea apista* sp. nov., *Pandoraea pulmonicola* sp. nov., *Pandoraea pnomenusa* sp. nov., *Pandoraea sputorum* sp. nov. and *Pandoraea norimbergensis* comb. nov. *Int J Syst Evol Microbiol* 2000;50:887-99.
- Coenye T, Liu L, Vandamme P, LiPuma JJ. Identification of *Pandoraea* species by 16S ribosomal DNA-based PCR assays. *J Clin Microbiol* 2001;39:4452-5.
- Costello A, Reen FJ, O'Gara F, Callaghan M, McClean S. Inhibition of co-colonizing cystic fibrosis-associated pathogens by *Pseudomonas aeruginosa* and *Burkholderia multivorans*. *Microbiology* 2014;160:1474-87.
- Daneshvar MI, Hollis DG, Steigerwalt AG, Whitney AM, Spangler L, Douglas MP, et al. Assignment of CDC weak oxidizer group 2 (WO-2) to the genus *Pandoraea* and characterization of three new *Pandoraea* genomospecies. *J Clin Microbiol* 2001;39:1819-26.
- Falces-Romero I, Gutiérrez-Arroyo A, Romero-Gómez MP. Bacteriemia asociada a catéter por *Pandoraea pnomenusa* en un paciente pediátrico con leucemia aguda linfoblástica. *Med Clín* 2016;147:132.
- Gao J, Wei Q, Shao H, Wu H. A case report of *Pandoraea* sp. isolated from neonatal blood culture. *Chin J Microbes Infect* 2018;13:368-72.
- Greninger AL, Streithorst J, Golden JA, Chiu CY, Miller S. Complete genome sequence of sequential *Pandoraea apista* isolates from the same cystic fibrosis patient supports a model of chronic colonization with *in vivo* strain evolution over time. *Diagn Microbiol Infect Dis* 2017;87:1-6.
- Lin C, Luo N, Xu Q, Zhang J, Cai M, Zheng G, et al. Pneumonia due to *Pandoraea apista* after evacuation of traumatic intracranial hematomas: A case report and literature review. *BMC Infect Dis* 2019;19:869.
- Monzón T, Valga F, Reichert J, López C. Hemodialysis catheter colonised by *Pandoraea sputorum*. *Nefrología* 2018;38:662-4.
- Peeters C, de Canck E, Cnockaert M, de Brandt E, Snauwaert C, Verheyde B, et al. Comparative genomics of *Pandoraea*, a genus enriched in xenobiotic biodegradation and metabolism. *Front Microbiol* 2019;10:2556.
- Singhal N, Kumar M, Kanaujia PK, Virdi JS. MALDI-TOF mass spectrometry: An emerging technology for microbial identification and diagnosis. *Front Microbiol* 2015;6:791.
- Stryjewski ME, LiPuma JJ, Messier RH, Reller LB, Alexander BD. Sepsis, multiple organ failure, and death due to *Pandoraea pnomenusa* infection after lung transplantation. *J Clin Microbiol* 2003;41:2255-7.
- Xiao X, Tian H, Cheng X, Li G, Zhou J, Peng Z, et al. *Pandoraea sputorum* bacteremia in a patient who had undergone allogeneic liver transplantation plus immunosuppressive therapy: A case report. *Infect Drug Resist* 2019;12:3359-64.
- Yong D, Tee KK, Yin WF, Chan KG. Characterization and comparative overview of complete sequences of the first plasmids of *Pandoraea* across clinical and non-clinical strains. *Front Microbiol* 2016;7:1606.

How to cite this article: Patil NR, Tripathi M, Charaya K, Angrup A, Ahuja C, Mohindra S. Skull base osteomyelitis by *Pandoraea apista*: An unusual pathogen at unusual location – A case report. *Surg Neurol Int* 2021;12:447.