

Case Report

Successful treatment of Henoch-Schonlein purpura nephritis with plasma exchange in an adult male

Kunal Chaudhary^{1,2}, Ji-Young Shin², Georges Saab^{1,2} and Alan M. Luger²

¹Harry S Truman VA Hospital and ²University of Missouri Health Center, Columbia, USA

Abstract

Henoch-Schonlein purpura (HSP) frequently occurs in children under 15 years of age but is quite rare in adults. Most children who develop HSP nephritis completely recover from the illness, whereas up to 40% of adults have persistent hematuria and 10% develop chronic renal failure. Plasma exchange alone has been shown to be beneficial in children who have HSP nephritis. Adults have been treated using immunosuppressive drugs such as cyclophosphamide but effects are not certain. Here, we present a case of a 59-year-old white male who developed HSP nephritis while undergoing treatment with steroids. The patient developed acute renal failure with proteinuria and hematuria ~2 weeks after being initially diagnosed with HSP by skin biopsy. Renal biopsy showed proliferative, exudative glomerulonephritis involving all 20 glomeruli; some with early crescent formation. Immunofluorescence staining showed 3+ IgA deposits in mesangium suggesting HSP-induced GN. The patient's serum creatinine rose to 2.5 mg/dl with ~5 g of proteinuria by dipstick. Steroids were continued and the patient received plasma exchange treatments. Due to a very low leukocyte count, immunosuppressive agents were not given. Subsequently, renal function improved and the creatinine level came down to 1.3 mg/dl and proteinuria to <1 g/24 h. Since then, 1 year after this event, his serum creatinine has continued to stay at 1.2 mg/dl and he has trace proteinuria while taking a low-dose ACE inhibitor. This case illustrates the usefulness of plasma exchange in adult onset HSP nephritis, even without concomitant use of cytotoxic agents.

Keywords: Henoch-Schonlein purpura; nephritis; plasmapheresis

Background

Henoch-Schonlein purpura (HSP) frequently occurs in children below the age of 15 years and gets rare with increasing age. The disease may be preceded by an upper respiratory tract infection, and certain drugs have also been implicated in the pathogenesis of the disease. Prognosis and therapy largely depend on the clinical presentation.

Approximately 20% of children have renal manifestations of the disease that are more likely if the child is older or has gastrointestinal manifestations [1]. In children renal involvement usually causes a focal glomerular involvement and clinically presents with slight worsening of renal function, mild hematuria and proteinuria that usually resolve spontaneously. In adults there have been very few reported cases of HSP with renal involvement. Adults tend to have more severe renal involvement that carries a grave renal outcome if not appropriately managed. Whereas most children recover from the illness, up to 80% of adult patients have renal insufficiency with decreased glomerular filtration rate (GFR) or persistent proteinuria and hematuria [2] and close to 18% develop end-stage renal disease (ESRD) [3]. High-risk patients with severe renal involvement have been conventionally treated with steroids, along with immunosuppressants such as cyclophosphamide. There has been increasing evidence that plasmapheresis or plasma exchange has an important therapeutic role in the management of HSP nephritis. In fact, plasma exchange alone has been shown to be beneficial in children who have HSP with renal involvement [4]. Our patient developed diffuse exudative glomerulonephritis with crescent formation despite receiving steroids about 2 weeks after being initially diagnosed with HSP. Subsequently, he was treated with plasma exchange while being continued on steroids, but immunosuppressive agents such as cyclophosphamide were not used due to a very low white blood cell (WBC) count.

His serum creatinine that had risen to 2.5 mg/dl decreased to 1.3 mg/dl after three plasma exchange treatments and the proteinuria decreased significantly as well.

Since then, ~12 months after the episode, the creatinine has stabilized at 1.2 mg/dl and he has minimal proteinuria. This case illustrates the therapeutic benefit of plasma

Correspondence and offprint requests to: Kunal Chaudhary, Harry S Truman VA Hospital, 800 Hospital Drive, Columbia, MO 65201, USA. Tel: +1-573-882-8556; Fax: +1-573-814-6314; E-mail: chaudharyk@health.missouri.edu

exchange in severe renal involvement with HSP nephritis without concomitant use of cyclophosphamide.

Case report

A 59-year-old white male with past medical history significant for hypertension, hyperlipidemia, coronary artery disease, s/p CABG, peripheral vascular disease and diabetes mellitus type II presented to the emergency room with a rash on both lower extremities since the past 3 days. He reported a spontaneous eruption of a rash on his lower extremities extending to buttocks and mid-back. The patient reported having a sore throat 2 days prior that had resolved spontaneously in a day. The rash was non-pruritic, and he denied any insect bite, hematuria or hemoptysis. He had no recent alteration to his meds. He also complained of bilateral lower abdominal pain that started the day after the rash. He described it as dull aching, constant pain, 8/10 in intensity.

On physical examination the patient was alert and oriented, and in no apparent distress. With a regular pulse: 87/min, blood pressure: 154/78 mmHg, respiration rate: 20, temperature: 98.2°F, pulse oximetry: 97 and weight: 273.2 lbs. His mucus membranes were dry. He had 1–2 mm palpable purpura on his buttocks, lower extremities, lower back and forearms. Respiratory and cardiovascular examinations were within normal limits, abdomen was soft and tender and there was no hepatosplenomegaly. Neurological examination was unremarkable. Initial urinalysis was negative for protein and blood. Serum chemistries showed sodium 132 mEq/l, potassium 3.6 mEq/l, creatinine 1.6 mg/dl and urea nitrogen 35 mg/dl. Hemoglobin was 15 gm/dl, WBC count was 8800/mm³ and platelet count was 178 000/mm³. He was given IV hydration and in the next 2 days his creatinine improved to 1.1 mg/dl. However, he had respiratory failure and was intubated and transferred to ICU. He received IV contrast for evaluation of abdominal pain, and subsequent to that his creatinine again rose to 1.6 mg/dl and stayed at that level for the next few days. CAT scan of the abdomen showed bowel wall thickening consistent with vasculitic changes. Serologies for ANCA, ANA and complement levels were unremarkable. The skin rash was biopsied and came back strongly positive for IgA on immunofluorescence (IF) staining confirming HSP. On Day 7 of hospitalization, he was started on methylprednisolone 500 mg intravenously for three doses and then switched to prednisone 60 mg daily. On Day 14, the patient's creatinine again started to rise and he was found to have significant proteinuria and hematuria with occasional RBC casts. His urine output dropped to <500 ml in 24 h with the serum creatinine rising to 2.5 mg/dl; a renal biopsy was performed. The biopsy showed 20 glomeruli with proliferative, exudative changes in all glomeruli and with early crescent formation in some of the glomeruli (Figure 1). IF staining showed 3+ IgA deposits in mesangium suggesting HSP-induced GN. The renal tubules showed no evidence of injury. Concomitantly, his WBC count dropped to <3000/mm³ and platelets dropped to 53 000/mm³. The eti-

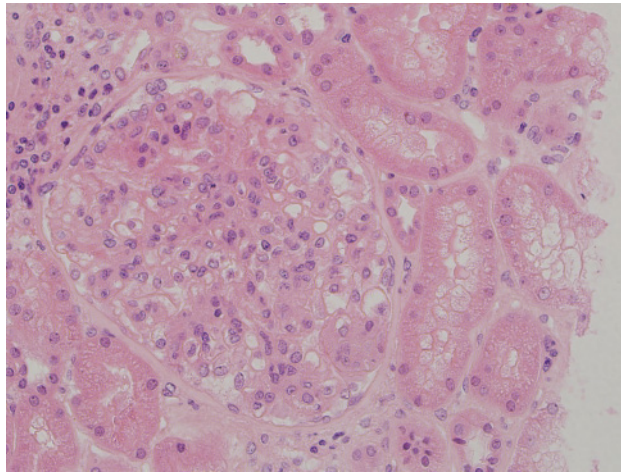


Fig. 1. Glomeruli showing inflammatory changes.

ology of his thrombocytopenia and leucopenia was not clear and possibly related to an underlying viral illness as it eventually resolved. Since the renal involvement occurred while he had been on steroids, alternate treatment was deemed necessary. As he had developed leucopenia and thrombocytopenia, treatment with cytotoxic agents was not instituted. Plasma exchange treatments with FFP replacement were instituted in the hope of reversing the renal failure. He received three plasma exchanges with FFP at a volume of 50 ml/kg body weight every other day. After the third treatment, the serum creatinine decreased to 1.3 mg/dl, and there was a decrease in hematuria and proteinuria as well. The patient was eventually discharged ~4 weeks after admission with a serum creatinine of 1.3 mg/dl.

Prednisone was tapered and discontinued after 3 months, and the patient's serum creatinine remained stable at 1.2 mg/dl at 12 months' follow-up with a protein creatinine ratio of 0.24. The hematuria has completely resolved. Pancytopenia has resolved and bone marrow biopsy showed no evidence of dysplasia and peripheral destructive processes as the likely etiology of pancytopenia.

Discussion

HSP is a small vessel leukocytoclastic vasculitis with the deposition of immune complexes containing IgA. It is characterized by the association of skin, joint, GI and renal manifestations. HSP is rare in the population older than 15 years of age, but the rate of developing renal complications and progressing to chronic renal failure is higher in the adult population. A study comparing 73 children to 31 adults found that whereas most of the children affected by this disease had a renal recovery, 40% adults had persistent hematuria and up to 10% sustained chronic renal failure [5]. A retrospective Italian study of 95 adults and 57 children with a mean follow-up of 5 years found that 31% of adults versus 24% of children had residual kidney disease but twice as many adults compared to children developed ESRD (15.8% versus 7%) [6]. In a series of 250 adults

Table 1. Incident and reported cases of adult onset HSP nephritis treated with plasma exchange

Case	Age	Initial SCr	Period from onset	Treatment	Post-SCr	Outcome
Incident	59	2.5 mg/dl	Day 5	3 × PE	1.3 mg/dl	Successful
Rech	57	DD	<2 weeks	5 × PE	Normal	Successful
Chen	33	DD	Day 11	9 × DFPP	3.1 mg/dl	Successful

SCr: serum creatinine; PE: plasma exchange; DFPP: double filtration plasma pheresis; DD: dialysis dependent.

with HSP nephritis, followed for a median of 14.8 years, Pillebaut *et al.* found that only 20% of patients returned to normal renal function with the absence of proteinuria and hematuria [2]. Ninety of these patients had moderate to severe proliferative glomerular disease, of which 32% had severe renal failure compared to only 15% in patients with less severe glomerular disease.

Twenty-seven (11%) patients developed ESRD. The proportion of glomeruli affected by fibrinoid necrosis correlated with the outcome but not the number of crescents. On multivariate analysis, levels of creatinine and proteinuria at the time of biopsy and proportion of interstitial fibrosis, glomerular fibrinoid necrosis and glomerular sclerosis were independent risk factors for severe renal failure. In a smaller study by Fogazzi *et al.*, 16 adult patients with HSP nephritis were followed for a mean of 90.5 months [3]. In their series, 11 (68.7%) of the patients had creatinine clearances of <60 ml/min, of which 3 (18.7%) ended up on dialysis. In their series, the percent of crescents was higher in patients who developed renal insufficiency.

Adults with HSP nephritis have been treated in analogy to pediatric patients using methylprednisolone pulse therapy, immunosuppressive drugs (cyclophosphamide and azathioprine), polyclonal immunoglobulin therapy, dapsone, plasmapheresis and thalidomide, but effects are not certain. The efficacy of steroids in treatment of HSP nephritis is not completely proven and results are conflicting. There are few reported cases of plasmapheresis in adults with HSP-induced renal failure; besides the present case, there have been two other reported cases of HSP nephritis in adults (Table 1). Rech *et al.* used plasmapheresis in one such patient with renal as well as GI involvement with success [7]. Chen *et al.* used double filtration plasmapheresis (DFPP) in a patient with crescentic HSP nephritis who was dialysis dependent but recovered to attain a GFR of 40 ml/min [8]. In both these cases, plasmapheresis was started within 2 weeks of onset of renal disease. In contrast, Harada *et al.* in their series of 17 patients with rapidly proliferative GN had 2 patients with HSP nephritis, who did not respond to plasma exchange treatments but were given this treatment after 1 month and 3 months of onset of renal disease respectively; one patient was dialysis dependent with a serum creatinine of 9.1 mg/dl [9]. It is not clear if these patients were adults or not. In our patient, deterioration in renal function with hematuria and proteinuria was observed after 2 weeks of admission, while he was on corticosteroids. Cytotoxic agents could not be used due to the neutropenia and thrombocytopenia that he developed. Plasmapheresis was instituted within 5 days of renal involvement after confirming the diagnosis of HSP nephritis on renal biopsy.

Renal function returned close to normal shortly after plasmapheresis, and this case suggests that plasmapheresis alone may be effective in treating HSP in adults as is the case with children.

The course of the renal disease and circulating antibody titers have been shown to be roughly parallel, and these auto antibodies do not appear to be present in those patients with HSP who do not have renal involvement. Plasmapheresis might be effective by removing antibody complexes before as well as after their deposition in mesangium [10]. Unfortunately we did not have antibody titers in our patient to make a comparison.

Conclusion

Our patient's renal function became severely impaired while being on steroids, and given the pathologic changes in all of 20 glomeruli with some showing early crescentic changes, we doubt if the patient's improvement in renal function was its natural course. Given the rapid decline of renal function even while on corticosteroids, the response to plasma exchange suggests this modality played a role in the improvement of renal function. Early institution of plasmapheresis seems to be a key as was the case with our patient and the two other successful outcomes. Plasmapheresis should be considered in adult onset HSP nephritis, especially in resistant cases and instituted early in the disease.

Conflict of interest statement. None declared.

References

1. Chang WL, Yang YH, Wang LC *et al.* Renal manifestations in Henoch-Schonlein purpura: a 10 year clinical study. *Pediatr Nephrol* 2005; 20: 1269–1272
2. Pillebaut E, Thervet E, Hill G *et al.* Henoch-Schonlein purpura in adults: outcome and prognostic factors. *J Am Soc Nephrol* 2002; 13: 1271–1278
3. Fogazzi GB, Paquali S, Moriggi M *et al.* Long term outcome of Henoch-Schonlein nephritis in the adult. *Clin Nephrol* 1989; 31: 60–66
4. Hattori M, Ito K, Konomoto T *et al.* Plasmapheresis as the sole therapy for rapidly progressive Henoch-Schonlein purpura nephritis in Children. *Am J Kidney Dis* 1999; 33: 427–433
5. Llan Y, Naparstek Y. Henoch-Schonlein purpura in children and adults: Is it one entity? *Semin Arthritis Rheum* 2002; 32: 139–140
6. Coppo R, Mazzucco G, Cagnoli L *et al.* Long term prognosis of Henoch-Schonlein nephritis in adults and children. *Nephrol Dial Transplant* 1997; 12: 2277–2283
7. Rech J, Fuchs F, Kallert S *et al.* Plasmapheresis therapy in an elderly patient with rapidly progressive Henoch-Schonlein purpura

- with disseminated organ involvement. *Clin Rheumatol* 2007; 26: 112–114
8. Chen TC, Chung FR, Lee CH *et al.* Successful treatment of crescentic glomerulonephritis associated with adult-onset Henoch-Schoenlein purpura by double-filtration plasmapheresis. *Clin Nephrol* 2004; 61: 213–216
 9. Harada T, Ozono Y, Sasaki O *et al.* Plasmapheresis in the treatment of rapidly progressive glomerulonephritis. *Ther Apher* 1997; 1: 366–369
 10. Lee J, Clayton J, Shihab F *et al.* Successful treatment of recurrent Henoch-Schonlein purpura in a renal allograft with plasmapheresis. *Am J Trans* 2008; 8: 228–231

Received for publication: 15.5.08

Accepted in revised form: 2.7.08