

# Sonographic diagnosis of perforation of the gastric antrum caused by a foreign body

## A case report

Yanan Zhao, MD<sup>a</sup>, Zheng Yang, MD<sup>b</sup>, Juan Quan, MD<sup>a</sup>, Huisen Hu, MD<sup>c,\*</sup>

### Abstract

**Rationale:** Ingestion of foreign bodies often occurs in clinical environments, especially in toddlers and aged patients. Although plain radiography and CT are widely used for the assessment of foreign bodies, sonography has an advantage in the diagnosis of some radiolucent foreign bodies, such as wood and bamboo materials.

**Patient concerns:** An 80-year-old woman presented with a 4-day history of right upper quadrant abdominal persistent distended pain without radiation.

**Diagnoses:** Radiographs, a preliminary abdominal ultrasound (US) and an abdominal computed tomography (CT) were unremarkable. A repeat abdominal US found a foreign body inserted in the gastric wall of antrum. But subsequent gastroscopy was negative. A laparotomy confirmed the diagnosis of bamboo stem penetration out of the gastric antrum.

**Interventions:** The patient was treated by laparotomy and the bamboo stem was removed successfully.

**Outcomes:** Bamboo stem-caused digestive perforation was confirmed by laparotomy. The perforation site was at the gastric wall of antrum. Intravenous antibiotic therapy was administered for two weeks until her body temperature dropped to a normal level, and C-reactive protein (CRP) decreased to the normal limits. She was discharged from the hospital.

**Lessons:** Previous studies suggest that US can identify the location and shape of foreign bodies in the alimentary tract in toddlers. This case shows US is also effective in aged patients. The US can be utilized as a problem-solving tool when radiolucent foreign bodies are suspected, especially when the results of CT and gastroscopy are negative.

**Abbreviations:** CRP = C-reactive protein, CT = computed tomography, US = ultrasound, WBC = white blood cell.

**Keywords:** foreign body, perforation, stomach, ultrasound

## 1. Introduction

Ingestion of foreign bodies often occurs in clinical environments; most of these objects pass through the alimentary tract in an uneventful manner. Incidence of digestive tract damage, such as obstruction and perforation of an ingested foreign body, is less than 1%.<sup>[1,2]</sup> Relying on history and symptoms to make a definite diagnosis is difficult, as most patients, especially toddlers and elderly, are unaware of the ingestion of a foreign body. Although

plain radiography and computed tomography (CT) are widely used for the assessment of foreign bodies, sonography is also helpful for diagnosis in some radiolucent foreign bodies.<sup>[3]</sup> We report a case in which a bamboo stem penetrating out of the gastric antrum was found by ultrasound (US) but not plain radiography, CT, or gastroscopy.

## 2. Case report

An 80-year-old woman presented with a 4-day history of right upper quadrant abdominal persistent distended pain without radiation. No fever, vomiting, or weight loss was reported. She was a farmer without a significant past medical history or a family history of malignancy. She denied a history of foreign body ingestion in the digestive tract. Physical examination showed right upper abdominal tenderness and mild muscular tension. Laboratory studies showed a white blood cell (WBC) count of 11100/mm<sup>3</sup> with 88.1% neutrophils, a hemoglobin level of 85.0g/L, and a C-reactive protein (CRP) concentration of 96.34 mg/L. Serum biochemical analyses including glucose level, liver function, renal function, amylase, lipase, cardiac markers, and tumor markers showed no abnormalities. Chest and abdominal radiographs were unremarkable. A preliminary abdominal US showed no remarkable signs except for chronic cholecystitis. Subsequently, an enhanced abdominal CT was performed, which revealed thickening and edema of gastric wall of antrum and chronic cholecystitis. She had no pain relief after 2 days of antibiotic and symptomatic therapies with a WBC count of 8300/mm<sup>3</sup> and a CRP concentration of 102.70 mg/L. A

Editor: N/A.

Informed Consent: Patient has provided informed consent for publication of the case.

The authors have no conflicts of interest to disclose.

<sup>a</sup> Department of Ultrasound, The Second Affiliated Hospital of Zhejiang University School of Medicine, Hangzhou, Zhejiang, <sup>b</sup> Department of Anesthesiology, The Second Affiliated Hospital of Zhejiang University School of Medicine, Hangzhou, Zhejiang, <sup>c</sup> Department of Ultrasound, Lanxi People's Hospital, Jinhua, Zhejiang, China.

\* Correspondence: Huisen Hu, Department of Ultrasound, Lanxi People's Hospital, Jinhua, Zhejiang 321000, China (e-mail: zynfer@163.com).

Copyright © 2019 the Author(s). Published by Wolters Kluwer Health, Inc. This is an open access article distributed under the terms of the Creative Commons Attribution-Non Commercial License 4.0 (CCBY-NC), where it is permissible to download, share, remix, transform, and buildup the work provided it is properly cited. The work cannot be used commercially without permission from the journal.

Medicine (2019) 98:8(e14586)

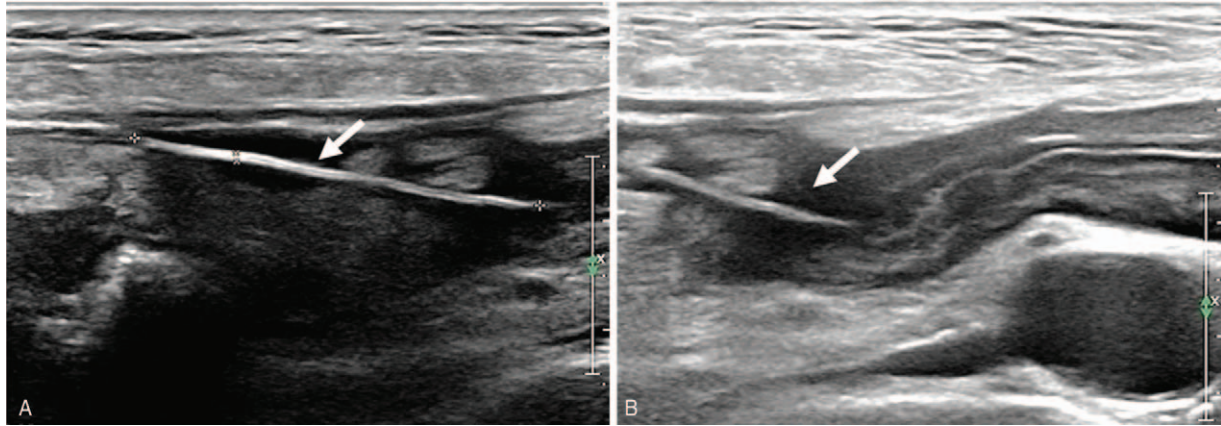
Received: 23 October 2018 / Received in final form: 19 January 2019 /

Accepted: 28 January 2019

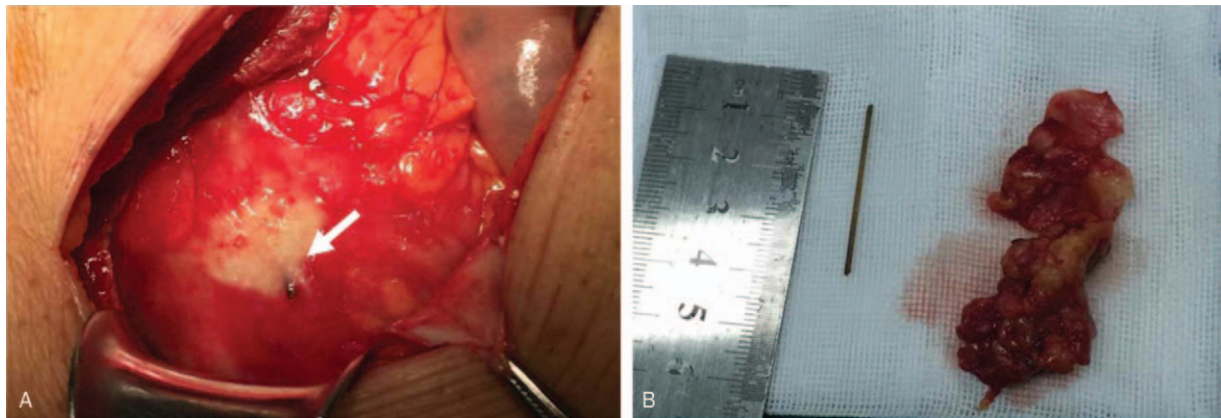
<http://dx.doi.org/10.1097/MD.0000000000014586>

repeat abdominal US was performed, and a hyperechoic straight-

The patient was advanced to gastroscopy at once, which



**Figure 1.** Ultrasound presenting a hyperechoic straight-line foreign body ( $3.5 \times 0.14$  cm) (white arrow) (A), for which the needle tip was located within gastric wall of antrum (B).



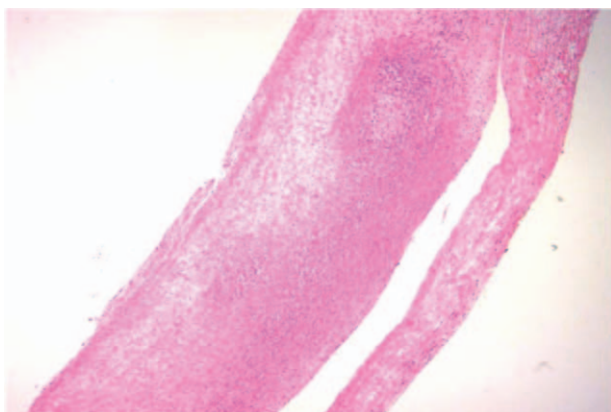
**Figure 2.** Operative photographs presenting the tip of the bamboo stem (white arrow) protruding through gastric wall of the antrum (A) and the bamboo stem and inflammatory mass after removal (B).

line foreign body ( $3.5 \times 0.14$  cm) with a needle tip was identified (Fig. 1). This foreign body was located within gastric wall of antrum embedded within a heterogenic echo inflammatory mass ( $5.5 \times 1.7$  cm) in the right periumbilical abdomen.

showed no abnormality of the stomach and duodenum, with the exception of chronic non-atrophic gastritis. A laparotomy was subsequently conducted. A  $6 \times 4$  cm inflammatory mass with yellow empyema of almost 30 mL in the right upper abdominal was found, and a bamboo stem ran obliquely out of the anterior wall of the gastric antrum during the operation. The perforation diameter was approximately 1.0 mm with significant local tissue edema (Fig. 2). The foreign body was removed, and percutaneous drainage of the right liver was performed. Pathology showed microscopic amounts of inflammatory necrotic tissue (Fig. 3). She had a fever during the postoperative phase, and intravenous antibiotic therapy was administered for 2 weeks until her body temperature dropped to a normal level, and CRP decreased to the normal limits. She was discharged from the hospital. She recovered well during the follow-up phase at the outpatient clinic.

### 3. Discussion

The most common sites of perforation are the gastric antrum, the duodenum, the ileocecal junction, and the sigmoid colon; perforation can be caused by sharp foreign bodies such as fish bones, chicken bones, needles, and toothpicks.<sup>[1,4]</sup> The patient was unable to recall the incidence of bamboo stem ingestion. We



**Figure 3.** Histopathological examination showed the amount of inflammatory cell infiltration and necrosis in the specimen.

suggest that some old patients without teeth more easily swallow foreign bodies by mistake while eating.

Radiopaque objects can be easily diagnosed with plain radiographs. However, it is a challenge for plain radiographs to diagnose radiolucent foreign bodies, such as wood and plastics.<sup>[5]</sup> One study revealed that plain radiographs have only 7.4% sensitivity at identifying wood foreign bodies.<sup>[6]</sup> Another study including 200 patients found that plain radiographs could only detect 15% of wood particles.<sup>[7]</sup> Previous studies<sup>[1,4]</sup> have demonstrated that CT is useful for evaluating the presence of foreign bodies, especially in detecting complications, such as perforation and abscess formation because of its high resolution and accuracy. The CT has been reported to have higher sensitivity in foreign body detection compared with plain radiography of faintly opaque objects of small size.<sup>[2]</sup> In this case, CT found edema and thickening of gastric wall of antrum. We suggest that CT missed the foreign body due to its radiolucent character. Meanwhile, we infer the imaging slice is not thin enough to reveal the foreign body because of almost parallel orientation of the bamboo stem to the scan plane.

Sonography has been proven useful in detecting superficial foreign bodies, especially radiolucent ones.<sup>[8]</sup> A recent meta-analysis found that US has 72% sensitivity and 92% specificity for identifying foreign bodies in soft tissues.<sup>[5]</sup> One study compared the sensitivity of CT and US for detecting foreign bodies in in-vitro models simulating superficial soft tissues, and it demonstrated that wood and plastic foreign bodies are more clearly on US images.<sup>[9]</sup> The US can also identify the location and shape of foreign bodies in the alimentary tract in pediatric population.<sup>[3,8,10]</sup>

The US is not only safe and repeatable but also can show the foreign body as hyperechoic structures.<sup>[8]</sup> Wooden materials always appear as hyperechoic structures in US, while the adjacent soft tissue visualized as hypoechoic due to reactive inflammation.<sup>[11]</sup> In this case, only in a supine position, the patient received preliminary US on a full stomach in the emergency room, and the result was negative. The patient underwent a repeated US on an empty stomach. US showed the status and location of the bamboo stem as a hyperechoic straight-line, which located within gastric wall of antrum after changing the patient's position. Meanwhile, US can also provide relative information such as integrity of the gastric wall, changes in the surrounding mesentery, the presence of free peritoneal fluid, and relationships with other abdominal organs.<sup>[12]</sup> Sometimes sonography of a water-filled stomach as an acoustic window can be helpful to visualize gastric foreign bodies because it reduces air artifacts.<sup>[8]</sup> It is a complementary method for helping diagnosis although we didn't use the technique in this case. Furthermore, observation of US also depends on the degree of clinical skills. Obliquity of the foreign body to the US beam always results in underestimation of its size. A perpendicular or near-perpendicular angle of approach to the surface of a foreign body can provide a strong reflection back to the transducer and produce a reverberation artifact. Both techniques are helpful in identifying objects.<sup>[13]</sup> The presence of acoustic shadowing is variable and depends on the composition of the foreign body and the incidence of the beam.<sup>[10]</sup> The comet-tail artifact always indicates metallic objects.<sup>[8,10]</sup>

Gastrointestinal endoscopy has been reported as having high sensitivity for foreign body detection.<sup>[14]</sup> This technique failed to identify the foreign body in this case, possibly due to the gastric mucosa being penetrated and subsequently healed. Therefore, endoscopy may be helpful when performed early, such as before foreign body migration and mucosal healing.<sup>[4]</sup>

We recommend that the elderly, especially those without teeth, should have healthy dietary habits in daily life. Plain radiography and CT can provide necessary and sufficient information for physicians in most cases, but when radiography and CT are negative, especially a radiolucent foreign body is suspected, sonography can be helpful to evaluate the location and status of foreign bodies. A foreign body detection with US is especially important in resource-limited areas where no other diagnostic imaging exists. The US can be utilized as a problem-solving tool when radiolucent foreign bodies are suspected, especially when the results of CT and gastric endoscopy are negative. Furthermore, we suggest the need for further studies to evaluate the value of sonography in detecting foreign bodies in alimentary tract in elderly.

## Author contributions

**Conceptualization:** Yanan Zhao, Zheng Yang.

**Data curation:** Huisen Hu.

**Formal analysis:** Yanan Zhao, Juan Quan.

**Investigation:** Zheng Yang.

**Resources:** Huisen Hu.

**Software:** Yanan Zhao.

**Validation:** Zheng Yang, Juan Quan.

**Visualization:** Huisen Hu.

**Writing – original draft:** Yanan Zhao.

**Writing – review & editing:** Huisen Hu.

Yanan Zhao orcid: 0000-0002-4938-9235.

## References

- [1] Yang Z, Wu D, Xiong D, et al. Gastrointestinal perforation secondary to accidental ingestion of toothpicks: a series case report. *Medicine (Baltimore)* 2017;96:e9066.
- [2] Broome CJ, Peck RJ. Hepatic abscess complicating foreign body perforation of the gastric antrum: an ultrasound diagnosis. *Clin Radiol* 2000;55:242–3.
- [3] Hosokawa T, Yamada Y, Sato Y, et al. Role of sonography for evaluation of gastrointestinal foreign bodies. *J Ultrasound Med* 2016;35:2723–32.
- [4] Santos SA, Alberto SCF, Cruz E, et al. Hepatic abscess induced by foreign body: case report and literature review. *World J Gastroenterol* 2007;13:1466–70.
- [5] Davis J, Czerniski B, Au A, et al. Diagnostic accuracy of ultrasonography in retained soft tissue foreign bodies: a systematic review and meta-analysis. *Acad Emerg Med* 2015;22:777–87.
- [6] Levine MR, Gorman SM, Young CF, et al. Clinical characteristics and management of wound foreign bodies in the ED. *Am J Emerg Med* 2008;26:918–22.
- [7] Anderson MA, Newmeyer WLIII, Kilgore ESJr. Diagnosis and treatment of retained foreign bodies in the hand. *Am J Surg* 1982;144:63–7.
- [8] Spina P, Minniti S, Bragheri R. Usefulness of ultrasonography in gastric foreign body retention. *Pediatr Radiol* 2000;30:840–1.
- [9] Haghnegahdar A, Shakibafard A, Khosravifard N. Comparison between computed tomography and ultrasonography in detecting foreign bodies regarding their composition and depth: an in vitro study. *J Dent* 2016;17:177–84.
- [10] Jeckovic M, Anupindi SA, Barbir SB, et al. Is ultrasound useful in detection and follow-up of gastric foreign bodies in children? *Clin Imaging* 2013;37:1043–7.
- [11] Polat B, Atici Y, GÜRpınar T, et al. Diagnosis and treatment of retained wooden foreign bodies in the extremities using ultrasound. *Acta Ortop Bras* 2018;26:198–200.
- [12] Moammar H, Al-Edreesi M, Abdi R. Sonographic diagnosis of gastric-outlet foreign body: case report and review of literature. *J Family Community Med* 2009;16:33–6.
- [13] Piotta L, Gent R, Kirby CP, et al. Preoperative use of ultrasonography to localize an ingested foreign body. *Pediatr Radiol* 2009;39:299–301.
- [14] Li ZS, Sun ZX, Zou DW, et al. Endoscopic management of foreign bodies in the upper-GI tract: experience with 1088 cases in China. *Gastrointest Endosc* 2006;64:485–92.