

Labial and lingual/palatal bone thickness of maxillary and mandibular anteriors in human cadavers in Koreans

Ji Young Han*, Gyu Un Jung

Division of Periodontology, Department of Dentistry, Hanyang University College of Medicine, Seoul, Korea

Purpose: The aim of this study is to evaluate the buccal and lingual bone thickness in the anterior teeth and the relationship between bone thickness and the tissue biotype.

Methods: Three male and two female human cadaver heads (mean age, 55.4 years) were used in this study. First, the biotype of periodontium was evaluated and categorized into a thick or a thin group. Next, full thickness reflections of the mandible and the maxilla to expose the underlying bone for accurate measurements in the anterior regions were performed. After the removal of the half of the alveolar bone, the probe with a stopper was used to measure the thickness of bone plate at the alveolar crest (AC), 3 mm apical to the alveolar crest (AC-3), 6 mm apical to the alveolar crest (AC-6), and 9 mm apical to the alveolar crest (AC-9).

Results: Four of them had a thick biotype. There was no penetration or dehiscence. The thickness of the buccal plates at the alveolar crest were 0.97 ± 0.18 mm, 0.78 ± 0.21 mm, and 0.95 ± 0.35 mm in the maxillary central incisors, lateral incisors, and canines, respectively. The thickness of the labial plates at the alveolar crest were 0.86 ± 0.59 mm, 0.88 ± 0.70 mm, and 1.17 ± 0.70 mm in the mandibular central incisors, lateral incisors and canines, respectively.

Conclusions: The thickness of the labial plate in the maxillary anteriors is very thin that great caution is needed for placing an implant. The present study showed the bone thickness of maxillary and mandibular anteriors at different positions. Therefore, these data can be useful for the understanding of the bone thickness of the anteriors and a successful implant placement.

Keywords: Alveolar bone, Dental esthetics, Dental implants.

INTRODUCTION

Osseointegrated implants have been successfully used in the edentulous area for many years [1,2]. For dental implant placement, the presence of sufficient bone volume is the most important of prerequisites. Moreover, there has been increasing interest in the placement of implants into tooth sockets immediately following an extraction. Implants placed in this manner, either with or without simultaneous restoration, are

advocated to preserve soft tissue contours, preserve bone dimensions, reduce the overall treatment period, and to achieve more pleasing esthetic results [3-8].

It has been suggested that an immediate placement of implants may avoid the resorption process of the buccal bone plate and maintain the original shape of the ridge [9]. However, a series of experiments in dogs [10-14] failed to support this hypothesis. It has been reported that the placement of an implant in a fresh extraction site failed to prevent remod-

Received: Nov. 23, 2010; Accepted: Feb. 5, 2011

*Correspondence: Ji Young Han

Division of Periodontology, Department of Dentistry, Hanyang University College of Medicine, 17 Haengdang-dong, Seongdong-gu, Seoul 133-791, Korea

E-mail: hjyperio@hanyang.ac.kr, Tel: +82-2-2290-8671, Fax: +82-2-2290-8673

eling that occurred in the walls of the socket, in particular in the buccal bone plate [11,12]. This marked reduction in the height of the buccal bone crest, which is composed almost entirely of bundle bone, is easily affected by the elevation of surgical flaps. Therefore, there have been trials for placing implants into extraction sockets with minimal flap elevation [15] or without the elevation of surgical flaps [16,17]. Achieving esthetic success is suggested to be dependent on an ideal three-dimensional implant position [18], maintenance of an adequate buccal bone over the implant buccal surface [19,20], and tissue biotype [5]. However, a flapless surgery does not reveal the dimension of the bone thickness and the bony contour. We have no choice but to rely on the information from the radiologic findings. Therefore, an anatomical understanding of the anterior region is necessary. Despite this, there are a few studies [21] attempting to evaluate bone thickness in the anterior region of the human cadaver.

The aim of this study is to evaluate buccal and lingual bone thickness in the anterior teeth and to examine whether a relationship exists between bone thickness and the tissue biotype.

MATERIALS AND METHODS

Three male and two female human cadaver heads (mean age, 55.4 years) were used in this study. The cadaver heads were donated to the Department of Anatomy and Cell Biology of Hanyang University for educational purposes. They were used for the present study after academic use.

Bilateral measurements were made on the 5 subjects (Fig. 1).

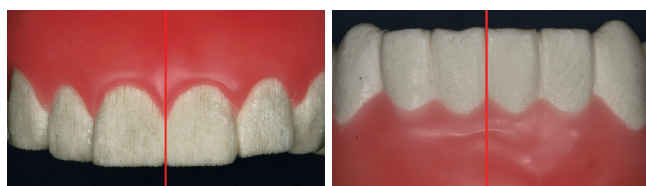


Figure 1. Bilateral measurements were made on the human cadaver heads.

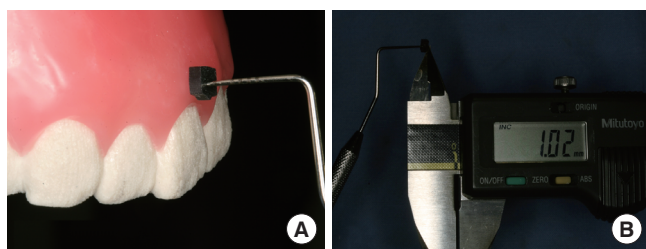


Figure 2. A periodontal probe was placed into the facial aspect of the gingiva (A), and the depth of periodontal probe penetration was measured with digital calipers (B).

First, the biotype of periodontium was evaluated and categorized into either a thick or thin group. To evaluate the biotype, a periodontal probe was placed into the facial aspect of the gingiva (Fig. 2A). In addition, the depth of periodontal probe penetration was measured with a digital caliper (Absolute Digimatic, Mitutoyo Co., Tokyo, Japan) (Fig. 2B). The gingival biotype was considered thin if the measurement was ≤ 1.0 mm and thick if it measured >1.0 mm [22]. In order to expose the underlying bone for accurate measurements in the anterior regions, full thickness reflections of the mandible and maxilla were performed. The thickness of the buccal and palatal/lingual plates was measured with a digital caliper (Fig. 3A). These measurements were taken along the line to the middle of the teeth and parallel to the long axis of the teeth (Fig. 3B). After the removal of half of the alveolar bone, a probe with a stopper was used to measure the thickness of the bone plate at the alveolar crest (AC), 3 mm apical to the alveolar crest (AC-3), 6 mm apical to the alveolar crest (AC-6), and 9 mm apical to the alveolar crest (AC-9) (Fig. 4).

Due to the brittleness of the buccal bone plate, great care was taken in the performance of these procedures. The measurements were taken by two examiners, and the statistical analysis was performed using a commercially available soft-

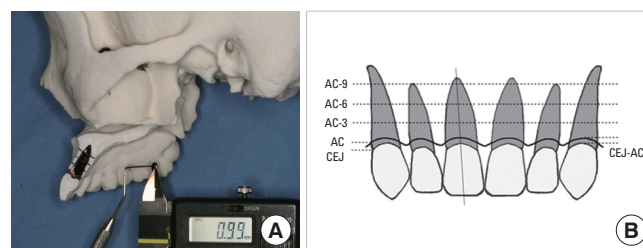


Figure 3. The thickness of the buccal and palatal/lingual plates was measured with digital calipers (A), and the measurements were taken along the line to the middle of the teeth and parallel to the long axis of the teeth (B). AC-3: 3 mm apical to the alveolar crest (AC), AC-6: 6 mm apical to the AC, AC-9: 9 mm apical to the AC, CEJ-AC: the distance between cemento-enamel (CEJ) junction and AC.

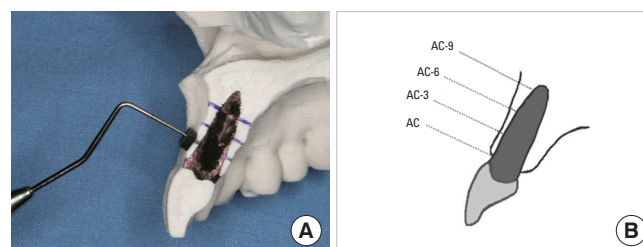


Figure 4. A probe with a stopper was used to measure the thickness of the bone plate at each position and landmarks used to describe the dimension of bone thickness in the anteriors: alveolar crest (AC), 3 mm apical to the AC (AC-3), 6 mm apical to the AC (AC-6), and 9 mm apical to the AC (AC-9).

ware program (SPSS ver. 17.0, SPSS Inc., Chicago, IL, USA). Mean values and standard deviations were calculated for the distance from the cementoenamel junction to the alveolar crest and the bone thickness at the alveolar crest (AC), 3 mm apical to the alveolar crest (AC-3), 6 mm apical to the alveolar crest (AC-6), and 9 mm apical to the alveolar crest (AC-9). The Wilcoxon signed ranks test was used to analyze potential differences between the bone thickness at the alveolar crest (AC) and the bone thickness at other positions. The level of significance chosen in all statistical tests was set at $P < 0.05$.

RESULTS

Four of the subjects had a thick biotype and the other had a thin biotype. There was no penetration or dehiscence in this study.

Labial thickness of the maxillary anteriors

The distance between the cementoenamel junction and the alveolar crest varied among the subjects (Fig. 5). The thickness of the labial plate in the maxillary central incisor was 0.97 ± 0.18 mm, 1.02 ± 0.55 mm, 1.25 ± 0.90 mm, and 1.72 ± 0.99 mm at the crest, AC-3, AC-6, and AC-9, respectively (Table 1). The thickness of the labial plate in the maxillary central incisor at the alveolar crest was very thin compared with those of other positions ($P < 0.05$). The thickness of the labial plate in the maxillary lateral incisor was 0.78 ± 0.21 mm, 0.85 ± 0.31 mm, 0.85 ± 0.52 mm, and 1.32 ± 0.69 mm at the crest, AC-3, AC-6, and AC-9, respectively. The thickness of the labial plate in the maxillary canine was 0.95 ± 0.35 mm, 1.13 ± 0.65 mm, 1.42 ± 0.76 mm, and 1.60 ± 1.00 mm at the crest, AC-3, AC-6, and AC-9.

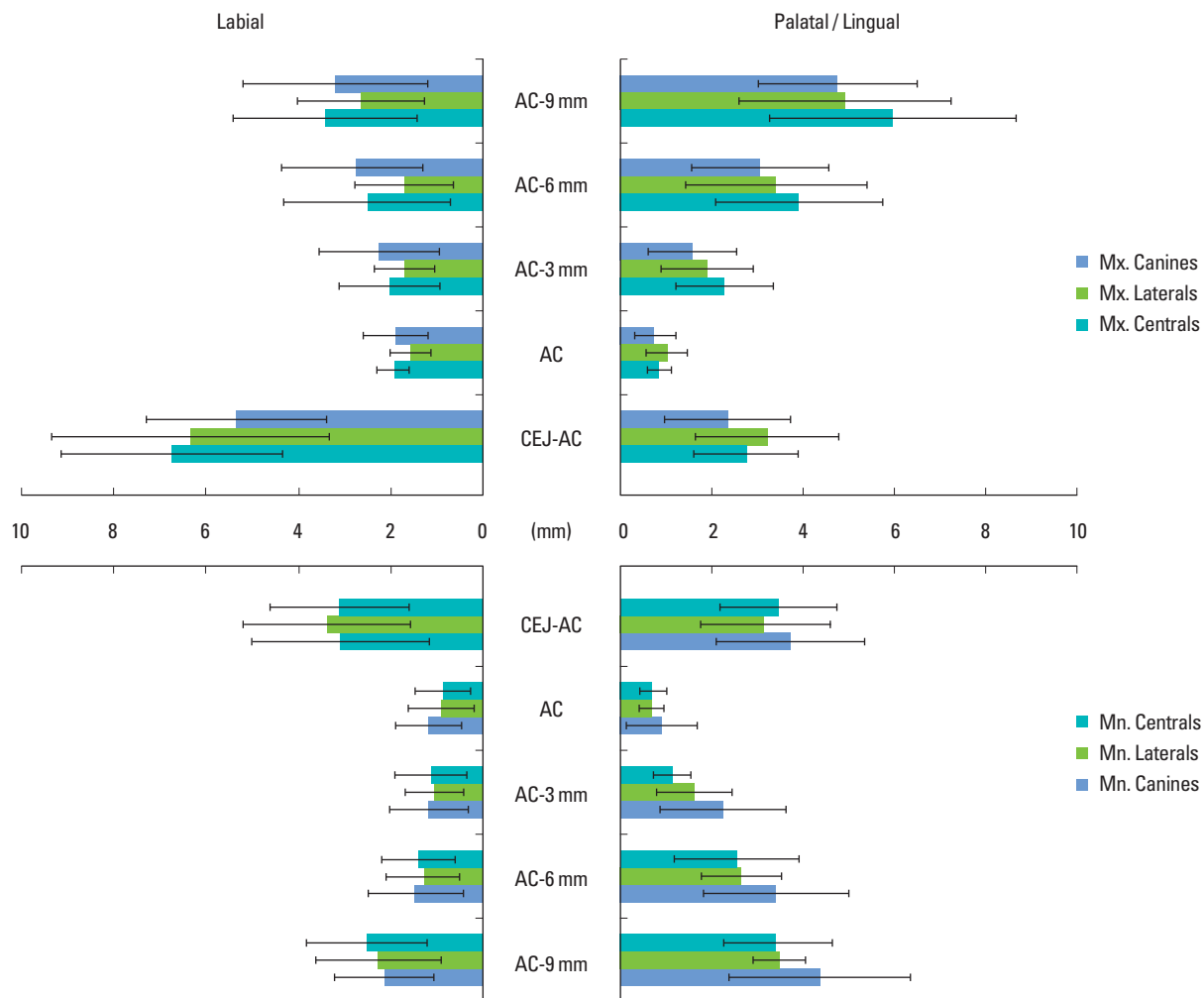


Figure 5. The thickness of the labial and palatal/lingual plates in the anteriors and the distance between the cementoenamel junction (CEJ) and the alveolar crest (mean \pm SD mm). AC-3: 3 mm apical to the alveolar crest (AC), AC-6: 6 mm apical to the AC, AC-9: 9 mm apical to the AC, CEJ-AC: the distance between CEJ, and AC. Mx.: maxilla, Mn.: mandible.

Palatal thickness of the maxillary anteriors

The distances between the cementoenamel junction and the alveolar crest in the palatal side of the maxillary anteriors were slightly less than those of the labial side (Fig. 5). The thickness of the palatal plate in the maxillary central incisor was 0.82±0.26 mm, 2.26±1.07 mm, 3.89±1.85 mm, and 5.95±2.70 mm at the crest, AC-3, AC-6, and AC-9, respectively (Table 1). The thickness of the palatal plate in the maxillary lateral incisor was 0.98±0.45 mm, 1.88±1.01 mm, 3.39±1.98 mm, and 4.91±2.33 mm at the crest, AC-3, AC-6, and AC-9, respectively. The width of the palatal plate in the maxillary canine was 0.72±0.45 mm, 1.55±0.98 mm, 3.05±1.51 mm, and 4.75±1.75 mm at the crest, AC-3, AC-6, and AC-9, respectively.

Labial thickness of the mandibular anteriors

The distance between the cementoenamel junction and the alveolar crest varied among subjects. The thickness of the labial plate in the mandibular central incisor was 0.86±0.59 mm, 1.13±0.79 mm, 1.39±0.79 mm, and 2.50±1.30 mm at the crest, AC-3, AC-6, and AC-9, respectively (Table 2). The thickness of the labial plate in the mandibular central incisor was thinnest at the alveolar crest (*P*<0.05). The thickness of the

labial plate in the mandibular lateral incisor was 0.88±0.70 mm, 1.04±0.62 mm, 1.31±0.81 mm, and 2.26±1.36 mm at the crest, AC-3, AC-6, and AC-9, respectively. The thickness of the labial plate in the mandibular lateral incisor at the alveolar crest was very thin compared with those of other positions (*P*<0.05). The thickness of the labial plate in the mandibular canine was 1.17±0.70 mm, 1.17±0.85 mm, 1.46±1.03 mm, and 2.14±1.07 mm at the crest, AC-3, AC-6, and AC-9, respectively.

Lingual thickness of the mandibular anteriors

The thickness of the lingual plate in the mandibular central incisor was 0.70±0.30 mm, 1.10±0.40 mm, 2.53±1.37 mm, and 3.44±1.19 mm at the crest, AC-3, AC-6, and AC-9, respectively (Table 2). The thickness of the lingual plate in the mandibular central incisor at the alveolar crest was very thin compared with those of other positions (*P*<0.05). The thickness of the lingual plate in the mandibular lateral incisor was 0.66±0.27 mm, 1.60±0.83 mm, 2.64±0.88 mm, and 3.46±0.57 mm at the crest, AC-3, AC-6, and AC-9, respectively. The thickness of the labial plate in the mandibular lateral incisor was thinnest at the alveolar crest (*P*<0.05). The thickness of the lingual plate in the mandibular canine was 0.88±0.78 mm, 2.24±1.40

Table 1. The thickness of the labial and palatal plates of maxillary anteriors (n=10).

	Central incisor		Lateral incisor		Canine	
	Labial	Palatal	Labial	Palatal	Labial	Palatal
CEJ-AC	3.368±1.196	2.731±1.147	3.163±1.506	3.196±1.581	2.664±0.971	2.328±1.377
AC	0.973±0.181 ^{a)}	0.826±0.263	0.787±0.218	0.985±0.455	0.951±0.352	0.722±0.452
AC-3	1.029±0.551	2.265±1.074	0.851±0.317	1.883±1.012	1.134±0.659	1.558±0.980
AC-6	1.253±0.900	3.898±1.856	0.858±0.526	3.392±1.987	1.420±0.761	3.050±1.516
AC-9	1.721±0.998	5.958±2.705	1.324±0.690	4.918±2.331	1.606±1.001	4.755±1.750

Values are presented as mean±SD mm.

CEJ-AC: the distance between cementoenamel junction and alveolar crest, AC: alveolar crest, AC-3: 3 mm apical to the alveolar crest, AC-6: 6 mm apical to the alveolar crest, AC-9: 9 mm apical to the alveolar crest.

Wilcoxon signed ranks test.

^{a)}Statistically significant difference between AC and AC-3, AC-6, and AC-9 at the labial plates of the maxillary central incisors (*P*<0.05).

Table 2. The thickness of the labial and lingual plates of mandibular anteriors (n=10).

	Central incisor		Lateral incisor		Canine	
	Labial	Lingual	Labial	Lingual	Labial	Lingual
CEJ-AC	3.104±1.512	3.473±1.292	3.385±1.814	3.174±1.429	3.085±1.920	3.722±1.647
AC	0.867±0.597 ^{a)}	0.707±0.306 ^{a)}	0.880±0.701 ^{a)}	0.662±0.274 ^{a)}	1.175±0.707	0.882±0.787
AC-3	1.138±0.791	1.107±0.407	1.043±0.623	1.606±0.834	1.178±0.859	2.243±1.401
AC-6	1.398±0.792	2.535±1.375	1.310±0.812	2.648±0.882	1.466±1.032	3.416±1.616
AC-9	2.505±1.303	3.445±1.197	2.260±1.369	3.469±0.579	2.144±1.077	4.375±2.001

Values are presented as mean±SD mm.

CEJ-AC: the distance between cementoenamel junction and alveolar crest, AC: alveolar crest, AC-3: 3 mm apical to the alveolar crest, AC-6: 6 mm apical to the alveolar crest, AC-9: 9 mm apical to the alveolar crest.

Wilcoxon signed ranks test.

^{a)}Statistically significant difference between AC and AC-3, AC-6, and AC-9 in mandibular central incisors and mandibular lateral incisors (*P*<0.05).

mm, 3.41 ± 1.61 mm, and 4.37 ± 2.00 mm at the crest, AC-3, AC-6, and AC-9, respectively.

DISCUSSION

The present study reveals that the thickness of the buccal and lingual plates of the anterior teeth seems to be very thin. The thickness of labial plates in the maxillary central incisor, the mandibular central incisor, and the mandibular lateral incisor was thinnest at the alveolar crest ($P < 0.05$). Therefore, great caution is needed in the immediate placement of implants in the anterior region. If there are bony defects, an even more cautious approach is needed. Immediate implant placement into tooth sockets is increasingly being applied to the replacement of teeth in the maxillary anterior region where esthetics are important, even though some studies [11,12] have shown that immediate implant placement did not prevent bone resorption. Additionally, it has been reported that bone to implant contact established during the early phase of socket healing following implant installation was in part lost when the buccal bone wall underwent continued resorption [23].

Marginal loss of osseointegration at the buccal aspect may result in poor esthetics. To overcome these problems, several researchers have recommended placing the implant into the extraction sockets with minimal flap elevation [15] or without elevation of surgical flaps [16]. In dog studies, flap exposure during periodontal mucoperiosteal procedures resulted in 2 to 4 mm of crestal bone loss [24,25]. This bone loss may result from bone exposure and trauma during flap reflection and manipulation. On the other hand, it was reported that immediate placement without flap elevation did not prevent marginal mucosal recession from occurring [17]. It has been suggested that increasing the thickness of the facial mucosa with the addition of a connective tissue graft beneath the facial flap at the time of implant placement may reduce this risk of recession [26]. However, Chen et al. [17] failed to show that the addition of a connective tissue graft at the time of surgery had any influence on the incidence or extent of mucosal recession. They showed that other clinical factors, including initial gingival health, the presence of facial sinus, the condition of the facial bone, and the state of transmucosal contour in the definitive crown, did not have a significant effect on marginal mucosa changes.

There has also been an ongoing debate over the appropriate procedure to use for tooth extraction - flapless or following flap elevation [27]. A recent study in this area showed no difference between the two approaches [28]. However, studies that have reported bone loss following tooth extraction were performed only on the posterior area in dogs. There-

fore, this mechanical trauma may cause more bone loss in the anterior than the posterior area.

To achieve esthetic success, it is necessary to consider an ideal three-dimensional position [18], to maintain adequate buccal bone over the implant buccal surface [19,20], and to understand tissue biotype [5]. However, it seems that the thickness of the buccal plate in the anterior area is too thin to resorb after tooth extraction.

In the present study, the labial plate thickness of the maxillary central incisor, the mandibular central incisor, and the mandibular lateral incisor was thinnest at the alveolar crest ($P < 0.05$). This, in line with the hypothesis of Araujo et al. [10-12], explains why the buccal plate is easily resorbed after tooth extraction. The thickness of the buccal plate of the maxillary anterior teeth was thicker than that of the mandibular anterior teeth. In the present study, the thickness of the buccal plate was a little thicker than that of the palatal plate in the maxillary anterior teeth. This was not consistent with the previous study [21]. They reported that the thickness of the buccal cortical plate was 1.59 ± 0.7 mm and the thickness of the lingual cortical plate was 1.95 ± 0.70 mm in the dentate maxilla. In this study, the thickness of the buccal plate at the alveolar crest was 0.97 ± 0.18 mm, 0.78 ± 0.21 mm, and 0.95 ± 0.35 mm in the maxillary central incisors, lateral incisors, and canines, respectively. The thickness of the palatal plate at the alveolar crest was 0.82 ± 0.26 mm, 0.98 ± 0.45 mm, and 0.72 ± 0.45 mm in the maxillary central incisors, lateral incisors, and canines, respectively. There was no fenestration in this study, and it was assumed that the observations were due to their thick gingival biotype.

It is advisable to use immediate implant placement only in well-selected patients with a low risk profile. Therefore, to reduce risks before implant placement, we investigated the relationship between gingival biotype and bone thickness in the present study. However, as we excluded subjects who had a missing tooth, only five subjects were included in the present study. Four of five specimens had a thick gingival biotype. It was concluded that the teeth were likely not lost because of the thick biotype. Therefore, it was impossible to show a relationship between the gingival biotype and the bone thickness, as a consequence of a lack of sample size and variety.

The labial and lingual bone thickness of the anterior is very important for esthetic implant therapy. The thickness of the labial plate in the maxillary anterior seems to be very thin, and hence great caution is needed when placing an implant. The present study provides valuable data on bone thickness of maxillary and mandibular anteriors at different positions. It is hoped that these data may provide a basis for further studies in the field to develop a better understanding of the

bone thickness of anteriors.

CONFLICT OF INTEREST

No potential conflict of interest relevant to this article was reported.

ACKNOWLEDGEMENTS

The authors are indebted to Professor Hwang, Se Jin in the Department of Anatomy and Cell Biology in Hanyang University. The competent contributions of KH Kim, JJ Song, TY Lim, and SH Jeon are highly appreciated for excellent technical assistance.

REFERENCES

- Blanes RJ, Bernard JP, Blanes ZM, Belser UC. A 10-year prospective study of ITI dental implants placed in the posterior region. II: influence of the crown-to-implant ratio and different prosthetic treatment modalities on crestal bone loss. *Clin Oral Implants Res* 2007;18:707-14.
- Tolstunov L. Implant zones of the jaws: implant location and related success rate. *J Oral Implantol* 2007;33:211-20.
- Evans CD, Chen ST. Esthetic outcomes of immediate implant placements. *Clin Oral Implants Res* 2008;19:73-80.
- Lazzara RJ. Immediate implant placement into extraction sites: surgical and restorative advantages. *Int J Periodontics Restorative Dent* 1989;9:332-43.
- Kan JY, Rungcharassaeng K, Umezue K, Kois JC. Dimensions of peri-implant mucosa: an evaluation of maxillary anterior single implants in humans. *J Periodontol* 2003;74:557-62.
- Chen ST, Darby IB, Reynolds EC. A prospective clinical study of non-submerged immediate implants: clinical outcomes and esthetic results. *Clin Oral Implants Res* 2007;18:552-62.
- Wheeler SL, Vogel RE, Casellini R. Tissue preservation and maintenance of optimum esthetics: a clinical report. *Int J Oral Maxillofac Implants* 2000;15:265-71.
- Becker BE, Becker W, Ricci A, Geurs N. A prospective clinical trial of endosseous screw-shaped implants placed at the time of tooth extraction without augmentation. *J Periodontol* 1998;69:920-6.
- Paolantonio M, Dolci M, Scarano A, d'Archivio D, di Placido G, Tumini V, et al. Immediate implantation in fresh extraction sockets. A controlled clinical and histological study in man. *J Periodontol* 2001;72:1560-71.
- Araújo MG, Lindhe J. Dimensional ridge alterations following tooth extraction. An experimental study in the dog. *J Clin Periodontol* 2005;32:212-8.
- Araújo MG, Sukekava F, Wennström JL, Lindhe J. Ridge alterations following implant placement in fresh extraction sockets: an experimental study in the dog. *J Clin Periodontol* 2005;32:645-52.
- Araújo MG, Wennström JL, Lindhe J. Modeling of the buccal and lingual bone walls of fresh extraction sites following implant installation. *Clin Oral Implants Res* 2006;17:606-14.
- Botticelli D, Berglundh T, Lindhe J. The influence of a bio-material on the closure of a marginal hard tissue defect adjacent to implants. An experimental study in the dog. *Clin Oral Implants Res* 2004;15:285-92.
- Botticelli D, Persson LG, Lindhe J, Berglundh T. Bone tissue formation adjacent to implants placed in fresh extraction sockets: an experimental study in dogs. *Clin Oral Implants Res* 2006;17:351-8.
- Becker W, Goldstein M, Becker BE, Sennerby L. Minimally invasive flapless implant surgery: a prospective multicenter study. *Clin Implant Dent Relat Res* 2005;7 Suppl 1: S21-7.
- Schwartz-Arad D, Chaushu G. Immediate implant placement: a procedure without incisions. *J Periodontol* 1998;69:743-50.
- Chen ST, Darby IB, Reynolds EC, Clement JG. Immediate implant placement postextraction without flap elevation. *J Periodontol* 2009;80:163-72.
- Buser D, Martin W, Belser UC. Optimizing esthetics for implant restorations in the anterior maxilla: anatomic and surgical considerations. *Int J Oral Maxillofac Implants* 2004;19 Suppl:43-61.
- Grunder U, Gracis S, Capelli M. Influence of the 3-D bone-to-implant relationship on esthetics. *Int J Periodontics Restorative Dent* 2005;25:113-9.
- Ferrus J, Cecchinato D, Pjetursson EB, Lang NP, Sanz M, Lindhe J. Factors influencing ridge alterations following immediate implant placement into extraction sockets. *Clin Oral Implants Res* 2010;21:22-9.
- Katranji A, Misch K, Wang HL. Cortical bone thickness in dentate and edentulous human cadavers. *J Periodontol* 2007;78:874-8.
- Kan JY, Morimoto T, Rungcharassaeng K, Roe P, Smith DH. Gingival biotype assessment in the esthetic zone: visual versus direct measurement. *Int J Periodontics Restorative Dent* 2010;30:237-43.
- Araújo MG, Sukekava F, Wennström JL, Lindhe J. Tissue modeling following implant placement in fresh extraction sockets. *Clin Oral Implants Res* 2006;17:615-24.
- Pennel BM, King KO, Wilderman MN, Barron JM. Repair of the alveolar process following osseous surgery. *J Peri-*

- odontol 1967;38:426-31.
25. Wilderman MN, Pennel BM, King K, Barron JM. Histogenesis of repair following osseous surgery. *J Periodontol* 1970;41:551-65.
 26. Kan JY, Rungcharassaeng K, Lozada JL. Bilaminar subepithelial connective tissue grafts for immediate implant placement and provisionalization in the esthetic zone. *J Calif Dent Assoc* 2005;33:865-71.
 27. Fickl S, Zuhr O, Wachtel H, Bolz W, Huerzeler M. Tissue alterations after tooth extraction with and without surgical trauma: a volumetric study in the beagle dog. *J Clin Periodontol* 2008;35:356-63.
 28. Araújo MG, Lindhe J. Ridge alterations following tooth extraction with and without flap elevation: an experimental study in the dog. *Clin Oral Implants Res* 2009;20:545-9.