



# Efficacy and Safety of Long-Term Intravenous Tranexamic Acid Administration for Blood Management in Revision Surgery for Femoral Shaft Nonunion: A Retrospective Case-Control Study

Clinical and Applied  
Thrombosis/Hemostasis  
Volume 27: 1-9  
© The Author(s) 2021  
Article reuse guidelines:  
sagepub.com/journals-permissions  
DOI: 10.1177/10760296211002277  
journals.sagepub.com/home/cat  


Zhimeng Wang, MD<sup>1</sup> , Yao Lu, MD<sup>1,2,3</sup>, Qiang Huang, MD<sup>1</sup>, Hanzhong Xue, MM<sup>1</sup>, Cheng Ran, MD<sup>1</sup>, Qian Wang, MD<sup>1</sup>, Teng Ma, MD<sup>1</sup>, Kun Zhang, MD<sup>1</sup>, Zhong Li, MD<sup>1</sup>, and Liang Sun, MD<sup>1</sup>

## Abstract

Femoral shaft nonunion is a complication that seriously affects physiological functions. We aimed to assess the effectiveness and safety of short- and long-term intravenous tranexamic acid (TXA) administration in the perioperative period of revision surgery for femoral shaft nonunion. In this retrospective study, 53 patients undergoing double-locking plates with channel bone grafting technology for the treatment of femoral shaft nonunion were divided into 3 groups: the patients in group A without use TXA during hospitalization, the patients in group B received intravenous (IV) 1-g TXA at 30 min before the surgery and deep soaked 1-g TXA for 5 min before closing the incision, and then 1-g TXA IV again 6 h after surgery, and the patients in group C received 1-g TXA IV before the operation, 1-g TXA topically during the operation, and subsequent long-term 1-g TXA IV until discharged. The primary outcomes were total blood loss (TBL) and hidden blood loss (HBL). The secondary outcomes included actual hemoglobin (Hb) loss values, transfusion requirement, number of units transfused, postoperative laboratory values (Hb, hematocrit, fibrinogen, and D-dimer), visual analogue scale (VAS) scores, and hospitalization time. The mean TBL was lower in group C than in group A (1168 mL vs. 2714 mL,  $P < 0.001$ ) and group B (1168 mL vs. 1557 mL,  $P = 0.008$ ). The differences in HBL volumes were also significant between groups A and C ( $P < 0.001$ ) and between groups A and B ( $P < 0.01$ ). The actual Hb loss in the 3 groups showed a consistent trend with TBL, but no significant differences between groups B and C ( $P = 0.23$ ). On postoperative day (POD) 3, the Hb level was higher in group C than in group A (111.1 g/L vs. 94.6 g/L,  $P = 0.02$ ). No significant differences were found in VAS, hospital stay, thromboembolic complications, incision-related complications, and TXA adverse reactions among groups. Long-term intravenous TXA during hospitalization can effectively reduce perioperative blood loss, Hb drop, and postoperative hyperfibrinolysis, but is associated with an increased incidence of adverse reactions.

## Keywords

femoral shaft nonunion, tranexamic acid, blood management, blood loss

Date received: 10 February 2021; revised: 10 February 2021; accepted: 22 February 2021.

<sup>1</sup> Department of Orthopaedics and Trauma, Hong Hui Hospital, Xi'an Jiaotong University College of Medicine, Xi'an, Shaanxi, People's Republic of China

<sup>2</sup> The Key Laboratory of Biomedical Information Engineering of Ministry of Education, School of Life Science and Technology, Xi'an Jiaotong University, Xi'an, People's Republic of China

<sup>3</sup> Bioinspired Engineering and Biomechanics Center (BEBC), Xi'an Jiaotong University, Xi'an, People's Republic of China

## Corresponding Authors:

Zhong Li and Liang Sun, Department of Orthopaedics and Trauma, Hong Hui Hospital, Xi'an Jiaotong University College of Medicine, Xi'an, Shaanxi 710000, People's Republic of China.

Emails: lizhong0607@126.com; 798410671@qq.com



Creative Commons Non Commercial CC BY-NC: This article is distributed under the terms of the Creative Commons

Attribution-NonCommercial 4.0 License (<https://creativecommons.org/licenses/by-nc/4.0/>) which permits non-commercial use, reproduction and distribution of the work without further permission provided the original work is attributed as specified on the SAGE and Open Access pages (<https://us.sagepub.com/en-us/nam/open-access-at-sage>).

## Introduction

Femoral shaft fractures are common in the clinical setting, with an incidence of approximately 6% to 10% and a cure rate of approximately 99% after surgical treatment.<sup>1-3</sup> However, because the medical level and equipment of Chinese primary hospitals are not highly advanced, iatrogenic errors such as incorrect timing of surgery, incorrect fixation principles, and premature postoperative weight-bearing exercise time are considered accountable for bone nonunion.<sup>4,5</sup> Therefore, nonunion is more common in China than reported in the literature.<sup>6,7</sup> Femoral shaft nonunion is a highly morbid complication that aggravates pain, disability, and financial burden, and has a devastating impact on the quality of life.<sup>4,6-8</sup>

Owing to its poor prognosis, nonunion may require multiple operations; thus, it has become a treatment dilemma for surgeons and has greatly burdened patients' physical function and the economy.<sup>9,10</sup> Therefore, finding an effective treatment for femoral shaft nonunion is of great importance. Currently, surgery is still the most important and effective method for treating femoral shaft nonunion, including nail motorization, exchange nailing, retention of additional steel plates for intramedullary nails, and external fixation, along with some auxiliary methods such as ultrasound stimulation, autologous bone grafting, bone morphogenetic protein, and bisphosphonate therapy.<sup>11-20</sup> The double-locking plates with the channel bone grafting technology adopted by our research department have the following unique advantages over the other schemes: (1) no further expansion of the medullary cavity is needed when cleaning the fractured medullary cavity to protect the intramedullary blood supply; (2) the broken end of the fracture nourishes the blood vessels, does not affect the blood circulation of the broken end, and helps in healing; (3) the poor stability of single-plate fixation is avoided, and the broken end becomes absolutely stable; (4) maximize the biological effects of bone and soft tissue and reduces the risk of mobility impairment after surgery. This protocol has now become the first choice of treatment for femoral shaft nonunion in our department.<sup>21</sup>

However, when we collected clinical data on femoral shaft nonunion, we found that perioperative apparent blood loss volume was not consistent with the hemoglobin (Hb) reduction value, which may be related to the use of antifibrinolytic drugs (TXA). Subsequently, we found that the TXA regimen in our department was divided into 2 types, short- and long-term, but no study has reported on the relationship between perioperative blood loss during femoral shaft nonunion revision surgery and TXA. Therefore, the purpose of this study was to assess the benefits and risks of short- and long-term use of TXA in the treatment of femoral shaft nonunion with those using double-locking plates with channel bone graft technology, and to provide a reference for surgeons.

## Methods

### Patients

This retrospective study included patients with femoral shaft nonunion who were treated using double-locking plates with

channel bone graft technology at the Hong Hui Hospital Affiliated to Xi'an Jiaotong University, Xi'an China, from July 2015 to September 2020. This study was approved by the Ethics Committee of our hospital (No: 201606008) and conducted in accordance with the Declaration of Helsinki. All participating patients provided informed consent by signing a written informed consent form.

The patients were sequentially enrolled according to the following inclusion criteria: (i) patients aged >18 years; (ii) patients treated with internal fixation and implantation due to femoral shaft fracture with subsequently developed aseptic nonunion, which was diagnosed by the chief surgeons on the basis of imaging and physical examinations. Nonunion was defined according to the US Food and Drug Administration (FDA) criteria as a fracture that had not healed within 9 months after the last surgery or had not shown any signs of healing for 3 consecutive months.<sup>22</sup>

The exclusion criteria were as follows: (i) patients with severe brain, heart, liver, and kidney dysfunction who could not tolerate surgery; (ii) patients with no signs of infection during the preoperative laboratory examinations, with low-toxicity infections at the fracture ends during the operation that required a change in surgical plan; (iii) nonunion of the proximal or distal femur; (iv) allergy to intravenous (IV) TXA; and (v) long-term use of anticoagulants before surgery.

Patients were divided according to the perioperative TXA treatment course. Group A included patients who were not given TXA because TXA was not introduced in our department before 2016. Group B received 1-g TXA IV 30 min before surgery, deep soaked 1-g TXA for 5 min before closing the incision, and 1-g TXA IV again 6 h after surgery. This is the routine TXA treatment plan of orthopedic physicians in our department. Lastly, group C received 1-g TXA IV before the operation, 1-g TXA topically during the operation, and subsequent long-term 1-g TXA IV until discharge. This is the empirical TXA treatment plan of some orthopedic physicians in our department.

### Surgical Procedure

**Preoperative management.** In this study, channel bone grafting technology combined with double-locking plates was used in all patients to treat nonunion under general anesthesia. All 3 groups of patients received IV antibiotics as preventive treatment 30 min before surgery. Groups B and C received 1-g TXA IV, and the other IV administration in the 3 groups was the same. The pressure of the balloon-type tourniquet on the affected limb was set to 450 mmHg, and the mean arterial blood pressure (MAP) was maintained at 60-70 mmHg.

**Original internal fixation treatment and incision position design.** For patients in whom bone plates or intramedullary nails were previously used for open reduction, an incision was made along the original surgical skin incision to expose and then remove the internal fixation. If the patient had previously fixed with intramedullary nails for closed reduction, a 20-cm longitudinal skin incision was made on the anterolateral or outer side of the

affected limb, and then the previous internal fixation device was removed.

**Treatment of fractured ends in nonunion and placement of locking plates.** The Judet periosteal peeling technique is used to expose the fractured ends of the nonunion. Under the premise of protecting the surrounding soft tissue and periosteum, the scar tissue between the fractured ends is completely removed, and some hardened dead bones are retained. The length recovery of the affected limb is determined by measuring the length of the contralateral side, while anatomical axis restoration is judged by the thickness of the distal and proximal bone cortex of the broken end, the intraoperative C-arm X-ray fluoroscopy, and limb shape. After the normal force line and length of the limbs are restored, the locking plate (Depuy Synthes, USA) is used for lateral cortical bridging and fixed, and at least 6 layers of cortex are fixed with screws.

**A specific type of autologous iliac crest block graft and bone slab placement.** A 3.5 mm drill is used to make holes at the front, cortical bone side of fracture end to form a slotted marking area with a width of approximately 1.0 to 1.5 cm and a length of about 3 to 10 cm. Slotting is then performed across the fractured end of the nonunion and extends beyond the fractured ends. Having obvious fresh blood seeping from the bone grooves both near and far, which is a positive paprika sign, is advisable. The length of the bone groove is measured, and the corresponding length of the uni- or bi-cortical iliac crest bone is then filled into the bone groove after trimming. Cancellous bone particles are produced from the ipsilateral iliac bone filling the posterior, lateral, and medial gaps of the femur fractured ends.

Once adequate bone grafting is achieved within the medullary cavity, a reconstruction bone plate (Depuy Synthes, USA) is placed at the front side of the bone graft; it is advisable that the screw penetrates at least 4 layers of the cortex.

**Stability testing and closure incision.** After checking the anatomical axis and length of the affected limb again, stability testing is performed by flexion and extension on the surgical side to check that there is no micro-motion at the fractured end. The wound is thoroughly irrigated with saline, and then 1 g TXA is used in Groups B and C, to soak the wound for 5 min. The incision is repaired anatomically with a continuous suture (2-0 absorbable suture; Ethicon Inc. Johnson & Johnson, USA), closing the wound in layers in a standard manner. One drainage tube is embedded in the incision.

**Postoperative treatment.** Antibiotics (Ceftazidime, IV 2.0 g Bid) are used as a preventive measure during the operation and on postoperative day (POD) 1. All patients were treated with anticoagulants (Enoxaparin, IH 20 mg qd) and intermittent compression boots as preventive treatment for lower extremity venous thrombosis during hospitalization, and then treated with oral-anticoagulants (Rivaroxaban, OP 10 mg qd) until 35 days after discharge. In patients with a history of DVT, enoxaparin, 40 mg subcutaneously daily during hospitalization. After

discharged, oral rivaroxaban 20 mg daily until 35 days. Group B received 1-g TXA IV 6 hours after surgery, while group C received long-term 1-g TXA IV (from the first day after surgery, every day at 8 am until discharge). The drainage tube is preserved for 48 h, and after it is pulled out, active muscle isometric contraction and knee joint function exercise are started. From the third day after the operation, continuous passive motion is used to restore hip and knee joint activities until discharge. During this period, no weight-bearing activities are allowed. According to the X-ray results, once an external callus is formed, the patient could use crutches to walk with partial weight-bearing. Full weight-bearing walking is initiated after complete bone union is achieved.

The red blood cell transfusion indications formulated by the guidelines of the Chinese Ministry of Health were as follows: (i) Hb level < 70 g/L; (ii) 70 g/L < Hb level < 100 g/L, when the patient has symptoms of dizziness, palpitation, asthma, and fatigue. Whether the patient needed blood transfusion was determined by a chief physician who was not involved in the study.

## Outcome Measurements

**Characteristics.** Patient characteristics included age, sex, affected side, height, weight, body mass index (BMI), American Society of Anesthesiologists (ASA) classification, and preoperative blood volume (PBV). The laboratory examination data collected included preoperative Hb, hematocrit, D-dimer, and fibrinogen (FIB) levels. The imaging examination data collected included the nonunion location (upper and middle, middle, or middle and lower), nonunion type (atrophic/hyper-trophic), and original internal fixation.

**Primary outcome.** Perioperative total blood loss (TBL) and hidden blood loss (HBL) were the primary outcomes in the present study. TBL was calculated by applying the Gross formula<sup>23</sup> as follows:

$$\text{Total blood loss} = \text{PBV} \times (\text{Hct}_1 - \text{Hct}_2) / \text{Hct}_{\text{ave}} + \text{Hb}_{\text{trans}}$$

PBV = preoperative blood volume

Hct<sub>1</sub> = the initial hematocrit level at admission

Hct<sub>2</sub> = the lowest postoperative hematocrit level for patients without blood transfusion or the lowest hematocrit level prior to blood transfusion

Hct<sub>ave</sub> = the average of Hct<sub>1</sub> and Hct<sub>2</sub>

The preoperative blood volume (PBV) was calculated by Nadler's equation<sup>24</sup> as follows:

$$\text{PBV} = K_1 \times h^3 + K_2 \times w + K_3, [h : \text{height(m)}, w : \text{weight(kg)}];$$

For male patients,  $K_1 = 0.3669$ ,  $K_2 = 0.03219$ , and  $K_3 = 0.6041$

For female patients,  $K_1 = 0.3561$ ,  $K_2 = 0.03308$ , and  $K_3 = 0.1833$

HBL was calculated as follows:  
 $HBL (mL) = TBL - IBL - TPD$

Intraoperative blood loss (IBL) was estimated from the weight of the surgical sponges and the measurement of the volume of blood collected by the suction canisters. The volume of the irrigation fluids added to the surgical field and the sponge volume were then subtract from this value. The total postoperative drainage (TPD) was the volume of fluid in the drainage bag collected over 48 h.

**Secondary outcomes.** The secondary outcomes included actual Hb decrease, transfusion requirement, number of units transfused, and postoperative laboratory values (Hb, hematocrit, FIB, and D-dimer).

Postoperative VAS pain score and hospitalization time were also assessed as secondary outcomes. Reviewing the previous literature and our own experience, the patient's Hb level often drops to the lowest level on the third day after orthopedic surgery.<sup>25</sup> Therefore, in the current study, we defaulted to POD3 to calculate the total perioperative blood loss. Complications [e.g., deep vein thrombosis (DVT), pulmonary embolism (PE), wound complications, and TXA adverse reactions] were recorded within 4 weeks post-surgery. IV ultrasound of both lower extremities was performed at admission, POD 1, POD 3, discharge, and after 4 weeks.

### Statistical Analysis

Statistical analyses were computed using GraphPad Prism 8.0. Continuous variables were reported as means and standard deviations. One-way analysis of variance (ANOVA) was used to compare the differences among multiple groups. Student's *t*-test was used to compare the differences between 2 groups, and the chi-square or Fisher test was used for the analysis of categorical data. *P* values < 0.05 were considered to indicate a statistically significant difference.

## Results

### Patient Demographics

A total of 53 patients were treated with double-locking plates with channel bone grafting technology, including 15 in Group A, 15 in Group B, and 23 in Group C. No significant differences in demographic data, imaging, and laboratory data at admission were found among the 3 groups (Table 1).

### Primary Outcome

The mean TBL was  $2714 \pm 999$  mL (range: 1236 mL-4363 mL) in group A,  $1557 \pm 418$  mL (range: 835 mL-2235 mL) in group B, and  $1168 \pm 415$  mL (range from 423 mL-2191 mL) in group C, with significant differences among the 3 groups ( $P < 0.001$ ). The pairwise comparisons and statistical analyses between the groups showed statistically significant differences. Similar

**Table 1.** Patient Demographic Data, Imaging Data and Laboratory Values.

Variable	Group A	Group B	Group C	<i>P</i> value
<b>Patient characteristics</b>				
Age (yr) <sup>a</sup>	$47.6 \pm 12.7$	$43.8 \pm 15.4$	$45.8 \pm 15.7$	0.78
Gender (male/ female) <sup>b</sup>	6/9	8/7	12/11	0.71
Height (cm) <sup>a</sup>	$157.4 \pm 10.1$	$161.1 \pm 5.5$	$159.5 \pm 9.3$	0.51
Weight (kg) <sup>a</sup>	$65.3 \pm 7.1$	$60.9 \pm 10.4$	$63.4 \pm 5.8$	0.30
BMI (kg/m <sup>2</sup> ) <sup>a</sup>	$25.1 \pm 5.4$	$24.3 \pm 3.5$	$25.5 \pm 4.7$	0.74
PBV (L) <sup>a</sup>	$4.4 \pm 0.5$	$4.7 \pm 0.6$	$4.5 \pm 0.6$	0.45
Operated side (L/R) <sup>b</sup>	8/7	5/10	9/14	0.51
<b>ASA classification<sup>b</sup></b>				
I	9	7	12	0.83
II	4	7	8	
III	2	1	3	
<b>Fracture type<sup>b</sup></b>				
32-A	3	4	6	0.58
32-B	6	3	10	
32-C	6	8	7	
<b>Fracture site<sup>b</sup></b>				
Upper and middle	2	4	6	0.80
Middle	12	9	15	
Middle and lower	1	2	2	
<b>Original internal fixation<sup>b</sup></b>				
Intramedullary nail	6	4	9	0.68
Plate	9	11	14	
<b>Nonunion type<sup>b</sup></b>				
Hypertrophic	6	5	9	0.92
Atrophic	9	10	14	
<b>Preoperative blood tests<sup>a</sup></b>				
Hb (g/L)	$146.9 \pm 14.9$	$139.1 \pm 18.0$	$142.9 \pm 16.4$	0.44
Hct (%)	$43.7 \pm 3.5$	$42.2 \pm 4.6$	$42.9 \pm 4.1$	0.61
D-dimer (mg/L)	$0.7 \pm 0.5$	$0.4 \pm 0.2$	$0.6 \pm 0.4$	0.11
FIB (g/L)	$2.7 \pm 0.6$	$3.2 \pm 0.9$	$3.4 \pm 1.3$	0.13

Abbreviations: BMI, body mass index; PBV, preoperative blood volume; ASA, American Society of Anesthesiologists; Hb, hemoglobin; Hct, hematocrit; FIB, fibrinogen.

Intergroup comparisons were performed using ANOVA, Chi-square test, or Fisher test (<sup>a</sup>ANOVA; <sup>b</sup>Chi-square test or Fisher).

results were also obtained for HBL, with HBL values of  $1566 \pm 864$  mL,  $724 \pm 210$  mL, and  $548 \pm 200$  mL in groups A, B, and C, respectively (Table 2 and Figure 1).

### Secondary Outcomes

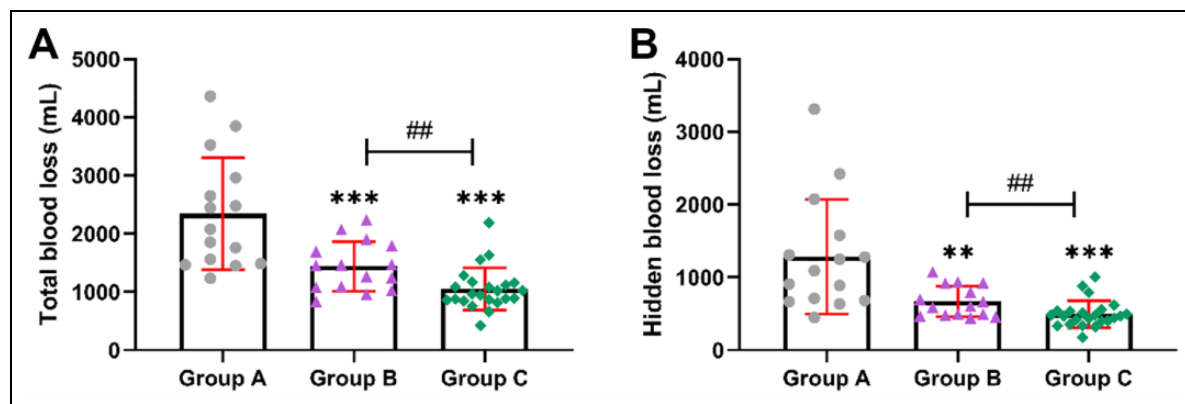
**Actual Hb loss.** The actual Hb loss was  $52.3 \pm 20.9$  g/L in group A,  $35.3 \pm 13.0$  g/L in group B, and  $29.4 \pm 15.5$  g/L in group C ( $P < 0.001$ ), with a significant difference between Groups A and B ( $P < 0.01$ ) and between groups A and C ( $P < 0.001$ ). We found no statistically significant difference between groups B and C ( $P = 0.23$ ; Table 2).

**Table 2.** Comparison of the Primary and Secondary Results of the 3 Groups.

Variable	Group A	Group B	Group C	P value	Intergroup comparison		
					P <sub>1</sub>	P <sub>2</sub>	P <sub>3</sub>
<b>Primary outcomes<sup>a</sup></b>							
TBL (mL)	2714 ± 999	1557 ± 418	1168 ± 415	<0.001	<0.001	<0.001	0.008
HBL (mL)	1566 ± 864	724 ± 210	548 ± 200	<0.001	0.001	<0.001	<0.01
<b>Secondary outcomes</b>							
Actual Hb loss (g/L) <sup>a</sup>	52.3 ± 20.9	35.3 ± 13.0	29.4 ± 15.5	<0.001	<0.01	<0.001	0.23
Patients requiring transfusion <sup>b</sup>	12 (80.0)	4 (26.7)	5 (21.7)	0.001	0.003	<0.001	0.73
Units transfused (IU)	3.3	2.5	3.2	NA	-	-	-
<b>Postop. laboratory values</b>							
Hb (g/L) <sup>a</sup>							
POD#1	116.7 ± 13.5	113.1 ± 14.5	115.9 ± 22.0	0.84	-	-	-
POD#3	94.6 ± 21.1	103.8 ± 14.5	111.1 ± 18.9	0.03	0.18	0.02	0.21
Hct (%) <sup>a</sup>							
POD#1	34.3 ± 3.6	33.9 ± 4.1	34.2 ± 6.1	0.97	-	-	-
POD#3	28.0 ± 5.9	30.2 ± 4.1	33.0 ± 5.4	0.02	0.25	<0.01	0.10
D-dimer (mg/L) <sup>a</sup>							
POD#1	6.3 ± 2.2	4.6 ± 2.6	4.6 ± 1.9	0.04	0.06	0.02	1.00
POD#3	5.1 ± 1.4	3.8 ± 1.1	3.3 ± 0.9	<0.001	0.01	<0.001	0.13
FIB (g/L) <sup>a</sup>							
POD#1	8.7 ± 2.8	5.4 ± 1.9	5.9 ± 2.5	<0.001	<0.001	<0.001	0.51
POD#3	7.2 ± 1.9	5.1 ± 2.1	5.8 ± 1.3	<0.01	<0.01	0.01	0.21
VAS pain score <sup>a</sup>							
POD#1	4.3 ± 1.4	3.8 ± 0.9	3.6 ± 1.1	0.19	-	-	-
POD#3	2.5 ± 0.9	2.4 ± 0.9	2.4 ± 0.7	0.92	-	-	-
Hospitalization duration <sup>a</sup> (d)							
	6.7 ± 1.4	5.9 ± 1.5	5.6 ± 0.8	0.03	0.14	<0.01	0.43

Abbreviations: TBL, total blood loss; HBL, hidden blood loss; Hb, hemoglobin; Hct, hematocrit; FIB, fibrinogen; POD#1, first postoperative day; POD#3, third postoperative day.

Intergroup comparisons were performed using ANOVA, Chi-square test, or Fisher test (<sup>a</sup>ANOVA; <sup>b</sup>Chi-square test or Fisher).



**Figure 1.** Comparison of TBL and HBL among the 3 groups. \*\*\* indicated  $P < 0.001$  (Group B or Group C vs Group A); ## indicated  $P < 0.01$  (Group B vs Group C). Intergroup comparisons were performed using ANOVA.

**Patients requiring transfusion and number of units transfused.** The number of patients per group who needed blood transfusion was as follows: 12 (80.0%, 3.3 U) in group A, 4 (26.4%, 2.5 U) in group B, and 5 (21.7%, 3.2 U) in group C. Significant differences were observed among the 3 groups of patients requiring transfusion ( $P = 0.001$ ). This is believed to be due to the small number of people included in groups A and B and the fact that only 9 patients required transfusion in groups B and C (23.7%,  $n = 38$ ; Table 2).

**Postoperative laboratory values.** No significant differences in the Hb and hematocrit levels on POD 1 were found among the 3 groups, but the levels on POD 3 were highest in group C ( $P = 0.03$  and  $P = 0.02$ , respectively). The D-dimer and FIB levels in group C were lowest on PODs 1 and 3, with significant differences (all  $P < 0.05$ ; Table 2).

**VAS pain score and hospitalization duration.** The VAS pain scores on PODs 1 ( $P = 0.19$ ) and 3 ( $P = 0.92$ ) were not significantly

different among the groups. The lengths of hospital stay were 6.7, 5.9, and 5.6 days in groups A, B, and C, respectively ( $P = 0.03$ ). Further comparisons between the groups showed significant differences between groups A and C ( $P < 0.01$ ; Table 2).

**Complications.** Thromboembolic event morbidity, incision-related complications, and TXA adverse reactions did not differ significantly among the 3 groups. However, the patients in group C had the highest incidence of adverse reactions such as peripheral nervous system and digestive system symptoms, but their symptoms improved after the infusion rate or interval administration were decreased (Table 3).

## Discussion

With the popularization of TXA in China, an increasing number of orthopedic surgeons have started using TXA with satisfactory results in clinical practice. Therefore, some professors in my country jointly formulated guidelines on TXA application, such as an expert consensus on enhanced recovery after orthopedic surgery in China, guidelines on perioperative blood management, an expert consensus on perioperative antifibrinolytic drugs, and sequential anticoagulant application programs in hip and knee replacement surgery in China. Several studies have confirmed that perioperative anemia increases the risk of postoperative infection and mortality and length of hospital stay, and significantly affects the quality of life.<sup>26-28</sup> Good perioperative blood management can reduce blood loss and transfusion due to surgical trauma, reduce the incidence of anemia, and maintain a high postoperative Hb level. It is also closely related to postoperative physical function rehabilitation.<sup>29-32</sup> Antifibrinolytic therapy, an important aspect of blood management that is considered to be closely related to the concept of enhanced recovery after surgery (ERAS), has emerged as a particular research focus, and TXA makes this strategy a reality.

Currently, TXA is administered in IV, intramuscular, topical, and oral regimens. As the safety of intramuscular and oral regimens has not yet been supported by a large number of clinical trials, these routes of administration have not been adopted by our institution. A pharmacokinetic study of TXA showed that its half-life is approximately 3 h.<sup>33</sup> However, several clinical studies have shown that the hyperfibrinolytic state of the body that is caused by surgical trauma reaches its peak at 6 h after surgery and continues until 18 to 24 h.<sup>34-36</sup> In addition, the application of postoperative anticoagulants (e.g., enoxaparin or rivaroxaban) may cause new bleeding. These facts indicate that a single-dose application of TXA in the perioperative period does not sufficiently inhibit postoperative hyperfibrinolysis; thus, we believe that administration of multiple dosages of drugs is necessary to inhibit fibrinolysis and reduce blood loss in the perioperative period.

The present study is the first to investigate the reduction of blood loss by TXA administration in the surgical treatment of femoral shaft nonunion. The results showed that with the long-

**Table 3.** Other Complications Including Thromboembolic Events, Wound Complications, and TXA Adverse Reactions.

Variable	Group A	Group B	Group C	P value
Thromboembolic events <sup>a</sup>				
DVT	0	1	1	0.62
PE	0	0	0	-
Incision-related complications <sup>a</sup>				
Ecchymoses	2	1	1	0.59
Hematoma	0	0	0	-
Infection	0	0	0	-
Wound secretion	1	1	0	0.45
TXA adverse reactions <sup>a</sup>				
Nausea or vomiting	0	0	1	0.51
Dizziness or headache	0	2	5	0.15

Abbreviations: DVT, deep vein thrombosis; PE, pulmonary embolism.

<sup>a</sup>Intergroup comparisons performed using Chi-square or Fisher test.

term use of TXA after surgery (Group C), the TBL volumes were lower than those in no TXA group (1168 mL vs 2714 mL,  $P < 0.001$ ) and short-term group (1168 mL vs 1557 mL,  $P = 0.008$ ). On POD 3, the Hb level in long-term group was higher than those in no TXA group and short-term group, indicating that when we prolonged use of TXA could reduce the blood loss from POD 1 to POD 3. The calculation of HBL also confirmed the advantages of prolonged TXA use. The mean HBL volumes in long-term group, short-term group, and no TXA group were 548 mL, 724 mL, and 1566 mL, respectively. The blood coagulation test results showed that the D-dimer and FIB levels in long-term group were lower than those in no TXA group and short-term group on POD 1 and POD 3. In light of the above-mentioned, we believe that long-term empiric use of TXA after revision surgery for femoral shaft nonunion can help inhibit fibrinolysis, thereby reducing perioperative blood loss. Although routine use (short-term group) also reduced perioperative blood loss, and the mean Hb and hematocrit levels on POD 1 in short-term group were not much different from those in long-term group, surgeons who empirically administered TXA believe that the advantage of this regimen is that the patients do not need frequent IV TXA administration on the operation day after general anesthesia.

Some animal models, in vitro experiments, and clinical trials have proven that TXA can reduce the release of inflammatory factors after surgery, thereby reducing postoperative swelling and pain.<sup>37-41</sup> In addition, it also reduces hospitalization costs and shortens hospital stays. However, in the present study, neither short- nor long-term use of TXA showed the advantage of reducing postoperative pain. In the ERAS strategy, postoperative analgesia is administered by the cooperation of surgeons, anesthesiologists, and nursing staff. We believe that the use of TXA alone cannot achieve the desired effect. Another advantage of this empirical use (group C) is that it can shorten the length of hospital stay as compared with that in patients who did not use TXA (group A) ( $P < 0.01$ ). Although our institution has strict requirements on the length of hospital stay for patients, the mean hospital stay was only 5.6 days

(group C). A similar conclusion was reported by Tzatzairis et al,<sup>34</sup> Liang et al,<sup>42</sup> and Xing et al.<sup>43</sup>

Whether the use of TXA will increase the incidence of DVT and PE has always been the focus of surgeons; no unified conclusion has been made yet.<sup>44-46</sup> Thus far, most orthopedic clinical trials have been designed to test the hemostatic effect of TXA instead of its safety. For rare complications such as PE, the current clinical trial sample size cannot provide a definitive conclusion. In this study, the coagulation levels on POD 1 and POD 3 were not significantly different between groups C and B. These results confirmed from another aspect that long-term TXA IV administration is safe. Among the patients who received TXA treatment during the perioperative period (n = 38), 1 patient in group C had nausea or vomiting symptoms, and 7 patients had dizziness or headache symptoms (2 patients in group B; 5 patients in group C). Therefore, long-term IV use of TXA has a dual sword; although it reduces blood loss during the perioperative period, it may also increase the patient's discomfort and anxiety. However, during the course of our research, all the patients still agreed to undergo TXA therapy even after being briefed about the risks (adverse reactions) and benefits (reduced blood loss and blood transfusion) of TXA use.

Despite the encouraging results of the present study, several limitations remain. First, the sample size included in the study was small because most patients did not undergo laboratory tests (hemoglobin, hematocrit, D-dimer, and FIB) on POD#3, they were excluded from the current study. Regarding the blood transfusion rate and number of units transfused, we believe that a larger sample size will better detect the differences between the groups. Second, we did not perform long-term follow-up after surgery, so the safety of long-term TXA use cannot be accurately concluded. Lastly, we did not check the postoperative inflammatory marker levels of these patients, so the relationship between postoperative inflammation and pain cannot be determined.

## Conclusion

This retrospective case-control study proved the advantages of long-term TXA IV administration in the treatment of femoral shaft nonunion involving double-locking plates with channel bone grafting technology, which decreased the blood loss volume and number of transfusion units, maintained the postoperative Hb values. However, attention should be paid to the adverse reactions caused by the TXA IV use.

## Abbreviations

TXA	tranexamic acid
IV	intravenous
TBL	total blood loss
HBL	hidden blood loss
RBC	red blood cell
DVT	deep vein thrombosis
ASA	American Society of Anesthesiologists score
Hb	hemoglobin

Hct	hematocrit
FIB	fibrinogen
BMI	body mass index
VAS	visual analogue scale
PE	pulmonary embolism
PBV	preoperative blood volume
TBL	total blood loss
HBL	hidden blood loss.

## Authors' Note

Zhimeng Wang, Yao Lu, and Qiang Huang contributed equally to this work. ZL and LS were responsible for the study design, the revision for intellectual content, and literature research. ZMW, CR, and YL analyzed and interpreted the data. TM and QW performed the statistical analyses. ZMW, QH, and YL drafted the manuscript. ZL, LS TM, and QW revised the manuscript. All authors have read and approved the final manuscript. All data generated or analyzed during this study are included in this published article. Approval was obtained from the Clinical Trials and Biomedical Ethics Committee of Hong Hui Hospital (Approval No. 201606008), and written informed consent was obtained from all participants.

## Acknowledgment

The authors thank the Project of Science and Technology Department of Shaanxi Province for supporting this work.


## Declaration of Conflicting Interests

The author(s) declared no potential conflicts of interest with respect to the research, authorship, and/or publication of this article.

## Funding

The author(s) disclosed receipt of the following financial support for the research, authorship, and/or publication of this article: This study was supported by the Project of Science and Technology Department of Shaanxi Province (Nos. 2016SF-340, 2017ZDXM-SF-009, and 2019JQ-976).

## ORCID iD

Zhimeng Wang  <https://orcid.org/0000-0002-9791-6861>

## References

1. Agarwal-Harding KJ, Meara JG, Greenberg SL, Hagander LE, Zurakowski D, Dyer GS. Estimating the global incidence of femoral fracture from road traffic collisions: a literature review. *J Bone Jt Surg Am Vol.* 2015;97(6):e31.
2. Wu SC, Rau CS, Kuo SCH, Chien PC, Hsieh CH. The influence of ageing on the incidence and site of trauma femoral fractures: a cross-sectional analysis. *BMC Musculoskelet Disord.* 2019;20(1):413.
3. Brinker MR, O'Connor DP. The incidence of fractures and dislocations referred for orthopaedic services in a capitated population. *J Bone Jt Surg Am Vol.* 2004;86(2):290-297.
4. Rupp M, Biehl C, Budak M, Thormann U, Heiss C, Alt V. Diaphyseal long bone nonunions—types, aetiology, economics, and treatment recommendations. *Int Orthop.* 2018;42(2):247-258.

5. Kubiak EN, Beebe MJ, North K, Hitchcock R, Potter MQ. Early weight bearing after lower extremity fractures in adults. *J Am Acad Orthop Surg.* 2013;21(12):727-738.
6. Ekegren CL, Edwards ER, de Steiger R, Gabbe BJ. Incidence, costs and predictors of non-union, delayed union and mal-union following long bone fracture. *Int J Environ Res Public Health.* 2018;15(12):2845.
7. Koso RE, Terhoeve C, Steen RG, Zura R. Healing, nonunion, and re-operation after internal fixation of diaphyseal and distal femoral fractures: a systematic review and meta-analysis. *Int Orthop.* 2018;42(11):2675-2683.
8. Tay WH, de Steiger R, Richardson M, Gruen R, Balogh ZJ. Health outcomes of delayed union and nonunion of femoral and tibial shaft fractures. *Injury.* 2014;45(10):1653-1658.
9. Schottel PC, O'Connor DP, Brinker MR. Time trade-off as a measure of health-related quality of life: long bone nonunions have a devastating impact. *J Bone Jt Surg Am Vol.* 2015; 97(17):1406-1410.
10. Brinker MR, Hanus BD, Sen M, O'Connor DP. The devastating effects of tibial nonunion on health-related quality of life. *J Bone Jt Surg Am Vol.* 2013;95(24):2170-2176.
11. Gao KD, Huang JH, Tao J, et al. Management of femoral diaphyseal nonunion after nailing with augmentative locked plating and bone graft. *Orthop Surg.* 2011;3(2):83-87.
12. Shroeder JE, Mosheiff R, Khoury A, Liebergall M, Weil YA. The outcome of closed, intramedullary exchange nailing with reamed insertion in the treatment of femoral shaft nonunions. *J Orthop Trauma.* 2009;23(9):653-657.
13. Bell A, Templeman D, Weinlein JC. Nonunion of the femur and tibia: an update. *Orthop Clin North Am.* 2016;47(2):365-375.
14. Zhang Q, Zhang W, Zhang Z, et al. Femoral nonunion with segmental bone defect treated by distraction osteogenesis with monolateral external fixation. *J Orthop Surg Res.* 2017;12(1):183.
15. Gelalis ID, Politis AN, Arnaoutoglou CM, et al. Diagnostic and treatment modalities in nonunions of the femoral shaft: a review. *Injury.* 2012;43(7):980-988.
16. Giannoudis PV, Kanakaris NK, Dimitriou R, Gill I, Kolimarala V, Montgomery RJ. The synergistic effect of autograft and BMP-7 in the treatment of atrophic nonunions. *Clin Orthop Relat Res.* 2009; 467(12):3239-3248.
17. Watanabe Y, Matsushita T. Femoral non-union with malalignment: reconstruction and biological stimulation with the chipping technique. *Injury.* 2016;47(6):S47-s52.
18. Roussignol X, Currey C, Duparc F, Dujardin F. Indications and results for the Exogen™ ultrasound system in the management of non-union: a 59-case pilot study. *Orthop Traumatol Surg Res: OTSR.* 2012;98(2):206-213.
19. Yue B, Ng A, Tang H, Joseph S, Richardson M. Delayed healing of lower limb fractures with bisphosphonate therapy. *Ann R Coll Surg Engl.* 2015;97(5):333-338.
20. Hackl S, Hierholzer C, Friederichs J, Woltmann A, Bühren V, von Räden C. Long-term outcome following additional rhBMP-7 application in revision surgery of aseptic humeral, femoral, and tibial shaft nonunion. *BMC Musculoskelet Disord.* 2017;18(1):342.
21. Sun L, Li Z, Ma T, et al. Treatment of atrophic nonunion via autogenous ilium grafting assisted by vertical fixation of double plates: a case series of patients. *J Int Med Res.* 2019;47(5): 1998-2010.
22. Marsh D. Concepts of fracture union, delayed union, and non-union. *Clin Orthop Relat Res.* 1998;(355 Suppl):S22-30.
23. Gross JB. Estimating allowable blood loss: corrected for dilution. *Anesthesiology.* 1983;58(3):277-280.
24. Nadler SB, Hidalgo JH, Bloch T. Prediction of blood volume in normal human adults. *Surgery.* 1962;51(2):224-232.
25. Lei J, Zhang B, Cong Y, et al. Tranexamic acid reduces hidden blood loss in the treatment of intertrochanteric fractures with PFNA: a single-center randomized controlled trial. *J Orthop Surg Res.* 2017;12(1):124.
26. Smilowitz NR, Oberweis BS, Nukala S, et al. Association between anemia, bleeding, and transfusion with long-term mortality following noncardiac surgery. *Am J Med.* 2016;129(3): 315-323.e312.
27. Sim YE, Sim SD, Seng C, Howe TS, Koh SB, Abdullah HR. Pre-operative anemia, functional outcomes, and quality of life after hip fracture surgery. *J Am Geriatr Soc.* 2018;66(8):1524-1531.
28. Clemmesen CG, Palm H, Foss NB. Delay in detection and treatment of perioperative anemia in hip fracture surgery and its impact on postoperative outcomes. *Injury.* 2019;50(11): 2034-2039.
29. Wang HY, Wang L, Luo ZY, et al. Intravenous and subsequent long-term oral tranexamic acid in enhanced-recovery primary total knee arthroplasty without the application of a tourniquet: a randomized placebo-controlled trial. *BMC Musculoskelet Disord.* 2019;20(1):478.
30. Yu CC, Kadri O, Kadado A, et al. Intravenous and oral tranexamic acid are equivalent at reducing blood loss in thoracolumbar spinal fusion: a prospective randomized trial. *Spine.* 2019;44(11): 755-761.
31. Liao L, Chen Y, Tang Q, Chen YY, Wang WC. Tranexamic acid plus drain-clamping can reduce blood loss in total knee arthroplasty: a systematic review and meta-analysis. *Int J Surg.* 2018; 52:334-341.
32. Wassilew GI, Perka C, Janz V, Krämer M, Renner L. Tranexamic acid reduces the blood loss and blood transfusion requirements following peri-acetabular osteotomy. *Bone Joint J.* 2015;97-b(12):1604-1607.
33. Pilbrant A, Schannong M, Vessman J. Pharmacokinetics and bioavailability of tranexamic acid. *Eur J Clin Pharmacol.* 1981; 20(1):65-72.
34. Tzatzairis T, Drosos GI, Vogiatzaki T, Tilkeridis K, Ververidis A, Kazakos K. Multiple intravenous tranexamic acid doses in total knee arthroplasty without tourniquet: a randomized controlled study. *Arch Orthop Trauma Surg.* 2019;139(6):859-868.
35. Lei Y, Huang Q, Huang Z, Xie J, Chen G, Pei F. Multiple-dose intravenous tranexamic acid further reduces hidden blood loss after total hip arthroplasty: a randomized controlled trial. *J Arthroplast.* 2018;33(9):2940-2945.
36. Cao G, Xie J, Huang Z, et al. Efficacy and safety of multiple boluses of oral versus intravenous tranexamic acid at reducing blood loss after primary total knee arthroplasty without a tourniquet: a prospective randomized clinical trial. *Thromb Res.* 2018; 171:68-73.



37. Carter DW, Prudovsky I, Kacer D, et al. Tranexamic acid suppresses the release of mitochondrial DAMPs and reduces lung inflammation in a murine burn model. *J Trauma Acute Care Surg.* 2019;86(4):617-624.
38. Barrett CD, Moore HB, Kong YW, et al. Tranexamic acid mediates proinflammatory and anti-inflammatory signaling via complement C5a regulation in a plasminogen activator-dependent manner. *J Trauma Acute Care Surg.* 2019;86(1):101-107.
39. Lei YT, Xie JW, Huang Q, Huang W, Pei FX. The antifibrinolytic and anti-inflammatory effects of a high initial-dose tranexamic acid in total knee arthroplasty: a randomized controlled trial. *Int Orthop.* 2020;44(3):477-486.
40. Wang D, Yang Y, He C, et al. Effect of multiple doses of oral tranexamic acid on haemostasis and inflammatory reaction in total hip arthroplasty: a randomized controlled trial. *Thromb Haemost.* 2019;119(1):92-103.
41. Tang Y, Wen Y, Li W, Li H, Yang Y, Liu Y. The efficacy and safety of multiple doses of oral tranexamic acid on blood loss, inflammatory and fibrinolysis response following total knee arthroplasty: a randomized controlled trial. *Int J Surg.* 2019;65:45-51.
42. Liang JQ, Rong TH, Liu HZ, et al. Topical injection of tranexamic acid via a drain plus drain-clamping to reduce blood loss in degenerative lumbar scoliosis surgery. *Orthop Surg.* 2020;12(1):67-73.
43. Xing F, Chen W, Long C, Huang F, Wang G, Xiang Z. Post-operative outcomes of tranexamic acid use in geriatric trauma patients treated with proximal femoral intramedullary nails: a systematic review and meta-analysis. *Orthop Traumatol Surg Res: OTSR.* 2020;106(1):117-126.
44. Myers SP, Kutcher ME, Rosengart MR, et al. Tranexamic acid administration is associated with an increased risk of posttraumatic venous thromboembolism. *J Trauma Acute Care Surg.* 2019;86(1):20-27.
45. Qi YM, Wang HP, Li YJ, et al. The efficacy and safety of intravenous tranexamic acid in hip fracture surgery: a systematic review and meta-analysis. *J Orthop Translat.* 2019;19:1-11.
46. Porter SB, White LJ, Osagiede O, Robards CB, Spaulding AC. Tranexamic acid administration is not associated with an increase in complications in high-risk patients undergoing primary total knee or total hip arthroplasty: a retrospective case-control study of 38,220 patients. *J Arthroplast.* 2020;35(1):45-51.e43.