

# Translational research of herniated discs: current status of diagnosis and treatment

Hiroataka Haro

Received: 26 December 2013 / Accepted: 2 March 2014 / Published online: 29 April 2014  
© The Japanese Orthopaedic Association 2014

**Abstract** Lumbar herniated discs commonly occur in patients 20–40 years of age, and result in acute symptoms of shooting and intractable pain in the low back and/or lower extremities. However, the prognosis of these patients is considered to be very good. Moreover, 70 % of these patients have been reported to be free from sciatica at approximately 6 months after the first onset. Magnetic resonance imaging (MRI) studies have described the spontaneous resorption process of herniated discs, which is a major cause of the reduction of symptoms in patients. New advancements in MRI have recently been developed that have facilitated the examination of nerve tract fibers and identification of symptomatic nerve tissue. Furthermore, the mechanism underlying the resorption process of a herniated disc has been determined. Inflammatory cytokines such as TNF (tumor necrosis factor)- $\alpha$ , angiogenic factors such as vascular endothelial growth factor, and enzymes such as matrix metalloproteinases are intricately related to each other. In our previous studies, matrix metalloproteinase-7 (MMP-7) has been shown to play a crucial role in the initiation of herniated disc resorption. Therefore, we developed recombinant human MMP-7 for intradiscal therapy through an industry–university joint research program. We have already performed *in vitro* and *in vivo* experiments to confirm its efficacy; this therapy avoids the side effects associated with surgery, such as

nerve tissue damage. Moreover, the phase 1/2 studies of recombinant human (rh) MMP-7 are currently ongoing in the United States, and careful monitoring is required for these clinical trials. In conclusion, patients with lumbar herniated discs may benefit from the development of a less invasive treatment for disc herniation, which can be applied even immediately after the onset of disease symptoms.

## Introduction

Low back pain is the primary reason for patients visiting physicians in Japan. This condition ranks second among the complaints in the United States, following upper respiratory tract complaints [1]. Herniated discs (HD) account for 4 % of the total cases of mechanical low back pain, and occur in approximately 2.8 million patients annually [2]. Patients with lumbar HD experience acute onset unilateral or bilateral lower extremity pain and numbness associated with the low back pain [3]. However, 70 % of lumbar HD patients recover from sciatica within 6 weeks of its onset. Thus, considering the natural history of HD, the overall patient prognosis is good. However, an estimated 10 % of patients will experience continued pain and neurological deficits, and surgical intervention should be considered for these patients [1]. A systematic review comparing surgical intervention and conservative management indicated that surgical intervention enables faster pain relief, compared to prolonged conservative treatment, during short-term follow-up, although no marked differences are noted during long-term follow-up [4, 5].

Lumbar HD patients are primarily between 20 and 40 years of age, employed, and play an active role in

---

This review article was presented at the 28th Annual Research Meeting of the Japanese Orthopaedic Association as Instructional Lecture, Chiba, Japan, October 17, 2013.

---

H. Haro (✉)  
Department of Orthopaedic Surgery, Graduate School of  
Medicine, University of Yamanashi, 1110 Shimokato, Chuo,  
Yamanashi 409-3898, Japan  
e-mail: haro@yamanashi.ac.jp

society. To reduce the quality of life issues caused by surgical intervention, including microdiscectomy, more effective and less invasive treatments—which require less treatment time—need to be developed.

### Molecular genetics and biology

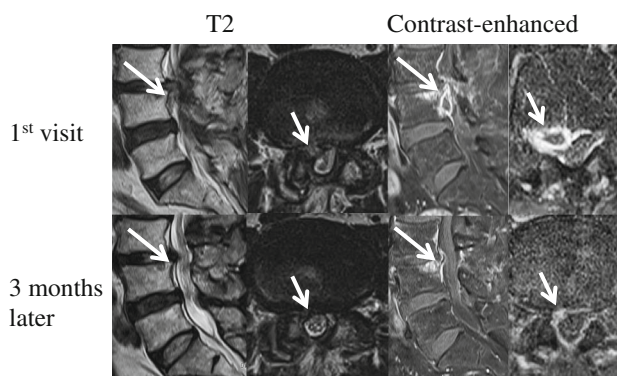
Several previous studies have described the potential gene markers for lumbar disc diseases, including collagen 9A2 [6, 7], vitamin D receptor [8], matrix metalloproteinase (MMP)-3 [9], cartilage intermediate layer protein [10], collagen 11A1 [11], thrombospondin (THBS2) [12], sickle tail (SKT) [13], MMP-9 [12], asporin (ASPN) [14], and carbohydrate sulfotransferase [15]. Systematic reviews demonstrated that there is moderate evidence of correlation of ASPN, COLXIA1, SKT, THBS2, and MMP-9 with HD [16]. However, further studies are needed to identify the gene that is strongly correlated with the disease. Assessment of the upregulation and downregulation patterns of specific candidate genes in animal models may facilitate the identification their precise roles in disc degeneration.

Regenerative medicine techniques for the treatment of disc degeneration have recently been developed for clinical use. Co-culture of autologous mesenchymal stem cells with the patient's nucleus pulposus cells or annulus fibrosus cells may be a good alternative for regenerating the degenerated disc matrix [17]. In addition, the administration of autologous platelet-rich plasma may promote a reparative effect on degenerative disc tissues [18]. These methods suggest the potential for regeneration of degenerated disc tissues in the near future.

### Development of image examination techniques

The resorption process of HD was demonstrated using sequential magnetic resonance imaging (MRI), and this resorption process may be the reason for the relatively good prognosis in cases of HD (Fig. 1) [19]. Vroomen [20] demonstrated that 70 % of patients with HD indicated the disappearance of sciatica within 6 weeks of its onset. In addition, the non-contained classification types of HD, such as transligamentous extrusion and sequestration, as well as the enhanced contrast noted around HD, indicated a high tendency for resorption, thus suggesting that vascularization around the HD would be an important factor for HD resorption [21]. This HD resorption phenomenon was demonstrated in the lumbar, thoracic, and cervical regions of the spine [22, 23].

A recent study indicated that it was impossible to assess good or unfavorable outcomes using MRI at the 1-year follow-up for patients who had been treated for lumbar HD



**Fig. 1** Sequential magnetic resonance imaging of a 66 year-old man demonstrating resorption of the herniated disc

[24]. However, with recent developments in MRI, the observation of tract fibers with diffusion tensor tract images [25] as well as the identification of symptomatic nerve roots (due to spinal disorders) with diffusion-weighted imaging, is currently possible [26]. Through these new technological advancements in MRI, the identification of symptomatic nerve tissues with HD will be possible in the near future, thus facilitating more accurate investigations for HD patients.

### Surgery for HD

A study on HD due to disc rupture or cartilaginous tumor was first reported in 1934. The study concluded that ruptures of the disc were more common than tumors. The authors recommended that the primary mode of treatment should be surgery. In 1939, Love described a surgical technique that involved the identification of an HD mass through myelography and subsequent removal of the HD via partial laminectomy. A study on the long-term outcomes of discectomy, including a follow-up period of more than 10 years, showed relatively favorable results with an average improvement rate of 73.5 % [27]. A prospective randomized multicenter study was performed on 1,244 cases at 13 medical institutes in the United States to compare whether surgical or conservative treatment showed favorable outcomes [28]. When the Short Form 36 and Oswestry Disability Index (ODI) assessment was performed at 3 months, 1 year, and 2 years after intervention, surgical treatment was found to be more effective. However, the findings of that study should be cautiously interpreted, as the crossover rates between the surgery and conservative group were 40 and 45 %, respectively.

The first case of the use of the microendoscopic discectomy system in Japan involved a patient with lumbar HD in 1998. Since then, the use of minimally invasive spinal

endoscopic surgery has increased rapidly, according to an annual report by the Japanese Orthopaedic Association. A prospective study was performed on 120 consecutive patients with lumbar HD treated by the lumbar MED system, with a 5-year follow-up period; the authors indicated that this less invasive and efficient approach using a small skin incision ensured minimal tissue damage and a shorter length of hospital stay, as well as excellent clinical outcomes (ODI and lumbar visual analogue scale scoring), as compared to conventional discectomy [29]. Cases of intraoperative dural tears, surgery at the wrong disc level, and contralateral symptoms owing to the lack of complete decompression of the nerve root were mainly reported for operations performed by inexperienced surgeons, although the frequency decreased with increasing experience of the operator [30]. However, cases of postoperative epidural hematomas, nerve root anomalies, and mechanical failures of surgical instruments were noted even in operations performed by experienced surgeons [30].

### Mechanism of HD resorption

The classical definition of HD is a protrusion or extrusion of a degenerated disc, which results in the presence of a low amount of disc matrix components such as proteoglycan and type II collagen in the spinal canal or neural foramen, where there is abundant vascular supply. Surgically removed tissues indicated tissue granulation, along with the marked infiltration of macrophages and some lymphocytes, concomitant with neovascularization [31]. We developed a co-culture model of disc chondrocytes and peritoneum macrophages derived from MMP-3- or MMP-7-deficient mice to reproduce the acute phase of HD and investigate the role in MMPs in HD resorption. The MMP-3 derived from disc chondrocytes plays a crucial role in the generation of a macrophage chemoattractant, which results in the subsequent infiltration of active macrophages into disc tissues [32]. In addition, the MMP-7 released by macrophages is essential for the release of soluble TNF- $\alpha$  from these macrophages [33]. Thus, extensive communication between disc chondrocytes and extrinsic infiltrated macrophages is important for HD resorption.

Vascular endothelial growth factor (VEGF), a potent angiogenic factor, was found to be strongly expressed in surgical samples of lumbar HD. We previously reported that the upregulation of VEGF under co-culture conditions strongly induced neovascularization [34]. TNF- $\alpha$  induces the release of VEGF from disc cells through NF- $\kappa$ B signaling, which results in CD31 expression on endothelial cells and formation of an anastomosing network [35]. Interestingly, the degree of angiogenic activity was found to be closely related to aging.

Monocyte chemoattractant protein (MCP)-1 is a CC chemokine that plays an important role in the activation and recruitment of macrophages. MCP-1 was found to be expressed in both infiltrated macrophages and disc cells from surgical HD samples [36]. Moreover, TNF- $\alpha$  acts as the initiator of inflammation, following contact between macrophages and disc chondrocytes [37]. TNF- $\alpha$  induces the release of thymic stromal lymphopoietin (TSLP) from disc cells through the NF- $\kappa$ B pathway [38]. The disc cells then express the TSLP receptor and produce MCP-1 through the phosphatidylinositol 3-kinase/Akt pathway. Interestingly, MCP-1 expression in murine intervertebral discs showed age-related decreases, whereas its response to inflammation showed age-related changes.

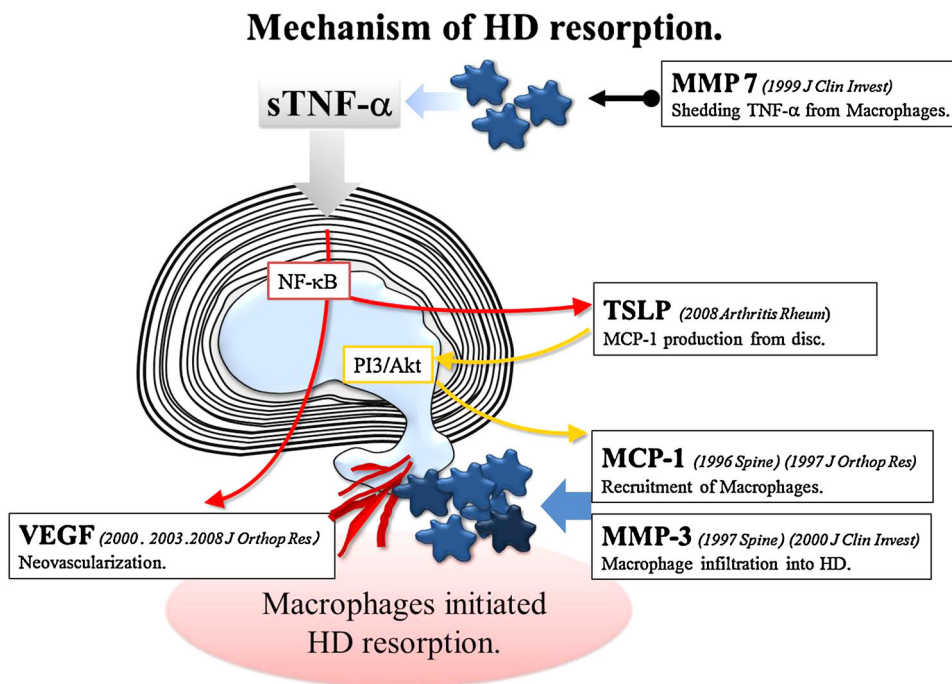
Tumor necrosis factor-like weak inducer of apoptosis (TWEAK) is a member of the TNF- $\alpha$  superfamily of cytokines. The TWEAK and its receptor, Fn14, were expressed in disc tissues [39]. The TWEAK-induced disc cells to generate MMP-3 via a c-Jun N-terminal kinase, resulting in disc matrix degradation. TWEAK also stimulated MCP-1 through the NF- $\kappa$ B pathway (Fig. 2) [40, 41].

### Development of a less invasive treatment for HD

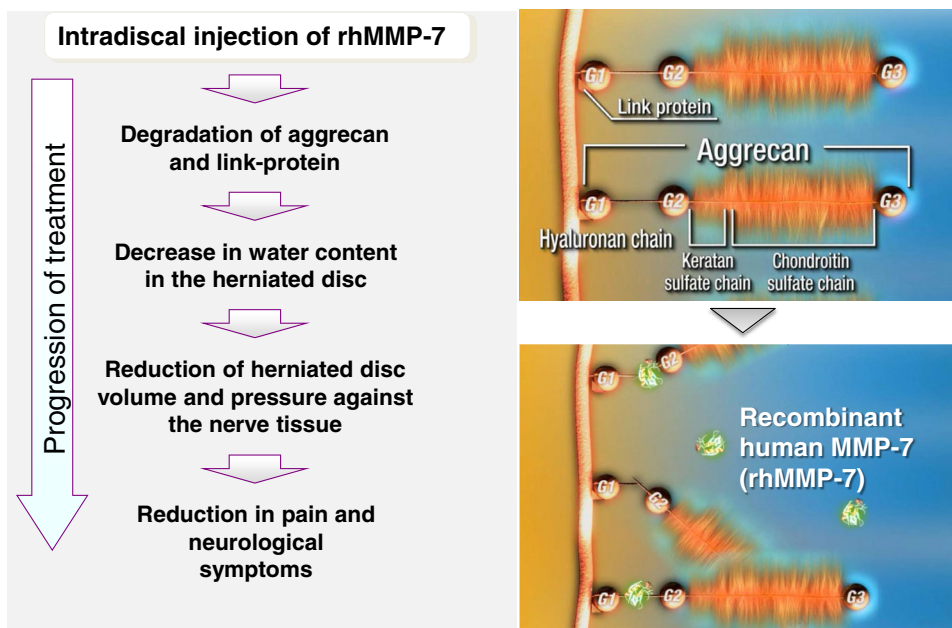
Lumbar HD commonly occurs in patients aged 20–40 years with active lifestyles. These patients show acute onset of low back and/or lower extremity pain, which results in absenteeism from daily work. Thus, a less invasive treatment compared to microdiscectomy with microscopy or endoscopy is required.

Chemonucleolysis is a treatment that involves the administration of enzymes into the HD, and has been proposed as an alternative and less invasive approach to avoid surgery. Chemonucleolysis causes the degradation of aggrecan and/or collagens, which results in the decrease of the HD matrix and water content, as well as a reduction in the pressure exerted by the HD on nerve tissues. Smith previously reported on the administration of chymopapain, derived from *Carica papaya*, into lumbar HD. Although its therapeutic effects have been well documented, chymopapain contains a wide range of substrates, such as aggrecan and collagens, which can lead to certain adverse side effects, including anaphylactic shock, subarachnoid hemorrhage, transverse myelitis, and discitis. Purified bacterial collagenase, derived from *Clostridium histolyticum*, has also been used for chemonucleolysis. A prospective randomized study using chymopapain and collagenase showed good and excellent outcomes 5 years after treatment in 72 % of the chymopapain group and in 52 % of the collagenase group [42]. In addition, a prospective randomized trial of 100 consecutive lumbar HD patients was performed to determine whether chemonucleolysis with chymopapain

**Fig. 2** Schematic model demonstrating the mechanism of herniated disc resorption. Activated macrophages generate tumor necrosis factor (TNF)- $\alpha$ . Matrix metalloproteinase (MMP)-7 derived from macrophages releases the soluble TNF- $\alpha$  from these macrophages, which induces disc cells to generate monocyte chemoattractant protein (MCP)-1 and MMP-3. Thymic stromal lymphopietin derived from disc cells promotes MCP-1 production from disc tissues. MMP-3 derived from disc cells releases chemoattractant and degrades the disc matrix. Vascular endothelial growth factor induces neovascularization



**Fig. 3** Hypothetical mechanism of chemonucleolysis with rhMMP-7



or standard discectomy showed better or improved outcomes. It was found that there were no differences between the two treatments at 1, 10–13, and 24–27 years after the treatment [43]. Thus, chymopapain—which had been recognized as a favorable chemonucleolysis reagent—was subsequently withdrawn as a treatment option owing to the associated complications.

We demonstrated that MMP-7, which is strongly expressed in human HD material, plays a crucial role in the HD resorption process [32]. Therefore, we developed

recombinant human (rh) MMP-7, which may be an ideal candidate as a chemonucleolysis drug. rhMMP-7 degraded human surgical samples of HD in a concentration-dependent manner [44]. Moreover, this effect is not significantly correlated with patient age, HD degeneration grade, and interval between the onset of symptoms and surgery. The aggrecan cleavage rates of rhMMP-7 exhibited a 1,000-fold increase when compared to that of type 1 or type 2 collagens [44]. The intradiscal administration of rhMMP-7 was found to decrease the proteoglycan and water content

in a canine vivo model [44]. Moreover, epidural injections of rhMMP-7 did not show any adverse effects at both the injection site and nerve tissues [44]. Thus, rhMMP-7 may be a novel chemonucleolysis agent (Fig. 3). We are currently performing clinical trials using rhMMP-7 on lumbar HD patients in the United States and are carefully monitoring the patients' conditions.

**Acknowledgments** The author appreciates the boundless support and criticism of Drs. Dan M Spengler, Lynn M Matrisian, Hiromichi Komori, Kenichi Shinomiya, Tsuyoshi Kato, Atsuhito Nakao, Masanori Wako, Tetsuro Ohba, Koji Fujita, and Shigeto Ebata. I also thank Drs. Takashi Kamimura, Yoshiaki Azuma, Noriyuki Tsunekawa, Kiyoyuki Sakon, Tsunefumi Kobayashi, Keishin Sugawara, Satoshi Koyanagi, Miyuki Nishiga, Daisuke Ishii, Takasumi Shimomoto, and many people concerned with developing rh MMP-7. Special recognition goes to Osamu Horie for developing the intervertebral disc device.

**Conflict of interest** The author accepted consulting fee or honorarium from Teijin Pharma Limited.

## References

- Deyo RA, Weinstein JN. Low back pain. *N Engl J Med*. 2001;5:363–70.
- McCulloch JA. Focus issue on lumbar disc herniation: macro- and microdiscectomy. *Spine (Phila Pa 1976)*. 1996;21:45S–56S.
- Vroomen OC, de Krom MC, Knottnerus JA. Predicting the outcome of sciatica at short-term follow-up. *Br J Gen Pract*. 2002;52:119–23.
- Hahne AJ, Ford JJ, McMeeken JM. Conservative management of lumbar disc herniation with associated radiculopathy. A systemic review. *Spine (Phila Pa 1976)*. 2010;35:E488–504.
- Jacobs WCH, Tulder MV, Arts M, Rubinstein SM, Middelkoop MV, Ostelo R, Verhagen A, Koes B, Peul WC. Surgery versus conservative management of sciatica due to a lumbar herniated disc: a systemic review. *Eur Spine J*. 2011;20:513–22.
- Annunen S, Paassilta P, Lohiniva J, Perälä M, Pihlajamaa T, Karppinen J, Tervonen O, Kröger H, Lähde S, Vanharanta H, Ryhänen L, Göring HH, Ott J, Prockop DJ, Ala-Kokko L. An allele of COL9A2 associated with intervertebral disc disease. *Science*. 1999;285:409–12.
- Seki S, Kawaguchi Y, Mori M, Mio F, Chiba K, Mikami Y, Tsunoda T, Kubo T, Toyama Y, Kimura T, Ikegawa S. Association study of COL9A2 with lumbar disc disease in the Japanese population. *J Hum Genet*. 2006;51:1063–7.
- Kawaguchi Y, Kanamori M, Ishihara H, Ohmori K, Matsui H, Kimura T. The association of lumbar disc disease with vitamin-D receptor gene polymorphism. *J Bone Jt Surg Am*. 2002;84-A:2022–8.
- Takahashi M, Haro H, Wakabayashi Y, Kawa-uchi T, Komori H, Shinomiya K. The association of degeneration of the intervertebral disc with 5a/6a polymorphism in the promoter of the human matrix metalloproteinase-3 gene. *J Bone Jt Surg Br*. 2001;83:491–5.
- Seki S, Kawaguchi Y, Chiba K, Mikami Y, Kizawa H, Oya T, Mio F, Mori M, Miyamoto Y, Masuda I, Tsunoda T, Kamata M, Kubo T, Toyama Y, Kimura T, Nakamura Y, Ikegawa S. A functional SNP in CILP, encoding cartilage intermediate layer protein, is associated with susceptibility to lumbar disc disease. *Nat Genet*. 2005;37:607–12.
- Mio F, Chiba K, Hirose Y, Kawaguchi Y, Mikami Y, Oya T, Mori M, Kamata M, Matsumoto M, Ozaki K, Tanaka T, Takahashi A, Kubo T, Kimura T, Toyama Y, Ikegawa S. A functional polymorphism in COL11A1, which encodes the alpha 1 chain of type XI collagen, is associated with susceptibility to lumbar disc herniation. *Am J Hum Genet*. 2007;81:1271–7.
- Hirose Y, Chiba K, Karasugi T, Nakajima M, Kawaguchi Y, Mikami Y, Furuichi T, Mio F, Miyake A, Miyamoto T, Ozaki K, Takahashi A, Mizuta H, Kubo T, Kimura T, Tanaka T, Toyama Y, Ikegawa S. A functional polymorphism in THBS2 that affects alternative splicing and MMP binding is associated with lumbar disc herniation. *Am J Hum Genet*. 2008;82:1122–9.
- Karasugi T, Semba K, Hirose Y, Kelempsioti A, Nakajima M, Miyake A, Furuichi T, Kawaguchi Y, Mikami Y, Chiba K, Kamata M, Ozaki K, Takahashi A, Mäkelä P, Karppinen J, Kimura T, Kubo T, Toyama Y, Yamamura K, Männikkö M, Mizuta H, Ikegawa S. Association of the tag SNPs in the human SKT gene (KIAA1217) with lumbar disc herniation. *J Bone Miner Res*. 2009;24:1537–43.
- Song YQ, Cheung KM, Ho DW, Poon SC, Chiba K, Kawaguchi Y, Hirose Y, Alini M, Grad S, Yee AF, Leong JC, Luk KD, Yip SP, Karppinen J, Cheah KS, Sham P, Ikegawa S, Chan D. Association of the asporin D14 allele with lumbar-disc degeneration in Asians. *Am J Hum Genet*. 2008;82:744–7.
- Song YQ, Karasugi T, Cheung KM, Chiba K, Ho DW, Miyake A, Kao PY, Sze KL, Yee A, Takahashi A, Kawaguchi Y, Mikami Y, Matsumoto M, Togawa D, Kanayama M, Shi D, Luk KD, Yip S, Cherny SS, Wang J, Mundlos S, Kelempsioti A, Eskola PJ, Männikkö M, Mäkelä P, Karppinen J, Järvelin MR, O'Reilly PF, Kubo M, Kimura T, Sham PC, Ikegawa S, Chan D. Lumbar disc degeneration is linked to a carbohydrate sulfotransferase 3 variant. *J Clin Invest*. 2013;123:4909–17.
- Eskola PJ, Lemmelä S, Kjaer P, Solovieva S, Männikkö M, Tommerup N, Lind-Thomsen A, Husgafvel-Pursiainen K, Cheung KM, Chan D, Samartzis D, Karppinen J. Genetic association studies in lumbar disc degeneration: a systematic review. *PLoS One*. 2012;7:e49995. doi:10.1371/journal.pone.0049995.
- Sakai D, Nakamura Y, Nakai T, Mishima T, Kato S, Grad S, Alini M, Risbud MV, Chan D, Cheah KS, Yamamura K, Masuda K, Okano H, Ando K, Mochida J. Exhaustion of nucleus pulposus progenitor cells with ageing and degeneration of the intervertebral disc. *Nat Commun*. 2012;3:1264.
- Obata S, Akeda K, Imanishi T, Masuda K, Bae W, Morimoto R, Asanuma Y, Kasai Y, Uchida A, Sudo A. Effect of autologous platelet-rich plasma-releasate on intervertebral disc degeneration in the rabbit anular puncture model: a preclinical study. *Arthritis Res Ther*. 2012;14:R241.
- Komori H, Shinomiya K, Nakai O, Yamaura I, Takeda S, Furuya K. The natural history of herniated nucleus pulposus with radiculopathy. *Spine (Phila Pa 1976)*. 1996;21:225–9.
- Vroomen PC, de Krom MC, Knottnerus JA. Predicting the outcome of sciatica at short-term follow-up. *Br J Gen Pract*. 2002;52:119–23.
- Komori H, Okawa A, Haro H, Muneta T, Yamamoto H, Shinomiya K. Contrast-enhanced magnetic resonance imaging in conservative management of lumbar disc herniation. *Spine (Phila Pa 1976)*. 1998;23:67–73.
- Mochida K, Komori H, Okawa A, Muneta T, Haro H, Shinomiya K. Regression of cervical disc herniation observed on magnetic resonance images. *Spine (Phila Pa 1976)*. 1998;23:990–5.
- Haro H, Domoto T, Maekawa S, Horiuchi T, Komori H, Hamada Y. Resorption of thoracic disc herniation. Report of 2 cases. *J Neurosurg Spine*. 2008;8:300–4.
- el Barzouhi A, Vleggeert-Lankamp CL, Lycklama à Nijeholt GJ, Van der Kallen BF, Van den Hout WB, Jacobs WC, Koes BW, Peul WC, Leiden-The Hague Spine Intervention Prognostic Study

- Group. Magnetic resonance imaging in follow-up assessment of sciatica. *N Engl J Med*. 2013;368:999–1007.
25. Fujiyoshi K, Yamada M, Nakamura M, Yamane J, Katoh H, Kitamura K, Kawai K, Okada S, Momoshima S, Toyama Y, Okano H. In vivo tracing of neural tracts in the intact and injured spinal cord of marmosets by diffusion tensor tractography. *J Neurosci*. 2007;27:11991–8.
  26. Eguchi Y, Ohtori S, Yamashita M, Yamauchi K, Suzuki M, Orita S, Kamoda H, Arai G, Ishikawa T, Miyagi M, Ochiai N, Kishida S, Inoue G, Masuda Y, Ochi S, Kikawa T, Toyone T, Takaso M, Aoki Y, Takahashi K. Diffusion-weighted magnetic resonance imaging of symptomatic nerve root of patients with lumbar disk herniation. *Neuroradiology*. 2011;53:633–41.
  27. Yorimitsu E, Chiba K, Toyama Y, Hirabayashi K. Long-term outcomes of standard discectomy for lumbar disc herniation: a follow-up study of more than 10 years. *Spine (Phila Pa 1976)*. 2001;26:652–7.
  28. Weinstein JN, Tosteson TD, Lurie JD, Tosteson AN, Hanscom B, Skinner JS, Abdu WA, Hilibrand AS, Boden SD, Deyo RA. Surgical vs nonoperative treatment for lumbar disk herniation: the Spine Patient Outcomes Research Trial (SPORT): a randomized trial. *JAMA*. 2006;296:2441–50.
  29. Casal-Moro R, Castro-Menéndez M, Hernández-Blanco M, Bravo-Ricoy JA, Jorge-Barreiro FJ. Long-term outcome after microendoscopic discectomy for lumbar disk herniation: a prospective clinical study with a 5-year follow-up. *Neurosurgery*. 2011;68:1568–75.
  30. Ebata S, Sato H, Orii H, Sasaki S, Ohba T, Haro H. Risk management in posterior spinal endoscopic surgery in lumbar diseases. *J Orthop Sci*. 2013;18:369–73.
  31. Grönblad M, Virri J, Tolonen J, Seitsalo S, Kääpä E, Kankare J, Myllynen P, Karaharju EO. A controlled immunohistochemical study of inflammatory cells in disc herniation tissue. *Spine (Phila Pa 1976)*. 1994;19:2744–51.
  32. Haro H, Crawford HC, Fingleton B, MacDougall JR, Shinomiya K, Spengler DM, Matrisian LM. Matrix metalloproteinase-3-dependent generation of a macrophage chemoattractant in a model of herniated disc resorption. *J Clin Invest*. 2000;105:133–41.
  33. Haro H, Crawford HC, Fingleton B, Shinomiya K, Spengler DM, Matrisian LM. Matrix metalloproteinase-7-dependent release of tumor necrosis factor- $\alpha$  in a model of herniated disc resorption. *J Clin Invest*. 2000;105:143–50.
  34. Haro H, Kato T, Komori H, Osada M, Shinomiya K. Vascular endothelial growth factor (VEGF)-induced angiogenesis in herniated disc resorption. *J Orthop Res*. 2002;20:409–15.
  35. Ohba T, Haro H, Ando T, Wako M, Suenaga F, Aso Y, Koyama K, Hamada Y, Nakao A. TNF- $\alpha$ -induced NF- $\kappa$ B signaling reverses age-related declines in VEGF induction and angiogenic activity in intervertebral disc tissues. *J Orthop Res*. 2009;27:229–35.
  36. Haro H, Komori H, Okawa A, Murakami S, Muneta T, Shinomiya K. Sequential dynamics of monocyte chemotactic protein-1 expression in herniated nucleus pulposus resorption. *J Orthop Res*. 1997;15:734–41.
  37. Kato T, Haro H, Komori H, Shinomiya K. Sequential dynamics of inflammatory cytokine, angiogenesis inducing factor and matrix degrading enzymes during spontaneous resorption of the herniated disc. *J Orthop Res*. 2004;22:895–900.
  38. Ohba T, Haro H, Ando T, Koyama K, Hatsushika K, Suenaga F, Ohnuma Y, Nakamura Y, Katoh R, Ogawa H, Hamada Y, Nakao A. A potential role of thymic stromal lymphopoietin in the recruitment of macrophages to mouse intervertebral disc cells via monocyte chemotactic protein 1 induction: implications for herniated discs. *Arthritis Rheum*. 2008;58:3510–9.
  39. Wako M, Haro H, Ando T, Hatsushika K, Ohba T, Iwabuchi S, Nakao A, Hamada Y. Novel function of TWEAK in inducing intervertebral disc degeneration. *J Orthop Res*. 2007;25:1438–46.
  40. Fujita K, Ando T, Ohba T, Wako M, Sato N, Nakamura Y, Ohnuma Y, Hara Y, Kato R, Nakao A, Haro H. Age-related expression of MCP-1 and MMP-3 in mouse intervertebral disc in relation to TWEAK and TNF- $\alpha$  stimulation. *J Orthop Res*. 2012;30:599–605.
  41. Wako M, Ohba T, Ando T, Arai Y, Koyama K, Hamada Y, Nakao A, Haro H. Mechanism of signal transduction in tumor necrosis factor-like weak inducer of apoptosis-induced matrix degradation by MMP-3 upregulation in disc tissues. *Spine (Phila Pa 1976)*. 2008;33:2489–94.
  42. Wittenberg RH, Opper S, Rubenthaler FA, Steffen R. Five-year results from chemonucleolysis with chymopapain or collagenase: a prospective randomized study. *Spine (Phila Pa 1976)*. 2001;26:1835–41.
  43. Wardlaw D, Rithchie IK, Sabboubeh AF, Vavdha M, Eastmond CJ. Prospective randomized trial of chemonucleolysis compared with surgery for soft disc herniation with 1-year, intermediate, and long-term outcome: part I: the clinical outcome. *Spine (Phila Pa 1976)*. 2013;38:E1051–7.
  44. Haro H, Nishiga M, Ishii D, Shimomoto T, Kato T, Takenouchi O, Koyanagi S, Ohba T, Komori H. Experimental chemonucleolysis with recombinant human matrix metalloproteinase 7 in human herniated discs and dogs. *Spine J*. 2013. doi:10.1016/j.spinee.2013.11.039.