



## Original Article

# Comparison of surgical outcome between conventional open thyroidectomy and endoscopic thyroidectomy through axillo-breast approach

Kian-Hwee Chong<sup>a</sup>, Ming-Hsun Wu<sup>b</sup>, Chieh-Wen Lai<sup>a,c\*</sup>

<sup>a</sup>Division of General Surgery, Department of Surgery, Taipei Tzu Chi Hospital, Buddhist Tzu Chi Medical Foundation, New Taipei, Taiwan, <sup>b</sup>Department of Surgery, National Taiwan University Hospital, Taipei, Taiwan, <sup>c</sup>School of Medicine, Tzu Chi University, Hualien, Taiwan

## ABSTRACT

**Objective:** Minimally invasive thyroidectomy can be categorized into either video-assisted method or remote access thyroidectomy (RAT). Although RAT provided excellent cosmetic results, some debate about the advantages and disadvantages remains in different countries. Thus, this study aimed to compare the surgical results between endoscopic thyroid surgery and conventional thyroidectomy. **Materials and Methods:** The study retrospectively reviewed the conventional and endoscopic thyroidectomy performed at our institution from September 2011 to July 2012. Overall, 30 patients were recruited for this study. The patients were divided into two groups: Group O (open group,  $n = 15$ ) and Group E (endoscopic group,  $n = 15$ ). Postoperative outcomes (including wound pain, swallowing disturbance, and chest wall paresthesia) and complications were analyzed and assessed. **Results:** The endoscopic group was associated with longer operation time and hospital stay. The visual analog scale (VAS) score of surgical wound pain was significantly higher in the open group in 1-week postoperation. However, the VAS score of swallowing disturbance was significantly higher in the endoscopic group in 1-week postoperation. More than half of the patients (53%) had chest wall paresthesia within 1-month postoperation in the endoscopic group. No surgical complications occurred in both groups. **Conclusion:** Although endoscopic thyroidectomy provides excellent cosmetic results in thyroid surgery, higher immediate postoperative pain, and prolonged chest wall paresthesia compared with those in conventional surgery are a concern and warrant careful patient selection.

**KEYWORDS:** Axillary-breast approach, Endoscopic thyroidectomy, Postoperative pain, Thyroid nodule

Submission : 12-May-2019  
Revision : 18-Jul-2019  
Acceptance : 10-Sep-2019  
Web Publication : 20-Nov-2019

## INTRODUCTION

Laparoscopy was first used as a diagnostic tool by Von Ott who inspected the abdominal cavity of a pregnant woman in 1901. In 1987, a French gynecologist Mouret performed the first acknowledged laparoscopic cholecystectomy using four trocars. Since then, operative laparoscopy has rapidly advanced in the last decade.

In 1912, Theodor Kocher established the open method for offering good exposure of the thyroid gland to enable a safe and effective surgery, which allowed the surgeon to achieve lower morbidity and mortality rates during thyroidectomy. However, to achieve better cosmetic results, many laparoscopic surgeons have attempted to design an ideal minimally invasive thyroid surgical approach. Gagner first reported a video-assisted endoscopic subtotal parathyroidectomy in 1996 [1-3]. Then, in 1997, Hüscher *et al.* performed the first totally video-assisted endoscopic thyroid lobectomy [4]. Since then, many surgeons suggested that compared with conventional open

thyroidectomy, video-assisted endoscopic thyroidectomy provided a better outcome with respect to postoperative pain and cosmetics [5]. However, an obvious postoperative neck scar remains. The concept of remote access thyroid surgery was proposed by the next generation of endoscopic surgeons. Ikeda *et al.* and Ohgami *et al.* reported on transaxillary endoscopic thyroidectomy and a breast approach for endoscopic thyroidectomy in 2000, respectively [6,7]. Meanwhile, minimally invasive methods can be categorized into either video-assisted method or remote access thyroidectomy (RAT).

In some Asian countries, such as Korea, the popularity of RAT has rapidly increased [8]. Many studies have suggested

### \*Address for correspondence:

Dr. Chieh-Wen Lai,  
Division of General Surgery, Department of Surgery, Taipei Tzu Chi Hospital, Buddhist Tzu Chi Medical Foundation, 289, Jianguo Road, New Taipei, Taiwan.  
E-mail: lai01030342@yahoo.com.tw

This is an open access journal, and articles are distributed under the terms of the Creative Commons Attribution-NonCommercial-ShareAlike 4.0 License, which allows others to remix, tweak, and build upon the work non-commercially, as long as appropriate credit is given and the new creations are licensed under the identical terms.

For reprints contact: WKHLRPMedknow\_reprints@wolterskluwer.com

**How to cite this article:** Chong KH, Wu MH, Lai CW. Comparison of surgical outcome between conventional open thyroidectomy and endoscopic thyroidectomy through axillo-breast approach. Tzu Chi Med J 2020; 32(3): 286-90.

Access this article online	
Quick Response Code: 	Website: www.tcmjmed.com
	DOI: 10.4103/tcmj.tcmj_109_19

that RAT provides a better cosmetic outcome than open surgery [6,9-11]. Korean thyroid surgeons have invested significant effort in this technique and are currently leading in this field.

Although RAT provides excellent cosmetic results, some debate about the advantages and disadvantages remains. Only a few studies have mentioned the disadvantages of RAT, showing that it is associated with a longer hospital stay, longer operating time, more surgical pain, and higher rate of right recurrent nerve injury [12-14]. However, local research of RAT is relatively lacking. Therefore, we conducted a retrospective study to analyze our surgical results between endoscopic thyroid surgery and conventional thyroidectomy.

## MATERIALS AND METHODS

We retrospectively reviewed the conventional and endoscopic thyroidectomy performed at Taipei Tzu Chi Hospital, New Taipei City, Taiwan, from September 2011 to July 2012. Overall, 30 patients were recruited for this study. The surgery, either open or endoscopic thyroidectomy, was performed by the same surgeon (Dr. Lai CW). Indications for thyroidectomy were described as follows: Symptomatic tumors, follicular neoplasm based on fine-needle aspiration (FNA) cytology, and cosmetic considerations. All patients underwent preoperative FNA examination, and cases of malignancy were excluded from this study. The following conditions were considered ineligible for endoscopic thyroidectomy: Tumor size >5 cm, previous neck surgery, intrathoracic goiter, and highly suspicious results of FNA cytology. Finally, the patient preferences for open versus endoscopic surgery were considered. The study was conducted in accordance with the Declaration of Helsinki and was approved by the ethics committee in our institution (No. 08-X-079). Written informed consent was waived because the study was a retrospective data analysis.

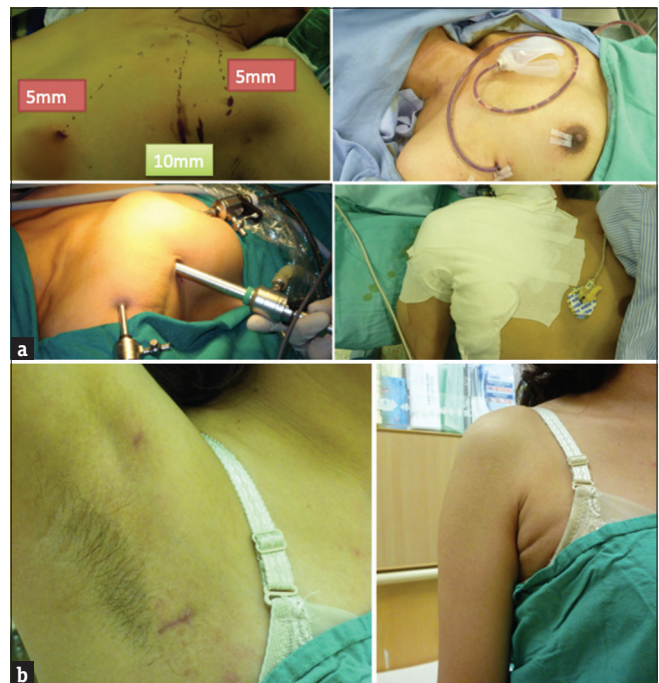The patients were divided into two groups: Group O (open group,  $n = 15$ ) and Group E (endoscopic group,  $n = 15$ ). Postoperative surgical wound pain and swallowing disturbance were measured with a visual analog scale (VAS) at 1 day, 1 week, 1 month, and 3 months postoperation. Chest wall sensory disturbance was also recorded within 3 months' postoperation. Surgical complications, including laryngeal nerve injury, hypocalcemia, hematoma, and wound infection, were also recorded.

### Open thyroidectomy

Under general anesthesia, the patient was placed in a supine position with mild neck extension. A 3–5-cm collar incision was made one fingerbreadth above the sternal notch. A vertical incision was made over the midline of the strap muscle, and the thyroid lobe was dissected from the strap muscle. The thyroid vessels and parenchyma were divided with a ligature. The recurrent laryngeal nerve and parathyroid glands were identified and preserved. After hemostasis, a drain was placed in the paratracheal space, and the surgical wound was closed in layers.

### Endoscopic thyroidectomy

The patient was placed in a supine position with mild neck extension. The arm on the side of the lesion was elevated above the head and held parallel to the low chin. The first skin incision, about 2 cm in length, was made over the anterior axillary line, and a subcutaneous tunnel was dissected with Kelly dissection. One 10-mm trocar was inserted with a CO<sub>2</sub> insufflator with the pressure set under 6 mmHg. The other two trocars were inserted from another axillary incision (5 mm) and a supra-areolar region incision (5 mm). The subcutaneous working space was created with electric cautery under direct vision until the sternocleidomastoid muscle was exposed. Dissection was cranially extended to the hyoid bone and inferiorly to the sternal notch. An incision was made along the border of the strap muscle, and the omohyoid muscle was pushed below to the strap muscle. The thyroid gland was identified and pulled upward with nontraumatic forceps. The thyroid gland was rotated anteriorly, exposing branches of the inferior thyroid vessels and middle thyroid vein, parathyroid glands, and recurrent laryngeal nerve. The terminal branches of the inferior thyroid vessels and middle thyroid vein were divided with a 5 mm Harmonic scalpel under direct visualization after the protection of the recurrent laryngeal nerve. Next, the thyroid gland was pulled inferiorly to expose the branches of superior thyroid vessels. The vessels were dissected free and separately clamped to avoid injury to the external branches of the superior laryngeal nerve. Finally, the thyroid gland was divided into two parts over the isthmus with the Harmonic scalpel. The specimen was placed into an endobag and extracted out through the wound. After hemostasis, a drain was inserted, and the wound was closed layer by layer. The surgical area was compressed with elastic adhesive tape to avoid postoperative subcutaneous hematoma and bleeding [Figure 1a].



**Figure 1:** Illustration of the surgical method and postoperative scar in transaxillary endoscopic thyroidectomy. (a) Trocar site and wound management. (b) Postoperative wound cosmetic result 1-month postoperation

**Statistical analysis**

Values are presented as the mean ± standard deviation of the mean, and data analyses were performed with a one-way analysis of variance, followed by Fisher’s exact test or an unpaired *t*-test (SPSS Version 15.0, Inc., Chicago, IL, USA). *P* < 0.05 is considered to be statistically significant.

**RESULTS**

Overall, 30 patients (27 females and 3 males) were recruited during 1 year. Of these patients, 15 underwent the open procedure (Group O) and 15 underwent the endoscopic procedure (Group E). Baseline demographic and clinical characteristics are shown in Table 1. Statistically significant differences were not observed between the groups in age, sex, tumor size, or blood loss. The operative time was significantly higher in the endoscopic group (109.7 ± 22.3 vs. 44.2 ± 10.9 min, *P* < 0.001) compared to the open group. The hospital stay was significantly longer in endoscopic group (4.1 ± 0.3 vs. 3.6 ± 0.4 days, *P* < 0.05). No surgical complications, such as recurrent laryngeal nerve injury, hypocalcemia, hematoma, or hemorrhage, occurred in either group. Final histologic examination demonstrated benign nodular goiter in the open group. However, one papillary carcinoma was diagnosed in the endoscopic group, and a complete total thyroidectomy using open method was performed a month later.

**Postoperative surgical wound pain assessment**

The severity of postoperative surgical wound pain was measured with a VAS from day 1 to 3 months postoperation, as shown in Figure 2. The pain score was significantly higher at 1 week postoperation in the endoscopic group than in the open group (2.3 ± 1.7 vs. 0.7 ± 0.6, *P* < 0.05). The pain score at other periods showed no difference between the two groups.

**Postoperative swallowing disturbance assessment**

Most patients experienced swallowing disturbance post-thyroidectomy as assessed by a VAS [Figure 3]. The pain score was significantly higher at 1-week postoperation in the open group compared to the endoscopic group (1.1 ± 0.6 vs. 0.4 ± 0.5, *P* < 0.05). The pain score at other periods showed no difference between the two groups.

**Table 1: Clinicopathologic characteristics of patients in Group O and E (n=15)**

	Group O	Group E	P
Age (year)	43.70±10	44.8±10	0.64
Gender (%)			
Female	13 (86.7)	14 (93.3)	0.334
Male	2 (13.3)	1 (6.7)	
Operative time (min)	44.20±10.96	109.70±22.38	<0.001
Hospital stay (day)	3.66±0.48	4.13±0.35	0.004
Tumor size (mm)	37.30±12.96	36.2±14.71	0.808
Blood loss (mL)	19.00±9.66	18.50±9.44	0.906
Histopathological report			
Papillary carcinoma	0	1	0.334
Benign	15	14	

Group O: Conventional open thyroidectomy, Group E: Transaxillary endoscopic thyroidectomy

**Postoperative chest wall paresthesia assessment**

Due to the additional dissection plane over the chest wall in the endoscopic group, more than half of the patients (53%) experienced chest wall paresthesia within 1-month postoperation. However, most of them (93%) resolved by 3 months’ postoperatively [Figure 4].

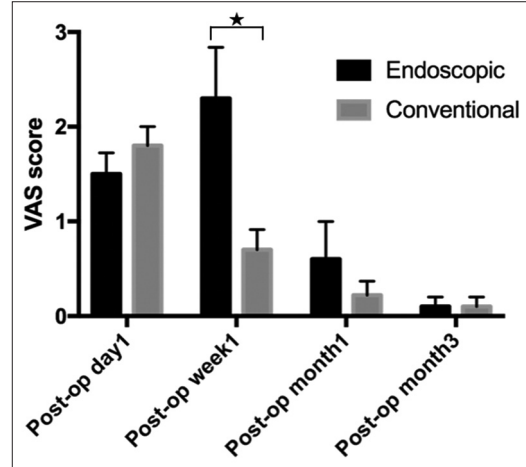


Figure 2: Illustration of the visual analog scale score in postoperative wound pain

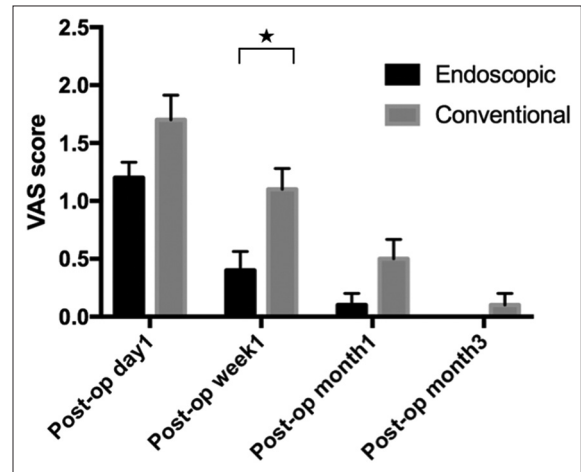


Figure 3: Illustration of the visual analog scale score in postoperative swallowing disturbance

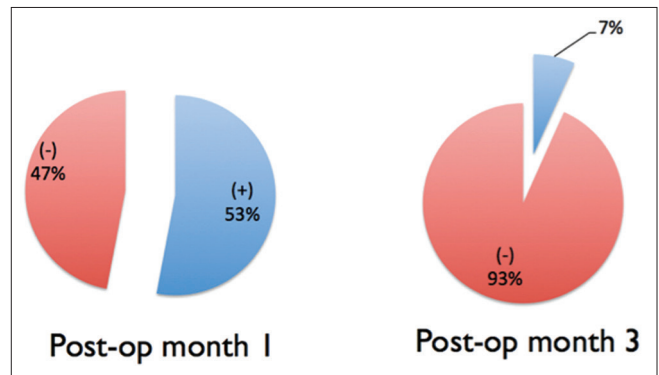


Figure 4: Illustration of the percentage of postoperative chest wall paresthesia in transaxillary endoscopic thyroidectomy



## DISCUSSION

In the new era of minimally invasive surgery, endoscopic thyroidectomy has been promoted by some surgeons for its clinical advantages. However, according to our study, the benefits may be less than expected. The present study demonstrated that patients in the endoscopic group had more pain and less prominent swallowing disturbances than those in the conventional group. Almost half of the patients developed chest wall paresthesia in the endoscopic group. In addition, this study showed longer operative time and hospital stay in the endoscopic group than in the conventional group.

Compared with patients undergoing conventional thyroidectomy, those undergoing endoscopic thyroidectomy had a significantly higher score with respect to postoperative wound pain during the 1<sup>st</sup> week postoperation. During endoscopic thyroidectomy, the dissection plane started from the axilla and breast, extending to the chest wall and neck. This results in a much larger dissection plane than conventional open surgery; therefore, it may cause more pain postoperation.

Endoscopic thyroidectomy also showed no advantages of a shorter operation time or hospital stay. Thus, endoscopic thyroidectomy is actually not a minimally invasive procedure, but a maximally invasive operation. Our results are consistent with those of previous reports [12,13]. Ikeda *et al.* and Tan *et al.* also reported higher pain scores in patients undergoing transaxillary endoscopic thyroidectomy. However, some researchers have reported different results. Lee *et al.* demonstrated that the pain score is comparable between robotic endoscopic thyroidectomy and conventional open surgery [15]. Because we are still early in our experience with endoscopic thyroidectomy, immature surgical techniques may lead to more pain in patients.

In the present study, less patients complained about swallowing disturbances in the endoscopic group, especially in the 1<sup>st</sup> week postoperation, compared with the open group. A similar result has been reported elsewhere. Hyun *et al.* reported that patients undergoing conventional open thyroidectomy had a significantly higher postoperative swallowing impairment index (SIS-6 scores) than patients undergoing transaxillary endoscopic thyroidectomy. The authors concluded that swallowing disorders and dysphagia were caused by strap muscle and subplatysma muscle adhesions. These complications are rare in transaxillary endoscopic thyroidectomy [16]. Lee *et al.* explained that because endoscopic thyroidectomy uses different incision sites, it may result in the preservation of innervation and less manipulation over the paraesophageal region [15]. Therefore, transaxillary endoscopic thyroidectomy may be beneficial for reduction of postthyroidectomy swallowing disturbance.

During cutaneous flap dissection, the skin is separated from the muscular layer. This procedure results in cutaneous sensory nerve injury and patient discomfort. In the present study, we found that more than half of the patients experienced chest wall paresthesia in the 1<sup>st</sup> month postoperation. Most of them recovered within 3 months' postoperation. Most patients can tolerate this discomfort, but not all. In our

series, one subject in the endoscopic group was diagnosed with papillary carcinoma postoperatively. Subsequent complete thyroidectomy was converted to an open procedure due to the unbearable wound pain, and chest wall paresthesia was experienced after the endoscopic method. Therefore, potential additional discomfort should be thoroughly described to the patient preoperatively.

Cosmetic satisfaction scores were higher in the endoscopic group than in the conventional group. This is easily understood as the surgical scars in the axilla are well-hidden in a natural posture [Figure 1b], while the neck scars caused by conventional surgery are obvious [17]. Our preliminary result was also consistent with previous reports, with all patients satisfied with their wound cosmetic result in the endoscopic group. A comparative study also reported the benefits of endoscopic thyroidectomy during the early postoperative period. Lee *et al.* demonstrated early improvement in physical and emotional functions in patients who underwent transaxillary endoscopic thyroidectomy compared with those who underwent conventional open thyroidectomy [18]. Despite a higher pain score, endoscopic thyroidectomy may be an alternative for patients who value a better quality of life and better cosmetic result.

The present study has several limitations. First, the sample size was relatively small. A larger study size is needed to define the postoperative results of transaxillary endoscopic thyroidectomy. Second, this is our early experience in endoscopic thyroidectomy. The learning curve in surgical techniques may affect the outcome of the study. Third, this is not a randomized controlled trial and may contain research bias in its design. Therefore, a randomized well-controlled study is needed in the future to better define the outcome of this operation.

## CONCLUSION

Transaxillary endoscopic thyroidectomy is more technically demanding. In our early experience, this procedure was associated with a higher pain score, more chest wall paresthesia, longer operative time, and longer hospital stay, but with less swallowing disturbance and excellent cosmetic satisfaction. Careful selection of patients and preoperative informed consent may be necessary.

## Financial support and sponsorship

Nil.

## Conflicts of interest

There are no conflicts of interest.

## REFERENCES

1. Gagner M. Endoscopic subtotal parathyroidectomy in patients with primary hyperparathyroidism. *Br J Surg* 1996;83:875.
2. Lang BH. Minimally invasive thyroid and parathyroid operations: Surgical techniques and pearls. *Adv Surg* 2010;44:185-98.
3. Lang BH, Lo CY. Technological innovations in surgical approach for thyroid cancer. *J Oncol* 2010;2010. pii: 490719.
4. Hüscher CS, Chiodini S, Napolitano C, Recher A. Endoscopic right thyroid lobectomy. *Surg Endosc* 1997;11:877.
5. Sgourakis G, Sotiropoulos GC, Neuhäuser M, Musholt TJ, Karaliotas C, Lang H, et al. Comparison between minimally invasive video-assisted thyroidectomy and conventional thyroidectomy: Is there any

- evidence-based information? *Thyroid* 2008;18:721-7.
6. Ikeda Y, Takami H, Sasaki Y, Kan S, Niimi M. Endoscopic neck surgery by the axillary approach. *J Am Coll Surg* 2000;191:336-40.
  7. Ohgami M, Ishii S, Arisawa Y, Ohmori T, Noga K, Furukawa T, et al. Scarless endoscopic thyroidectomy: Breast approach for better cosmesis. *Surg Laparosc Endosc Percutan Tech* 2000;10:1-4.
  8. Bae JS, Cho YU, Sung GY, Oh SJ, Jung EJ, Lee JB, et al. The current status of endoscopic thyroidectomy in Korea. *Surg Laparosc Endosc Percutan Tech* 2008;18:231-5.
  9. Jeong JJ, Kang SW, Yun JS, Sung TY, Lee SC, Lee YS, et al. Comparative study of endoscopic thyroidectomy versus conventional open thyroidectomy in papillary thyroid microcarcinoma (PTMC) patients. *J Surg Oncol* 2009;100:477-80.
  10. Yoon JH, Park CH, Chung WY. Gasless endoscopic thyroidectomy via an axillary approach: Experience of 30 cases. *Surg Laparosc Endosc Percutan Tech* 2006;16:226-31.
  11. Chantawibul S, Lokechareonlarp S, Pokawatana C. Total video endoscopic thyroidectomy by an axillary approach. *J Laparoendosc Adv Surg Tech A* 2003;13:295-9.
  12. Ikeda Y, Takami H, Sasaki Y, Takayama J, Kurihara H. Are there significant benefits of minimally invasive endoscopic thyroidectomy? *World J Surg* 2004;28:1075-8.
  13. Tan CT, Cheah WK, Delbridge L. "Scarless" (in the neck) endoscopic thyroidectomy (SET): An evidence-based review of published techniques. *World J Surg* 2008;32:1349-57.
  14. Lang BH, Wong KP. A comparison of surgical morbidity and scar appearance between gasless, transaxillary endoscopic thyroidectomy (GTET) and minimally invasive video-assisted thyroidectomy (VAT). *Ann Surg Oncol* 2013;20:646-52.
  15. Lee J, Nah KY, Kim RM, Ahn YH, Soh EY, Chung WY, et al. Differences in postoperative outcomes, function, and cosmesis: Open versus robotic thyroidectomy. *Surg Endosc* 2010;24:3186-94.
  16. Hyun K, Byon W, Park HJ, Park Y, Park C, Yun JS, et al. Comparison of swallowing disorder following gasless transaxillary endoscopic thyroidectomy versus conventional open thyroidectomy. *Surg Endosc* 2014;28:1914-20.
  17. Ikeda Y, Takami H, Sasaki Y, Takayama J, Niimi M, Kan S, et al. Comparative study of thyroidectomies. Endoscopic surgery versus conventional open surgery. *Surg Endosc* 2002;16:1741-5.
  18. Lee MC, Park H, Lee BC, Lee GH, Choi IJ. Comparison of quality of life between open and endoscopic thyroidectomy for papillary thyroid cancer. *Head Neck* 2016;38 (Suppl 1):E827-31.