

Endovascular Management of Immediate Procedure-Related Complications of Failed Hemodialysis Access Recanalization

Dong Hun Kim, MD¹
Dong Erk Goo, MD²
Seung Boo Yang, MD²
Cheul Moon, MD³
Deuk Lin Choi, MD²

Endovascular procedures are becoming the standard type of care for the management of hemodialysis vascular access dysfunction. As with any type of medical procedure, these techniques can result in procedure-related complications, although the expected number of complications is low. The clinical extent of these complications varies from case to case. Management of these cases depends on the clinical presentation. Major complications such as vein rupture, arterial embolism, remote site bleeding or hematoma, symptomatic pulmonary embolism and puncture site complications necessitating treatment require major therapy. Minor complications such as non-flow compromising small puncture site hematoma or pseudoaneurysms require little or no therapy. It is essential that the interventionist be prepared to manage these complications appropriately when they arise.

Index terms:
Hemodialysis
Transluminal angioplasty

Korean J Radiol 2005; 6: 185-195

Received February 23, 2005; accepted after revision June 14, 2005.

¹Department of Radiology, Chosun University Hospital; ²Department of Radiology, Soonchunhyang University Hospital; ³Department of General Surgery, Soonchunhyang University Hospital

Address reprint requests to:
Dong Erk Goo, MD, Department of Radiology, Soonchunhyang University Medical School, 657 Hannam-dong, Younsan-gu, Seoul 140-743, Korea.
Tel. (822)709-9396
Fax. (822)795-3928
e-mail: dhk1107@hanmail.net

Venous stenosis and its end result, thrombosis, are common when synthetic grafts are used for hemodialysis (HD) access (1, 2). Endovascular procedures are becoming the standard type of care for the management of these problems. In general, a procedure-related complication is defined as an adverse event that occurs as a result of the procedure. The rate at which these complications can be expected to occur varies based on each individual procedure. The actual rate observed can be affected by external factors such as the manner in which the procedure is performed. A procedure with an excessive complication rate suggests the need for critical evaluation of the technique and procedure. The interventionist performing the basic procedure must be prepared to manage any complications as they occur (3, 4). The purpose of this article is to discuss the complications that can occur during the treatment of vascular access problems requiring additional endovascular therapy for management.

MATERIALS AND METHODS

A retrospective review of 3,430 failing dialysis accesses (graft : native = 1,662 : 1,768), between April 1997 and June 2004, revealed 221 (6.4%) complications occurred during percutaneous transluminal angioplasty (PTA). In dysfunction of the 3,430 accesses, there was 708 thrombosed HD access grafts. In 606 of 708 the thrombosed grafts, percutaneous thrombi aspiration with a Desilets-Hoffman sheath (COOK, Bloomington, IN, USA) and balloon dilatation of the venous anastomosis and mobilization of the arterial plug using a Forgarty catheter (Baxter, Santa Ana, CA, USA) maneuver were used (5). In 102 of the thrombosed grafts, the urokinase thrombolysis technique (urokinase 20,000–300,000 IU) was used and then a balloon

angioplasty was performed (6). Three hundred and ten stent deployments (peripheral vein : central vein = 99 : 211) were performed. When stenoses of the native veins occurred, thrombolysis was performed with urokinase, and was followed by PTA. When a complete obstruction of central veins occurred, guide wire was passed and then ballooning and stenting was performed using urokinase. Details of the procedure-related complications (n=221) are summarized in Table 1. The reported complications were identified clinically or angiographically while the patient was still undergoing the procedure. Most of complications were treated at the same time, allowing for the completion of the procedure. Records of delayed complications such as prolonged bleeding or reopening of the puncture sites after the patient was discharged, were not available. Due to the diverse nature of the complications, each type and their treatment will be described separately. Definitions apply to the treatment of immediate complications allowing for the completion of the recanalization of the HD access dysfunction.

COMPLICATIONS AND MANAGEMENT

All events related to complications that arose from access intervention and occurred during the procedure. Major complications were defined as complications; 1) requiring therapy and minor hospitalization (< 48 hours), 2) requiring major therapy, unplanned increase in level of care and prolonged hospitalization (> 48 hours), 3) permanent adverse sequelae, or 4) death. These include vascular perforation or rupture, arterial embolization, remote site bleeding or hematoma, death, symptomatic pulmonary embolism and puncture site complications necessitating

treatment. Minor complications such as non-flow compromising small puncture site hematoma or pseudoaneurysms were defined as incidents with 1) no consequences and no additional therapy, 2) nominal therapy and no consequences, including overnight admission for observation only (1).

Vein Rupture-Extravasation Following PTA

Vein rupture is a common complication of PTA. Ruptures following angioplasty have been reported to occur in 2.1 to 20% of patients (7, 8). Both acute and delayed venous ruptures have been reported. Vein ruptures typically occur as a complication of venous angioplasty used to correct the stenosis in synthetic grafts and autologous fistulas. Contrast extravasation can be of minor significance, causing a small hematoma and requiring no corrective action, or it can be more serious, causing a tear in the vein wall and affecting flow within the graft (9). Treatment of venous ruptures is aimed at minimizing hemorrhage and preserving access function. In most cases observation alone or repeated, prolonged inflation of the angioplasty balloon can control contrast extravasation, stop the hemorrhage, and preserve access function. In more severe tears and ruptures of the vein, endovascular stents have been successfully used to stop bleeding and preserve the access (9). Sometimes hemorrhage in the ruptured vein can be controlled by intentional graft thrombosis, with placement of a temporary hemodialysis catheter, followed by percutaneous thrombolysis of the graft. With ruptures of the vein surgical intervention is rarely necessary, although graft loss may occur, and a new vascular access may be required.

In the authors' hospital, PTA was used to treat greater

Table 1. Complications and Treatments Occurring During Hemodialysis Access Recanalization

| Complications | No of Pts | Treatment |
|--|-----------|--|
| Venous/ venous anastomotic rupture | 158 | Ballooning (142), stent (14), OP (2) |
| Arterial emboli | 19 | Retracting emboli (17), OP (1), conservative treatment (1) |
| Venous/Intragraft dissection | 11 | Ballooning (11) |
| Graft extravasation | 10 | Digital pressure/elastic bandage / balloon tamponade (10) |
| Hematoma at puncture site | 6 | Elastic bandage (6) |
| Arterial rupture | 4 | Ballooning (4) |
| Balloon fragmentation | 3 | OP (3) |
| Symptomatic pulmonary embolism | 2 | Conservative treatment (2) |
| Cardiac arrest | 2 | Death (1), conservative treatment (1) |
| Displacement of stent | 2 | Snaring (1), conservative treatment (1) |
| Septic embolism | 1 | OP (1) |
| Arterial dissection | 1 | Conservative treatment (1) |
| Iatrogenic femoral arteriovenous fistula | 1 | Conservative treatment (1) |
| Guide wire fracture | 1 | OP (1) |

Note.— No of Pts = number of patients, OP = operation

Endovascular Management of Procedure-Related Complications of Failed Hemodialysis Access Recanalization

than 50% of stenoses involving segments via an appropriate size vascular sheath. An angioplasty balloon 4–16 mm in diameter over a 0.035 inch guidewire was inflated to 12–24 atm. All cases involving a rupture (158/3,430, 4.6%) described here were identified as contrast extravasation from the angioplasty site, which resulted in severe stasis in the graft and outflow. In order to manage venous

ruptures, the sites where the rupture occurred were compressed manually for 3–5 minutes, or flow was blocked with a balloon catheter for 3–5 minutes (10) (Fig. 1). Persistent extravasations accompanied by cessation of flow, after prolonged balloon tamponade (3–5 min) were managed by deploying uncovered metallic stents (11) (Fig. 2). Stent placements are thought to control ruptures by

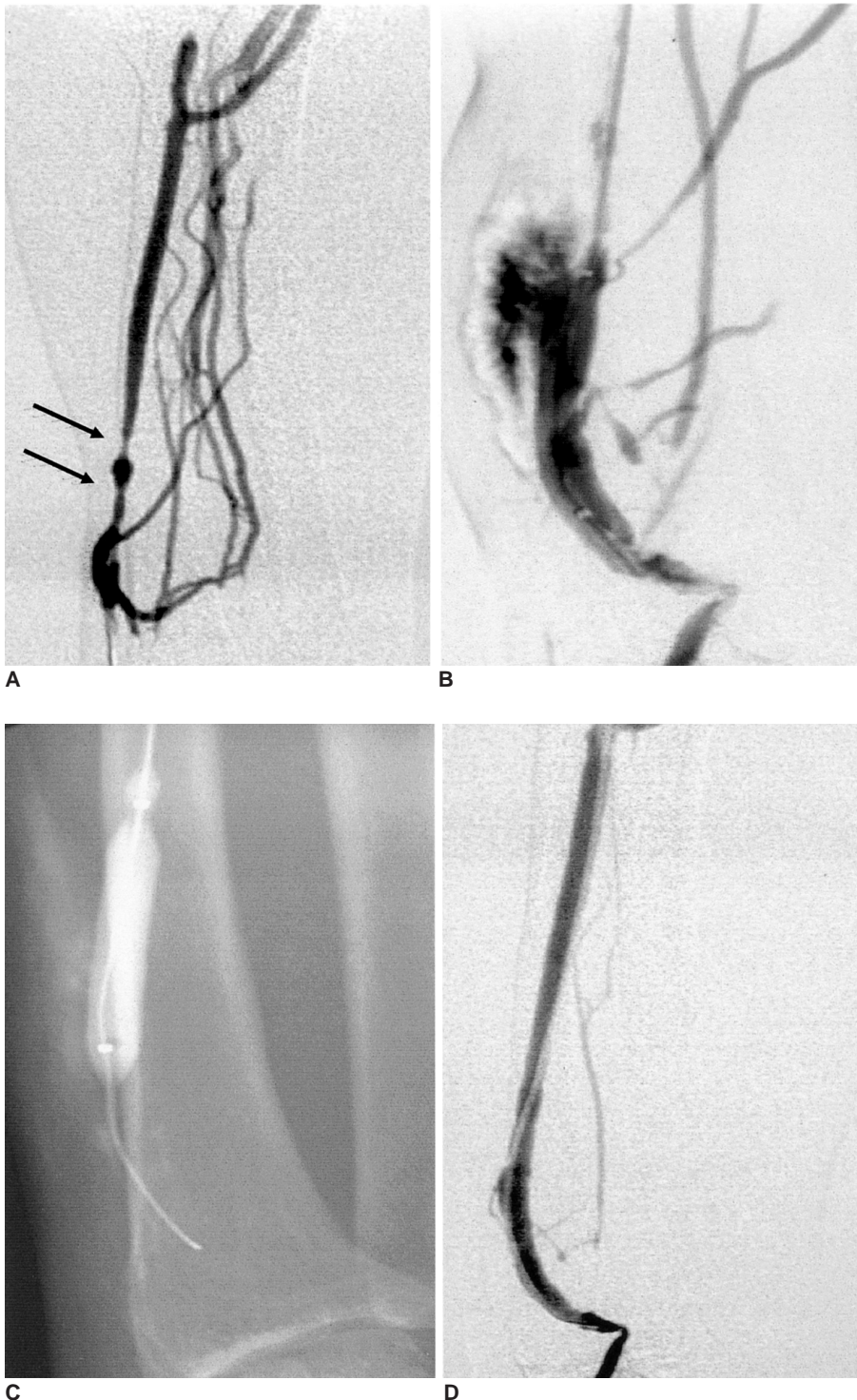


Fig. 1. 58-year-old woman with a left radiocephalic fistula.
A. Diffuse stenosis of the distal cephalic vein is shown.
B. Contrast extravasation after ballooning is shown at the proximal diffuse stenotic lesion.
C. Blood flow is blocked by a balloon catheter for five minutes.
D. Postprocedural angiography shows restoration of the lumen.

improving graft outflow, which then decreases pressure locally at the site of rupture. The stent also may work to flatten the intimal flap, which was raised during angioplasty, and allow for closure. Stents ranged in size from 6 × 40 mm to 10 × 60 mm. Selection was made on a case by case basis based on the patient's vessel size. All stents were introduced to the access using an appropriate

size (7–8 Fr) vascular sheath which was advanced through the venous anastomosis and outflow into the central vein. Each stent was subsequently dilated with the use of an angioplasty balloon of the same diameter. A total of 14 (graft anastomosis : native peripheral vein = 13 : 1) uncovered metallic stents were deployed to treat the vascular ruptures. Immediate angiographic evaluation was

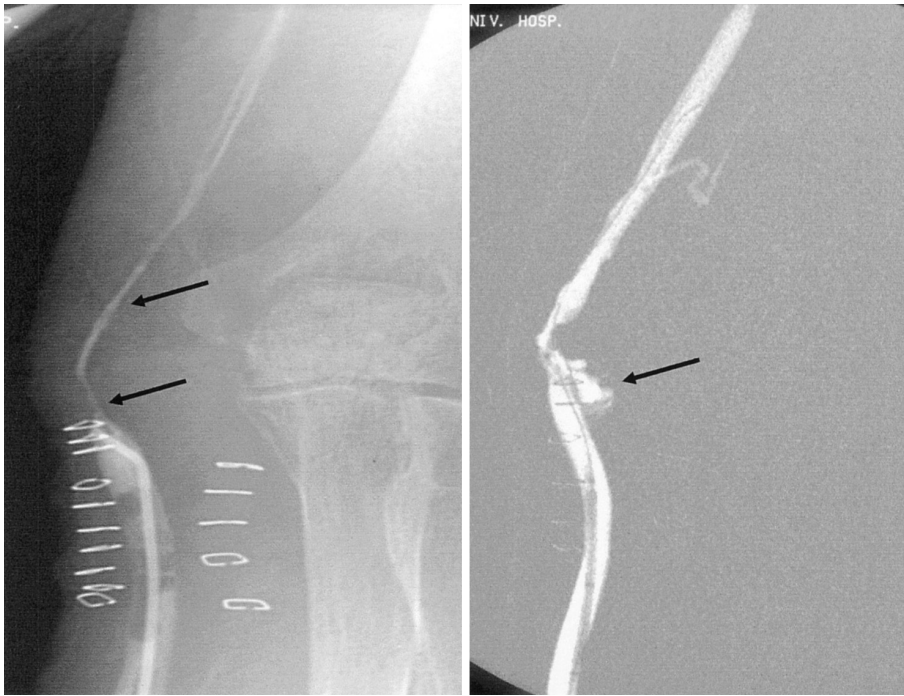
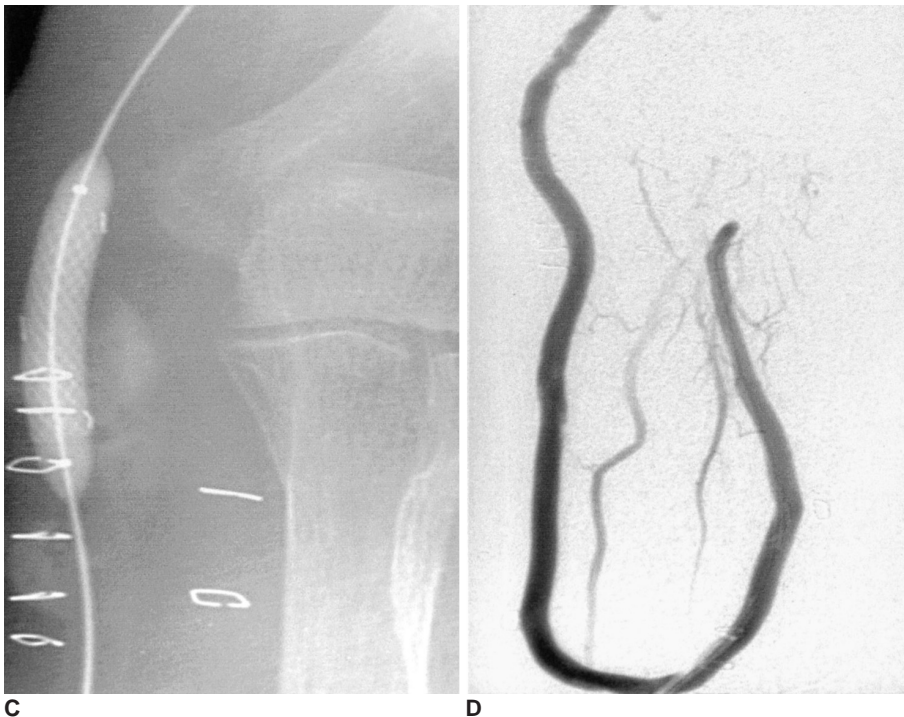
Fig. 2. 47-year-old woman with a left radiobasilic graft.
A. Diffuse tight stenosis is shown at the venous anastomosis (arrows).
B. Extravasation after ballooning causing vein rupture.
C. Blood flow was blocked by a balloon catheter for five minutes. However, fistulography shows continuous extravasation and persistent residual stenosis by severe tears and ruptures of the vein. Endovascular stents were successfully used to stop the bleeding and preserve the access.
D. Follow-up angiography shows good patency of the lumen and no leakage.



Endovascular Management of Procedure-Related Complications of Failed Hemodialysis Access Recanalization

performed following stent deployment to confirm proper position and to evaluate whether there was any persistent extravasation or pseudoaneurysm formation. There were no hemodynamically significant complications following the deployment of the stents. Two patients underwent surgery: one had uncontrollable bleeding, and the other had nerve compression symptoms as a result of a hematoma. The Dialysis Outcomes Quality Initiative

(DOQI) guidelines recommend stent placement to be reserved for patients with limited residual access sites that have a contraindication to surgery or in whom the lesion is surgically inaccessible that fail PTA (two PTAs in a 3-month period).

Arterial Emboli

Arterial embolism is a well-known complication of

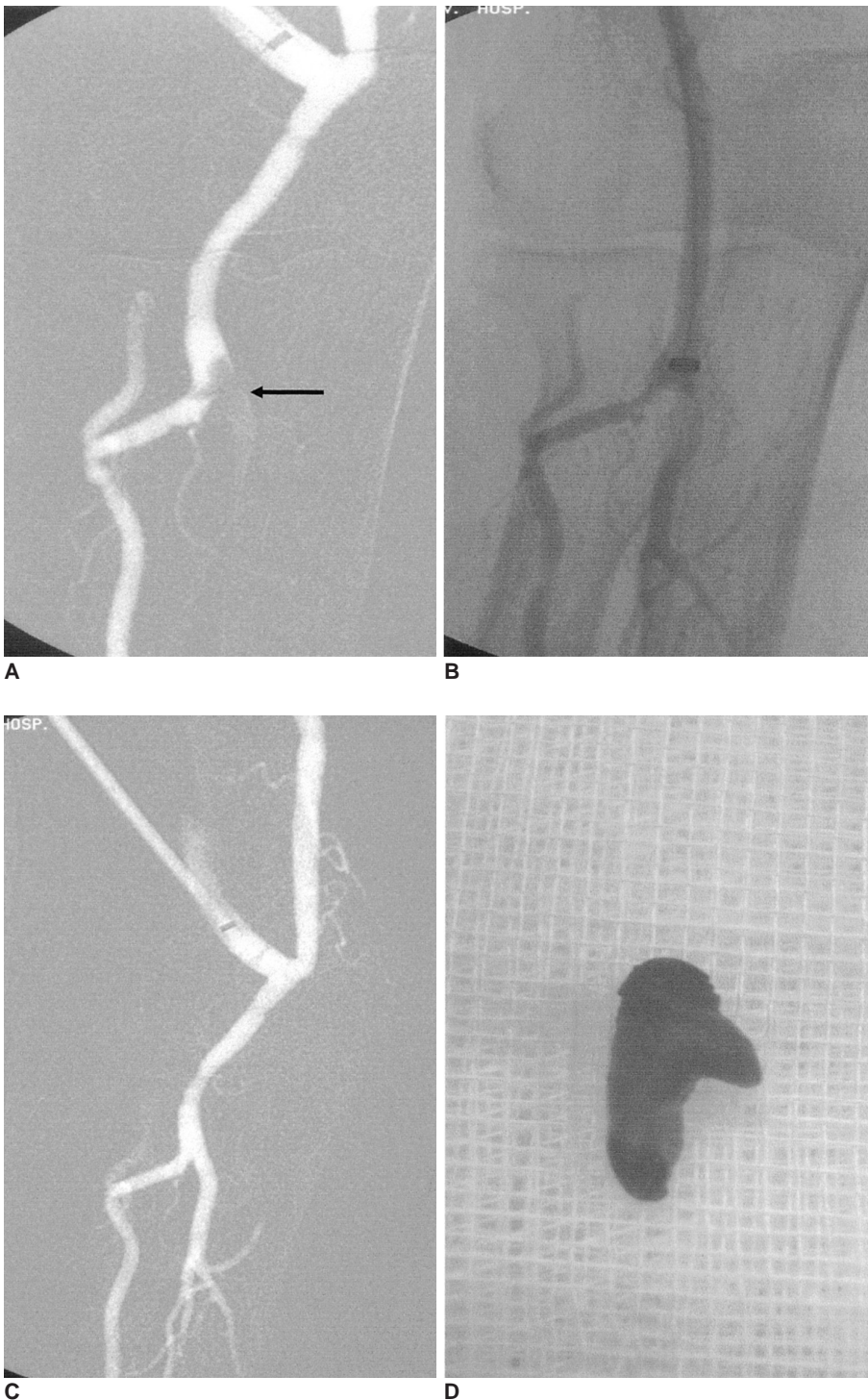


Fig. 3. 68-year-old woman with a right upper arm brachiobasilic graft.
A. Abrupt cutoff in the ulnar artery means an arterial embolus.
B. 7F Desilet-Hoffman sheath was advanced through the artery near the embolus.
C. Angiography after retraction of the embolus in the sheath demonstrates a successful retrieval resulting in the restoration of the arterial lumen.
D. The retracted embolus is shown.

percutaneous dialysis graft thrombolysis. In pulse spray techniques, overly vigorous flushing of the catheters inserted into the clotted grafts may cause an acute increase in pressure within the graft, leading to reflux of the clot into the artery and peripheral embolism. Passing catheters and guide wires across and beyond the arterial anastomosis may also cause arterial embolisms, as may maceration of the arterial plug. The incidence of arterial emboli following percutaneous dialysis graft thrombolysis has been reported to be in the range of between 0% and 6.3% (12).

Management of arterial emboli hinges upon whether they are symptomatic or asymptomatic. Asymptomatic emboli may not require any specific treatment. In one series, asymptomatic emboli following surgical graft thrombectomy were not treated, resolved without further intervention, and did not result in any ischemic symptoms for a mean of one year following the procedure (13). These findings, if applied to percutaneous intervention, support a policy of observation for asymptomatic arterial emboli.

Symptomatic emboli causing hand ischemia or diminished post-procedure pulses clearly require treatment. Available options have traditionally included surgical thrombectomy, infusion of thrombolytic agents such as urokinase, and mechanical mobilization (pulling the embolus back into the graft) with a balloon.

In our cases, arterial emboli were observed in 19/708

(2.7%) of the recanalization procedures. The emboli were observed during imaging of the arterial anastomosis and the artery distal to the anastomosis, as a filling defect or abrupt cutoff of the arterial lumen. Symptomatology and clinical findings including pain, paresthesia, hypothermia, coldness along the anastomotic distribution of the affected arterial branch were not noted. Regardless of the presence or absence of symptoms, 16 of the arterial emboli were removed using an occlusion balloon (Boston Scientific, Natick, MA, USA). The balloon was used to retrieve the emboli from the graft while being inflated and then retracted in a retrograde manner (3, 4). No additional complications were encountered during the retraction process and in all cases, normal flow was re-established in the artery. In the remaining three cases, one embolus was removed using a Desilets-Hoffman sheath (Cook, Bloomington, IN, USA) (Fig. 3), one by surgery, and one followed up with observation. Graft patency was re-established allowing successful hemodialysis in all cases.

Venous Intimal Dissection

A total of 11/3,430 (0.3%) intimal dissections occurred during the recanalization procedures. They were observed angiographically as persistent intravenous linear defects that compromised flow via the vein. All of the cases occurred during the ballooning. In all 11 cases, the linear

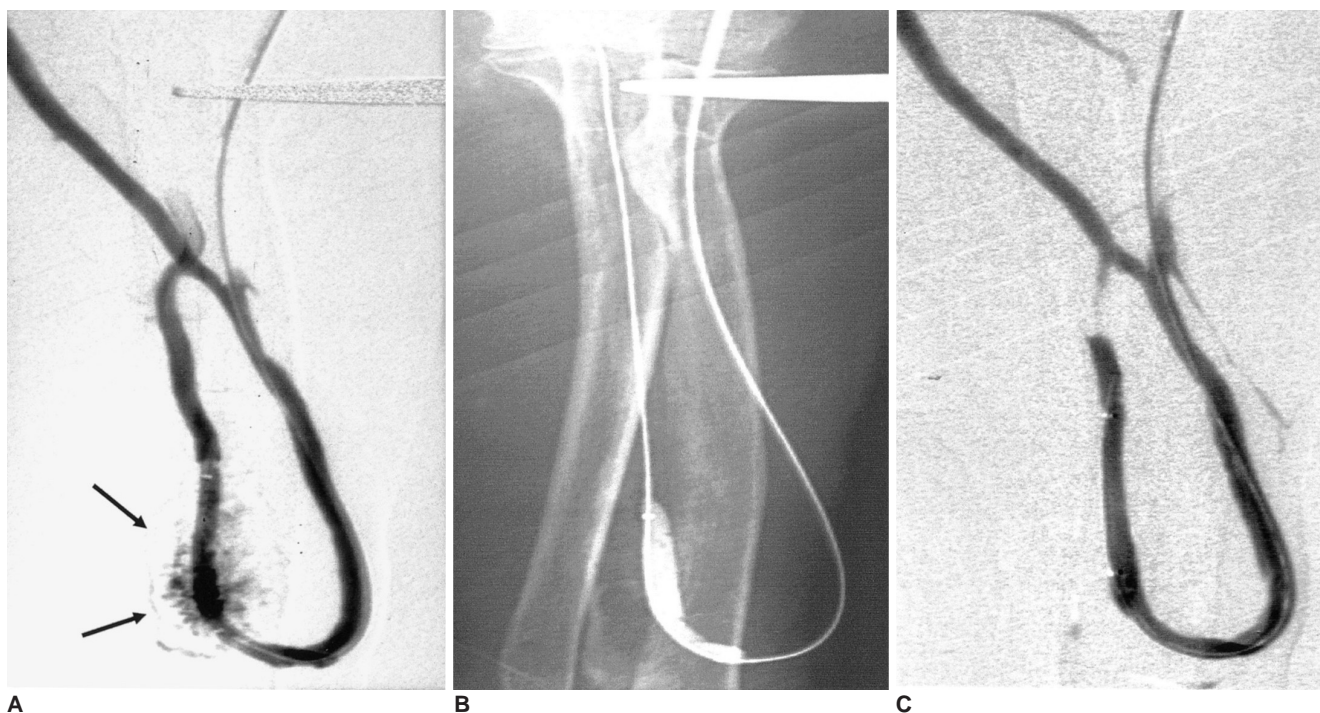


Fig. 4. 55-year-old man with a left radiocephalic fistula.

A. Extravasation from the distal radial artery is shown.

B. Blood flow is blocked by an angioplasty balloon for five minutes.

C. A follow-up angiography shows no blood leaking. There are no hemodynamically significant complications.

Endovascular Management of Procedure-Related Complications of Failed Hemodialysis Access Recanalization

defects were 'tacked up' against the vein wall by a prolonged PTA (2–3 min balloon inflation time), with a successful angiographic result and immediate hemodialysis in all 11 patients (4).

Graft Rupture-Extravasation During Thrombolysis or Balloon Dilatation

Graft extravasation from the prior hemodialysis

puncture site was observed in 10/1,662 (0.6%) of graft recanalizations. Control of this complication was achieved by light focal digital pressure or by using a balloon tamponade during the procedure at the site of the extravasation. Special attention is needed in these cases so that the minimum required distal pressure is applied to control the extravasation without compromising the flow via the recanalization graft (4). In this manner, the extravasation

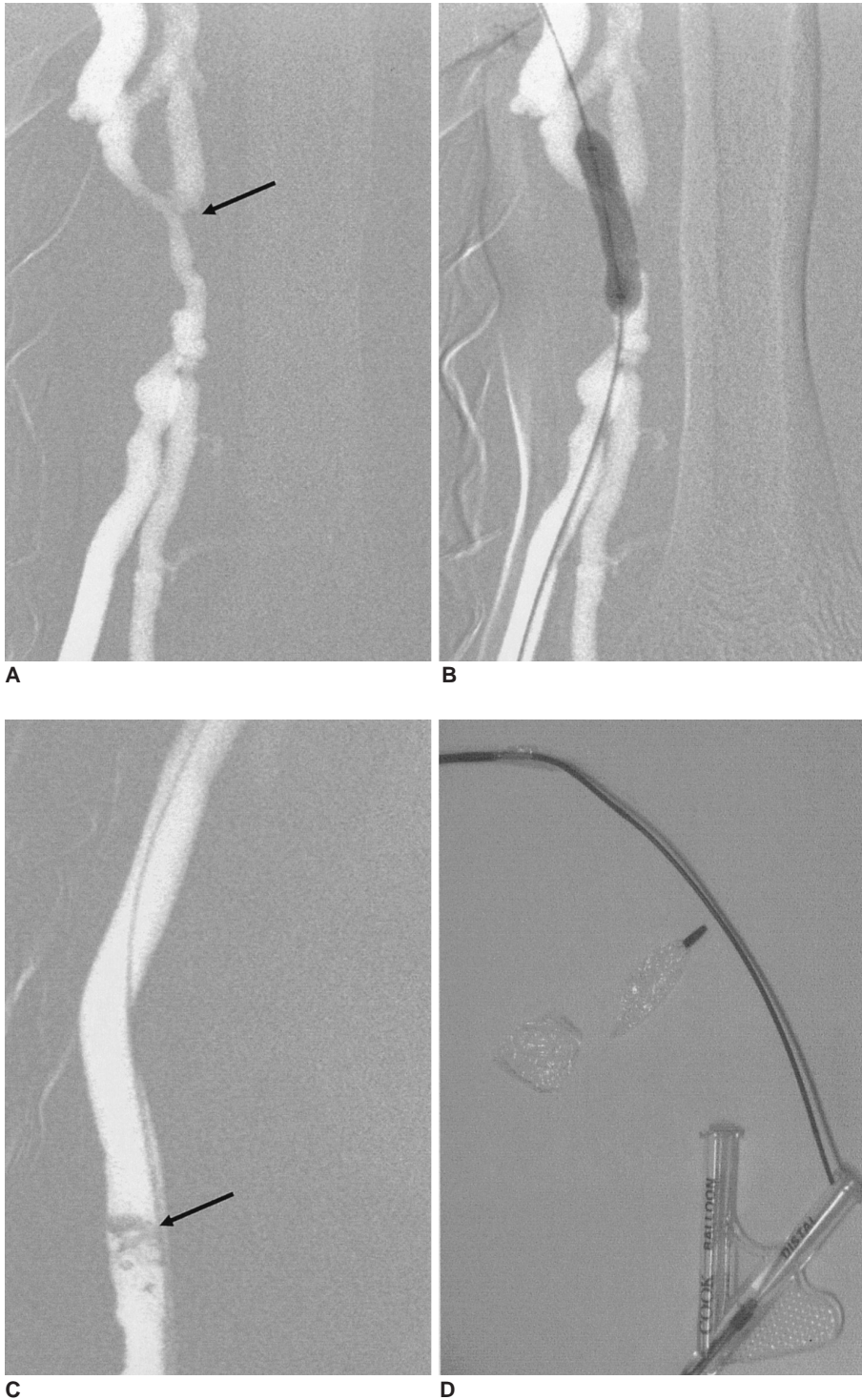


Fig. 5. 56-year-old woman with a left upper arm brachiocephalic graft. **A.** Tight stenosis at the venous anastomosis (arrow). **B.** An angioplasty was attempted, but the balloon ruptured abruptly. **C.** Fragmented balloon is shown in contrast filled vascular lumen. The fragmented balloon was removed by open surgery. **D.** Fragmented balloon specimen, removed.

ceased and the procedure was completed when graft patency was established, allowing long-term utilization for hemodialysis. In extravasation occurred with graft thrombolysis, firm pressure using an elastic bandage was applied. No other attempts at treatment of these grafts were used.

Hematoma and Bleeding

When the only available techniques were purely pharmacologic, percutaneous thrombolysis resulted in a large amount of bleeding and perigraft hemorrhage. The advent of pulse-spray pharmacomechanical thrombolysis (PMT) and pulse-spray mechanical thrombolysis (MT) with heparinized saline lowered this rate, but hemorrhagic complications remain relatively common. For example, the incidence of bleeding necessitating transfusion was reported to be 12.9% with pharmacological thrombolysis, compared to 1.4% with pulse-spray MT (14). Typically hemorrhage and perigraft hematomas occur at the site where the needle and sheath were inserted into the arteriovenous graft. In a large series using pulse-spray MT, less than 3% of the cases were complicated by localized perigraft hematomas, typically at needle sites.

In our cases, subcutaneous hematomas after urokinase thrombolysis were observed in 6/102 (5.9%) of the

thrombosed grafts. The hematomas ranged in size from 1 to 3 cm and they did not enlarged during or immediately following the procedure. The perigraft hematomas were compressed using an elastic bandage. The graft remained patent after the initial recanalization without any signs of hemodynamic insufficiency. They remained stable in size and well contained without compromising the graft's lumen or the normal blood flow in the graft. The grafts were completely recanalized and then successfully used in hemodialysis. These patients were monitored clinically for four weeks following the procedure and complete resolution or a significant decreased of the hematoma was observed.

Arterial Dissection and Rupture

In general, the results of angioplasty depend much less on the number of balloon inflations than on the inflation pressure and duration. Therefore, as a general rule, balloons with the lowest possible compliance should be used. In this way, maximum dilation force with exact definition of the balloon diameter can be achieved even with high inflation pressures. Normally, balloon size is chosen according to the estimated diameter of the nondiseased section. As noted earlier, however, some experienced investigators always use slightly oversized (1 – or

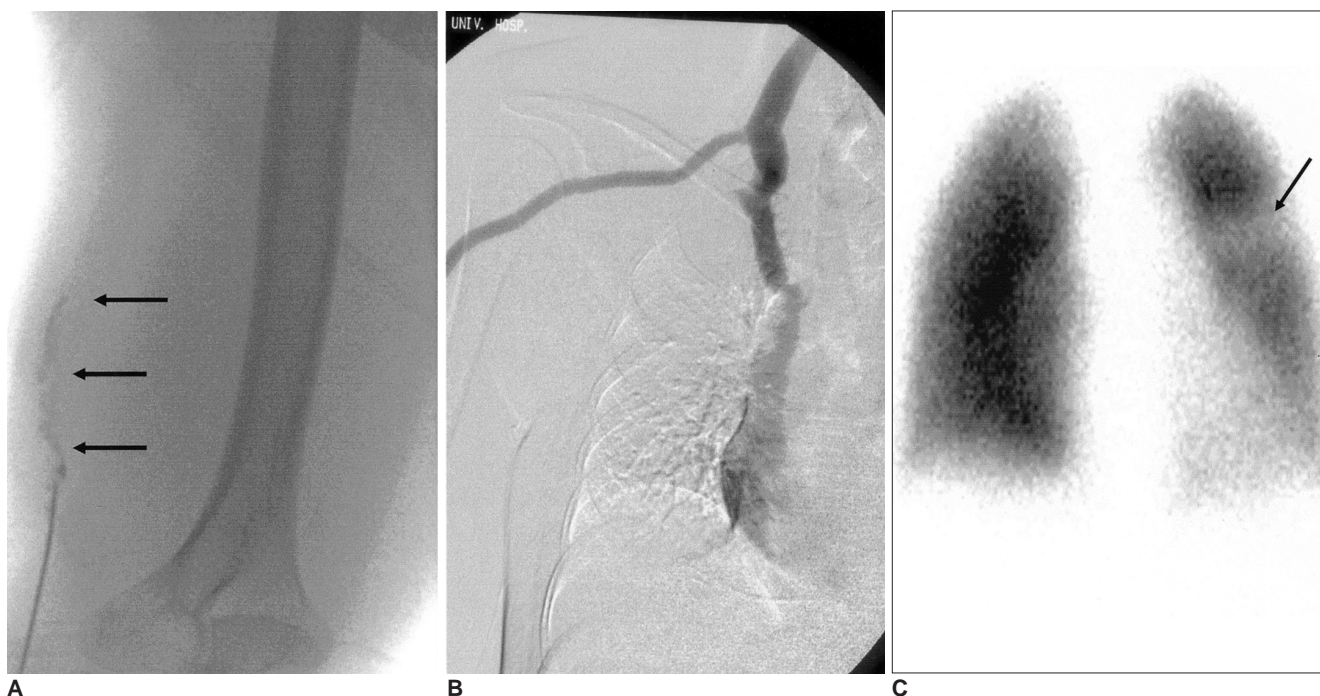


Fig. 6. 48-year-old woman with a right upper arm brachiojugular graft.

A. Intragraft filling defects means thrombi (arrows).

B. Thrombi aspiration with Desilets-Hoffman sheath was performed. During the procedure the patient experienced chest discomfort and dyspnea. The final fistulography shows no abnormal filling defect.

C. Perfusion defect is shown in upper left lobe. The patient was managed by conservative treatment with anticoagulant.

2–mm) balloons. The use of a slightly oversized balloon seems justified as long as inflation pressures do not exceed 4–6 atm; but when high pressures (10–12 atm or more) are used, it is prudent not to use oversized balloon.

In our group, three cases of four arterial ruptures (4/3,430, 0.1%) were treated using the same method used for vein ruptures (Fig. 4). The angioplasty balloon 4–5 mm in diameter over a 0.035 inch guidewire was inflated to 2–4 atm. Arterial dissections were successfully managed with conservative treatment.

Balloon Fragmentation

In all three cases of fragmented balloon (3/3,430, 0.1%) were removed by open surgery (Fig. 5). All cases described above were identified as fragmented, which resulted in the retrieval of the balloon by force under incomplete decompression of the ruptured balloon.

Miscellaneousness

Percutaneous treatment of a thrombosed arteriovenous graft may lead to the lysed or macerated clot moving distally into the central venous system, passing through the right heart into the pulmonary artery, resulting in pulmonary emboli (PE). Pulmonary embolisms following percutaneous thrombolysis remain a vexing problem. Clinically apparent PE occur rarely following these procedures, but subclinical PE appear to be relatively common and their long-term effects remain unknown. There is known to be a large pulmonary vascular reserve, such that occlusion of 30% or more of the pulmonary vascular bed is necessary for there to be a significant hemodynamic effect (15). The volume of the clot that might be dislodged within the thrombus graft has been measured to be between 1.6 and 4.7 ml and estimated to have a maximum volume of 8.4 ml (13), likely much smaller than would cause a clinically significant pulmonary embolism. Two points have been raised regarding PE in

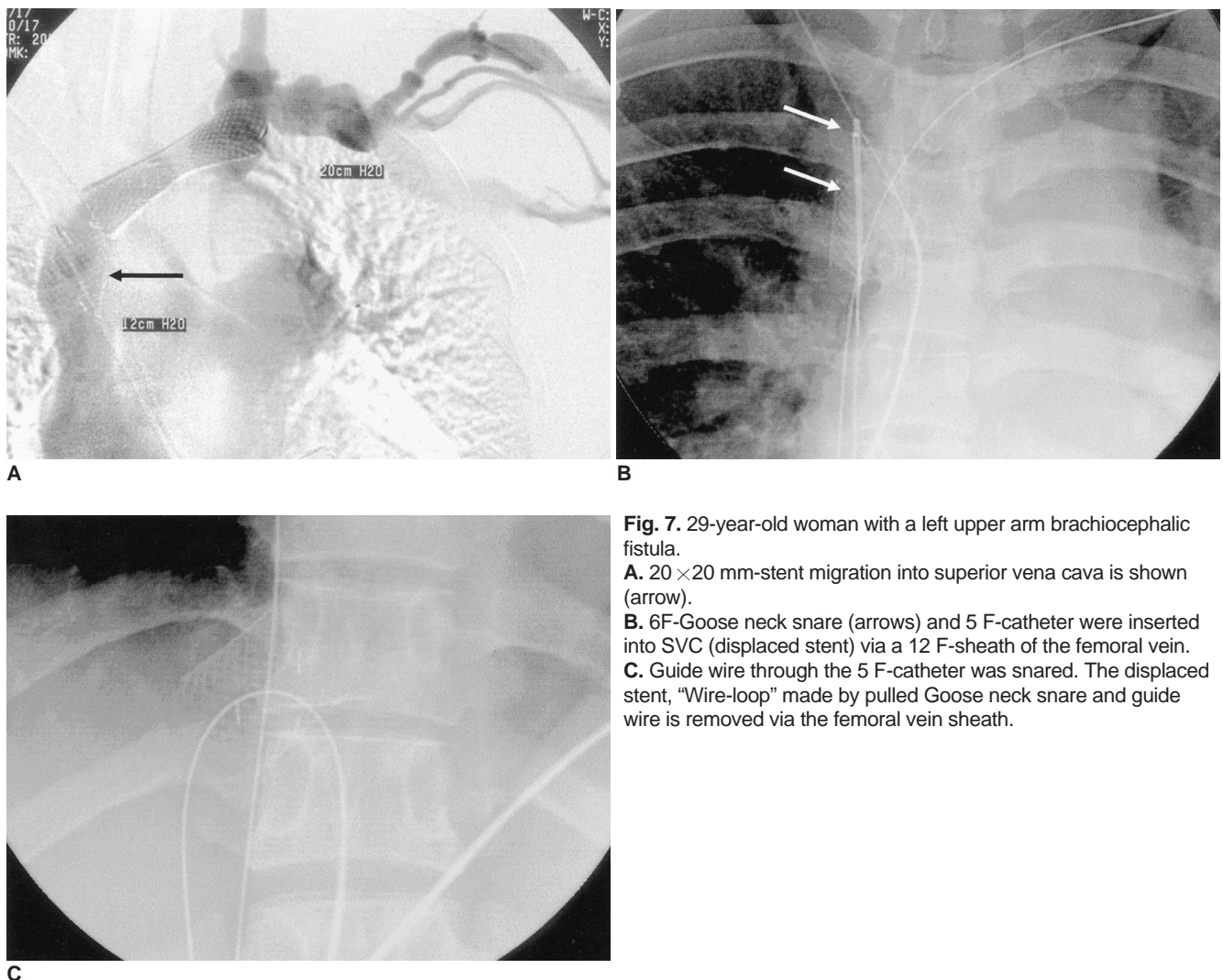


Fig. 7. 29-year-old woman with a left upper arm brachiocephalic fistula.
A. 20 × 20 mm-stent migration into superior vena cava is shown (arrow).
B. 6F-Goose neck snare (arrows) and 5 F-catheter were inserted into SVC (displaced stent) via a 12 F-sheath of the femoral vein.
C. Guide wire through the 5 F-catheter was snared. The displaced stent, “Wire-loop” made by pulled Goose neck snare and guide wire is removed via the femoral vein sheath.

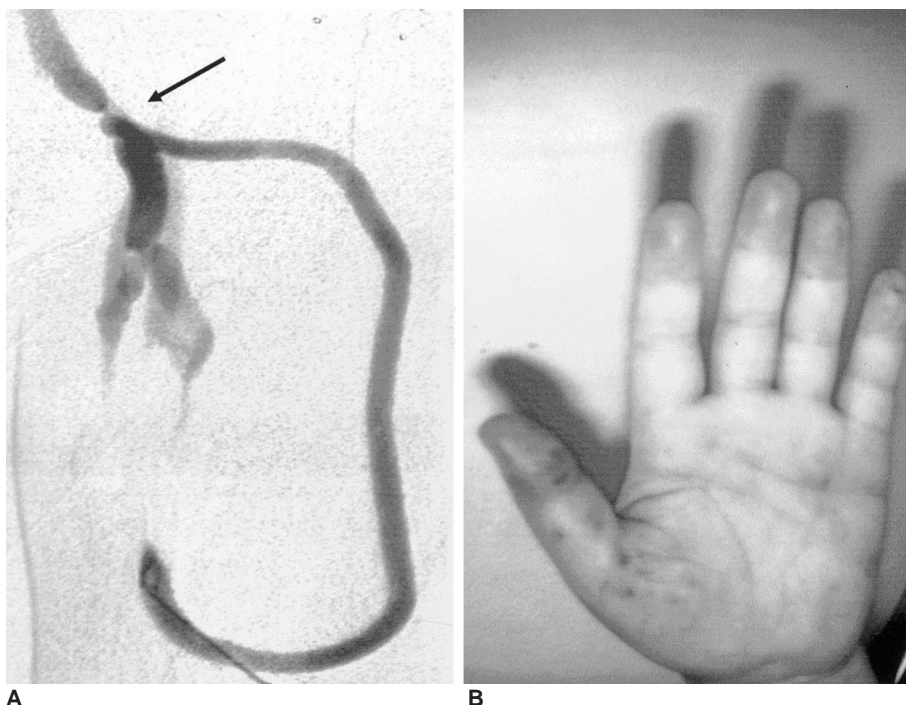
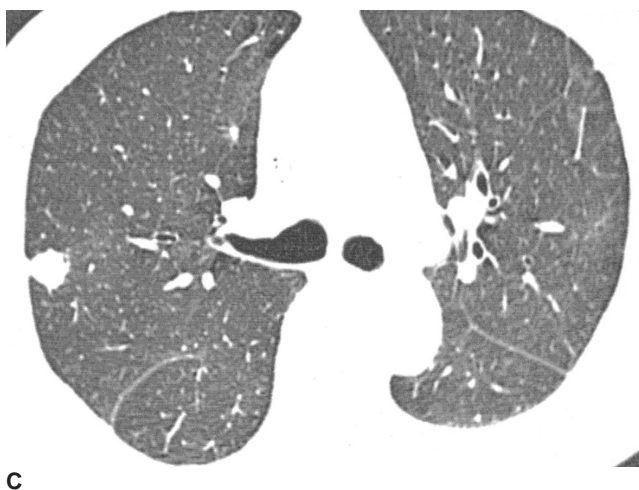

Fig. 8. 63-year-old man with an infected graft and stenosis of the venous anastomosis.

A. The patient had a focal infection in the arterial limb of the graft. Angiography shows focal stenosis at the venous anastomosis (arrow).

B. Angioplasty was performed successfully. After one day, the patient experienced high fever and petechiae in the phalanges.

C. After two weeks, multiple nodules were seen in the periphery of both lung fields. *Yersinia Enterocolitica* was confirmed microbiologically in pleural effusion and blood.



cases of symptomatic pulmonary emboli were observed (Fig. 6). The two patients were managed by conservative treatment.

One of the two patients with cardiac arrest due to hyperkalemia died one day following the procedure. In patients with chronic renal failure, hyperkalemia is always associated with hemodialysis failure. Authors check potassium level and if $K^+ > 7$ mmol/L, start hemodialysis via central line.

The rate of stent misplacement or migration described in the literature is very low (2.5% of all procedures). Management of a displaced stent is successful in 96% of cases (15). Intravascular stents can migrate into cardiac cavities or the pulmonary artery when they are deployed on the venous side. Despite a mean mortality rate of 40% for patients with a migrated foreign body, it was decided to abstain from percutaneous therapy after discussions with the cardiothoracic surgeon and the pneumatologist. The reasons for this decision were varied and include; the clinically asymptomatic nature of the pulmonary embolism; the absence of any signs of pulmonary arterial hypertension at pulmonary angiography; the absence of cardiac arrhythmia; the presence of progressive metastatic disease; the absence of contraindicators for anticoagulants; the risk of a severe iatrogenic complication in case of an attempted percutaneous retrieval; and the hazardous catheterization of the dislodged stent in the right pulmonary artery. The general opinion is that intravascular foreign bodies should be removed as soon as possible to

hemodialysis patients. First, because of the high rate of graft thrombosis, many patients with arteriovenous grafts undergo multiple percutaneous thrombolysis procedures. This potential exposure to recurrent PE may be harmful. Second, many, if not most, hemodialysis patients have preexisting cardiopulmonary disease, including pulmonary hypertension, perhaps rendering them more susceptible to hemodynamic compromise from iatrogenic PE. The true incidence of PE following percutaneous thrombolysis of arteriovenous grafts is unknown, and the incidence may vary depending on the technique used. Clinical trials of PMT and MT have reported a low incidence of PE, in the 0–1.0% range (12). In our series of 708 thrombosed HD access grafts treated by endovascular means, only two

prevent serious complications such as thrombus formation with a high risk of distal embolization, pulmonary embolism, sepsis, and endocarditis, and to prevent myocardial or vascular damage leading to severe arrhythmias and cardiac arrest, perforation of the hemopericardium, and cardiac tamponade. A major determinant of the procedure's success is the selection of the correct stent size. The diameter of the stent must be greater than that of the designated vein to prevent stent migration and to compensate neointimal growth. In our displaced stent group (n=2), one stent was removed by snare (Fig. 7). The other patient with a displaced stent in the pulmonary artery has received conservative follow up treatment for five years.

In one septic embolism, the infected graft was removed surgically (Fig. 8). Hemodialysis patients with prosthetic vascular access devices, such as polytetrafluoroethylene (PTFE) grafts are at an increased risk of infection. Infections are common and the second most common cause of death, because hemodialysis patients are in an immunocompromised state, have diabetes, or suffer from old age. Incidence rates of infection are 1–4%/year in native arteriovenous fistula and 10–20%/year in graft vessels, with *Staphylococcus* being the most common microorganism. This suggests that in our report an impure puncture of the native arteriovenous fistula is the most likely way for infections to facilitate, provoking transient invasion of the bloodstream with bacteria from the local flora. Consequently, extra care must be given to the skin at the vascular access site, and patients with dermatitis near or at the access site should receive antistaphylococcal antibiotic treatment. In addition, good hand hygiene and wearing a mask before puncturing provide the best method of prophylaxis in this context.

In conclusion, this article describes the various complications that occur during management of HD vascular access dysfunction and the immediate percutaneous treatment of these complications can result in relatively high success and patency rates. It is important to ensure that complications be monitored on an ongoing basis. These interventional radiological treatment options contribute significantly to prolonged access survival and therefore in a better quality of life for an increasing number of patients undergoing hemodialysis.

References

1. Sacks D, Marinelli DL, Martin LG, Spies JB. Society of

- Interventional Radiology Technology Assessment Committee. Reporting standards for clinical evaluation of new peripheral arterial revascularization devices. *J Vasc Interv Radiol* 2003;14(9Pt2):395-404
2. Sullivan KL, Besarab A, Bonn J, Shapiro MJ, Gardiner GA Jr, Moritz MJ. Hemodynamics of failing dialysis grafts. *Radiology* 1993;186:867-872
3. Weng FL, Berns JS. Complications of percutaneous treatment of thrombosed hemodialysis access grafts. *Semin Dial* 2003;16:257-262
4. Sofocleous CT, Schur I, Koh E, Hinrichs C, Cooper SG, Welber A, et al. Percutaneous treatment of complications occurring during hemodialysis graft recanalization. *Eur J Radiol* 2003;47:237-246
5. Trerotola SO, Lund GB, Scheel PJ Jr, Savader SJ, Venbrux AC, Osterman FA Jr. Thrombosed dialysis access grafts: percutaneous mechanical declotting without urokinase. *Radiology* 1994;191:721-726
6. Valji K, Bookstein JJ, Roberts AC, Davis GB. Pharmacomechanical thrombolysis and angioplasty in the management of clotted hemodialysis grafts: early and late clinical results. *Radiology* 1991;178:243-247
7. Beathard GA. Percutaneous transvenous angioplasty in the treatment of vascular access stenosis. *Kidney Int* 1992;42:1390-1397
8. Turmel-Rodriguez L, Pengloan J, Blanchier D, et al. Insufficient dialysis shunts: improved long-term patency rates with close hemodynamic monitoring, repeated percutaneous balloon angioplasty and stent placement. *Radiology* 1993;187:273-278
9. Beathard GA. Angioplasty for arteriovenous grafts and fistulae. *Semin Nephrol* 2002;22:202-210
10. Rundback JH, Leonardo RF, Poplausky MR, Rozenblit G. Venous rupture complicating hemodialysis access angioplasty: percutaneous treatment and outcomes in seven patients. *AJR Am J Roentgenol* 1998;171:1081-1084
11. Funaki B, Szymanski GX, Leef JA, Rosenblum JD, Burke R, Hackworth CA. Wallstent deployment to salvage dialysis graft thrombolysis complicated by venous rupture: early and intermediate results. *AJR Am J Roentgenol* 1997;169:1435-1437
12. Beathard GA, Welch BR, Maidment HJ. Mechanical thrombolysis for the treatment of thrombosed hemodialysis access grafts. *Radiology* 1996;200:711-716
13. Trerotola SO, Johnson MS, Shah H, Namyslowski J. Backbleeding technique for treatment of arterial emboli resulting from dialysis graft thrombolysis. *J Vasc Interv Radiol* 1998;9(1Pt1):141-143
14. Cohen MA, Kumpe DA, Durham JD, Zwerdinger SC. Improved treatment of thrombosed hemodialysis access sites with thrombolysis and angioplasty. *Kidney Int* 1994;46:1375-1380
15. Slonim SM, Dake MD, Razavi MK, Kee ST, Samuels SL, Rhee JS, et al. Management of misplaced or migrated endovascular stents. *J Vasc Interv Radiol* 1999;10:851-859