

Nonossifying fibroma: A possible pitfall in F18-FDG-PET/CT imaging of Hodgkin's disease

Manuela Pagano, MD; Mara Berta, MD; Anna Maria Postini, MD; Maurizio Bianchi, MD; Adalberto Brach del Prever, MD; Claudio Defilippi, MD; Umberto Ficola, MD; and Angelina Cistaro, MD

A 14-year-old girl was examined for a right lateral neck swelling and radiographic mediastinal widening. Biopsy of a right supraclavicular lymph node demonstrated the nodular sclerosing form of Hodgkin's lymphoma. An 18F-fluorodeoxyglucose-positron emission tomography/computed tomography (F18-FDG-PET/CT) study showed several pathological areas of lymph-node uptake in the upper mediastinum and right distal tibia. Radiography of the tibia revealed a nonossifying fibroma in the site corresponding to the distal tibial uptake. The PET appearance of benign fibro-osseous lesions may be similar to those of skeletal metastases. Information obtained by the CT component of the PET/CT study and by conventional radiography can be useful in preventing erroneous interpretations of F18-FDG-PET uptake.

Introduction

Hodgkin's lymphoma may involve all organ systems, including thorax, abdomen, and bone (1). F18-FDG-PET/CT is a hybrid diagnostic technique used in the staging of many malignant neoplasms. It can identify lesions and characterize them metabolically (2, 3). A combination of coregistered anatomical and biological images permits a dual gain in diagnostic accuracy.

Studies have shown that F18-FDG-PET/CT may have a higher diagnostic value than conventional diagnostic imaging modalities and can reliably help differentiate between active tumor and fibrosis or necrosis after treatment in adult

patients affected by Hodgkin's lymphoma (4, 5). In recent years, F18-FDG-PET/CT has also become a very useful imaging method in the evaluation of pediatric patients (1, 4, 6).

Case report

A 14-year-old girl was examined for a history of right lateral neck swelling, without other subjective symptoms or laboratory abnormalities. Radiography of the chest showed an mediastinal widening. Biopsy of a right supraclavicular lymph node was consistent with the nodular sclerosing form of Hodgkin's lymphoma. Bone-marrow aspiration and biopsy were negative. The patient was referred to the PET Center in order to complete the staging.

The study was acquired with a Discovery-ST PET/CT system (General Electric), 60 minutes after intravenous injection of FDG (248 MBq). At the time of the tracer injection, the patient had fasted for more than six hours, and the glucose blood level was 81 mg/dl. The data were acquired in 3D mode, with attenuation correction calculated by coregistered CT images.

The F18-FDG-PET/CT study showed several areas of pathological lymph-node uptake in the upper mediastinum (Fig. 1). The PET scan of the lower limbs showed a right tibial uptake (Fig. 2). Radiography of the tibias revealed a lucent lesion, with findings consistent with nonossifying fibroma (Fig. 3).

Citation: Pagano M, Berta M, Postini AM, Bianchi M, del Prever A, Defilippi C, Ficola U, Cistaro A. Nonossifying fibroma: A possible pitfall in F18-FDG-PET/CT imaging of Hodgkin's disease. *Radiology Case Reports*. [Online] 2011;6:217.

Copyright: © 2011 The Authors. This is an open-access article distributed under the terms of the Creative Commons Attribution-NonCommercial-NoDerivs 2.5 License, which permits reproduction and distribution, provided the original work is properly cited. Commercial use and derivative works are not permitted.

Drs. Pagano, Berta, Postini, Bianchi, and del Prever are in the Paediatric Oncology Department, and Dr. Defilippi is in the Operative Unit of Radiology, all at the Regina Margherita Children's Hospital, Turin, Italy. Dr. Ficola is in the Operative Unit of Nuclear Medicine, La Maddalena, Palermo, Italy. Dr. Cistaro is at the Positron Emission Tomography Center IRMET S.p.A., Turin, Italy. Contact Dr. Pagano at m.pagano9@virgilio.it.

Competing Interests: The authors have declared that no competing interests exist.

DOI: 10.2484/rcr.v6i2.271

Nonossifying fibroma: A possible pitfall in F18-FD-PET/CT imaging of Hodgkin's disease

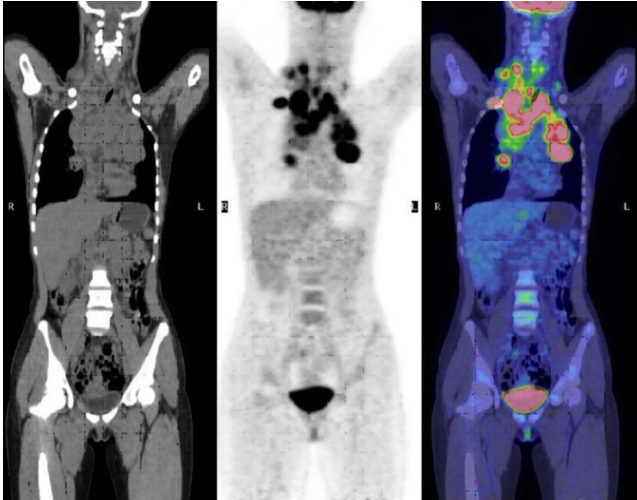


Figure 1. 14-year-old girl with nonossifying fibroma. Multiple enlarged mediastinal and right cervical lymph nodes are noted on CT (left), with increased uptake on coronal F18-FDG PET (middle) and F18-FDG PET/CT fusion image (right)

The patient was treated according to the AIEOP protocol LH-2004 for Hodgkin's lymphoma: six cycles of Cyclophosphamide, Vincristine, Procarbazine, and Prednisolone

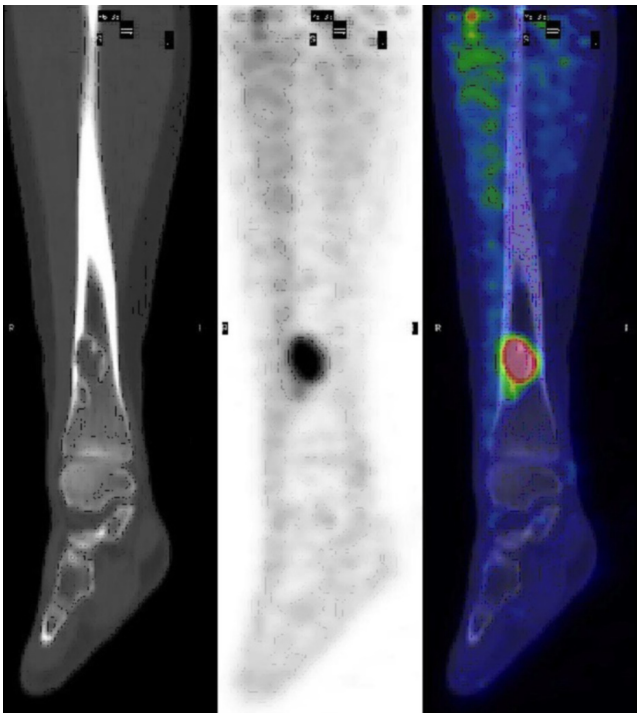


Figure 2. 14-year-old girl with nonossifying fibroma. Lucent lesion is noted in the distal right tibia on sagittally reformatted CT (left). Increased uptake is noted in this lesion on coronal F18-FDG PET (middle) and F18-FDG PET/CT fusion image (right).

(COPP), with interval administration of Adriamycin, Bleomycin, and Vinblastin (ABV), followed by radiotherapy "mini-mantle" therapy (DFT 14.4 Gy).

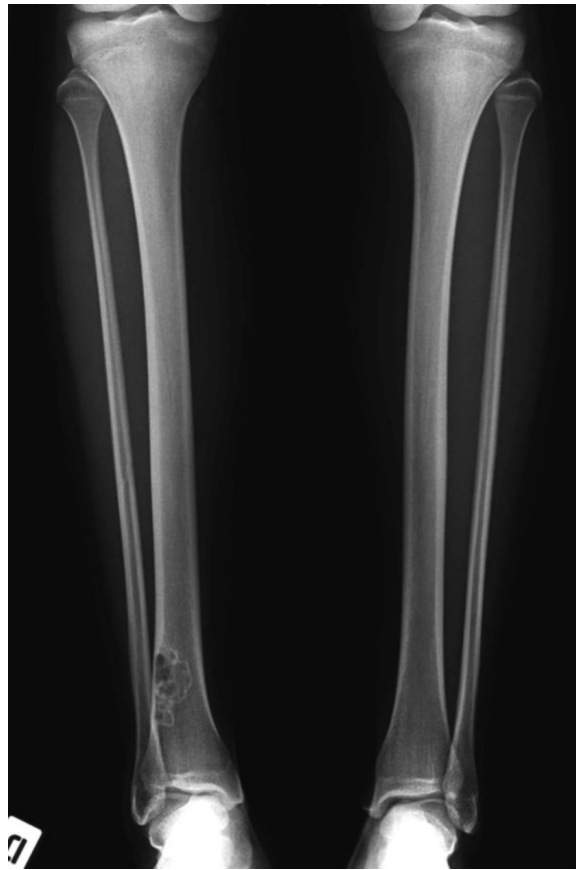

Figure 3. 14-year-old girl with nonossifying fibroma. AP radiograph of both tibias, showing an eccentric, lucent lesion in the distal right tibia with a well-demarcated, sclerotic border, consistent with a nonossifying fibroma.

The F18-FDG-PET study during chemotherapy showed complete resolution of the lymph-node uptake and a persistent accumulation of tracer in the tibia. The evaluation at the end of treatment indicated complete lymphoma remission (Fig. 4). However, tibial uptake was unchanged (Fig. 5).

Discussion

Diagnostic imaging methods, such as conventional radiographic, sonographic, and cross-sectional imaging, are excellent tools for evaluating Hodgkin's disease in pediatric patients (1). F18-FDG-PET/CT recently achieved an important role in the initial staging of disease. This method is also important during chemotherapy (evaluation of early response), in radiotherapy planning, at the end of treatment, and during followup (1, 2, 6, 7). However, FDG is not a tumor-specific substance. FDG accumulation may be observed in a variety of benign entities (2, 7) because activated granulocytes and macrophages may display signifi-

Nonossifying fibroma: A possible pitfall in F18-FD-PET/CT imaging of Hodgkin's disease

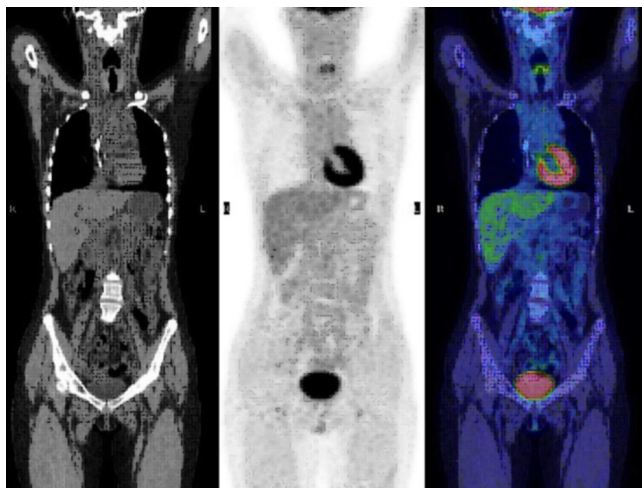


Figure 4. 14-year-old girl with nonossifying fibroma. Coronally reformatted CT (left), coronal F18-FDG PET (middle), and F18-FDG PET/CT fusion image (right). The lymphadenopathy noted in Figure 1 has completely resolved.

cantly increased glucose consumption (infection, G-CSF administration, radiation therapy, fracture) (8). FDG biodistribution also can be affected by various physiologic factors, such as brown adipose tissue (2), blood glucose levels, and muscle uptake (9). All these conditions may give rise to false-positive results in staging, in evaluation of treatment response, and in post-treatment assessment and followup.

Nonossifying fibroma (NOF) is a common benign finding encountered in radiology. It is a well-circumscribed solitary proliferation of fibrous tissue. NOF is more common in males than females, and may occur in as many as 35% of all children (10-12), with 75% of cases presenting in the second decade of life (10, 11, 13). Clinically, NOF is asymptomatic and is usually discovered by chance on a radiograph. NOF is usually located in the metaphysis or diaphyseal junction of the femur or tibia (10-15). In general, NOF regresses spontaneously. During the involutional phase, osteoblastic activity increases as the lesion is replaced by new bone (13). Conventional radiography, CT, and MRI characteristics of NOF have been extensively studied (10-15). On unenhanced radiographs, a nonossifying fibroma appears as an eccentric radiolucent lesion with thinned cortex, a multilocular appearance, and often a sclerotic margin. Some authors have reported NOF as being metabolically active on F18-FDG-PET images (10, 13). Such activity, probably independent of lesion size, varies among patients and over time, as indicated by their F18-FDG uptake on PET (13).

Conclusion

The PET appearance of nonossifying fibroma can mimic bone metastasis (13). The possible mechanism for F18-FDG uptake in such cases is similar to that for acute fractures, consisting of increased blood flow and osteoblastic activity.

When PET reveals metabolically active osseous abnormalities in children who are at risk for bone metastases, benign fibro-osseous lesions should be considered in the differential diagnosis before additional diagnostic procedures are undertaken. Information obtained by the CT component of the PET/CT study and by conventional radiography is essential to characterize the nature of these lesions and to prevent erroneous interpretations of the F18-FDG uptakes.

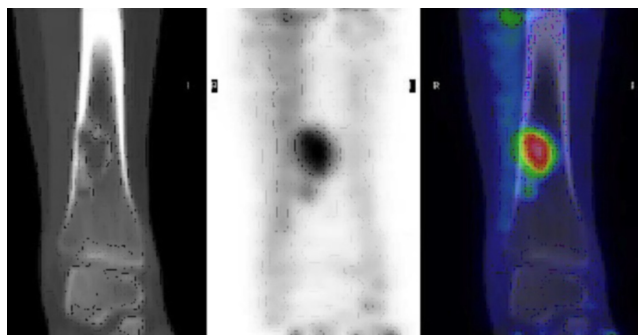


Figure 5. 14-year-old girl with nonossifying fibroma. Lucent lesion (left) is noted in the distal right tibia on coronally reformatted CT. Increased uptake is again noted in this lesion on coronal F18-FDG PET (middle) and F18-FDG PET/CT fusion image (right).

References

1. Toma P, Granata C, Rossi A, Garaventa A. Multimodality imaging of Hodgkin disease and non-Hodgkin lymphomas in children. *Radiographics* 2007; 27(5):1335-54 [PubMed]
2. Castellucci P, Zinzani P, Pourdehnad M, Alinari L, Nanni C, Farsad M, Battista G, Tani M, Stefoni V, Canini R, Monetti N, Rubello D, Alavi A, Franchi R, Fanti S. 18-F-FDG PET in malignant lymphoma: significance of positive findings. *Eur J Nucl Med Mol Imaging* 2005; 32(7):749-56 [PubMed]
3. Montravers F, de Bazelaire C, Kerrou K, Farges C, Huchet V, Talbot JN, Frija J, de Kerviler E. Imaging and PET-CT of adult and childhood lymphoma. *J Radiol* 2008; 89(3 pt 2):371-84 [PubMed]
4. Hines-thomas M, Kaste SC, Hudson MM, Howard SC, Liu WA, Wu J, Kun LE, Shulkin BL, Krasin MJ, Metzger ML. Comparison of gallium and PET scans at diagnosis and follow-up of pediatric patients with Hodgkin lymphoma. *Pediatr Blood Cancer* 2008; 51(2):198-203 [PubMed]
5. Moog F, Bangert M, Diederichs CG, Guhlmann A, Kotzerke J, Merkle E, Kolokythas O, Herrmann F, Reske SN. Lymphoma: role of whole-body 2-deoxy-2-[F-18]fluoro-D-glucose (FDG) PET in nodal staging. *Radiology* 1997; 203(3):795-800 [PubMed]

Nonossifying fibroma: A possible pitfall in F18-FD-PET/CT imaging of Hodgkin's disease

6. Mardis N, Wong CY. The accuracy of PET(CT) in evaluating pediatric lymphoma. *J Pediatr Hematol Oncol* 2007; 29(9):667-68 [\[PubMed\]](#)
7. Castellucci P, Nanni C, Farsad M, Alinari L, Zinzani P, Stefoni V, Battista G, Valentini D, Pettinato C, Margengo M, Boschi S, Canini R, Baccarani M, Monetti N, Franchi R, Rampin L, Fanti S, Rubello D. Potential pitfalls of 18-F-FDG PET in a large series of patients treated for malignant lymphoma: prevalence and scan interpretation. *Nucl Med Commun* 2005; 26(8):689-94 [\[PubMed\]](#)
8. Metser U, Miller E, Lerman H, Even-Sapir E. Benign non physiologic lesion with increased 18F-FDG uptake on PET/CT: characterization and incidence. *AJR Am J Roentgenol* 2007; 189(5):1203-10 [\[PubMed\]](#)
9. Barrington SF, O'Doherty MJ. Limitation of PET for imaging lymphoma. *Eur J Nucl Med Mol Imaging* 2003; 30(suppl 1): S117-27 [\[PubMed\]](#)
10. Betsy M, Kupersmith LM, Springfield DS. Metaphyseal fibrous defects. *J Am Acad Orthop Surg* 2004; 12:89-95 [\[PubMed\]](#)
11. Brant WE, Helms CA. *Fundamentals of diagnostic radiology*, 2nd ed. Philadelphia, PA: Lippincott Williams & Wilkins, 1999:969-971
12. Caffey J. On fibrous defects in cortical walls of growing tubular bone: their radiologic appearance, structure, prevalence, natural course, and diagnostic significance. *Adv Pediatr* 1955; 7:13-51 [\[PubMed\]](#)
13. Goodin GS, Shulkin BL, Kaufman RA, Mc Carville MB. PET/CT Characterization of Fibrous Defects in Children: 18F-FDG Uptake Can Mimic Metastatic Disease. *AJR* 2006; 187:1124-28 [\[PubMed\]](#)
14. Jee WH, Choe BY, Kang HS et al. Nonossifying fibroma: characteristics at MR imaging with pathologic correlation. *Radiology* 1998; 209:197-202 [\[PubMed\]](#)
15. Smith SE, Kransdorf MJ. Primary musculoskeletal tumors of fibrous origin. *Semin Musculoskelet Radiol* 2000; 4:73-88 [\[PubMed\]](#)