

CASE REPORT

ADVANCED

TCT CONNECT 2021 CLINICAL CASE

# Total Percutaneous Revascularization of the Hand to Treat Refractory Digital Ischemia in Advanced Systemic Sclerosis



Kevin A. Honan, DO,<sup>a</sup> Lily Romero-Karam, MD,<sup>b</sup> Maureen Mayes, MD,<sup>b</sup> Salman A. Arain, MD<sup>c</sup>

## ABSTRACT

We present the case of a young woman with systemic sclerosis (SSc) and refractory digital ulceration who was successfully treated with percutaneous revascularization of chronically occluded ulnar and radial arteries. To our knowledge, this is the first detailed report of limb salvage in SSc-induced hand ischemia in which contemporary endovascular techniques were used. (**Level of Difficulty: Advanced.**) (J Am Coll Cardiol Case Rep 2022;4:161-166) © 2022 The Authors. Published by Elsevier on behalf of the American College of Cardiology Foundation. This is an open access article under the CC BY-NC-ND license (<http://creativecommons.org/licenses/by-nc-nd/4.0/>).

## HISTORY OF PRESENTATION

A 39-year-old woman presented to the emergency room with painful ulceration of her right second and third digits. She had been hospitalized multiple times in the year leading up to presentation for similar presentations of intractable pain of these same digits. The patient was treated with analgesic agents for the ulcers and with apixaban and sildenafil for the digital ischemia, and she was admitted for epoprostenol administration.

## LEARNING OBJECTIVES

- To demonstrate the novel use of percutaneous intervention techniques to treat digital ischemia in the upper extremities.
- To understand the role of revascularization in the treatment of SSc-associated chronic digital ischemia.

The patient's initial physical examination was notable for gangrenous lesions involving the right second digit and third digits, with patchy areas of erythema and violaceous discoloration at the perimeter of the nailbeds (**Figure 1**). There was no evidence of calcinosis, telangiectasias, or skin thickening. Mobility was severely reduced in both digits, and there was reduced sensation to touch. The patient reported severe pain at rest and was referred for upper extremity angiography on the basis of her presentation and lack of response to standard digital ischemia therapies.

## PAST MEDICAL HISTORY

The patient had a past medical history of autoimmune hepatitis, hypertension, limited cutaneous systemic sclerosis (SSc), and severe Raynaud phenomenon. She received a diagnosis of SSc 1 year before presentation on the basis of symptoms of

From the <sup>a</sup>Department of Internal Medicine, The University of Texas Health Science Center at Houston/Memorial Hermann Hospital, Texas Medical Center, Houston, Texas, USA; <sup>b</sup>Department of Rheumatology, The University of Texas Health Science Center at Houston/Memorial Hermann Hospital, Texas Medical Center, Houston, Texas, USA; and the <sup>c</sup>Department of Cardiology, The University of Texas Health Science Center at Houston/Memorial Hermann Hospital, Texas Medical Center, Houston, Texas, USA.

The authors attest they are in compliance with human studies committees and animal welfare regulations of the authors' institutions and Food and Drug Administration guidelines, including patient consent where appropriate. For more information, visit the [Author Center](#).

Manuscript received July 14, 2021; revised manuscript received November 29, 2021, accepted December 7, 2021.

**ABBREVIATIONS  
AND ACRONYMS**

**ANA** = antinuclear antibody  
**CLI** = critical limb ischemia  
**SsC** = systemic sclerosis  
**UAO** = ulnar artery occlusion

Raynaud phenomenon, ischemic digital ulcers, abnormal nailfold capillaries, and a positive antinuclear antibody (ANA) 1:1,280 titer.

**DIFFERENTIAL DIAGNOSIS**

The differential diagnosis for our patient's presentation included a range of connective tissue diseases with the potential to cause Raynaud phenomenon and digital ischemia, including systemic lupus erythematosus, Sjögren syndrome, and mixed connective tissue disease. Other causes of digital ischemia such as vasculitis (eg, cryoglobulinemic vasculitis) were also considered.

**INVESTIGATIONS**

The patient had a positive ANA 1:1,280 titer in a centromere pattern. Immunologic work-up on admission showed negative titers for anti-Scl-70, anti-RNA polymerase III, anti-PM/Scl, anti-smooth muscle, anti-RNP, and anti-SSA/SSB antibodies, and it showed a rheumatoid factor level of 15 IU/mL. Computed tomography angiography of the right upper extremity 3 months before presentation showed a long occlusion of the right radial artery, a short occlusion of the ulnar artery near the wrist, and partial reconstitution of the superficial palmar arch. Notably, she had not had previous cannulations of the right radial or ulnar arteries before her presentation.

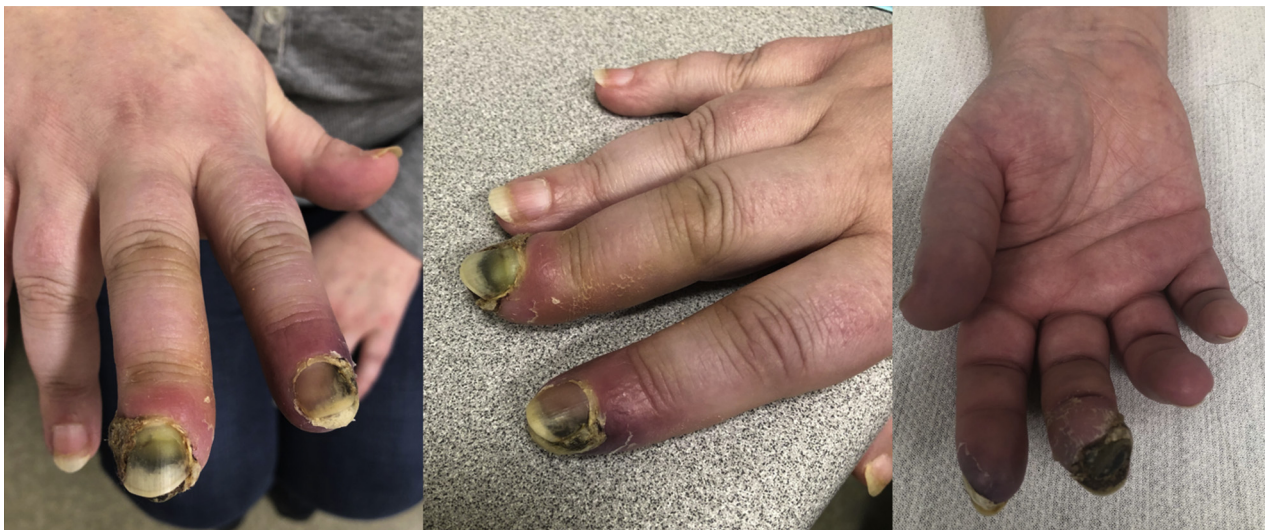**MANAGEMENT**

The patient underwent right upper extremity angiography through the right common femoral artery (Figures 2A and 2B). We obtained diagnostic images of the right upper extremity by using a 4-F multipurpose catheter positioned within the brachial artery. We exchanged this for a 6-F 90-cm long sheath for the intervention. We used heparin to maintain an activated clotting time of >300 seconds throughout the procedure.

**ULNAR ARTERY INTERVENTION.** We used a Sion (Asahi Intecc) wire to deliver a 150-cm TurnPike LP (Teleflex) microcatheter to the proximal cap of the occluded ulnar artery. We crossed the proximal occlusion by using a Gaia-2 (Asahi Intecc) wire and created a channel by advancing the TurnPike LP catheter over the wire. We then performed sequential angioplasty using 2.0 and 3.0 × 30 mm balloons. We treated an "undilatable" segment of the ulnar artery with a 3.0-mm Chocolate (Medtronic) percutaneous transluminal angioplasty balloon. Postangioplasty angiography showed antegrade flow through the ulnar artery and opacification of the superficial palmar arch and the palmar digital branches (Figures 3A to 3C).

**RADIAL ARTERY INTERVENTION.** We redirected the TurnPike LP catheter into the right radial artery and used a Gaia-2 wire to cross the proximal two-thirds of the occlusion. We initially had difficulty in

**FIGURE 1** Patient With Dry Gangrene of the Second and Third Digits of the Right Hand



negotiating the wire across the distal occlusion; however, we were able to form a wire “knuckle” and advance it into the true lumen by means of subintimal tracking and re-entry (Figures 4A to 4C). We used the TurnPike LP catheter to exchange the knuckled wire for a Sion wire, and we treated the radial artery with a 2.5 × 150 mm NanoCross (Medtronic) balloon proximally and a 2.5 × 80 mm Chocolate balloon distally. Final angiography showed brisk antegrade flow through both the ulnar and radial arteries and opacification of both the superficial and deep palmar arches (Figure 5).

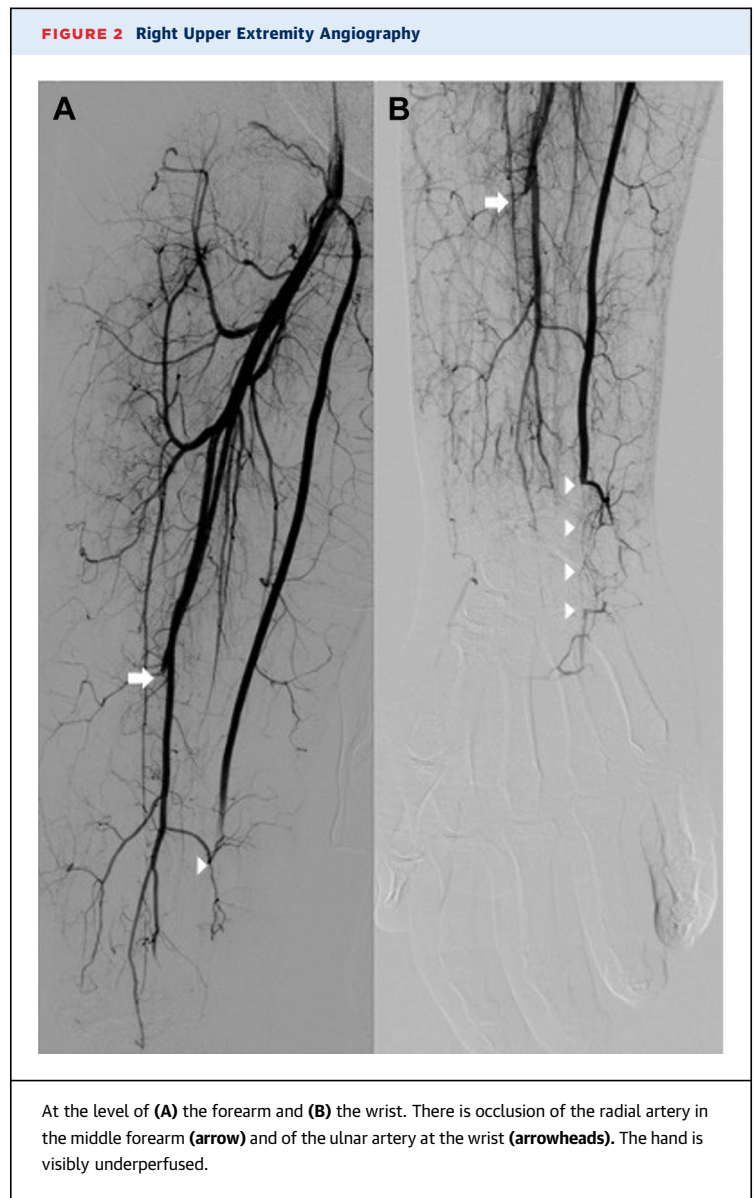
The patient had immediate improvement in hand skin color following intervention. She reported being able to “feel her fingers” again and could flex the second and third digits. She was treated with aspirin, clopidogrel, and epoprostenol. She had minimal residual pain in both digits at discharge. Her outpatient regimen included amlodipine, aspirin, sildenafil, and apixaban. The patient was monitored closely in the rheumatology clinic and had complete healing of her fingertips by 4 months (Figure 6).

## DISCUSSION

As many as 90% of patients with SSc experience vascular complications and symptoms of Raynaud phenomenon, with one-half developing arterial occlusions and subsequent digital ischemia.<sup>1</sup> The etiology of digital ischemia involves a combination of prolonged and recurrent vasospasm of the medium and small arteries of the limb, in situ thrombosis, and chronic changes in vascular anatomy such as vessel wall hypertrophy. The net result consists of vessel occlusion and chronic hypoperfusion of the digits.

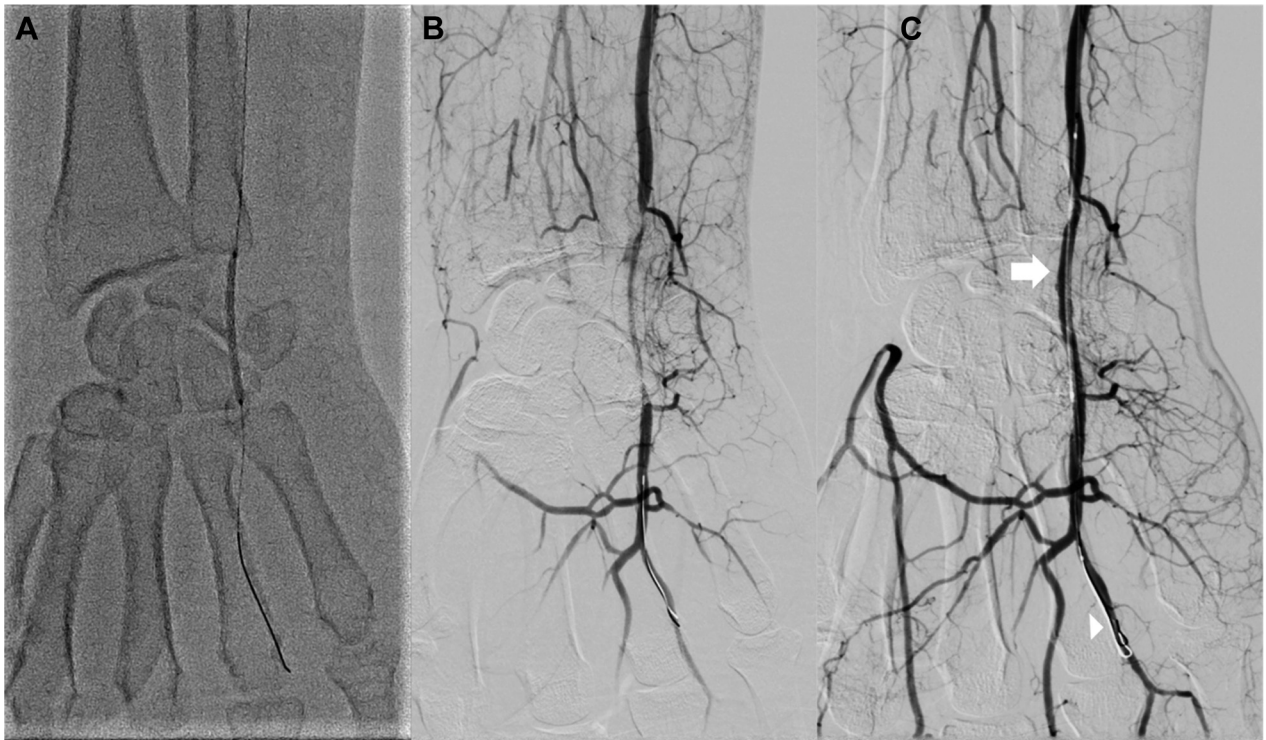
Refractory digital ischemia and ulceration associated with SSc are notoriously difficult to reverse. Most patients are treated with supportive care and medical therapy to prevent further tissue damage and avoid amputation. Some patients find symptomatic relief from surgical sympathectomy or microsurgical vein reconstruction, but the data are limited, and the clinical efficacy of these procedures in reversing ischemia is poor.<sup>2-4</sup> Revascularization of the SSc-associated arterial lesions, surgical or otherwise, is seldom performed.

Many patients with SSc and digital ulcers have ulnar artery occlusion (UAO) and interruption of at least 1 of the palmar arches. Radial artery occlusion is less common. A study by Frerix et al<sup>5</sup> reported a UAO prevalence of 21.5% in a cohort of 79 patients with SSc. Interestingly, the prevalence of UAO was higher in patients with localized cutaneous SSc (like our patient) compared with patients with cutaneous

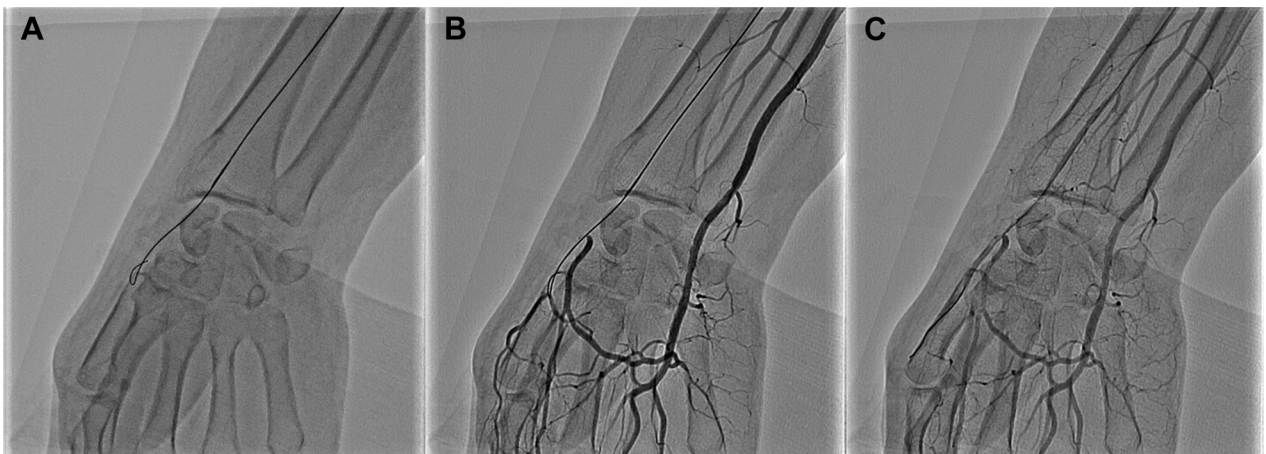


disease (24.4% vs 9.0%). Recurrent digital ulcerations occurred more frequently in patients with UAO compared with patients with SSc but without an occlusion.

Percutaneous revascularization is commonly performed for limb salvage in lower extremity atherosclerotic disease and has been shown to be safe in small cohorts of patients with other forms of critical limb ischemia (CLI).<sup>6,7</sup> Patients with lower extremity CLI of any cause often present with chronic occlusion of small-caliber ( $\leq 3$ -mm diameter) arteries, which can be successfully revascularized using contemporary endovascular techniques in most cases. We hypothesized that this approach could be used to treat refractory upper extremity digital ischemia in our

**FIGURE 3** Revascularization of the Occluded Right Ulnar Artery

(A to C) Antegrade flow within the treated segment of the ulnar artery (**arrow in C**) and opacification of the common palmar digital branches (**arrowhead in C**) after angioplasty are noted.

**FIGURE 4** Revascularization of the Occluded Right Radial Artery

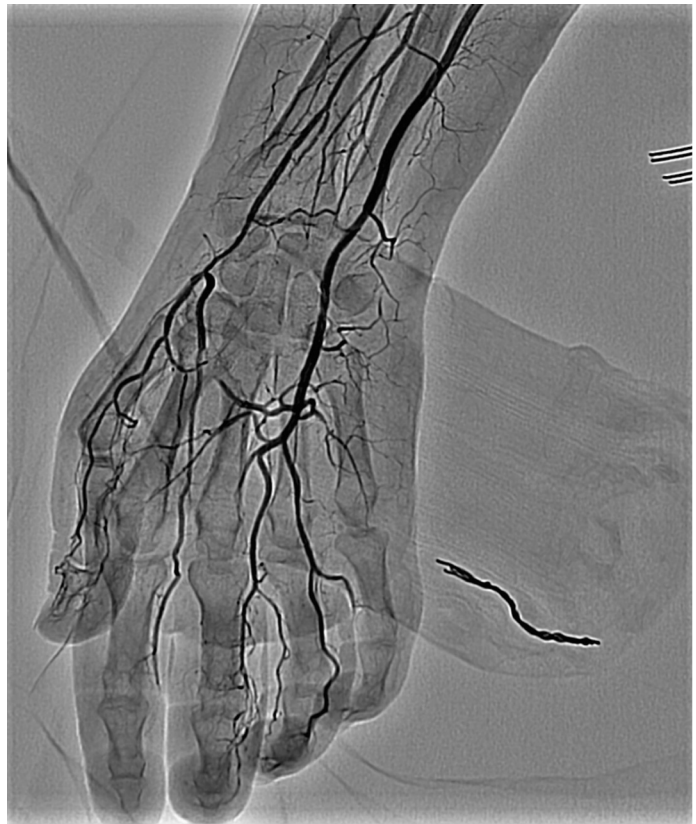
(A) The TurnPike LP catheter (Teleflex) and Gaia-2 wire (Asahi Intecc) were used to cross the radial artery occlusion proximally. A wire knuckle was used to cross (B) the distal occlusion into (C) the patent princeps pollicis artery.

patient. We decided to treat both arteries in the same setting to expedite wound healing by maximizing flow to the ischemic digits and hopefully minimizing the risk for further tissue loss or recurrence. Although a small case series alluded to the potential utility of angiography and angioplasty in patients with SSc, this case represents the first detailed account of successful arterial revascularization in SSc-associated critical hand ischemia.<sup>8</sup> One potential limitation of the procedure is radiation exposure to the patient's extremity and the operator. We minimized the patient's risk by using standard radiation management strategies such as low frame rates (7.5/s), region of interest fluoroscopy, limited cine, and monitoring of the radiation dose to the patient's hand. Furthermore, we used a ceiling-mounted radiation shield and a table-mounted lead skirt to minimize operator exposure. The total dose delivered to the patient was 315 mGy over 89 minutes, similar to, if not lower than, the dose expected after a complex peripheral intervention.

#### FOLLOW-UP

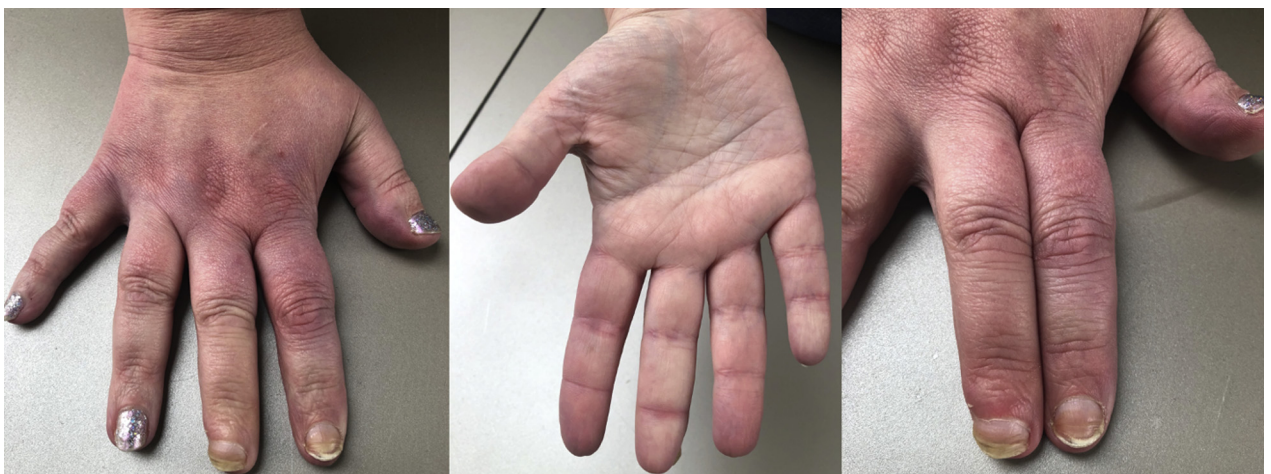Our patient was able to flex the digits immediately after intervention and experienced complete healing of both fingers within 4 months. The likely mechanism of healing was reversal of ischemia, similar to treating lower extremity CLI in atherosclerotic disease. It is also possible that reperfusion of the hand improved the delivery of epoprostenol, thereby potentiating its effectiveness. Additional studies are needed to demonstrate the

**FIGURE 5** Final Angiogram Demonstrating Restoration of Antegrade Flow to the Entire Hand



Comparison with [Figure 2](#) shows a stark difference in opacification of the ulnar and radial arteries at the wrist, the palmar branches, and the digital arteries.

**FIGURE 6** Patient's Right Hand at 4-Month Follow-Up Visit



reproducibility of this technique and explore its role in the management of SSc-associated digital ischemia and ulceration.

### CONCLUSIONS

Our initial experience suggests that reversal of chronic upper extremity digital ischemia is possible in at least some patients with SSc and may offer a potent new therapeutic option for patients who have not responded to other therapies.

### FUNDING SUPPORT AND AUTHOR DISCLOSURES

Dr Arain has served as a consultant for Teleflex. All other authors have reported that they have no relationships relevant to the contents of this paper to disclose.

**ADDRESS FOR CORRESPONDENCE:** Dr Kevin A. Honan, The University of Texas Health Science Center at Houston/Memorial Hermann Hospital, Texas Medical Center, 6410 Fannin Street, Suite 600, Houston, Texas 77030, USA. E-mail: [kevin.a.honan@uth.tmc.edu](mailto:kevin.a.honan@uth.tmc.edu).

### REFERENCES

1. Hughes M, Herrick AL. Digital ulcers in systemic sclerosis. *Rheumatology (Oxford)*. 2017;56(1):14-25.
2. Taylor MH, McFadden JA, Bolster MB, Silver RM. Ulnar artery involvement in systemic sclerosis (scleroderma). *J Rheumatol*. 2002;29(1):102-106.
3. Jones NF, Raynor SC, Medsger TA. Microsurgical revascularisation of the hand in scleroderma. *Br J Plast Surg*. 1987;40(3):264-269.
4. Kwon ST, Eun SC, Baek RM, Minn KW. Peripheral arterial-bypass grafts in the hand or foot in systemic sclerosis. *J Plast Reconstr Aesthet Surg*. 2009;62(7):e216-e221.
5. Frerix M, Stegbauer J, Dragun D, Kreuter A, Weiner SM. Ulnar artery occlusion is predictive of digital ulcers in SSc: a duplex sonography study. *Rheumatology (Oxford)*. 2012;51(4):735-742.
6. Ruzsa Z, Berta B, Tóth J, et al. Short- and long-term results with a percutaneous treatment in critical hand ischaemia. *Catheter Cardiovasc Interv*. 2019;93(7):1301-1310.
7. Tomoi Y, Soga Y, Fujihara M, et al. Outcomes of endovascular therapy for upper extremity peripheral artery disease with critical hand ischemia. *J Endovasc Ther*. 2016;23(5):717-722.
8. Dick EA, Aviv R, Francis I, et al. Catheter angiography and angioplasty in patients with scleroderma. *Br J Radiol*. 2001;74(888):1091-1096.

**KEY WORDS** hand, percutaneous, revascularization, systemic sclerosis