

Why are congenital heart defects being missed?

A. E. L. VAN NISSELROOIJ¹ , A. K. K. TEUNISSEN¹, S. A. CLUR² , L. ROZENDAAL³,
E. PAJKRT⁴, I. H. LINSKENS⁴, L. RAMMELOO², J. M. M. VAN LITH¹, N. A. BLOM³
and M. C. HAAK¹ 

¹Department of Obstetrics and Fetal Medicine, Leiden University Medical Center, Leiden, The Netherlands; ²Department of Paediatric Cardiology, Emma Children's Hospital, Amsterdam University Medical Centers, Amsterdam, The Netherlands; ³Department of Paediatric Cardiology, Leiden University Medical Center, Leiden, The Netherlands; ⁴Department of Obstetrics, Amsterdam University Medical Centers, Amsterdam, The Netherlands

KEYWORDS: audit; congenital heart defects; false negative; prenatal diagnosis; risk factors; screening; ultrasound

CONTRIBUTION

What are the novel findings of this work?

Screening for congenital heart defects (CHD) in a low-risk population is known to be challenging. This study shows that the quality of the cardiac planes obtained during the second-trimester standard anomaly scan (SAS), rather than circumstantial factors, plays an important role in the prenatal detection of CHD, which can be improved by increasing the volume of examinations performed by each sonographer per year.

What are the clinical implications of this work?

This study shows that adequate quality of the second-trimester SAS, especially in abnormal cases, is essential for prenatal detection of CHD. By setting up large screening centers, in which sonographers perform a high volume of examinations alongside sufficient training and monitoring of quality, the prenatal detection rate of CHD may further improve to the goal of 80%.

ABSTRACT

Objective Congenital heart defects (CHD) are still missed frequently in prenatal screening programs, which can result in severe morbidity or even death. The aim of this study was to evaluate the quality of fetal heart images, obtained during the second-trimester standard anomaly scan (SAS) in cases of CHD, to explore factors associated with a missed prenatal diagnosis.

Methods In this case–control study, all cases of a fetus born with isolated severe CHD in the Northwestern region of The Netherlands, between 2015 and 2016,

were extracted from the PRECOR registry. Severe CHD was defined as need for surgical repair in the first year postpartum. Each cardiac view (four-chamber view (4CV), three-vessel (3V) view and left and right ventricular outflow tract (LVOT, RVOT) views) obtained during the SAS was scored for technical correctness on a scale of 0 to 5 by two fetal echocardiography experts, blinded to the diagnosis of CHD and whether it was detected prenatally. Quality parameters of the cardiac examination were compared between cases in which CHD was detected and those in which it was missed on the SAS. Regression analysis was used to assess the association of sonographer experience and of screening-center experience with the cardiac examination quality score.

Results A total of 114 cases of isolated severe CHD at birth were analyzed, of which 58 (50.9%) were missed and 56 (49.1%) were detected on the SAS. The defects comprised transposition of the great arteries (17%), aortic coarctation (16%), tetralogy of Fallot (10%), atrioventricular septal defect (6%), aortic valve stenosis (5%), ventricular septal defect (18%) and other defects (28%). No differences were found in fetal position, obstetric history, maternal age or body mass index (BMI) or gestational age at examination between missed and detected cases. Ninety-two cases had available cardiac images from the SAS. Compared with the detected group, the missed group had significantly lower cardiac examination quality scores (adequate score (≥ 12) in 32% vs 64%; $P=0.002$), rate of proper use of magnification (58% vs 84%; $P=0.01$) and quality scores for each individual cardiac plane (4CV (2.7 vs 3.9; $P<0.001$), 3V view (3.0 vs 3.8; $P=0.02$), LVOT view (1.9 vs 3.3; $P<0.001$) and RVOT view (1.9 vs 3.3; $P<0.001$)). In

Correspondence to: Dr A. E. L. van Nisselrooij, Department of Obstetrics and Fetal Medicine, Leiden University Medical Center, K6-35, Albinusdreef 2, 2333 ZA Leiden, The Netherlands (e-mail: a.e.l.nisselrooij@lumc.nl)

Accepted: 20 May 2019

49% of missed cases, the lack of detection was due to poor adaptational skills resulting in inadequate images in which the CHD was not clearly visible; in 31%, the images showed an abnormality (mainly septal defects and aortic arch anomalies) which had not been recognized at the time of the scan; and, in 20%, the cardiac planes had been obtained properly but showed normal anatomy. Multivariate regression analysis showed that the volume of SAS performed per year by each sonographer was associated significantly with quality score of the cardiac examination.

Conclusions A lack of adaptational skills when performing the SAS, as opposed to circumstantial factors such as BMI or fetal position, appears to play an important role in failure to detect CHD prenatally. The quality of the cardiac views was inadequate significantly more often in undetected compared with detected cases. Despite adequate quality of the images, CHD was not recognized in 31% of cases. A high volume of SAS performed by each sonographer in a large ultrasound center contributes significantly to prenatal detection. In 20% of undetected cases, CHD was not visible even though the quality of the images was good. © 2019 The Authors. *Ultrasound in Obstetrics & Gynecology* published by John Wiley & Sons Ltd on behalf of the International Society of Ultrasound in Obstetrics and Gynecology.

INTRODUCTION

Congenital heart defects (CHD) are the most common birth defect, with a prevalence of approximately 5–8 per thousand live births. Ultrasound in pregnancy enables prenatal diagnosis of CHD, which allows for delivery in a facility with appropriate postnatal care. Prenatal identification of CHD has been shown to decrease mortality and perioperative morbidity and may improve neurodevelopmental outcome^{1–5}.

Prenatal detection of CHD, however, still fails in approximately half of cases⁶. Screening programs in most developed countries have reported a detection rate (DR) of only 30–60%, which varies according to the type of cardiac defect^{7–19}. Although prenatal DRs have increased gradually over the past few years, the identification of modifiable factors, if targeted appropriately, could potentially increase the sensitivity of current screening programs to achieve a DR of 80–90%, as reported in single-center studies^{20–22}.

The most commonly missed severe CHDs are conotruncal lesions, such as transposition of the great arteries, tetralogy of Fallot, double outlet right ventricle and truncus arteriosus, as the four-chamber view may be falsely reassuring in the majority of these cases. The outflow tract views, which are necessary to detect these lesions, are more challenging to capture in a routine screening setting¹³. Cases with a heart defect that present with a normal four-chamber view therefore appear to be those that are most likely to be missed, especially in the absence of known risk factors or additional structural anomalies^{23–28}. It has also been speculated that human

factors, such as experience, might be associated with failure to detect fetal CHD, as large differences in DRs can be found between healthcare facilities and geographical areas within the same country^{24,25}.

Therefore, this study aimed to identify factors that contribute to the failure to detect CHD, by auditing images obtained during the second-trimester standard anomaly scans (SAS) of fetuses born with CHD which was or was not detected prenatally, in order to potentially improve antenatal DRs.

METHODS

Selection of cases

Screening for congenital anomalies is performed in The Netherlands based on a strict national SAS protocol, similar to the ISUOG protocol²⁹. Every sonographer who performs SAS is required to pass a national standardized examination and is monitored every 2 years by evaluation of three randomly selected SAS, in order to assess their competence. If a sonographer does not pass this assessment, their qualification is withdrawn, and they are no longer able to perform SAS. This national screening program has resulted in one of the highest DRs for CHD worldwide^{6,30}, which is reflected in the 82% detection rate for transposition of the great arteries³¹.

The Amsterdam University Medical Centers (Academic Medical Center (AMC) and VU University Medical Center (VUMC)) and Leiden University Medical Center collaborate in the care for children with CHD in the Amsterdam and Leiden regions. All subjects with either a prenatal diagnosis of CHD or a postnatal diagnosis of severe CHD in these regions have been registered in the PRECOR database since 2002. Severe CHD is defined as need for surgery or therapeutic cardiac catheterization within the first year postpartum. Data collection for this registry has been described previously²³. This registry was used to identify all cases of severe isolated CHD, delivered in the period 2015–2016. We decided to include only recent cases, as the three-vessel view was introduced as a mandatory plane in 2012, to ensure retrieval of the original ultrasound images in the majority of cases. Cases that did not undergo SAS in the second trimester were excluded.

The mothers of CHD subjects were sent a letter with information regarding the study and an informed consent form to return if they were willing to participate. Mothers of CHD subjects that were not alive at the time of recruitment were excluded from the study, as requested by the ethical review board of our institution, but we ascertained the type of lesion in these cases from the PRECOR database. Following receipt of informed consent, mothers were contacted once to retrieve the location at which the SAS had been performed. Included subjects were allocated to either the group with or without a prenatal diagnosis of CHD.

Data collection

We collected the original ultrasound images from the SAS and pregnancy data. If data were missing, midwives were contacted for additional information. From 2007 onwards, the national prenatal screening database, PERIDOS, has registered all pregnant women who undergo SAS in The Netherlands. This database was used to retrieve information regarding the volume of SAS performed per year at each prenatal screening center, and by each sonographer, and sonographer experience (in years) at the end of the year in which the SAS was performed.

We developed a standard form to assess the quality of the ultrasound examination, as an indicator of the sonographer's technical skills, and additional parameters of interest. In order to assess objectively the quality of the cardiac examination, each of the four standard cardiac planes (four-chamber view (4CV), three-vessel (3V) view and the left and right outflow tract views) received a score between 0 and 5, resulting in a maximum total score of 20 for the entire cardiac examination. The score was based on the number of quality criteria met for that specific plane (Table 1). For example, if 3/5 criteria were met, the plane received a score of 3 (adequate quality). If the sonographer obtained multiple images of the same cardiac plane, these were assessed together. In cases for which videoclips were recorded, they were assessed in the same manner. A cardiac examination with a total score of ≥ 12 (average score

of ≥ 3 for each plane) was considered adequate, whereas a total score of < 12 was considered inadequate. Examples of cardiac images with their respective scores are depicted in Figure 1. A fetal medicine consultant (M.C.H.), specialized in fetal cardiology, and a senior cardiac sonographer (A.K.K.T.) scored the images together and were blinded to patient characteristics, diagnosis and whether the CHD had been detected prenatally. To quantify the reliability of this scoring system, 27 cases were scored twice and the intraclass correlation coefficient (ICC) calculated³². The time interval between the first and repeat assessments was more than 6 months in order to avoid recall bias.

The collected baseline characteristics comprised gestational age at screening, maternal age, body mass index, obstetric and medical history, multiple pregnancy, fetal gender, CHD diagnosis, sonographer experience and sonographer and screening center SAS volume. We evaluated fetal position, resolution of the ultrasound images (amount of detail in the image that could be obtained), use of magnification, visibility of the heart defect and quality of each of the four cardiac planes. Fetal position was classified based on the position of the spine on an analog clock. A position of the spine from 10 to 2 o'clock (clockwise) was considered to be unfavorable, whereas any other position was considered favorable. Sonographer and screening center volume, as well as the experience of the sonographer in years, was assessed for the year in which the SAS had been performed. Image resolution was scored on a five-point Likert scale, in which 1 represented poor resolution (lots of noise, multiple speckles, gray amniotic fluid) and 5 represented good resolution (clear black amniotic fluid, lots of detail visible in the image).

In order to gain insight into the completeness and quality of the SAS in normal cases, we retrieved the results from routine quality-monitoring assessments in the Leiden region in 2015. In these assessments, the four standard cardiac planes were scored as either 0 (inadequate), 1 (adequate) or a (absent). Normal cases could not be recruited in the same way in which CHD cases were as, in The Netherlands, only the physician who treated the patient is allowed to approach them. First, we collected the results from three normal scans obtained by sonographers in the Leiden region who missed a heart defect in the current cohort. Second, results from three normal scans performed by a random sample of 40 sonographers in the Leiden region were evaluated. We then assessed whether cardiac examination quality differed significantly between these groups. As the evaluation in the national monitoring system had been performed in less detail, direct comparison of scores between the normal and CHD cases was not possible.

Statistical analysis

All variables of interest that may possibly influence the ability to detect CHD prenatally were compared between the undetected and detected groups. Univariate and multivariate regression analyses were performed to

Table 1 Criteria for quality assessment of cardiac planes obtained during second-trimester standard anomaly scan

<i>Cardiac view/quality criteria</i>	
4CV	
	Complete depiction of both atrial chambers
	Complete depiction of both ventricles
	Cardiac crux visible
	Clear visualization of both AV valves
	Clear visualization of ventricular septum
3V view	
	True transverse plane through chest
	PA visible from RV to arterial duct
	PA valve visible
	Clear visualization of aorta
	Clear visualization of right superior caval vein
LVOT view	
	Plane approximately at level of LVOT
	Depicted at maximum size of vessel
	Aortic valve visible
	Perimembranous septum visible
	Complete long-axis from LV apex to ascending aorta visible
RVOT view	
	Plane approximately at level of RVOT
	Depicted at maximum size of vessel
	Pulmonary valve visible
	Upper part of RV visible
	Pulmonary artery visible from RV to arterial duct

3V, three-vessel; 4CV, four-chamber view; AV, atrioventricular; LV, left ventricle; LVOT, left ventricular outflow tract; PA, pulmonary artery; RV, right ventricle; RVOT, right ventricular outflow tract.

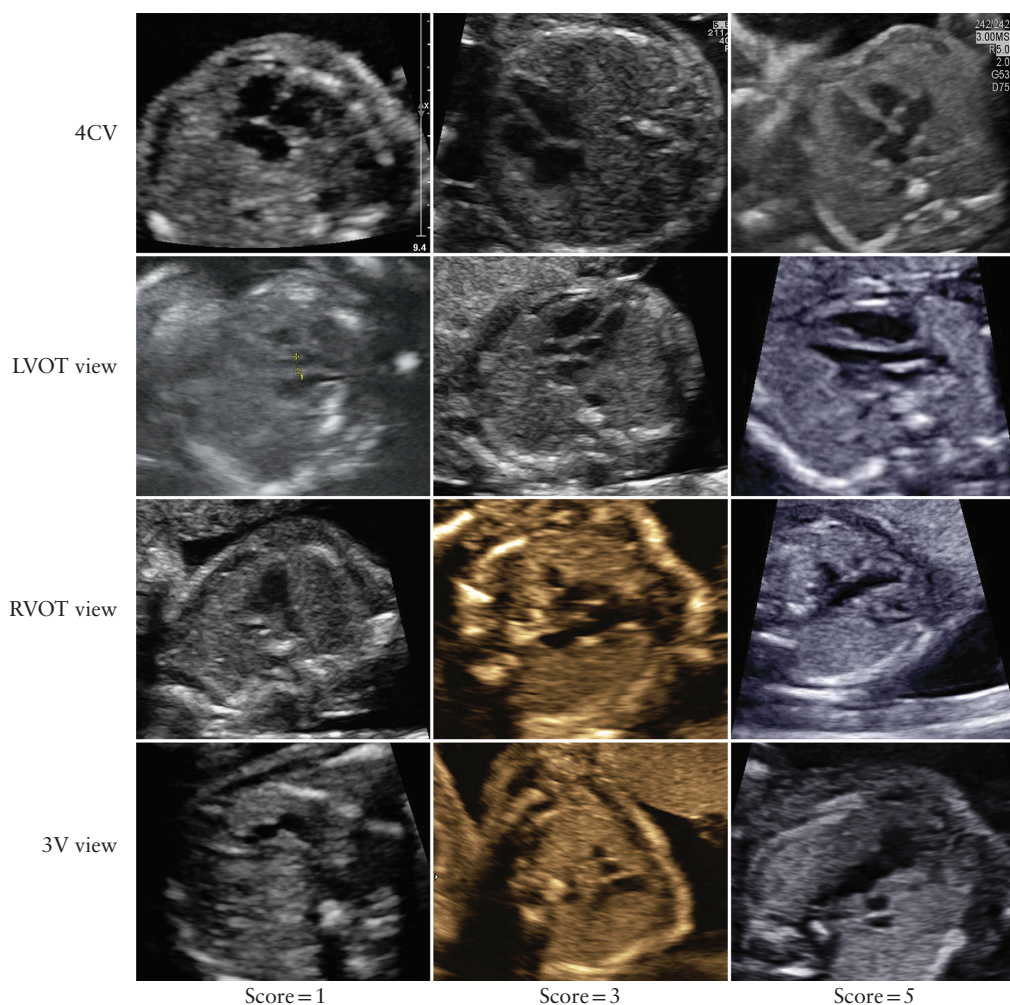


Figure 1 Examples of ultrasound images of fetal heart in four-chamber (4CV), left ventricular outflow tract (LVOT), right ventricular outflow tract (RVOT) and three-vessel (3V) views, that obtained quality score of 1, 3 or 5, in cases with severe congenital heart disease at birth.

assess whether the quality of the ultrasound examination was influenced by sonographer experience in years or the volume of SAS performed per year by each sonographer or screening center.

To identify potential causes of missed prenatal detection, we considered the adequacy of the cardiac examination (total score $<$ or ≥ 12) alongside the visibility of the heart defect, as assessed by the expert examiners (M.C.H. and A.K.K.T.), in all undetected cases. These were used to define three types of cause for a missed prenatal diagnosis. The first involved the sonographer being unable to obtain technically correct cardiac planes in cases with abnormal anatomy. These cases were missed due to a lack of adaptational skills and comprised all undetected cases in which the total quality score was < 12 and the heart defect was not clearly visible, according to the expert examiners, because of suboptimal planes. The second cause was when the heart defect was not recognized despite being clearly visible on the retrieved images, irrespective of the quality of the planes. Undetected heart defects that were not visible despite good quality of the images (total score ≥ 12) were classified as inevitable.

These three causes of a missed diagnosis, and the quality scores of each of the four cardiac planes in undetected cases, were assessed according to the type of CHD.

Categorical variables were compared using the χ^2 test and continuous variables were compared using the independent *t*-test. ICC estimates and their 95% CI were calculated based on a mean-rating ($k=2$), consistency-agreement, two-way mixed-effects model. IBM SPSS Statistics 23.0 for Windows (IBM Corp., Armonk, NY, USA) was used for all statistical analyses. A *P*-value < 0.05 was considered statistically significant.

RESULTS

A total of 198 cases of severe CHD without an additional anomaly, born in 2015–2016, were extracted from the PRECOR registry. All mothers were approached to participate in the study, except for 12 (6.1%) cases, in which the infant was not alive at time of recruitment; these 12 cases comprised univentricular heart defects (67%; all of which were detected prenatally) and other defects (33%; 80% of which were detected prenatally and 20% of

which were not). We did not receive a response from 51 (25.8%) subjects and 10 (5.1%) chose not to participate in the study. Eleven (5.6%) subjects did not undergo SAS in the second trimester because they had indications, mainly increased nuchal translucency, for an advanced diagnostic scan including fetal echocardiography. This resulted in a total of 114 cases eligible for inclusion, of which 58 (50.9%) were undetected and 56 (49.1%) were detected prenatally (Figure 2).

At baseline, significantly more women had a history of abdominal surgery in the undetected (33.3%) compared

to the detected (9.5%) group ($P=0.01$). This difference, however, could not be accounted for in subsequent analysis as this information was missing in 39% of cases. The two groups did not differ significantly in any of the other parameters assessed at baseline (Table 2).

Ultrasound images could be retrieved from the initial screening center in 92/114 (80.7%) CHD cases. Sonographer use of magnification was significantly poorer in the undetected group ($P=0.01$). The proportion of cases with unfavorable fetal position did not differ significantly between the groups, which demonstrates that

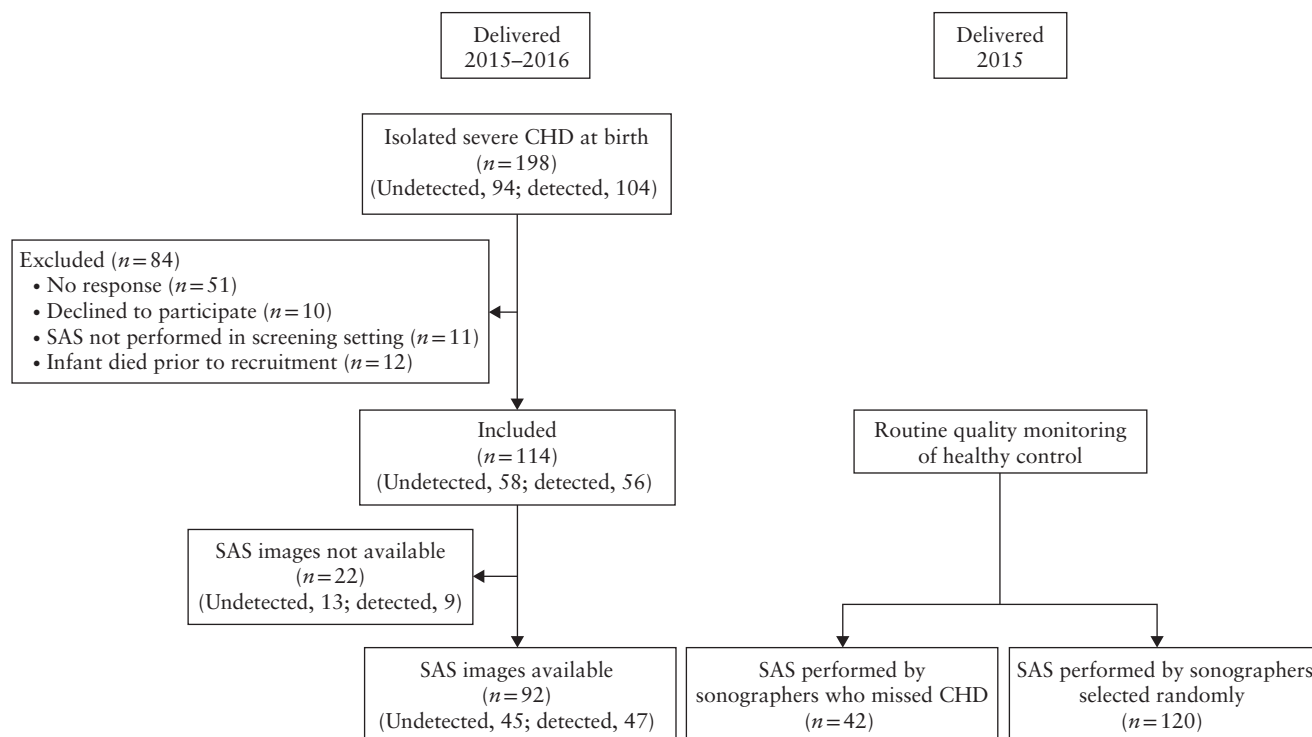


Figure 2 Flowchart summarizing inclusion of fetuses with severe congenital heart disease (CHD) at birth and normal controls. SAS, standard anomaly scan.

Table 2 Baseline characteristics for 114 pregnancies with severe fetal congenital heart disease (CHD) at birth, according to whether defect was detected on second-trimester standard anomaly scan (SAS)

Characteristic	Undetected CHD (n = 58)	Detected CHD (n = 56)	P	95% CI of difference
Gestational age at screening (weeks)	20.0 ± 0.72§	20.0 ± 0.95	0.96	−0.31 to 0.32
Ultrasound scan repeated	5/40 (12.5)	6/40 (15.0)	0.75	
Maternal age (years)*	31.6 ± 4.33	31.6 ± 4.62	0.98	−1.68 to 1.64
Maternal obesity†	22/41 (53.7)	17/50 (34.0)	0.06	
Multigravid	31/50 (62.0)	38/55 (69.1)	0.45	
History of abdominal surgery	9/27 (33.3)	4/42 (9.5)	0.01	
Pregnancy complication	12/30 (40.0)	6/28 (21.4)	0.13	
Multiple pregnancy	3/46 (6.5)	6/56 (10.7)	0.46	
Fetal sex male	38 (65.5)	27 (48.2)	0.06	
Sonographer experience (years)‡	5.6 ± 2.67¶	5.6 ± 2.98‡‡	0.92	−1.09 to 1.21
Volume of SAS performed (n/year)‡				
Per sonographer	343.4 ± 247.00**	410.0 ± 289.50§§	0.22	−173.12 to 39.88
Per screening center	1289.3 ± 1041.80††	1157.5 ± 1076.21§§	0.54	−290.92 to 554.53

Data are given as mean ± SD, n/N (%) or n (%). *Mean is given as it did not differ significantly from median (interval not skewed). †Body mass index > 25 kg/m². ‡Calculated using data from end of year in which case underwent prenatal screening. §n = 57. ¶n = 50. **n = 53. ††n = 52. ‡‡n = 46. §§n = 47.

the majority of sonographers waited until the fetus was in a favorable position to assess the heart. The quality of the cardiac examination, overall and for each of the cardiac planes, was significantly lower in undetected CHD cases. In the undetected group, the cardiac examination was more frequently incomplete i.e. ≥ 1 cardiac plane was not obtained or saved (46.7% vs 22.2%; $P = 0.02$). The expert assessors classified the defect as being clearly visible in 83.7% of detected cases compared to only 31.1% of undetected cases ($P < 0.001$), due mainly to technically incorrect cardiac planes (Table 3). The

cardiac examination received an inadequate score in a higher proportion of missed CHD cases (64.4%) than in normal controls evaluated by the same sonographers (14.3%), although different scoring systems were used. With regards to the completeness and quality of the cardiac examinations in normal cases, those performed by sonographers who missed a defect did not differ significantly from those performed by randomly selected sonographers (Table 4). The ICC for quality scoring of the overall cardiac examination (0.88; 95% CI, 0.75–0.95) and for each of the cardiac planes (varying from 0.77

Table 3 Characteristics and quality assessment of cardiac images obtained during second-trimester standard anomaly scan in 92 fetuses with severe congenital heart disease (CHD) at birth, according to whether defect was detected on scan

Variable	Undetected CHD (n = 45)	Detected CHD (n = 47)	P	95% CI of difference
Characteristic				
Unfavorable fetal position*	4 (8.9)	3 (6.7)	1.00	
Amniotic fluid volume score†	3.0 ± 0.16	3.0 ± 0.00	0.32	−0.08 to 0.03
Use of magnification			0.01	
Poor	2 (5.0)	3 (6.8)		
Average	15 (37.5)	4 (9.1)		
Good	23 (57.5)	37 (84.1)		
Image resolution			0.18	
Poor	4 (9.1)	0 (0.0)		
Below average	8 (18.2)	9 (21.4)		
Average	21 (47.7)	17 (40.5)		
Above average	9 (20.5)	10 (23.8)		
Good	2 (4.5)	6 (14.3)		
Quality assessment				
Quality score‡	9.4 ± 5.24	14.2 ± 5.51	< 0.001	−7.05 to −2.52
Four-chamber view	2.7 ± 1.47	3.9 ± 1.26	< 0.001	−1.78 to −0.62
Three-vessel view	3.0 ± 1.58	3.8 ± 1.57	0.02	−1.46 to −0.14
Left ventricular outflow tract view	1.9 ± 1.57	3.3 ± 1.75	< 0.001	−2.02 to −0.62
Right ventricular outflow tract view	1.9 ± 1.95	3.3 ± 1.87	< 0.001	−2.27 to −0.67
Inadequate cardiac scan§	29 (64.4)	14 (31.8)	0.002	
Incomplete cardiac scan¶	21 (46.7)	10 (22.2)	0.02	
CHD clearly visible**	14 (31.1)	36 (83.7)	< 0.001	

Data are given as n (%) or mean ± SD. *All positions in which fetal spine was lying towards probe (on opposite side of maternal spine), i.e. from 10 to 2 o'clock (clockwise), were classified as unfavorable. †Scored on 5-point Likert scale as follows: 1, anhydramnios; 3, normal volume of amniotic fluid; and 5, polyhydramnios. ‡Scored 1–5 for each plane; score = 0 if not obtained. §Total quality score < 12. ¶ ≥ 1 plane not obtained or saved. **Original images showed abnormal cardiac anatomy according to fetal echocardiography experts (M.C.H., A.K.K.T.).

Table 4 Routine quality assessment of cardiac images obtained during second-trimester standard anomaly scan in uncomplicated pregnancies, performed by 14 sonographers who missed congenital heart disease (CHD) on scan in current study and 40 sonographers selected randomly

Variable	Scan performed by		P	95% CI of difference
	Sonographer who missed CHD (n = 42 scans)	Sonographer selected randomly (n = 120 scans)		
Quality score*	3.14 ± 0.90	3.20 ± 0.87	0.72	−0.24 to 0.27
Four-chamber view	0.93 ± 0.26	0.96 ± 0.20	0.45	−0.37 to 0.25
Three-vessel view	0.86 ± 0.35	0.88 ± 0.32	0.66	−0.11 to 0.05
Left ventricular outflow tract view	0.71 ± 0.46	0.68 ± 0.47	0.64	−0.14 to 0.09
Right ventricular outflow tract view	0.64 ± 0.48	0.68 ± 0.46	0.63	−0.13 to 0.20
Inadequate cardiac scan†	6 (14.3)	25 (20.8)	0.35	
Incomplete cardiac scan‡	10 (23.8)	31 (25.8)	0.80	

Data are given as mean ± SD or n (%). Three scans included per sonographer. Quality assessment data based on results of quality monitoring assessments in Leiden region in 2015. *Maximum score of 1 for each plane. †Quality score of 0 for ≥ 2 planes. ‡ ≥ 1 plane not obtained or saved.

Table 5 Univariate and multivariate analyses for association of sonographer experience and volume of second-trimester standard anomaly scans (SAS) performed with quality of cardiac examination in 92 fetuses with severe congenital heart disease at birth

Variable	Regression coefficient (95% CI)	SE	P
Univariate analysis			
Sonographer experience in years	0.07 (−0.410 to 0.548)	0.24	0.78
Volume of SAS performed in <i>n</i> /year			
Per sonographer	0.007 (0.001 to 0.013)	0.003	0.02
Per screening center	0.001 (0.000 to 0.003)	0.001	< 0.05
Multivariate analysis			
Volume of SAS performed in <i>n</i> /year			
Per sonographer	0.006 (0.000 to 0.012)	0.003	< 0.05
Per screening center	0.001 (0.000 to 0.002)	0.001	0.15

SE, standard error.

to 0.89) demonstrated good to excellent intrarater agreement.

On univariate regression analysis, the volume of SAS performed per year by each sonographer and screening center had a small but significant influence on the quality of the cardiac scan in CHD cases. Multivariate regression analysis, however, showed that only an increase in the number of SAS performed by each sonographer improved significantly the overall score of the cardiac examination (Table 5).

Analysis of undetected CHD cases revealed that the quality of the cardiac examination was inadequate and the defect was not clearly visible due to lack of adaptational skills in 22/45 (48.9%) cases. In 14/45 (31.1%) undetected cases, the defect was visible on the cardiac planes obtained, and it was therefore lack of recognition that led to it being missed. In 9/45 (20.0%) cases, the defect was not visible, even though the quality of the images was adequate; these missed cases were therefore classified as inevitable. Example images of undetected cases classified into each of these three causes of missed prenatal diagnosis are depicted in Figure 3.

Coarctation of the aorta, transposition of the great arteries and tetralogy of Fallot were diagnoses that were often not recognized, despite the fact that the obtained images showed abnormal cardiac anatomy. The inevitable group involved mainly CHD types that are speculated to be difficult to diagnose prenatally, such as coarctation of the aorta or total anomalous pulmonary venous return. Images in a considerable number of these undetected diagnoses did indeed show normal cardiac anatomy. Table 6 details the types of CHD included in this study and quality scores for each of the four cardiac planes, overall and in missed cases, as well as causes of missed prenatal diagnosis.

DISCUSSION

This study audited images obtained during the second-trimester SAS to identify potential causes for a missed prenatal diagnosis of CHD, by comparing ultrasound examinations between undetected and detected cases. Although sonographers practiced in a high-quality screening program, our results showed that the cardiac

planes obtained during the SAS were of significantly better quality in detected compared with undetected CHD cases. Cardiac examinations appeared of better quality when performed by sonographers who carried out a greater number of SAS per year.

Sonographers who missed a CHD diagnosis were not poorly trained as all had passed the national quality assessment. However, at the initial assessment, 25% of sonographers did not obtain or save all cardiac planes, indicating that they either accepted technically incorrect planes or did not obtain and save all cardiac planes in a structured manner. The poorer performance in CHD cases may also be explained by slightly impaired motor skills when acquiring accurate planes in abnormal anatomy, combined with a lack of gut feeling for detection of abnormal cases. We hypothesize that the poorer performance in missed cases may be attributed to certain personality traits and lack of adaptational skills. The second reason for a missed prenatal diagnosis was failure to recognize the CHD despite it being visible on the images, which involved mainly subtle signs, such as asymmetry in the 4CV and discrepancy between the size of the aorta and the pulmonary trunk in coarctation of the aorta. Missed prenatal diagnosis was classified as inevitable in 20% of undetected cases, which may be explained partly by development later in gestation.

Although further analysis revealed a small but significant positive association between sonographer volume (number of SAS performed per year) and quality of the cardiac planes, quality was not associated with sonographer experience in years. This indicates that a minimum number of examinations per year might be necessary to maintain skills and develop a gut feeling for detection of abnormalities³³. We speculate that sonographers performing a low volume of examinations may be more likely to question their own capability and accept technically incorrect cardiac planes, whereas those performing a high volume of examinations will rely on their technical skills to obtain the cardiac images properly, trust their gut feeling that the images are abnormal due to differences in fetal anatomy and refer the case to a specialized fetal medicine unit. The screening center's size was also associated with superior quality of the cardiac planes. This might be explained by their increased exposure to abnormal scans, as high-volume sonographers will most

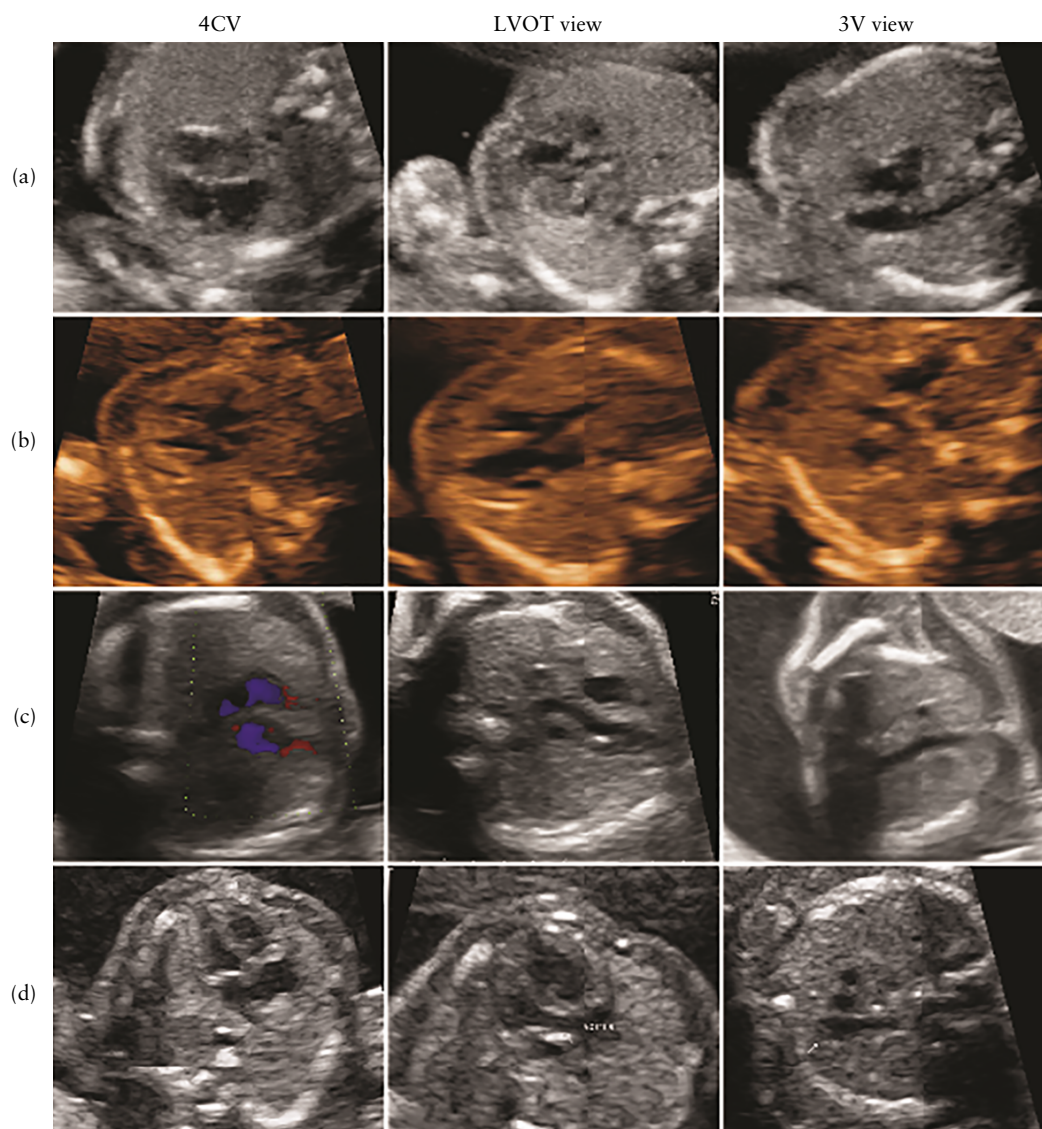


Figure 3 Ultrasound images of fetal heart in four-chamber (4CV), left ventricular outflow tract (LVOT) and three-vessel (3V) views in four cases with severe congenital heart disease at birth that was missed on prenatal ultrasound examination due to poor adaptational skills of sonographer (a), inability of sonographer to recognize defect (b,c) or defect not being visible despite adequate image quality (d). (a) Case of atrioventricular septal defect missed prenatally due to poor adaptational skills of sonographer. In 4CV, atria are blurred, plane is not taken at proper level (too far towards diaphragm, showing atrioventricular valve annuli instead of valves). Only ventricles and septum are visible. LVOT view quality was scored 1 as aorta is barely recognizable. (b) Case of tetralogy of Fallot that was not recognized by sonographer; although quality of planes is inadequate (total score of 6), ventricular septal defect can be identified with over-riding aorta. In 3V view, it is clearly visible that pulmonary artery is small and ascending aorta is relatively large. Right aortic arch is visible just anterior to spine. (c) Case of transposition of great arteries that was not recognized by sonographer despite planes having adequate quality score; as only two vessels (right superior caval vein and ascending aorta arising from right ventricle) are visible in 3V view, which is typical for this diagnosis. (d) Case of coarctation of aorta that was classified as inevitably missed, as quality of cardiac examination was adequate (total score of ≥ 12), and in particular, no discrepancies in size of ventricles or great arteries were evident on any cardiac images obtained.

likely work in large screening centers, which enables them to review difficult cases with fellow sonographers. A French study confirmed this by showing that meetings in which cases are discussed contribute to increased DRs, in conjunction with training³⁴. Recording of videoclips during the SAS might also enhance screening results and aid the review of difficult cases. The fact that high volume was associated with better quality of the examination, but not with increased prenatal detection, may be explained by a lack of power, as 20% of the missed cases were inevitable and allocated to the undetected cases by definition.

Cardiac images in undetected cases scored particularly low for the outflow tract planes, which was not the case in the detected group. Previous cohort studies have confirmed that assessment of the outflow tracts, including the 3V or three-vessels-and-trachea view, is valuable for prenatal detection^{31,35,36}. The use of universal guidelines and increased effort to obtain these outflow tract views has therefore been shown to increase prenatal DRs^{9,18}. Specific training programs focused on achieving satisfactory views of the heart^{28,36–39} were able to improve significantly DRs towards 60%. As DRs in

our region²³ are already above 60%, we hypothesize that monitoring, alongside training, is imperative to assure strict adherence to protocol and to reach higher DRs.

Our results also suggest that an increase in the annual volume of SAS performed by the sonographers, rather than their experience in years, can improve quality.

Setting up large screening centers with sonographers performing a high volume of examinations might be the final step to reach DRs of the previously mentioned goal of 80%, because it will ensure sufficient exposure to abnormal cardiac images and create an environment that potentially counteracts the above described character

Table 6 Overview of types of congenital heart disease (CHD), reason for missed diagnosis on prenatal ultrasound and cardiac examination quality score in fetuses with severe CHD at birth

CHD	Cases (n (%))	US available (n)	Cause of missed diagnosis			Image quality score on:							
			Adaptational skills (%)*	Not recognized (%)†	Inevitable (%)‡	4CV		3V		LVOT		RVOT	
						Mean	≥ 3 (%)	Mean	≥ 3 (%)	Mean	≥ 3 (%)	Mean	≥ 3 (%)
TAPVR													
All	3 (2.6)	3				3.3	66.7	3.3	66.7	1.0	33.3	1.7	33.3
Undetected	3 (100)	3	66.7	0	33.3	3.3	66.7	3.3	66.7	1.0	33.3	1.7	33.3
VSD													
All	21 (18.4)	16				2.9	56.3	2.6	43.8	1.9	31.3	1.4	25.0
Undetected	18 (85.7)	13	76.9	0	23.1	2.8	53.8	2.6	46.2	1.8	30.8	1.2	23.1
Double aortic arch													
All	4 (3.5)	2				4.5	100.0	4.0	100.0	4.5	100.0	4.5	100.0
Undetected	3 (75.0)	2	0	50.0	50.0	4.5	100.0	4.0	100.0	4.5	100.0	4.5	100.0
TOF													
All	4 (3.5)	4				3.8	75.0	4.0	100.0	3.5	75.0	3.3	75.0
Undetected	3 (75.0)	3	0	66.7	33.3	3.7	66.7	4.0	100.0	3.3	66.7	3.0	66.7
CoA													
All	18 (15.8)	13				2.5	46.2	3.9	76.9	2.5	53.8	3.0	53.8
Undetected	12 (66.7)	9	11.1	77.8	11.1	2.1	33.3	3.9	77.8	2.0	33.3	2.4	44.4
Aortic stenosis													
All	6 (5.3)	6				3.2	66.7	2.7	50.0	2.2	50.0	2.7	66.7
Undetected	4 (66.7)	4	50.0	50.0	0	3.0	75.0	2.8	50.0	2.3	50.0	2.3	50.0
PVS													
All	3 (2.6)	2				3.5	50.0	3.5	100.0	3.0	50.0	3.0	50.0
Undetected	2 (66.7)	1	100.0	0	0	2.0	0.0	3.0	100.0	2.0	0.0	2.0	0.0
AVSD													
All	7 (6.1)	5				3.8	60.0	4.2	100.0	2.4	40.0	3.2	60.0
Undetected	3 (42.9)	2	50.0	0	50.0	3.5	50.0	4.0	100.0	0.5	0.0	3.5	50.0
Shone's complex													
All	3 (2.6)	2				3.5	50.0	4.5	100.0	2.0	50.0	4.5	100.0
Undetected	1 (33.3)	0	—	—	—								
TGA													
All	19 (16.7)	18				3.8	82.4	3.9	82.4	3.8	76.5	3.4	72.2
Undetected	3 (15.8)	3	33.3	66.7	0	1.7	33.3	1.7	33.3	2.0	33.3	0.3	0.0
DORV (TOF type)													
All	7 (6.1)	5				3.6	80.0	4.2	100.0	3.8	80.0	3.4	80.0
Undetected	0 (0.0)	0	—	—	—								
Interrupted aortic arch													
All	2 (1.8)	2				4.0	100.0	3.5	50.0	0.5	0.0	1.5	50.0
Undetected	0 (0.0)	0	—	—	—								
Common arterial trunk													
All	2 (1.8)	1				3.0	100.0	0.0	0.0	0.0	0.0	0.0	0.0
Undetected	0 (0.0)	0	—	—	—								
PA/IVS													
All	2 (1.8)	1				4.0	100.0	0.0	0.0	0.0	0.0	0.0	0.0
Undetected	0 (0.0)	0	—	—	—								
Unbalanced AVSD													
All	2 (1.8)	2				4.0	100.0	4.0	100.0	2.0	50.0	2.5	50.0
Undetected	0 (0.0)	0	—	—	—								
Other													
All	11 (9.6)												
Undetected	6 (54.5)												
Total	114 (100)	92	48.9	31.1	20.0	3.3	66.3	3.4	68.9	2.6	51.7	2.6	54.4

*Cardiac examination had inadequate quality score (< 12) and heart defect was not clearly visible. †Defect was clearly visible on images but was not recognized by sonographer, irrespective of examination quality. ‡Defect was not visible despite adequate quality score (≥ 12). 3V, three-vessel view; 4CV, four-chamber view; AVSD, atrioventricular septal defect; CoA, coarctation of the aorta; DORV, double outlet right ventricle; LVOT, left ventricular outflow tract view; PA/IVS, pulmonary atresia with intact ventricular septum; PVS, pulmonary valve stenosis; RVOT, right ventricular outflow tract view; TAPVR, total anomalous pulmonary venous return; TGA, transposition of the great arteries; TOF, tetralogy of Fallot; VSD, ventricular septal defect.

traits. This is in line with the current opinion that centralization of care improves quality. Factors that possibly hamper proper cardiac assessment, such as maternal obesity or unfavorable fetal position, were not found to influence the prenatal detection of CHD, which is in accordance with previous reports^{24,25,40,41}.

Although this topic can be studied only retrospectively, this design led to some inevitable limitations. First, it is not possible to determine if improved quality of images led directly to detection of the heart defect, rather than *vice versa*. Second, we had to obtain consent from the mothers in order to retrieve the images, which may have resulted in selection bias. The inclusion of only live cases should not affect significantly the study's clinical value, because the cases that resulted in termination of pregnancy or neonatal demise comprised mainly univentricular defects with DRs of nearly 100% in our country²³. However, this did impede blinding of assessors to whether a heart defect was present, as we were unable to retrieve the original images from healthy fetuses. Finally, the distribution of diagnoses differed between the two groups. This, however, does not affect our primary results, as sonographers are still obliged to acquire and save proper cardiac planes, even if they assume a structurally normal heart, as described in our national SAS protocol⁴².

In conclusion, the quality of the cardiac examination at the time of second-trimester screening appears to be the cornerstone in improving prenatal DRs for CHD in a low-risk population. Although it seems obvious that sonographers performing a high volume of scans are more likely to retain technical skills and remain qualified, this association has not been demonstrated previously. The volume of examinations performed by the sonographer, alongside training, was shown to be equally important in ensuring adequate examination of the fetal heart and recognition of abnormality. Future research should therefore consider performing more extensive audit studies and evaluating annual volume targets for sonographers who perform SAS, in order to maintain their competence.

ACKNOWLEDGMENT

This study received a grant from the Hartekind Foundation (Stichting Hartekind), a Dutch patient initiative fund, organized to support scientific research in and for children with a congenital heart defect.

REFERENCES

- Calderon J, Angeard N, Moutier S, Plumet MH, Jambaque I, Bonnet D. Impact of prenatal diagnosis on neurocognitive outcomes in children with transposition of the great arteries. *J Pediatr* 2012; 161: e1.94–98.
- Chakraborty A, Gorla SR, Swaminathan S. Impact of prenatal diagnosis of complex congenital heart disease on neonatal and infant morbidity and mortality. *Prenat Diagn* 2018; 38: 958–963.
- Peyvandi S, De Santiago V, Chakkarapani E, Chau V, Campbell A, Poskitt KJ, Xu D, Barkovich AJ, Miller S, McQuillen P. Association of Prenatal Diagnosis of Critical Congenital Heart Disease With Postnatal Brain Development and the Risk of Brain Injury. *JAMA Pediatr* 2016; 170: e154450.
- Quartermain MD, Hill KD, Goldberg DJ, Jacobs JP, Jacobs ML, Pasquali SK, Verghese GR, Wallace AS, Ungerleider RM. Prenatal Diagnosis Influences Preoperative Status in Neonates with Congenital Heart Disease: An Analysis of the Society of Thoracic Surgeons Congenital Heart Surgery Database. *Pediatr Cardiol* 2019; 40: 489–496.
- Thakur V, Dutil N, Schwartz SM, Jaeggi E. Impact of prenatal diagnosis on the management and early outcome of critical duct-dependent cardiac lesions. *Cardiol Young* 2018; 28: 548–553.
- van Velzen CL, Ket JCF, van de Ven PM, Blom NA, Haak MC. Systematic review and meta-analysis of the performance of second-trimester screening for prenatal detection of congenital heart defects. *Int J Gynaecol Obstet* 2018; 140: 137–145.
- Buskens E, Grobbee DE, Frohn-Mulder IM, Stewart PA, Juttman RE, Wladimiroff JW, Hess J. Efficacy of routine fetal ultrasound screening for congenital heart disease in normal pregnancy. *Circulation* 1996; 94: 67–72.
- Galindo A, Herraiz I, Escribano D, Lora D, Melchor JC, de la Cruz J. Prenatal detection of congenital heart defects: a survey on clinical practice in Spain. *Fetal Diagn Ther* 2011; 29: 287–295.
- Levy DJ, Pretorius DH, Rothman A, Gonzales M, Rao C, Nunes ME, Bendelstein J, Mehalek K, Thomas A, Nehls C, Ehr J, Burchette RJ, Sklansky MS. Improved prenatal detection of congenital heart disease in an integrated health care system. *Pediatr Cardiol* 2013; 34: 670–679.
- Marek J, Tomek V, Skovranek J, Povysilova V, Samanek M. Prenatal ultrasound screening of congenital heart disease in an unselected national population: a 21-year experience. *Heart* 2011; 97: 124–130.
- Sharland GK, Allan LD. Screening for congenital heart disease prenatally. Results of a 2 1/2-year study in the South East Thames Region. *Br J Obstet Gynaecol* 1992; 99: 220–225.
- Stumpflen I, Stumpflen A, Wimmer M, Bernaschek G. Effect of detailed fetal echocardiography as part of routine prenatal ultrasonographic screening on detection of congenital heart disease. *Lancet* 1996; 348: 854–857.
- Khoo NS, Van Essen P, Richardson M, Robertson T. Effectiveness of prenatal diagnosis of congenital heart defects in South Australia: a population analysis 1999–2003. *Aust N Z J Obstet Gynaecol* 2008; 48: 559–563.
- Kuehl KS, Loffredo CA, Ferencz C. Failure to diagnose congenital heart disease in infancy. *Pediatrics* 1999; 103: 743–747.
- Stoll C, Garne E, Clementi M, Group ES. Evaluation of prenatal diagnosis of associated congenital heart diseases by fetal ultrasonographic examination in Europe. *Prenat Diagn* 2001; 21: 243–252.
- Chu C, Yan Y, Ren Y, Li X, Gui Y. Prenatal diagnosis of congenital heart diseases by fetal echocardiography in second trimester: a Chinese multicenter study. *Acta Obstet Gynecol Scand* 2017; 96: 454–463.
- Lytzen R, Vejstrup N, Bjerre J, Petersen OB, Leenskjold S, Dodd JK, Jorgensen FS, Sondergaard L. Live-Born Major Congenital Heart Disease in Denmark: Incidence, Detection Rate, and Termination of Pregnancy Rate From 1996 to 2013. *JAMA Cardiol* 2018; 3: 829–837.
- Sun HY, Proudfoot JA, McCandless RT. Prenatal detection of critical cardiac outflow tract anomalies remains suboptimal despite revised obstetrical imaging guidelines. *Congenit Heart Dis* 2018; 13: 748–756.
- Itsukaichi M, Serikawa T, Yoshihara K, Suzuki H, Haino K, Yamaguchi M, Enomoto T, Niigata Fetal Cardiac Screening Study G, Takakuwa K. Effectiveness of fetal cardiac screening for congenital heart disease using a combination of the four-chamber view and three-vessel view during the second trimester scan. *J Obstet Gynaecol Res* 2018; 44: 49–53.
- Cuneo BF, Curran LF, Davis N, Elrad H. Trends in prenatal diagnosis of critical cardiac defects in an integrated obstetric and pediatric cardiac imaging center. *J Perinatol* 2004; 24: 674–678.
- Clur SA, Van Brussel PM, Ottenkamp J, Bilardo CM. Prenatal diagnosis of cardiac defects: accuracy and benefit. *Prenat Diagn* 2012; 32: 450–455.
- Letourneau KM, Horne D, Soni RN, McDonald KR, Karlicki FC, Fransoo RR. Advancing Prenatal Detection of Congenital Heart Disease: A Novel Screening Protocol Improves Early Diagnosis of Complex Congenital Heart Disease. *J Ultrasound Med* 2018; 37: 1073–1079.
- van Velzen CL, Clur SA, Rijlaarsdam ME, Bax CJ, Pajkrt E, Heymans MW, Bekker MN, Hruđa J, de Groot CJ, Blom NA, Haak MC. Prenatal detection of congenital heart disease—results of a national screening programme. *BJOG* 2016; 123: 400–407.
- Friedberg MK, Silverman NH, Moon-Grady AJ, Tong E, Nourse J, Sorenson B, Lee J, Hornberger LK. Prenatal detection of congenital heart disease. *J Pediatr* 2009; 155: 31e1.26–31.
- Wong SF, Chan FY, Cincotta RB, Lee-Tannock A, Ward C. Factors influencing the prenatal detection of structural congenital heart diseases. *Ultrasound Obstet Gynecol* 2003; 21: 19–25.
- Acherman RJ, Evans WN, Luna CF, Rollins R, Kip KT, Collazos JC, Restrepo H, Adasheek J, Iriye BK, Roberts D, Sacks AJ. Prenatal detection of congenital heart disease in southern Nevada: the need for universal fetal cardiac evaluation. *J Ultrasound Med* 2007; 26: 1715–1719; quiz 1720–1711.
- Garne E, Stoll C, Clementi M, Euroscan G. Evaluation of prenatal diagnosis of congenital heart diseases by ultrasound: experience from 20 European registries. *Ultrasound Obstet Gynecol* 2001; 17: 386–391.
- Hunter S, Heads A, Wyllie J, Robson S. Prenatal diagnosis of congenital heart disease in the northern region of England: benefits of a training programme for obstetric ultrasonographers. *Heart* 2000; 84: 294–298.
- Carvalho JS, Allan LD, Chaoui R, Copel JA, DeVore GR, Hecher K, Lee W, Munoz H, Paladini D, Tutschek B, Yagel S. ISUOG Practice Guidelines (updated): sonographic screening examination of the fetal heart. *Ultrasound Obstet Gynecol* 2013; 41: 348–359.
- Baardman ME, du Marchie Sarvaas GJ, de Walle HE, Fleurke-Rozema H, Snijders R, Ebels T, Bergman JE, Bilardo CM, Berger RM, Bakker MK. Impact of introduction of 20-week ultrasound scan on prevalence and fetal and neonatal outcomes in cases of selected severe congenital heart defects in The Netherlands. *Ultrasound Obstet Gynecol* 2014; 44: 58–63.

31. Everwijn SMP, van Nisselrooij AEL, Rozendaal L, Clur SB, Pajkrt E, Hruda J, Linskens IH, van Lith JM, Blom NA, Haak MC. The effect of the introduction of the three-vessel view on the detection rate of transposition of the great arteries and tetralogy of Fallot. *Prenat Diagn* 2018; **38**: 951–957.
32. Zou GY. Sample size formulas for estimating intraclass correlation coefficients with precision and assurance. *Stat Med* 2012; **31**: 3972–3981.
33. van den Bruel A, Thompson M, Buntinx F, Mant D. Clinicians' gut feeling about serious infections in children: observational study. *BMJ* 2012; **345**: e6144.
34. Pezard P, Bonnemains L, Boussion F, Sentilhes L, Allory P, Lepinard C, Guichet A, Triau S, Biquard F, Leblanc M, Bonneau D, Descamps P. Influence of ultrasonographers training on prenatal diagnosis of congenital heart diseases: a 12-year population-based study. *Prenat Diagn* 2008; **28**: 1016–1022.
35. Vinals F, Heredia F, Giuliano A. The role of the three vessels and trachea view (3VT) in the diagnosis of congenital heart defects. *Ultrasound Obstet Gynecol* 2003; **22**: 358–367.
36. Carvalho JS, Mavrides E, Shinebourne EA, Campbell S, Thilaganathan B. Improving the effectiveness of routine prenatal screening for major congenital heart defects. *Heart* 2002; **88**: 387–391.
37. Asplin N, Dellgren A, Conner P. Education in obstetrical ultrasound—an important factor for increasing the prenatal detection of congenital heart disease. *Acta Obstet Gynecol Scand* 2013; **92**: 804–808.
38. McBrien A, Sands A, Craig B, Dornan J, Casey F. Impact of a regional training program in fetal echocardiography for sonographers on the antenatal detection of major congenital heart disease. *Ultrasound Obstet Gynecol* 2010; **36**: 279–284.
39. Tegnander E, Eik-Nes SH. The examiner's ultrasound experience has a significant impact on the detection rate of congenital heart defects at the second-trimester fetal examination. *Ultrasound Obstet Gynecol* 2006; **28**: 8–14.
40. Pinto NM, Keenan HT, Minich LL, Puchalski MD, Heywood M, Botto LD. Barriers to prenatal detection of congenital heart disease: a population-based study. *Ultrasound Obstet Gynecol* 2012; **40**: 418–425.
41. Vavolizza RD, Dar P, Suskin B, Moore RM, Stern KWD. Clinical yield of fetal echocardiography for suboptimal cardiac visualization on obstetric ultrasound. *Congenit Heart Dis* 2018; **13**: 407–412.
42. Gijtenbeek M, Haak MC. [The standard mid-pregnancy anomaly scan in the Netherlands: what is its effect?]. *Ned Tijdschr Geneesk* 2017; **161**: D1293.