

# Identification of telocytes in dystrophic mice testis

## Identificação de telócitos em testículos de camundongos distróficos

Vilessa Lilian de Araújo Gomes<sup>1</sup>, Janine Karla França da Silva Braz<sup>2</sup>, Gabriel Moura Martins<sup>3</sup>, Naianne Kelly Clebis<sup>2</sup>, Moacir Franco de Oliveira<sup>3</sup>, Danielle Barbosa Morais<sup>2</sup>, Carlos Eduardo Bezerra de Moura<sup>3</sup>

<sup>1</sup> Universidade Federal de Campina Grande, Campina Grande, PB, Brazil.

<sup>2</sup> Universidade Federal do Rio Grande do Norte, Natal, RN, Brazil.

<sup>3</sup> Universidade Federal Rural do Semi-Árido, Mossoró, RN, Brazil.

DOI: 10.31744/einstein\_journal/2021AI5737

### How to cite this article:

Gomes VL, Braz JK, Martins GM, Clebis NK, Oliveira MF, Morais DB, et al. Identification of telocytes in dystrophic mice testis. *einstein* (São Paulo). 2021;19:eAI5737.

### Corresponding author:

Carlos Eduardo Bezerra de Moura  
Universidade Federal Rural do Semi-Árido  
Avenida Francisco Mota, 572 – Presidente Costa e Silva  
Zip code: 59625-900 – Mossoró, RN, Brazil  
Phone: (55 84) 3317-8510, extension 1661  
E-mail: carlos.moura@ufersa.edu.br

### Received on:

Apr 9, 2020

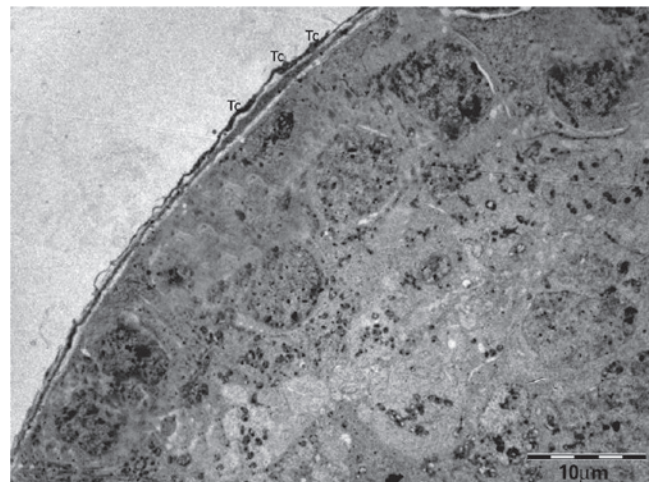
### Accepted on:

Oct 8, 2020

### Copyright 2021

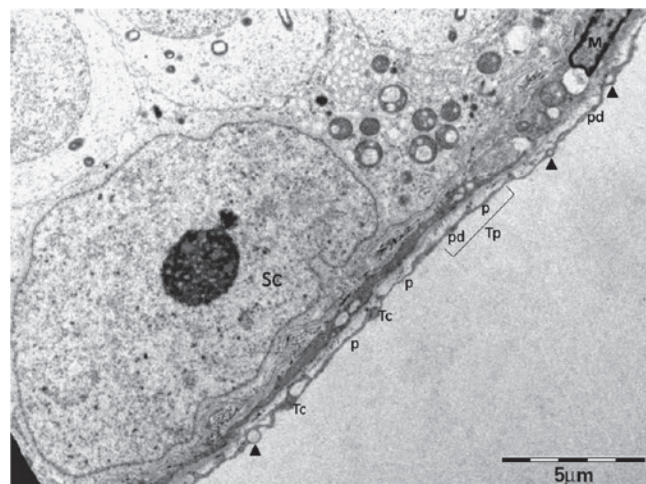


This content is licensed under a Creative Commons Attribution 4.0 International License.



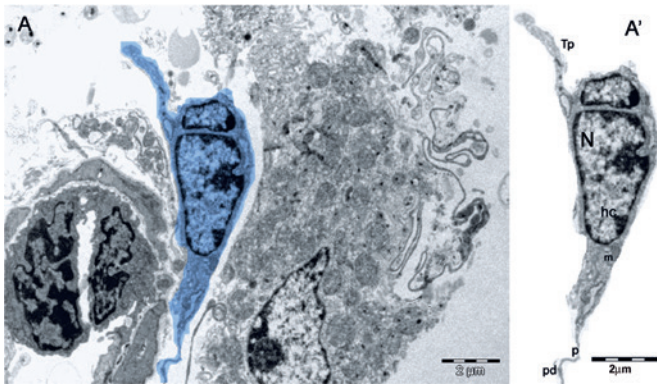
Tc: telocyte.

**Figure 1.** Telocytes surrounding seminiferous tubule in testis of dystrophic mouse



Arrow head: vesicles. Tc: telocyte; p: podomer; pd: podom; Tp: telopodes; SC: Sertoli cell; M: single peritubular myoid cell.

**Figure 2.** Telocytes in peritubular cells of testis of dystrophic mouse



Tp: telopodes; N: nucleus; hc: peripheral heterochromatin; m: mitochondria; p: podomer; pd: podom.

**Figure 3.** Telocytes in intertubular spaces of testis of dystrophic mouse. (A) digitally colored transmission electron microscope of telocyte (blue); (A') section of telocyte with oval nucleus and peripheral heterochromatin

Telocyte (Tc) is a new type of classic interstitial cells, described by Popescu et al.,<sup>(1)</sup> in the human pancreas. Telocytes are found in several organs, including the human testis.<sup>(2)</sup> They are long, thin cells (Figure 1), with small cell bodies, a nucleus containing heterochromatin and presence of mitochondria in the periphery, in addition to a scarcely evident nucleolus.<sup>(3-5)</sup> They differ from other interstitial cells by their long moniliform cytoplasmic extensions, called telopodes (Tp) (Figure 2), and are usually identified through their ultrastructure by transmission electron microscopy (TEM).<sup>(1-5)</sup> The long cytoplasmic projections, Tp, comprise thin segments (podomeres) and dilated regions (podoms), containing secretory vesicles and mitochondria<sup>(4,5)</sup> (Figure 2). Telocytes are located in the peritubular region of the testis and contact myoid cells through cell junctions, while also contacting blood vessels and androgen-producing interstitial cells (Leydig cells) through Tp.<sup>(2,3,5,6)</sup> Therefore, it is believed that Tc establish homo- and heterocellular junctions, vesicle release and paracrine and/or autocrine signaling. They also interact and communicate with Leydig myoid cells and blood vessels through Tp, being responsible for the transport of substances between the interstitium (Figure 3A) and the seminiferous tubule, such as testosterone, which is essential for spermatogenesis.<sup>(2-5)</sup>

Dystrophic intertubular spaces contain Tc measuring, in average, approximately  $8\mu\text{m}$ .<sup>(7)</sup> On the scale of  $2\mu\text{m}$ , it is possible to identify mitochondria, an irregular and oval nucleus with peripheral heterochromatin,

telopodes, podom and podomer (Figure 3A').<sup>(8)</sup> In this context, we could demonstrate Tc, for the first time, in 12 testis of mdx mice with Duchenne muscular dystrophy through TEM analyses. Duchenne muscular dystrophy is a degenerative, progressive and disabling genetic disorder linked to the X chromosome, which does not cause infertility.<sup>(9)</sup> Thus, evidence of Tc in the testis of dystrophic mice implies in further understanding of spermatogenesis, since these cells help transporting testosterone to the seminiferous tubule.

## AUTHORS' INFORMATION

Gomes VL: <http://orcid.org/0000-0002-5772-7361>  
 Braz JK: <http://orcid.org/0000-0002-9570-6465>  
 Martins GM: <http://orcid.org/0000-0001-6489-4187>  
 Clebis NK: <http://orcid.org/0000-0002-1749-7565>  
 Oliveira MF: <http://orcid.org/0000-0002-6269-0823>  
 Morais DB: <http://orcid.org/0000-0003-3277-1857>  
 Moura CE: <http://orcid.org/0000-0002-7960-5373>

## REFERENCES

- Popescu LM, Hinescu ME, Ionescu N, Ciontea SM, Cretoiu D, Ardelean C. Interstitial cells of Cajal in pancreas. *J Cell Mol Med*. 2005;9(1):169-90.
- Marini M, Rosa I, Guasti D, Gacci M, Sgambati E, Ibba-Manneschi L, et al. Reappraising the microscopic anatomy of human testis: identification of telocyte networks in the peritubular and intertubular stromal space. *Sci Rep*. 2018;8(1):14780.
- Pawlicki P, Hejmej A, Milon A, Lustofin K, Plachno BJ, Tworzydło W, et al. Telocytes in the mouse testicular interstitium: implications of G-protein-coupled estrogen receptor (GPER) and estrogen-related receptor (ERR) in the regulation of mouse testicular interstitial cells. *Protoplasma*. 2019; 256(2):393-408.
- Cretoiu SM, Popescu LM. Telocytes revisited. *Biomol Concepts*. 2014; 5(5):353-69. Review.
- Liu Y, Liang Y, Wang S, Tarique I, Vistro WA, Zhang H, et al. Identification and characterization of telocytes in rat testis. *Aging (Albany NY)*. 2019;11(15):5757-68.
- Holstein AF, Schulze W, Davidoff M. Understanding spermatogenesis is a prerequisite for treatment. *Reprod Biol Endocrinol*. 2003;1:107. Review.
- Dawidowicz J, Szotek S, Matysiak N, Mielarczyk Ł, Maksymowicz K. Electron microscopy of human fascia lata: focus on telocytes. *J Cell Mol Med*. 2015;19(10):2500-6.
- Kondo A, Kaestner KH. Emerging diverse roles of telocytes. *Development*. 2019;146(14):dev175018. Review.
- Braz J, Gomes VA, Siman VA, Matta SL, Clebis N, Oliveira M, et al. Spermatogenesis in Mdx mouse model of Duchenne muscular dystrophy. *Anal Quant Cytopathol Histopathol*. 2018;40:125-31.