

LETTER

Pityriasis rubra pilaris following booster dose of mRNA (Pfizer-BioNTech) COVID-19 vaccine

Dear Editor,

Data on various cutaneous adverse events as a result of widespread SARS-CoV-2 vaccination is currently accumulating. However, data on cutaneous reactions following booster dose of COVID-19 vaccines are still limited.^{1,2} Herein, we present a case of pityriasis rubra pilaris (PRP) following a booster dose of the BNT163b2 (Pfizer-BioNTech) mRNA COVID-19 vaccine.

An 85-years-old woman presented to our department with pruritic, erythematous lesions on her scalp, spreading to the trunk and palms, appearing one week after the injection of the booster dose of the Pfizer-BioNTech COVID-19 vaccine. By contrast, the patient reported only mild local tenderness after administration of the first and second dose of the Pfizer-BioNTech COVID-19 vaccine. The patient didn't reveal other possible triggers such as recent infections, changes in her medications, or exposure to UV light preceding the skin eruption. Her medical history was positive for chronic pancreatitis, arrhythmia, and arterial hypertension, and these conditions were well-controlled over a long period. She had no personal or family history of skin diseases. On physical examination, she presented with scaly orange to red plaques on her trunk and waxy yellow palmar keratoderma (Figure 1A–C). Her legs, soles, and nails were not affected at the initial assessment. Our clinical diagnosis of PRP was confirmed by histopathological examination showing irregular epidermal hyperplasia with broad epidermal ridges, hyperkeratosis with alternating orthokeratosis and parakeratosis, follicular plugging and a sparse perivascular lymphocytic infiltrate in the superficial dermis (Figure 1D). The COVID-19 vaccination was the only detectable trigger. Therefore, we started treatment with acitretin 30 mg once daily, along with topical mometasone 0.1% ointment which resulted in complete regression of skin lesions 4 months later.

PRP is a rare inflammatory papulosquamous dermatosis, that has recently been linked to the mutations in the caspase recruitment domain-containing protein 14 (CARD14).³ Infections, drugs, malignancies, and rarely vaccines, are all possible PRP triggers.^{3,4} Previously, cases of PRP have been observed following vaccination with diphtheria, poliovirus and influenza vaccines.⁴ SARS-CoV-2 vaccines have recently been recognized as a potential trigger for PRP.^{5–9} Several cases of PRP have already been reported following the first two doses of SARS-CoV-2 vaccines, however this is the first case to describe PRP after homologous booster dose of Pfizer-BioNTech mRNA COVID-19 vaccine.^{5–9} Booster doses are given 6 months after the patient's primary vaccine series has been completed. A recent study on cutaneous reactions after booster doses of mRNA COVID-19

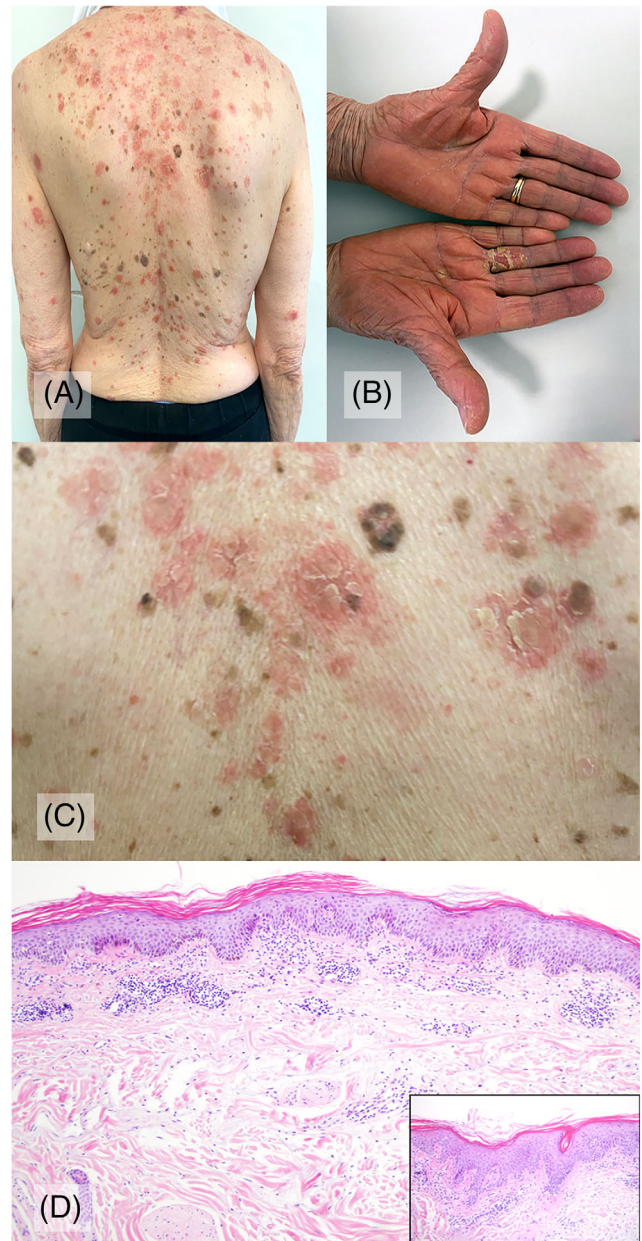


FIGURE 1 Clinical and histopathological presentation of PRP. Red to orange scaly plaques on the back with orange waxy palmar keratoderma (A–C). A skin biopsy (D) showing irregular epidermal hyperplasia with broad rete ridges, hyperkeratosis with alternating orthokeratosis and parakeratosis and a sparse superficial perivascular lymphocytic infiltrate (H&E, 100× magnification). Inset shows additional section with follicular plugging (H&E, 200× magnification)

vaccines found that urticaria was the most common reaction, followed by local injection site reactions, erythromelalgia, and vesicular reactions.^{1,2} In our case, the onset of PRP was 7 days, which is consistent with the study on cutaneous adverse reactions following SARS-CoV-2 vaccine booster.² Interestingly, and in line with our findings, cutaneous reactions to booster doses might happen even in the absence of reactions to the first and second shots.^{1,2} The vaccine-related PRP development may be induced by upregulation of inflammatory immunological pathways, or cross-reactivity between viral or adjuvant molecules and self-antigens.^{1,8} It appears that in our patient, repeated exposure to the same mRNA vaccine stimulated the immune system, causing a cytokine imbalance that resulted in the development of PRP.

This is, to the best of our knowledge, the first case of PRP following a booster dose of the novel BNT163b2 mRNA COVID-19 vaccine. Currently, cutaneous reactions following the booster dose represent only a small portion of the cutaneous reactions caused by COVID-19 vaccines.^{1,2} Nonetheless, as a result of booster vaccination having the potential to trigger immune-mediated skin diseases, it is reasonable to expect more reports on vaccine-induced cutaneous adverse reactions in the future. Finally, our case demonstrates the possibility of developing a cutaneous reaction after receiving a booster dose of mRNA COVID-19 vaccine, even in the absence of a reaction to the first and second doses of the same SARS-CoV-2 vaccine.

AUTHOR CONTRIBUTIONS

Nika Hlaca conceived the original idea and wrote the original manuscript. Tina Zagar, Sandra Peternel, Katarina Dujmovic-Hasanbegovic and Ines Brajac performed literature research and contributed to the analysis of the data. Marija Kastelan and Larisa Prpic-Massari performed supervision, writing-review and editing.

CONFLICT OF INTEREST





The authors declare that they have no competing interests.

DATA AVAILABILITY STATEMENT

The data that support the findings of this study are available from the corresponding author upon reasonable request.


INFORMED CONSENT

Informed consent was obtained from the patient for publication of this report.

Nika Hlaca^{1,2} 
 Tina Zagar^{1,2} 
 Marija Kastelan^{1,2} 
 Sandra Peternel^{1,2} 

Ines Brajac^{1,2} 

Katarina Dujmovic-Hasanbegovic^{1,2}

Larisa Prpic-Massari^{1,2} 

¹Department of Dermatovenerology, Clinical Hospital Centre Rijeka, Rijeka, Croatia

²Faculty of Medicine, University of Rijeka, Rijeka, Croatia

Correspondence

Tina Zagar, Department of dermatovenerology, Clinical Hospital Centre Rijeka and Faculty of Medicine, University of Rijeka, Croatia.

Email: tinazagar89@gmail.com

ORCID

Nika Hlaca  <https://orcid.org/0000-0002-0517-5462>

Tina Zagar  <https://orcid.org/0000-0002-0308-4057>

Marija Kastelan  <https://orcid.org/0000-0002-8318-8031>

Sandra Peternel  <https://orcid.org/0000-0001-8590-0451>

Ines Brajac  <https://orcid.org/0000-0003-1491-7998>

Larisa Prpic-Massari  <https://orcid.org/0000-0003-3572-6197>

REFERENCES

- Prasad S, McMahon DE, Tyagi A, et al. Cutaneous reactions following booster dose administration of COVID-19 mRNA vaccine: A first look from the American Academy of Dermatology/International League of Dermatologic Societies registry. *JAAD Int.* 2022;8:49-51.
- Avallone G, Cavallo F, Astrua C, et al. Cutaneous adverse reactions following SARS-CoV-2 vaccine booster dose: a real-life multicentre experience. *J Eur Acad Dermatol Venereol.* 2022 Jun 30. [Epub ahead of print]. doi:[10.1111/jdv.18386](https://doi.org/10.1111/jdv.18386)
- Wang D, Chong VC, Chong WS, Oon HH. A Review on Pityriasis Rubra Pilaris. *Am J Clin Dermatol.* 2018;19(3):377-390.
- Mohamed M, Belhadjali H, Hammedi F, Ben Meriem C, Zili J. Pityriasis rubra pilaris occurring after vaccination with diphtheria-pertussis-tetanus and oral poliovirus vaccines. *Indian J Dermatol Venereol Leprol.* 2015;81(6):618-620.
- Hunjan MK, Roberts C, Karim S, Hague J. Pityriasis rubra pilaris-like eruption following administration of the BNT163b2 (Pfizer-BioNTech) mRNA COVID-19 vaccine. *Clin Exp Dermatol.* 2022;47(1):188-190.
- Lladó I, Butrón B, Sampredo-Ruiz R, Fraga J, de Argila D. Pityriasis rubra pilaris after Vaxzevria® COVID-19 vaccine. *J Eur Acad Dermatol Venereol.* 2021;35(12):e833-e835.
- Sechi A, Pierobon E, Pezzolo E, et al. Abrupt onset of Sweet syndrome, pityriasis rubra pilaris, pityriasis lichenoides et varioliformis acuta and erythema multiforme: unravelling a possible common trigger, the COVID-19 vaccine. *Clin Exp Dermatol.* 2022;47(2):437-440.
- Criado PR, Ianhez M, Rocha PS, Miot HA. Pityriasis rubra pilaris (type I) following ChAdOx1 COVID-19 vaccine: A report of two cases with successful treatment with oral isotretinoin. *J Eur Acad Dermatol Venereol.* 2022;36(7):e508-e510.
- Sahni MK, Roy K, Asati DP, Khurana U. An old entity, a new trigger: Post COVID-19 vaccine pityriasis rubra pilaris. *Int J Risk Saf Med.* 2021; 32(4):261-264.