



RBO

REVISTA BRASILEIRA DE ORTOPEDIA

www.rbo.org.br



Original Article

Fasciocutaneous flaps for covering foot and ankle injuries

Alexandre Carvalho Quirino^{a,*}, Karen Cristina Viegas^b

^a Hand Surgery Service, Hospital São João de Deus, Divinópolis, MG, Brazil

^b Universidade Federal de São João Del Rei, São João Del Rei, MG, Brazil

ARTICLE INFO

Article history:

Received 18 January 2012

Accepted 27 May 2013

Available online 18 March 2014

Keywords:

Surgical flaps

Lower extremity

Leg injuries/surgery

Reconstructive surgical procedures

ABSTRACT

Objective: to present some cases from our service and to confirm that sural and lateral supramalleolar flaps are good options for covering the soft tissues of the foot and ankle.

Methods: twenty-two flaps were constructed in 21 patients of ages ranging from 15 to 72 years. Male patients predominated (66.6%) and in 47.6% of the cases the injury resulted from accidents involving motorcycles.

Results: among the 22 flaps, 12 were sural and 10 were lateral supramalleolar; in one case, two flaps were used. In all the cases, the injuries were successfully covered and the patients recovered well. During the postoperative follow-up, the commonest complication was epidermolysis, occurring in eight cases (three in a sural flap and five in a supramalleolar flap), among which two cases progressed to distal necrosis of the flap (one sural and the other supramalleolar). One patient wanted the flap reviewed for esthetic reasons.

Conclusions: sural and supramalleolar flaps are very reliable. They preserve the main trunk arteries, are quickly dissected, have low hospital cost, enable coverage of extensive areas, present esthetically acceptable damage to the donor area and do not impair motor function.

© 2014 Sociedade Brasileira de Ortopedia e Traumatologia. Published by Elsevier Editora

Ltda. Este é um artigo Open Access sob a licença de [CC BY-NC-ND](http://creativecommons.org/licenses/by-nc-nd/4.0/)

Retalhos fasciocutâneos para cobertura de lesões no pé e tornozelo

RESUMO

Objetivo: mostrar alguns casos do nosso serviço, além de confirmar como boas opções os retalhos sural e supramaleolar lateral na cobertura de partes moles do pé e tornozelo.

Métodos: foram feitos 22 retalhos em 21 pacientes, entre 15 e 72 anos. Houve predomínio do sexo masculino, com 66,6%, e em 47,6% as lesões foram decorrentes de acidentes que envolveram motocicletas.

Resultados: dos 22 retalhos, 12 foram do tipo sural e 10, supramaleolar lateral. Em um caso usaram-se os dois retalhos. Em todos os casos houve sucesso na cobertura das lesões, com boa recuperação dos pacientes. No seguimento pós-operatório a complicação mais comum

Palavras-chave:

Retalhos cirúrgicos

Extremidade inferior

Traumatismos da perna/cirurgia

Procedimentos cirúrgicos

reconstrutivos

* Please cite this article as: Quirino AC, Viegas KC. Retalhos fasciocutâneos para cobertura de lesões no pé e tornozelo. Rev Bras Ortop. 2014;49:183-188.

** Work performed at Hospital São João de Deus and at Hospital Santa Lúcia, Divinópolis, MG, Brazil.

* Corresponding author.

E-mail: alexandrequirino@uol.com.br (A.C. Quirino).

2255-4971 © 2014 Sociedade Brasileira de Ortopedia e Traumatologia. Published by Elsevier Editora Ltda.

Este é um artigo Open Access sob a licença de [CC BY-NC-ND](http://creativecommons.org/licenses/by-nc-nd/4.0/) <http://dx.doi.org/10.1016/j.rboe.2014.03.004>

foi a epidermólise, com oito casos, três no retalho sural e cinco no supramaleolar, dos quais dois progrediram para pequena necrose distal do retalho, um deles sural e o outro supramaleolar. Um paciente desejou rever o retalho por questão estética.

Conclusões: os retalhos sural e supramaleolar são bastante confiáveis, preservam os troncos arteriais principais, são de rápida dissecação, têm baixo custo hospitalar, permitem cobertura de áreas extensas e apresentam dano estético aceitável na área doadora sem prejuízo funcional motor.

© 2014 Sociedade Brasileira de Ortopedia e Traumatologia. Publicado por Elsevier Editora Ltda. Este é um artigo Open Access sob a licença de [CC BY-NC-ND](#)

Introduction

Before beginning this study, we obtained approval from the Brazil Platform, an online tool for registering research that involves human beings, which is aimed toward the general public and toward aiding the work of the Research Committee system and the National Research Ethics Committee of the National Health Council (CEP/CONEP/CNS).

Today, with the significantly increased number of car and motorcycle accidents, tissue losses from the foot and ankle region are becoming increasingly frequent.¹ These injuries are dealt with routinely at referral services, where labor, surgical techniques and specialized training are abundantly available, with the capability to resolve such losses using free flaps.

On the other hand, many such services, often distant from the metropolises, also receive significant numbers of cases of these injuries but do not have the same conditions as the referral services. Thus, one very reasonable choice for covering these tissue losses in feet and ankles is sural fasciocutaneous and lateral supramalleolar flaps. These two flaps were described by Masquelet et al. in 1992,^{2,3} and they have become one of the few options for covering these regions, which have a sparse vascular bed⁴ in which bones and tendons are often found to be exposed in addition to vessels and nerves.

Sural and lateral supramalleolar flaps are very reliable^{5,6}; they preserve the main trunk arteries, can be dissected rapidly and, differently from free flaps, have a low hospital cost. They make it possible to cover large areas, have a large range of rotation,^{5,7} presented acceptable esthetic damage in the donor area without functional damage and are therefore a good choice for covering foot and ankle injuries.⁸

The present study had the aim of showing some cases from our service, as well as confirming that sural and lateral supramalleolar flaps are good options for covering soft tissues of the foot and ankle. It also confirms that many injuries that formerly were only covered with free flaps can also be resolved using fasciocutaneous flaps, with faster and simpler techniques, at services that do not have the human and/or surgical resources for microsurgical flaps of greater sophistication. In this manner, free flaps are left as the last option and/or for cases in which there really is no other choice.

Materials and methods

Twenty-one patients (22 flaps) attended at Hospital São João de Deus and Hospital Santa Lúcia in Divinópolis, Minas Gerais, between 2007 and 2012, were evaluated. Fourteen patients

Table 1 – Details of the population studied.

Variables	N	%
Sex		
Male	14	66.67
Female	7	33.33
Cause of injury		
Motorcycle accidents	10	47.62
Other types	11	52.38
Comorbidities		
Yes	3 (SAH ^a : 2/DM ^b : 1)	14.28
No	18	85.72

^a Systemic arterial hypertension.
^b Diabetes mellitus.

were male and seven were female, with a mean age of 37 years and a range from 15 to 72. The side affected and dominant side were evenly balanced among the patients.

In 10 patients (47.6%), the injuries resulted from motorcycle accidents. The injuries were observed in different regions of the foot and ankle, with nine cases in the ankle, seven in the hindfoot (including the heel) and six between the midfoot and forefoot. The time that had elapsed between the injury and the surgery to provide coverage ranged from two to 264 days, with a mean of 40.3. There were four contaminated cases, which were the ones with the longest delay in provision of coverage, with a mean of 116.5 days.

Three patients presented comorbidities: two with systemic arterial hypertension (SAH) and one with diabetes mellitus (DM) (Table 1 and Fig. 1).

The surgical options for covering the tissue losses were chosen between sural flaps (constructed in 12 patients) and

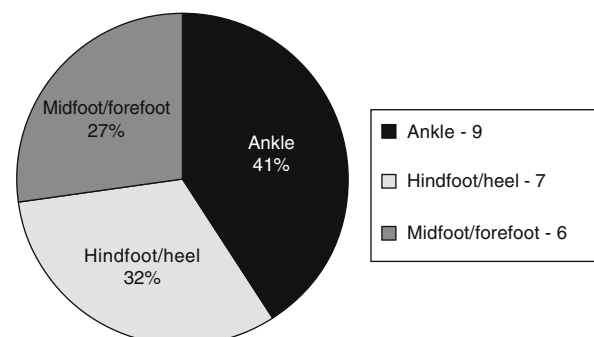


Fig. 1 – Distribution of the population studied according to the location of the injury.

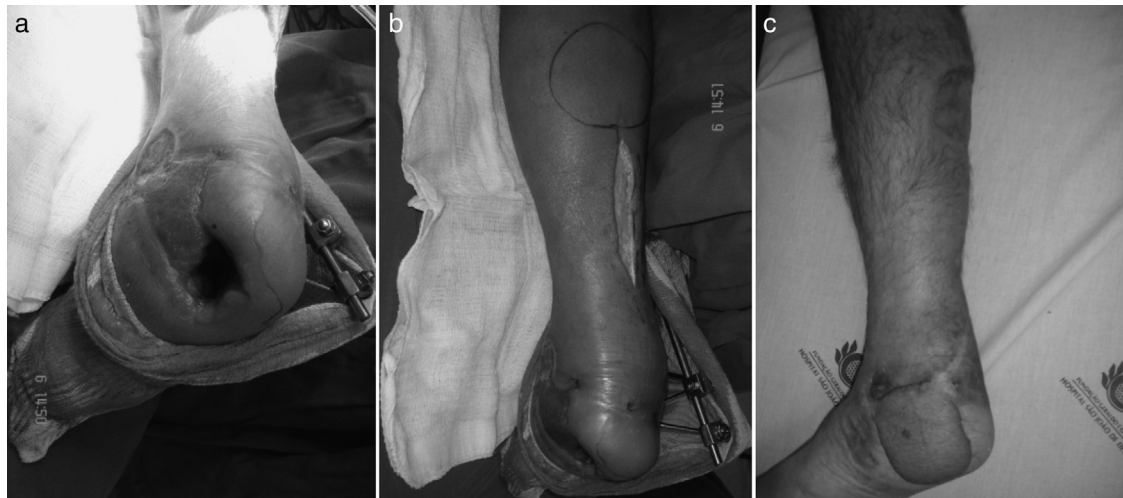


Fig. 2 – Case 1, right foot. (a) Loss of skin and bone tissue at the level of the heel; contaminated wound; (b) marking for the sural flap with start of the dissection and a pivot point 5 cm above the lateral malleolus; (c) final result after 18 months of evolution, without infection.

lateral supramalleolar flaps (in 10 patients). Both flaps were used in one patient.

Both of these are fasciocutaneous flaps, composed of skin, subcutaneous tissue and fascia. Sural flaps contain the sural nerve and, for this reason, they are also neurocutaneous flaps with irrigation through a branch of the fibular artery, the sural artery.^{9,10} Meanwhile, supramalleolar flaps are supplied by an anastomotic network from the ankle.¹¹

The flap is only constructed after rigorous debridement in one or more surgical procedures, depending on the type of wound and the degree of contamination. The position was chosen according to the choice of flap: ventral decubitus for the sural flap and lateral decubitus of 50° for the supramalleolar flap. Both of these were constructed using a pneumatic tourniquet.

Sural flaps were marked out starting at a point 5 cm above the lateral malleolus, at the site where the sural artery emerges, which was the pivot point. A line was traced out longitudinally in the proximal direction, between this point and the Achilles tendon. Following this, a mold of the injury was made using a compress and methylene blue, so as to then project the mold corresponding to the area of the injury, from the pivot point to the location for raising the flap, on the posterior face of the lower leg. Raising the flap began proximally, with the aid of a magnifying glass of 3.5× magnification, and the sural nerve and artery were located so as to form part of the flap. The flap was carefully lifted from a subfascial layer and the branches of the sural artery to the adjacent muscles were cauterized. The pedicle of the flap should always be accompanied by about 2–3 cm of fatty tissue surrounding it, so that there is no risk of distress and to minimize congestion of the flap (Fig. 2a–c).

In the supramalleolar flap, a point was marked in the depression of the lower part of the local tibiofibular space, where the perforating branch of the fibular artery penetrates the interosseous membrane, around 5 cm from the tip of the lateral malleolus. This branch is anastomosed with the anterior lateral malleolar artery and then with the lateral tarsal

artery in the lateral edge of the foot. The flap can be peninsular or pedunculate, in an island with a distal base, depending on the area of coverage.

The sural flap needed to be designed to be located 2–3 cm distally to the abovementioned point and, as described for sural flaps, the supramalleolar flap was also designed starting from the pivot point, with the mold of the injury, and was raised with a broad pedicle for security. The dissection was started on the anterior face of the design and proceeded proximally. At this location, the superficial fibular nerve was encountered and was cauterized. The flap was raised from a subfascial plane and was extended to the periosteum of the fibula. If there was a need for very distal coverage of the foot, the dissection became slightly more laborious and there was a need to dissect the pedicle beyond the tarsal canal. At this location, the pedicle was subdermal and there was a greater risk of injury to the pedicle and also of flap distress (Fig. 3a–d).

Among the sural flap cases, flap rotation passing through a tunnel was performed in five patients and the skin was opened for the flap to pass by in seven patients. Eleven patients firstly underwent grafting in the donor area.

Among the supramalleolar cases, the flap was rotated and the skin was opened (without a tunnel) in five patients, while the flap passed through a tunnel in four patients and the flap was peninsular in one patient. In all these ten patients, the donor area firstly underwent grafting.

Out of the 21 patients, the wounds were clean in 17 cases and contaminated in four cases: three with osteomyelitis and one with pyoarthritis. Thirteen patients came through SUS, seven through contracted services and one as a private patient.

All the patients were operated under spinal anesthesia. Doppler ultrasound was not used in any of the cases. Suturing was performed using mononylon 4.0 and 5.0 and was left quite slack when above the pedicle. Long gauze was used extensively for the dressings, with care regarding compression.

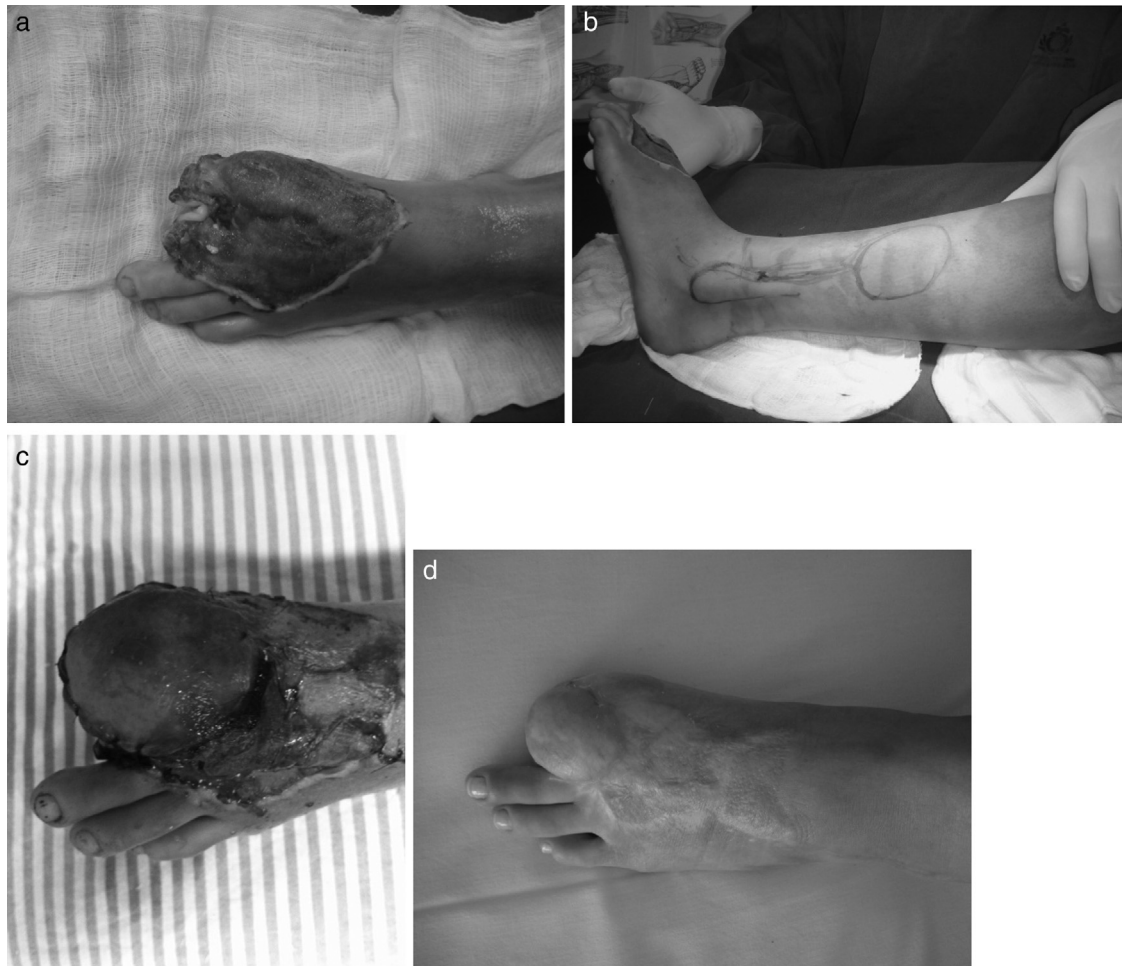


Fig. 3 – Case 2, left foot. (a) Loss of skin and bone material at the level of the forefoot, with exposure of the phalanx bone and the sesamoids of the hallux; (b) marking of the lateral supramalleolar flap with the pivot point in the depression in the lower part of the tibiofibular space, the location where the perforating branch of the fibular artery penetrates the interosseous membrane around 5 cm from the tip of the lateral malleolus; (c) 7th postoperative day, showing grafted area around the flap, and flap with epidermolysis; (d) final result after 10 months of evolution, showing good coverage of the injury.

Results

In all cases, the injuries were successfully covered, with good recovery among the patients. However, some complications were observed. The commonest of these was epidermolysis, in eight cases (36.3%): three in sural flaps and five in supramalleolar flaps. Of these patients, two (one sural and the other supramalleolar) progressed to slight distal necrosis of the flap. The supramalleolar case required a new intervention, with subsequent skin grafting at the site. In one patient who had already undergone reconstruction with a sural flap, the burn injury progressed, with new bone exposure. It was decided to construct a new flap, choosing the lateral supramalleolar type (Fig. 4a-c).

Among the four contaminated cases, one of them presented recurrence of secretion drainage, even with the treatment. Another two interventions were needed, with debridement and curettage.

Out of the 21 patients operated, 20 were not concerned regarding the issue of esthetics and only one wished to review

the flap. Fat elimination was performed one year after the first surgical approach.

No neuromas were observed in the flap donor areas, neither in the sural nor in the fibular nerve. None of the patients suffered gait alterations consequent to undergoing the flap surgery. When asked, all the patients reported paresthesia on the lateral face of the foot in cases of sural flaps or the medial and intermediate faces of the midfoot and forefoot in cases of lateral supramalleolar flaps. However, they did not place any importance on this symptom.

Discussion

Flaps for providing skin coverage for feet and ankles have been described.^{6,12-17} However, in most injuries involving loss of tissue, it is not possible to achieve coverage using only the surrounding tissue. Distant flaps have to be chosen, which could be fasciocutaneous or free flaps.^{6,13-17}

Because these are poorly vascularized regions⁴ that also have thin skin and a large number of prime tissues such as

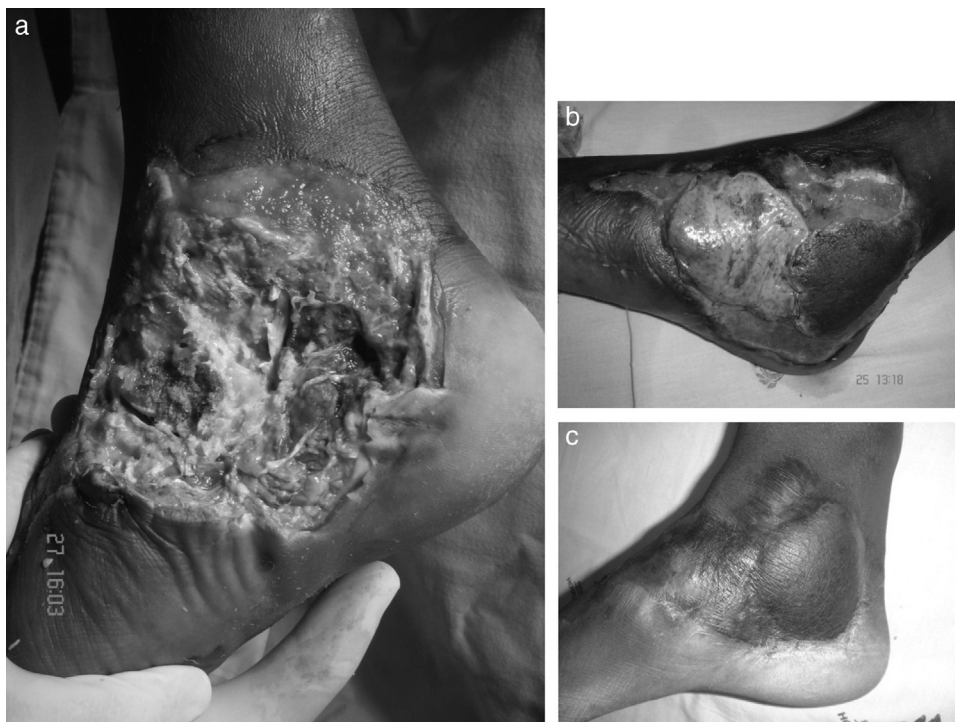


Fig. 4 – Case 3, right foot: sural and lateral supramalleolar flaps. (a) Loss of skin tissue with bone exposure in the midfoot and hindfoot and part of the ankle, secondary to burns after an accident involving a motorcycle exhaust; (b) sural flap integrated in the hindfoot and lateral supramalleolar flap with epidermolysis in the midfoot; (c) final result after two years of evolution.

tendons, arteries, veins, nerves and, just below, bones, coverage using skin grafts is not achieved in most of these injuries. These segments require stable coverage so as to enable better joint mobility and make it possible for the tendons to slide well, for gait to occur with a minimum of claudication and for there to be as few functional sequelae as possible.

Sural and lateral supramalleolar flaps are reliable, allow coverage of extensive areas and have a large arc of rotation.^{5,6,18,19} Thus, they are an excellent choice for coverage of injuries to feet and ankles.^{6,20-22} Even though these flaps are different regarding their dissection, such that supramalleolar flaps take longer, with greater technical difficulty, we did not observe any significant differences regarding complications. Our experience differed from that of Touam et al., who found a greater number of complications, such as flap necrosis, when lateral supramalleolar flaps were chosen.²³

The first-choice flap was the sural flap, because it is the simpler of the two. What matters is not the size of the injury but, rather, its location. In cases of very distal injuries to the forefoot and midfoot, and in patients with scars in the area where the sural flap would be raised, the lateral supramalleolar flap was chosen. In our sample, we could see that the greater time required and the difficulty cited in relation to lateral supramalleolar flaps only occurred when there was a need to extend the flap beyond the point corresponding to the depression in the lower part of the tibiofibular space, the location where the perforating branch of the fibular artery penetrates the interosseous membrane. We believe that these are the cases in which there are more failures in raising this flap.

With regard to tunnel construction, there is divergence in the literature and it is believed that this increases the risk of flap distress, due to vessel compression,²⁴ as well as the risk of distress due to traction. In the present study, we do not have sufficient comparative data to decide between open or tunneled approaches. However, in cases in which the tunnel was long, such as in forefoot injuries, and in those in which the flap was extensive, we preferred to open the skin and subcutaneous tissue, rather than running the risk of compression and traction of the pedicle.

Conclusion

Sural and supramalleolar flaps are very safe, with reliable pedicles, a good cost/benefit relationship and acceptable tissue damage in the region. They do not cause functional damage, the duration of the surgery is short, they are easy to dissect, important vessels in the region are preserved and there is a low complication rate.

They are options for providing coverage for extensive injuries to the hindfoot, midfoot, forefoot and ankle; they can be performed at medium and high-complexity services, and can be considered to be one of the first choices for these injuries.

Conflicts of interest

The authors declare no conflicts of interest.

Acknowledgement

The authors are grateful to Prof. Dr. Arlindo Gomes Pardini Júnior.

REFERENCES

1. Ministério da Saúde – Sistemas de Informações Hospitalares do SUS (SIH-SUS). Morbidade Hospitalar do SUS por Acidentes de Transporte por Local de Internação de 2008–2010. Available from: <http://tabnet.datasus.gov.br/cgi/tabcgi.exe?sih/cnv/fiuf.def> [accessed 2012].
2. Masquelet AC, Beveridge J, Romana C, Gerber C. The lateral supramalleolar flap. *Plast Reconstr Surg*. 1988;81(1):74–81.
3. Masquelet AC, Romana MC, Wolf G. Skin island flaps supplied by the vascular axis of the sensitive superficial nerves: anatomic study and clinical experience in the leg. *Plast Reconstr Surg*. 1992;89(6):1115–21.
4. Buluç L, Tosun B, Sen C, Sarlak AY. A modified technique for transposition of the reverse sural artery flap. *Plast Reconstr Surg*. 2006;117(7):2488–92.
5. Kneser U, Bach AD, Polykandriotis E, Kopp J, Horch RE. Delayed reverse sural flap for staged reconstruction of the foot and lower leg. *Plast Reconstr Surg*. 2005;116(7):1910–7.
6. Follmar KE, Baccarani A, Baumeister SP, Levin LS, Erdmann D. The distally based sural flap. *Plast Reconstr Surg*. 2007;119(6):138e–48e.
7. Garcia AMC. Retalho sural reverso para reconstrução distal da perna, tornozelo, calcanhar e do pé. *Rev Bras Cir Plast*. 2009;24(1):96–103.
8. Weber ES, Franciosi LF, Mueller SF, Dalponte M, Heurich NR, Gonçalves SC. Retalho sural para reconstrução do pé. *ACM Arq Catarin Med*. 2007;36 Suppl. 1:1–4.
9. Almeida MF, da Costa PR, Okawa RY. Reverse-flow island sural flap. *Plast Reconstr Surg*. 2002;109(2):583–91.
10. Vendramin FS. Retalho sural de fluxo reverso: 10 anos de experiência clínica e modificações. *Rev Bras Cir Plast*. 2012;27(2):309–15.
11. Torres CB. El colgajo supramaleolar lateral: un colgajo de excepción. *Rev Colomb Ortop Traumatol*. 2011;25(1):40–9.
12. Martins GB, Moreira AA, Viana FO. Reconstrução de lesões de partes moles do calcânhar com o uso de retalhos fasciocutâneos. *Rev Bras Cir Plast*. 2009;24(1):104–9.
13. Masquelet AC, Gilbert A. Atlas colorido de retalhos na reconstrução dos membros. Rio de Janeiro: Revinter; 1997.
14. Karki D, Narayan RP. The versatility of perforator-based propeller flap for reconstruction of distal leg and ankle defects. *Plast Surg Int*. 2012;2012:303247.
15. Rezende MR, Rabelo NTA, Benabou JE, Wei TH, Mattar JR, Zumioti AV, et al. Cobertura do terço distal da perna com retalhos de perfurantes pediculados. *Acta Ortop Bras*. 2008;16(4):223–9.
16. Lazo DA, Zatiti SCA, Colicchio O, Alvarez DM, Mazzer N, Alvarez IM, et al. O emprego dos retalhos livres em pacientes queimados: experiência de 58 retalhos em 46 pacientes. *Rev Bras Cir Plast*. 2009;24(2):138–44.
17. Heller L, Levin S. Lower Extremity microsurgical reconstruction. *Plast Reconstr Surg*. 2001;108(4):1029–41.
18. Cheema TA, Saleh ES, Carvalho AF. The distally based sural artery flap for ankle and foot coverage. *J Foot Ankle Surg*. 2007;46(1):40–7.
19. All-Qattan MM. The reverse sural fasciomusculocutaneous “mega high” flap: a study of 20 consecutive flaps for lower-limb reconstruction. *Ann Plast Surg*. 2007;58(5):513–6.
20. Suga H, Oshima Y, Harii K, Asato H, Takushima A. Distally-based sural flap for reconstruction of the lower leg and foot. *Scand J Plast Reconstr Surg Hand Surg*. 2004;38(1):16–20.
21. Akhtar S, Hameed A. Versatility of the sural fasciocutaneous flap in the coverage of lower third leg and hind foot defects. *J Plast Reconstr Aesthet Surg*. 2006;59(8):839–45.
22. Demiri E, Foroglou P, Dionysiou D, Kakas AAP, Pavlidis L, Lazaridis L. Our experience with the lateral supramalleolar island flap for reconstruction of the distal leg and foot: a review of 20 cases. *Scand J Plastic Reconstr Surg Hand Surg*. 2006;40(2):106–10.
23. Touam C, Rostoucher P, Bhatia A, Oberlin C. Comparative study of two series of distally based fasciocutaneous flaps for coverage of the lower one-fourth of the leg, the ankle, and the foot. *Plast Reconstr Surg*. 2001;107(2):383–92.
24. Belém LFMM, Lima JCSA, Ferreira FPM, Ferreira EM, Penna FV, Alves MB. Retalho sural de fluxo reverso em ilha. *Rev Soc Bras Cir Plast*. 2007;22(4):195–201.