

A Giant Internal Carotid Bifurcation Aneurysm as a Rare and Dangerous Differential Diagnosis of a Craniopharyngioma

Review began 01/16/2022
Review ended 01/21/2022
Published 01/25/2022

© Copyright 2022

Perret et al. This is an open access article distributed under the terms of the Creative Commons Attribution License CC-BY 4.0., which permits unrestricted use, distribution, and reproduction in any medium, provided the original author and source are credited.

Caio M. Perret^{1,2}, Raphael Bertani³, Stefan W. Koester⁴, Paulo Eduardo Santa Maria³, Daniela Von Zuben³, Sávio Batista⁵, Hugo C. Schiavini³, José Alberto Landeiro⁶

1. Neurological Surgery, Hospital Municipal Miguel Couto, Rio de Janeiro, BRA 2. Neuroscience, Federal University of Rio de Janeiro, Rio de Janeiro, BRA 3. Neurosurgery, Hospital Municipal Miguel Couto, Rio de Janeiro, BRA 4. Neurosurgery, Vanderbilt University School of Medicine, Nashville, USA 5. Faculty of Medicine, Federal University of Rio de Janeiro, Rio de Janeiro, BRA 6. Neurosurgery, Hospital Universitario Antonio Pedro, Rio de Janeiro, BRA

Corresponding author: Raphael Bertani, neurosurgery@rbertani.com

Abstract

Craniopharyngiomas are supra/parasellar lesions that often present with general, unspecific symptoms. Similarly, internal carotid artery (ICA) bifurcation giant aneurysms may also produce calcified, heterogeneous, parasellar expansive lesions, posing a relevant differential diagnosis due to their inherently different surgical strategies and risks. We report the case of a 54-year-old female presenting with progressive disorientation and apathetic behavior. CT and MRI reports described a suprasellar heterogeneous mass with calcifications associated with an adjacent, laterally located fluid collection suggestive of a craniopharyngioma. During the surgical procedure, perfuse and unexplained arterial bleeding ensued, prompting the surgical team to review a previous contrast-enhanced CT scan. Careful inspection revealed an image suggestive of vascular pathology, with an area of continuous hyperdensity along the right ICA bifurcation. The Sylvian fissure was dissected, and an aneurysmal neck was encountered and successfully clipped. Giant intracranial aneurysms are rare but essential differential diagnoses to be considered during the workup and surgical approach toward parasellar mass lesions. This case illustrates the importance of performing a CT angiogram (CTA) for skull base lesions, even when the size is more suggestive of tumor pathology.

Categories: Neurosurgery

Keywords: giant carotid aneurysm, imaging, carotid bifurcation aneurysm, craniopharyngioma, giant aneurysm

Introduction

The differential diagnosis of lesions of the sellar, parasellar, and suprasellar regions of the central nervous system (CNS) includes various lesions with varying etiologies. Not all of them are neoplastic (and more recurrent), such as the more common Rathke cleft cysts, pituitary adenomas, and craniopharyngiomas. There are granulomatous processes, autoimmune diseases, and immunocompromised state-related infections among rare cases. These cases potentially impose significant challenges in establishing the proper diagnosis and clinical conduction because of the low frequency in this anatomic region. They may present similar signs, symptoms, and radiological findings [1]. Therefore, as a therapeutic approach, the diagnostic conclusion of these lesions is only adequate and thorough after histopathological studies, which require surgical intervention and biopsy of the lesion [2].

Craniopharyngiomas are calcified, cystic, or mixed solid and cystic tumors. Embryologically, they originate from Rathke's pouch and extend into the suprasellar midline region, often directed into the third ventricle, along the pituitary stalk and the optic chiasm [3]. Main neuroimaging findings include calcifications in the parasellar region, cystic degeneration, and sometimes distortions of the sellar anatomy. Due to their location, these lesions may produce hormonal imbalances and vision loss, apart from more general symptoms such as chronic headache, depression, and disorientation [4,5].

However, some lesions might not be amenable to a straightforward diagnosis due to their unusual presentation on simple imaging, and their true nature is only revealed either with a more detailed workup with vascular studies or only intraoperatively. In addition, carotid bifurcation giant aneurysms may also produce calcified, heterogeneous, parasellar expansion-masses mimicking the appearance of a craniopharyngioma, posing a relevant differential due to their inherently different surgical strategies and risks [6]. In the entire medical literature, two papers have reported giant aneurysms mimicking craniopharyngiomas both clinically and radiologically [7,8].

We report the case of a patient presenting with a heterogeneous, calcified, parasellar/suprasellar mass lesion measuring 5.1 cm, with an apparent 6.0-cm cystic-degeneration; it was reported as a probable craniopharyngioma on a radiologist's notes, and which was revealed intraoperatively to be a giant, calcified aneurysm upon its inadvertent incision, subsequent bleeding, and successful treatment with direct clipping.

How to cite this article

Perret C M, Bertani R, W. Koester S, et al. (January 25, 2022) A Giant Internal Carotid Bifurcation Aneurysm as a Rare and Dangerous Differential Diagnosis of a Craniopharyngioma. *Cureus* 14(1): e21588. DOI 10.7759/cureus.21588

Case Presentation

A 54-year-old female patient presented to the emergency room with progressive disorientation, apathetic behavior, and bilateral lower limb weakness. She underwent a CT scan to rule out bleeding, which was followed by a contrast-enhanced CT scan when a suprasellar mass was identified. MRI showed a suprasellar heterogeneous mass with calcification areas associated with an adjacent, lateralized fluid collection. Intraoperatively, further contrasted CT reconstruction evidenced a hyperdense image within the tumor wall, continuous with the top of the right carotid artery. The radiological report suggested a craniopharyngioma (Figure 1). The patient had a clinical history of hypothyroidism, with no other hormonal or metabolic alterations in the preoperative screening.

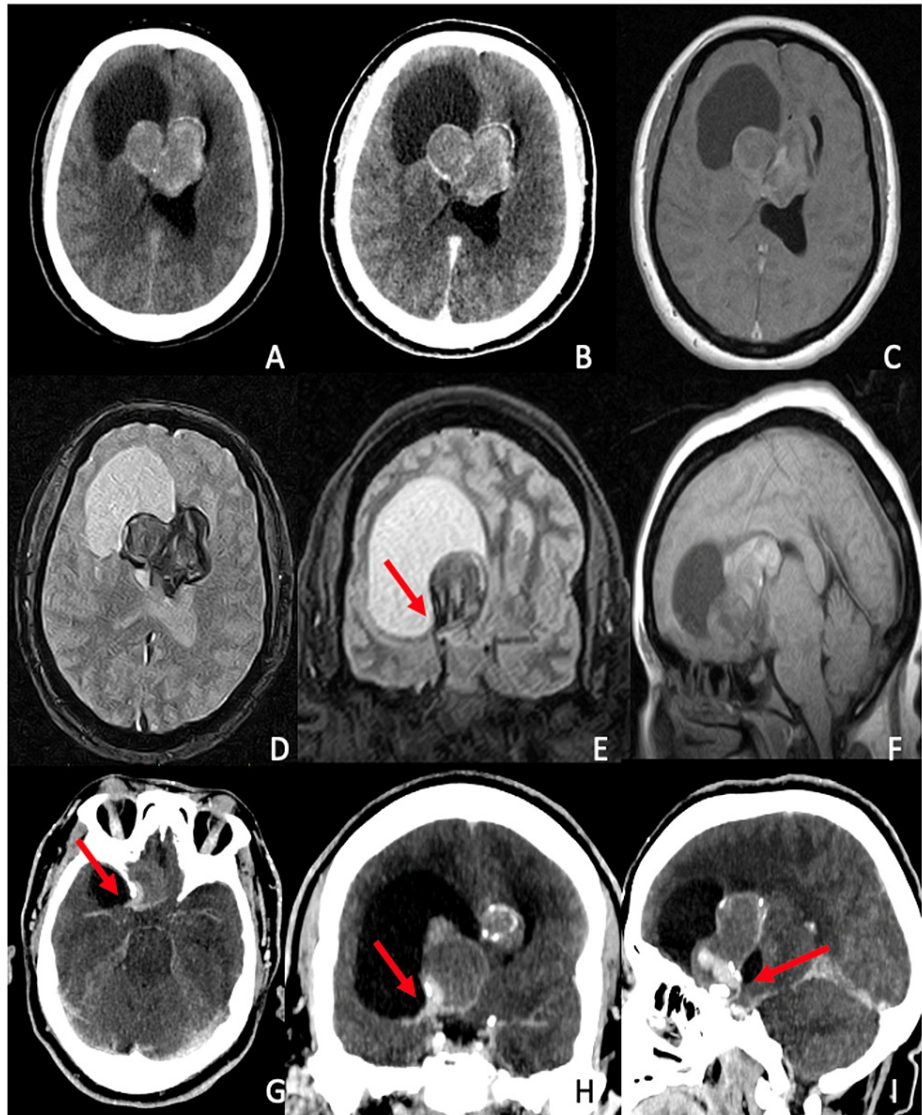

FIGURE 1: Preoperative neuroimaging assessments

Axial section contrast-enhanced CT scan showed a midline mass with peripheral calcifications (A) and heterogeneous contrast enhancement (B). The right frontal cystic lesion appears more hyperintense than the CSF in contrast-enhanced MRI sequences. SWI reconstructions evidenced flow voids (D, E) and heterogeneous contrast enhancement is seen on sagittal T1 (F). Prior radiology report suggested craniopharyngioma. A contrast-enhanced CT scan adjusted for arterial vessels evidenced a hyperdense pattern within the tumoral wall, suggesting luminal patency (red arrows) from the right ICA bifurcation

CT: computed tomography; CSF: cerebrospinal fluid; MRI: magnetic resonance imaging; SWI: susceptibility-weighted imaging; ICA: internal carotid artery

An extended pterional incision and a fronto-orbitozygomatic approach for the resection of the tumor were planned. A middle frontal gyrus corticectomy was performed to gain access to the cystic portion of the lesion. The cyst was drained, and a firm lesion was noticed in the cavity. The lesion was dissected and debulked for volume reduction and easier maneuverability.

During debulking, high-volume arterial bleeding ensued. It was not compatible with the injury of a standard, tumor-related artery. Hemostasis was achieved with fibrillar hemostats and irrigation under pressure. The high-flow bleeding and location of the lesion raised suspicion for an aneurysmal lesion of the internal carotid artery (ICA). The Sylvian fissure was dissected immediately, and an aneurysmal neck was encountered at the ICA bifurcation (Figure 2) and clipped with a 13-mm straight clip, ceasing the arterial flow. Thrombectomy was performed. The event lasted for approximately 15 minutes and caused momentary hemodynamic instability that was corrected shortly after clipping.

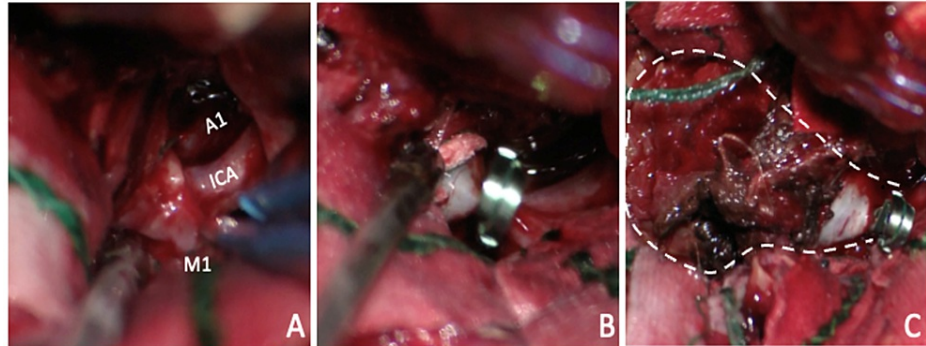


FIGURE 2: Intraoperative microscopic view of the lesion dissection

Microscopic view of the aneurysm neck dissection (A) and clipping (B). Wide exposure, neck, and opened dome with thrombus and hemostats inside (traced line) and final clip position (C)

Discussion

Giant intracranial aneurysms are arterial malformations greater than 2.5 cm that represent only 2-5% of all intracranial aneurysms [6,9]. They usually present between the fifth and the seventh decade of life, with a slight predominance among the female sex. Giant aneurysms may impose significant challenges in surgical management. Due to their increased size, symptoms associated with mass effect may be seen with unruptured aneurysms, related to their location. Hence, they should be considered in the differential diagnosis of expansion lesions of the CNS [1,6].

As expansion lesions, giant aneurysms might present cystic, degenerated, heterogeneous, lobulated, and calcified lesions when unruptured [7,8]. Due to the parasellar topography, giant carotid aneurysms might show sufficient mass effects to cause pituitary and hypothalamic dysfunction, as seen in this case [4]. There are two reports in the medical literature in which giant aneurysms were previously misdiagnosed as craniopharyngiomas [7,8].

Due to limited resources and the patient being admitted with contrasted imaging suggestive of a tumor, a CT angiogram (CTA) was not performed since it was not deemed essential by the hospital's administration. However, we believe that this type of advanced vascular imaging would have helped diagnose the aneurysm before the surgery.

Conclusions

We reported a case of a giant aneurysm presenting as a parasellar/suprasellar lesion that resembled a craniopharyngioma. Advanced vascular imaging would likely have helped with the proper diagnosis of the lesion. The radiological findings and the unspecific symptom onset point to later diagnoses in these reported cases, with their true natures being unveiled only during intraoperative dissection or during preoperative vascular assessments when available or considered. Although our case was resolved without nefarious consequences, knowing what pathology was being operated on would have allowed for more adequate surgical planning and avoided significant intraoperative hemorrhage and potential harm. We recommend that surgeons increase their efforts in requesting advanced vascular imaging when faced with lesions of the sellar/parasellar regions, as there may be more to them than meets the eye.

Additional Information

Disclosures

Human subjects: Consent was obtained or waived by all participants in this study. **Conflicts of interest:** In compliance with the ICMJE uniform disclosure form, all authors declare the following: **Payment/services info:** All authors have declared that no financial support was received from any organization for the submitted work. **Financial relationships:** All authors have declared that they have no financial relationships at present or within the previous three years with any organizations that might have an

interest in the submitted work. **Other relationships:** All authors have declared that there are no other relationships or activities that could appear to have influenced the submitted work.

References

1. Petrakakis I, Pirayesh A, Krauss JK, Raab P, Hartmann C, Nakamura M: The sellar and suprasellar region: a "hideaway" of rare lesions. Clinical aspects, imaging findings, surgical outcome and comparative analysis. *Clin Neurol Neurosurg*. 2016, 149:154-65. [10.1016/j.clineuro.2016.08.011](https://doi.org/10.1016/j.clineuro.2016.08.011)
2. Honegger J, Tatagiba M: Craniopharyngioma surgery. *Pituitary*. 2008, 11:361-73. [10.1007/s11102-008-0137-z](https://doi.org/10.1007/s11102-008-0137-z)
3. Petito CK, DeGirolami U, Earle KM: Craniopharyngiomas: a clinical and pathological review. *Cancer*. 1976, 37:1944-52. [10.1002/1097-0142\(197604\)37:4<1944::aid-cnrcr2820370446>3.0.co;2-#](https://doi.org/10.1002/1097-0142(197604)37:4<1944::aid-cnrcr2820370446>3.0.co;2-#)
4. Fonseca AL, Souto AA, Domingues F, et al.: Hormonal dysfunction of nonpituitary lesions from midline and perisellar area (Article in Portuguese). *Arq Neuropsiquiatr*. 2001, 59:905-12. [10.1590/s0004-282x2001000600013](https://doi.org/10.1590/s0004-282x2001000600013)
5. Lee IH, Zan E, Bell WR, Burger PC, Sung H, Yousem DM: Craniopharyngiomas : radiological differentiation of two types. *J Korean Neurosurg Soc*. 2016, 59:466-70. [10.3340/jkns.2016.59.5.466](https://doi.org/10.3340/jkns.2016.59.5.466)
6. Choi IS, David C: Giant intracranial aneurysms: development, clinical presentation and treatment. *Eur J Radiol*. 2003, 46:178-94. [10.1016/s0720-048x\(03\)00090-1](https://doi.org/10.1016/s0720-048x(03)00090-1)
7. Smith KA, Kraus GE, Johnson BA, Spetzler RF: Giant posterior communicating artery aneurysm presenting as third ventricle mass with obstructive hydrocephalus. Case report. *J Neurosurg*. 1994, 81:299-303. [10.3171/jns.1994.81.2.0299](https://doi.org/10.3171/jns.1994.81.2.0299)
8. Hongo K, Morota N, Watabe T, Isobe M, Nakagawa H: Giant basilar bifurcation aneurysm presenting as a third ventricular mass with unilateral obstructive hydrocephalus: case report. *J Clin Neurosci*. 2001, 8:51-4. [10.1054/jocn.2000.0730](https://doi.org/10.1054/jocn.2000.0730)
9. Lawton MT, Spetzler RF: Surgical strategies for giant intracranial aneurysms. *Acta Neurochir Suppl*. 1999, 72:141-56. [10.1007/978-3-7091-6377-1_12](https://doi.org/10.1007/978-3-7091-6377-1_12)