

# Efficacy of corticosteroid ductal irrigation in acute salivary gland inflammation induced in a rat model

Chena Lee<sup>1</sup>, Ari Lee<sup>1</sup>, Hak-Sun Kim<sup>1</sup>, Yoon Joo Choi<sup>1</sup>, Kug Jin Jeon<sup>1</sup>, Sang-Sun Han<sup>1,\*</sup>

<sup>1</sup>Department of Oral and Maxillofacial Radiology, Yonsei University College of Dentistry, Seoul, Korea

## ABSTRACT

**Purpose:** This study aimed to compare the therapeutic effects of corticosteroid irrigations and normal saline irrigations in the early inflammatory state of the salivary gland.

**Materials and Methods:** Adult male Wistar rats were divided into experimental (n=6) and control (n=3) groups. Inflammation was induced in the experimental subjects on both sides of the submandibular gland with ligation. After 14 days, both sides of the glands were de-ligated and retroductal irrigation using saline (n=3) and a corticosteroid (n=3) was performed on the left sides only. The controls (n=3) were used to normalize the gland state for the effects of diet and aging. Magnetic resonance imaging was performed to confirm inflammation and post-irrigation gland recovery by measuring relative signal intensity (SI). The glands were excised for histological examination.

**Results:** All experimental animals showed inflamed glands with increased SI and subsequent recovery of the gland with decreased SI to varying degrees. The SI of the controls showed no significant changes during the overall period. The mean SI change of the irrigated gland was higher than that of the non-irrigated side, without a significant difference. The corticosteroid-irrigated glands showed a greater change in SI than that of the saline-irrigated glands. Histology revealed that inflammation was not observed in most of the irrigated glands, while mild to moderate quantities inflammatory cells were found in non-irrigated glands.

**Conclusion:** Corticosteroid irrigation mitigated the early stages of salivary gland inflammation more effectively than normal saline. (*Imaging Sci Dent* 2022; 52: 61-6)

**KEY WORDS:** Salivary Glands; Sialadenitis; Therapeutic Irrigation; Corticosteroid; Models, Animal

## Introduction

Ductal irrigation is a conservative treatment for chronic obstructive salivary gland inflammation.<sup>1,2</sup> Transient but frequent salivary gland obstruction interferes with the smooth secretion of saliva, eventually causing recurrent and chronic sialadenitis with sialodochitis.<sup>3</sup> During this pathologic process, microorganism and enzymatic protein debris in the saliva precipitate obstruct and inhibit active saliva secretion.<sup>4</sup> Ductal irrigation is an effective form of conservative treatment, as it physically removes intraductal residues

and dilutes inflammatory substances.<sup>2,3</sup>

Recent studies have reported that retroductal drug or gene therapy approaches showed effective distribution into the gland, helping to protect or recover its function.<sup>5-7</sup> Varghese et al.<sup>8</sup> reported that the ductal drug delivery approach had a significant impact on gland hypofunction compared to systemic drug administration. Ductal irrigation is effective in physically removing sediments and can also be considered effective as a means for pharmacological treatment in selected cases. Therefore, further studies are needed to identify the appropriate indications that respond well to ductal irrigation with drug application.

Systemic administration of a drug is currently performed at the initial stage of gland inflammation, although application of the drug directly to the salivary gland would be an effective way to control local inflammation.<sup>9</sup> In particular, corticosteroids are known to be effective in controlling

This work was supported by a National Research Foundation of Korea (NRF) grant funded by the Korean government (MSIT) (grant number: 2020R1F1A1073956).

Received August 12, 2021; Revised September 25, 2021; Accepted October 4, 2021  
Published online November 18, 2021

\*Correspondence to : Prof. Sang-Sun Han

Department of Oral and Maxillofacial Radiology, Yonsei University, College of Dentistry, 50-1 Yonsei-ro, Seodaemun-gu, Seoul 03722, Korea  
(Tel) 82-2-2228-8843, E-mail) sshan@yuhs.ac

Copyright © 2022 by Korean Academy of Oral and Maxillofacial Radiology

This is an Open Access article distributed under the terms of the Creative Commons Attribution Non-Commercial License (<http://creativecommons.org/licenses/by-nc/3.0>) which permits unrestricted non-commercial use, distribution, and reproduction in any medium, provided the original work is properly cited.

Imaging Science in Dentistry · pISSN 2233-7822 eISSN 2233-7830

inflammation and are widely used in oral gargling solutions.<sup>10,11</sup>

In this study, the therapeutic effect of corticosteroids was compared with that of normal saline in the early stage of gland inflammation induced in an animal model to elucidate whether ductal irrigation demonstrated therapeutic effects as well as cleansing effects.

## Material and Methods

### Animal care

This study was approved by the Institutional Animal Care and Use Committee of Yonsei University Health System (No. 2020-0151) and followed the guidelines of the Laboratory Animal Unit, Yonsei Biomedical Research Institute, Yonsei University College of Medicine, and Animal Research Reporting In Vivo Experiments guidelines.

Nine adult male Wistar strain rats (350-400 g) were obtained from a breeder (Orientbio Inc., Seongnam, Korea). After a week of acclimatization, the animals were divided into experimental (n=6) and control (n=3) groups. In the experimental animals, bilateral submandibular gland inflammation was induced by ductal ligation as referenced in previous studies.<sup>12,13</sup> After de-ligation, retroductal irrigation was performed on a single side of the inflamed gland. The control group was used to normalize any changes in the salivary gland due to aging or diet. The overall timeline of the experiment is shown in Figure 1. During the experiment, 1 animal in the experimental group (rat 2) died, leaving 5 rats in that group.

### Surgical procedure

The animals were anesthetized with ketamine (0.75 mL/kg) and xylazine (0.15 mg/kg) through an intraperitoneal in-

jection. A small incision was made on the neck area, exposing the main duct of the submandibular gland on both sides. The hilum area of each duct was ligated with 5-0 black silk (Ailee Co., Ltd., Busan, Korea). The overall surgical procedure was conducted under aseptic conditions to reduce the risk of infection, and meloxicam (2 mg/kg; Metacam, Boehringer Ingelheim, Germany) was administered after the surgical procedure for pain relief. On the 14th day, both ligations were removed through a small incision on the neck, following the same procedure as described above.

### Intraoral duct irrigation

On the day following ligation removal, duct irrigation was performed via the orifice on the floor of the mouth. Ductal irrigation was then conducted on the left side of the submandibular gland, wherein 2 animals were administered saline solution and the other 3 were irrigated with 6% corticosteroid (Solondo; Yuhan Corp., Seoul, Korea), a solution used for oral gargling.

The irrigation procedure was performed as previously reported.<sup>1,6</sup> Orifice exploration and duct enlargement were performed using a #15 endodontic finger spreader, and an endodontic 27-gauge irrigation needle with a vent was placed into the enlarged duct, gradually pushing 270-300 µL of the solution into the duct.<sup>6</sup> Filling of the duct with solution was maintained for 1 minute and the needle tip was removed to allow the solution to evacuate. This single irrigation procedure was repeated 3 times, and the overall procedure was performed 3 times at 2-day intervals.

### Imaging and histology

Magnetic resonance imaging (MRI) examinations were performed for all groups at the baseline (day 0) and post-treatment (day 28) stages of the experiment. For the experi-

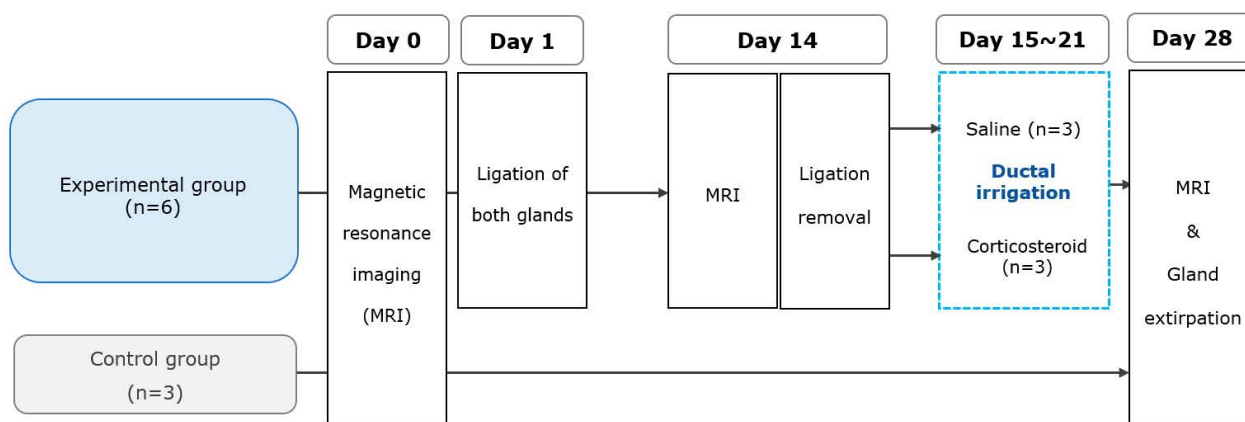
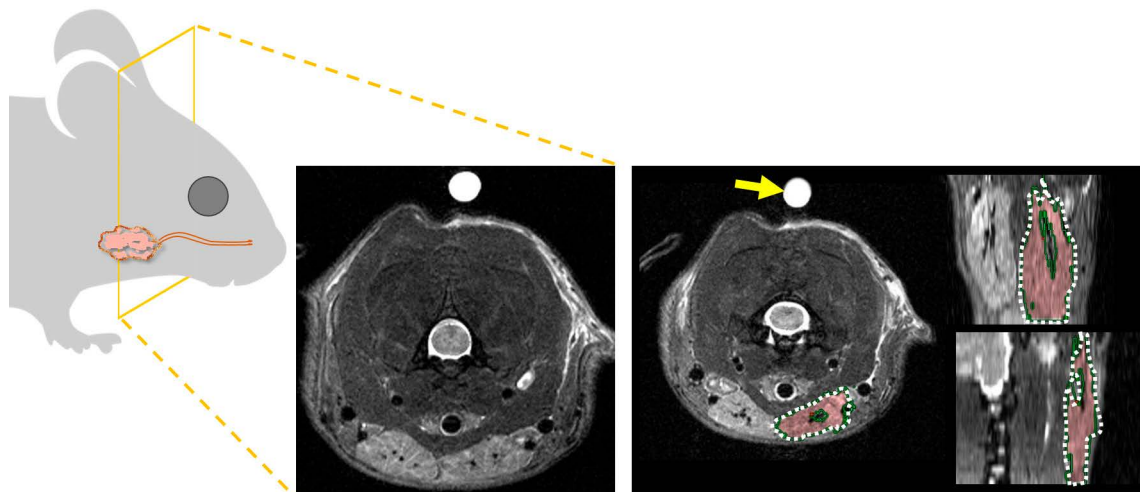


Fig. 1. Schematic view of the overall experimental timeline.



**Fig. 2.** Volume region of interest selection on T2-weighted magnetic resonance imaging on an axial section referencing the coronal and sagittal sections. The measured signal intensity (SI) is divided by the SI of pure water (arrow) examined simultaneously in each animal.

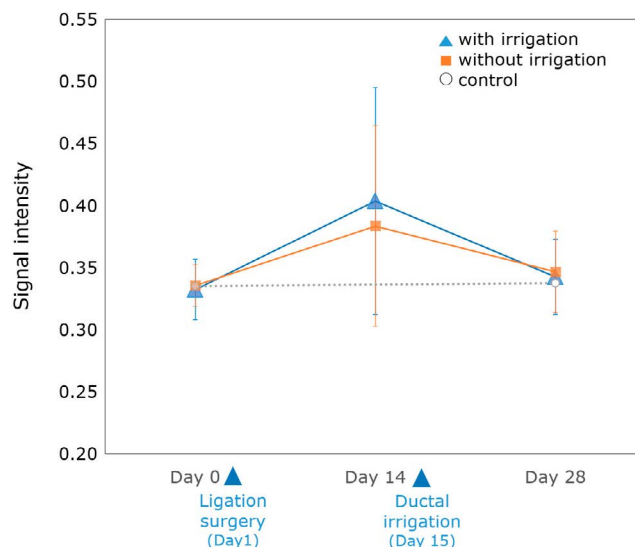
mental group, the examination was performed after ligation surgery (day 14) to confirm the inflammation of the gland (Fig. 1).

For inflammation assessment, T2-weighted imaging was performed as described in a previous study,<sup>12</sup> wherein submandibular gland imaging was performed using a 9.4 T Bruker Biospin (Billerica, MA, USA) as follows: fast-spin echo T2-weighted images (FSE T2WI, TR: 2750 ms, TE: 33 ms, FA: 180°, field of view: 40 × 40 mm<sup>2</sup>). Additionally, a rod containing pure water was included in the image as a reference.<sup>12,14</sup> The volume region of interest (VROI) was drawn on the submandibular gland border using a Zetta PACS viewer (Taeyoung Soft, Anyang, Korea). The SI value obtained from the VROI was divided by the SI of pure water to obtain the calibrated SI (Fig. 2).

Euthanasia was performed under 100% carbon dioxide gas and both submandibular glands were harvested. Each gland was fixed in formalin solution and stained with hematoxylin and eosin. The degree of inflammatory cell infiltration within the gland structures was observed under a light microscope (Olympus BX51; Olympus Co., Ltd., Tokyo, Japan) and a slide scanner (Panoramic 250 Flash III Scanner; 3DHISTECH Kft., Budapest, Hungary).

### Statistical analysis

The average SI values were compared among the baseline (day 0), inflamed (day 14), and post-treatment (day 28) stages. The SI change (SI of day 28 minus SI of day 14) after irrigation was compared between the irrigated and non-irrigated glands as well as saline and corticosteroid irrigated glands using the Wilcoxon test, with a 95% con-

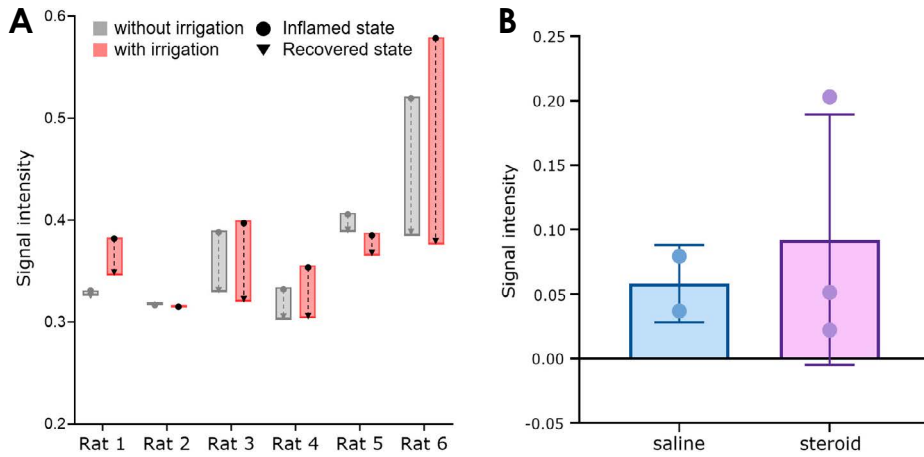


**Fig. 3.** Increasing signal intensity after surgery indicates gland inflammation, whereas decreasing values after the irrigation procedure indicate recovery of the gland.

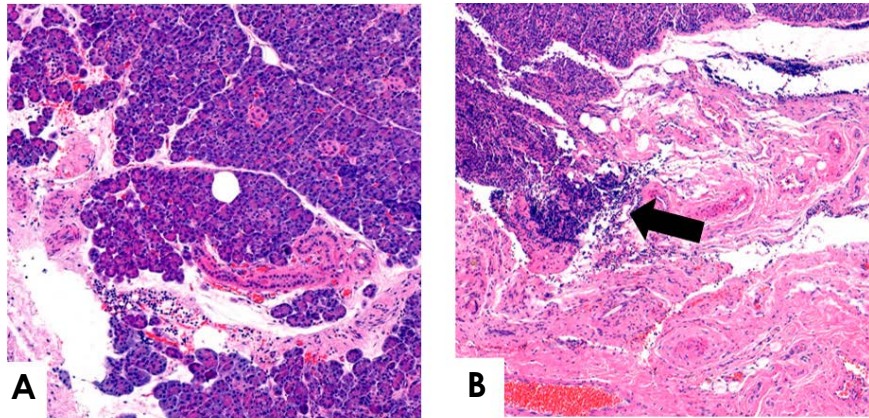
fidence level. Statistical analysis was performed using GraphPad Prism 8.4.2 (GraphPad Software Inc., San Diego, CA, USA).

### Results

The experimental subjects showed inflammation of the submandibular gland with increased SI after ligation (day 15). The mean SI decreased to the level of the onset state 28 days after ligation surgery (recovery), regardless of irrigation type. Meanwhile, the glands of controls showed no



**Fig. 4.** Signal intensity (SI) changes according to the individual animal (A) and irrigation solution (B) group. A. The SI decreases from the inflamed state (after ligation) to the recovery state (after irrigation) for all animals. B. The mean SI change of the corticosteroid irrigated glands is larger than that of saline irrigated glands.



		Rat 1	Rat 3	Rat 4	Rat 5	Rat 6	Rat 7~9 (control)
Gland	without irrigation	(-)	(+)	(+)	(-)	(++)	(-)
	with irrigation	(-)	(-)	(+)	(-)	(-)	

**Fig. 5.** A. Histologic analysis of the salivary gland in irrigated glands shows no significant inflammatory cells except for 1 gland sample (rat 4). B. Focal inflammatory cells are present in the non-irrigated glands (B). Arrow, inflammatory cells (H&E stain, original magnification  $\times 200$ ). (+): presence of inflammatory cells, (-): absence of inflammatory cells.

significant changes. The mean SI difference between the inflamed and recovered states was higher in the irrigated gland than non-irrigated gland. However, there was no significant difference (Fig. 3).

One subject irrigated with saline solution died before the experiment ended. All experimental subjects showed a higher level of SI decrease for the irrigated gland than that for its non-irritated counterpart, except the subject

where SI measurement could not be performed due to death before MRI acquisition. Specifically, the SI changed from an inflamed state to a recovered state, varying according to the individual (Fig. 4A). When the saline-irrigated glands were compared with the corticosteroid-irrigated glands, the corticosteroid-irrigated glands showed a greater decrease in the mean SI (0.0921 and 0.0581, respectively; Fig. 4B).

The imaging findings were consistent with the histological findings. Inflammation was only observed in 1 of the irrigated glands (rat 4). In contrast, the three non-irrigated glands showed mild to intermediate levels of inflammatory cells remaining within the tissue (Fig. 5).

## Discussion

Previous studies on the effects of using drug solutions for ductal irrigation reported inconsistent results.<sup>5,9,15</sup> Antonides et al.<sup>5</sup> reported that irrigation with an antibiotic solution did not show a superior effect over saline irrigation. Another study showed that retroductal application of corticosteroids was effective in patients with chronic recurrent sialadenitis and Sjögren syndrome.<sup>15-17</sup> In contrast, Jokela et al.<sup>16</sup> reported that steroid irrigation did not provide additional benefit compared to saline irrigation; however, they conducted single-dose steroid injections, which were not sufficient to determine the efficacy of the drug.<sup>16</sup> Another variable to consider would be the timing of the intervention, since inflammatory gland changes vary widely depending on the duration or severity of disease.

It is difficult to study the effect of drug irrigation on inflamed salivary glands because of variations in the onset, duration, and frequency of inflammation among individual patients. Thus, in this study, an animal model was used to control the pathologic status of sialadenitis. The aim of this study was to demonstrate the therapeutic effect of corticosteroid irrigation on early-stage gland inflammation. As a result, for the first time, it was possible to confirm that the application of corticosteroid drugs in the early-stage inflammatory gland was more effective in addressing inflammation than normal saline. A recent study investigated the efficacy of steroid irrigation, considering the causes of inflammation and the pathology of the overall gland.<sup>17</sup> The authors concluded that steroid irrigation helped to reduce recurrence in the long term compared to the saline group.

It has been reported that corticosteroid irrigation was effective in patients with Sjögren syndrome.<sup>15</sup> In that study, patients with early-stage Sjögren syndrome showed a significantly favorable response to irrigation. Chen et al.<sup>18</sup> also reported that over 60% of Sjögren syndrome patients showed a positive response to retroductal irrigation with corticosteroids. Sjögren syndrome primarily causes inflammation of the salivary and lacrimal glands.<sup>19</sup> As corticosteroids are widely used in the treatment of oral inflammatory lesions,<sup>10</sup> it can be assumed that corticosteroid irrigation would be effective for the early stages of sialadenitis, as this study and several others have shown.<sup>20</sup>

In the present study, the glands without irrigation consequently showed remission of inflammation, although to a lesser degree than the glands with irrigation. Moreover, the subject believed to have high immune potency showed a comparable decrease of inflammation in the non-irrigated glands. This was probably because the induced sialadenitis was transient. The salivary gland in rats has a high potential for recovery, even after severe atrophy.<sup>13</sup> In the current study, follow-up imaging was done 1 week after the irrigation, and this period seemed to be sufficient for the non-irrigated gland to recover by itself. Therefore, it is necessary to obtain multiple images, within shorter periods, to evaluate the efficacy of irrigation for the rapid reduction of inflammation. Further studies are also needed to evaluate the therapeutic effect on chronic inflammation with permanent structural changes in the gland.

The current animal experiment showed that both the effectiveness of ductal irrigation and the inflammatory response of the salivary gland were highly variable among individuals. This widely varied response was a major factor that rendered analysis of the treatment response in salivary gland inflammation difficult. Thus, further research should be performed on a larger sample to compensate for individual differences.

Retroductal irrigation of the salivary gland was effective in reducing inflammation of the gland. In addition, corticosteroid irrigation contributed more to remission in the early stages of salivary gland inflammation than normal saline irrigation, suggesting a therapeutic effect of the drug.

**Conflicts of Interest:** None

## References

1. Lee C, Kim JE, Huh KH, Yi WJ, Heo MS, Lee SS, et al. Therapeutic effect of intraductal irrigation of the salivary gland: a technical report. *Imaging Sci Dent* 2017; 47: 123-7.
2. Kim JE, Lee SS, Lee C, Huh KH, Yi WJ, Heo MS, et al. Therapeutic effect of intraductal saline irrigation in chronic obstructive sialadenitis. *BMC Oral Health* 2020; 20: 86.
3. Wilson KF, Meier JD, Ward PD. Salivary gland disorders. *Am Fam Physician* 2014; 89: 882-8.
4. Harrison JD. Causes, natural history, and incidence of salivary stones and obstructions. *Otolaryngol Clin North Am* 2019; 42: 927-47.
5. Antoniadis D, Harrison JD, Epivatianos A, Papanayotou P. Treatment of chronic sialadenitis by intraductal penicillin or saline. *J Oral Maxillofac Surg* 2004; 62: 431-4.
6. Nair RP, Zheng C, Sunavala-Dossabhoj G. Retroductal submandibular gland instillation and localized fractionated irradiation in a rat model of salivary hypofunction. *J Vis Exp* 2016; 110: 53785.

7. Varghese JJ, Schmale IL, Wang Y, Hansen ME, Newlands SD, Ovitt CE, et al. Retroductal nanoparticle injection to the murine submandibular gland. *J Vis Exp* 2018; 135: 57521.
8. Varghese JJ, Schmale IL, Mickelsen D, Hansen ME, Newlands SD, Benoit DS, et al. Localized delivery of amifostine enhances salivary gland radioprotection. *J Dent Res* 2018; 97: 1252-9.
9. Nahlieli O, Bar T, Shacham R, Eliav E, Hecht-Nakar L. Management of chronic recurrent parotitis: current therapy. *J Oral Maxillofac Surg* 2004; 62: 1150-5.
10. Mehdipour M, Zenouz AT. Role of corticosteroids in oral lesions. In: Magdeldin S. *State of the art of therapeutic endocrinology*. London: IntechOpen; 2012. p. 87-120.
11. Barnes PJ, Adcock I. Anti-inflammatory actions of steroids: molecular mechanisms. *Trends Pharmacol Sci* 1993; 14: 436-41.
12. Shimizu M, Sekine N, Nishimura K, Tokumori K, Saitoh M, Kanda S. Magnetic resonance imaging of experimentally-induced sialadenitis in rat submandibular glands. *Dentomaxillofac Radiol* 1999; 28: 330-7.
13. Osailan SM, Proctor GB, Carpenter GH, Paterson KL, McGurk M. Recovery of rat submandibular salivary gland function following removal of obstruction: a sialometrical and sialochemical study. *Int J Exp Pathol* 2006; 87: 411-23.
14. Song D, Shujaat S, Zhao R, Huang Y, Shaheen E, Van Dessel J, et al. In vivo quantification of mandibular bone remodeling and vascular changes in a Wistar rat model: A novel HR-MRI and micro-CT fusion technique. *Imaging Sci Dent* 2020; 50: 199-208.
15. Izumi M, Eguchi K, Nakamura H, Takagi Y, Kawabe Y, Nakamura T. Corticosteroid irrigation of parotid gland for treatment of xerostomia in patients with Sjögren's syndrome. *Ann Rheum Dis* 1998; 57: 464-9.
16. Jokela J, Haapaniemi A, Mäkitie A, Saarinen R. Sialendoscopy in treatment of adult chronic recurrent parotitis without sialolithiasis. *Eur Arch Otorhinolaryngol* 2018; 275: 775-81.
17. Lele SJ, Hamiter M, Fourrier TL, Nathan CA. Sialendoscopy with intraductal steroid irrigation in patients with sialadenitis without sialoliths. *Ear Nose Throat J* 2019; 98: 291-4.
18. Chen YC, Dang LH, Chen LC, Chang CC, Han DY, Hsu CH, et al. Office-based salivary gland ductal irrigation in patients with chronic sialoadenitis: a preliminary study. *J Formos Med Assoc* 2021; 120: 318-26.
19. Brito-Zerón P, Baldini C, Bootsma H, Bowman SJ, Jonsson R, Mariette X, et al. Sjögren syndrome. *Nat Rev Dis Primers* 2016; 2: 16047.
20. Jonsson R, Kroneld U, Bäckman K, Magnusson B, Tarkowski A. Progression of sialadenitis in Sjögren's syndrome. *Br J Rheumatol* 1993; 32: 578-81.