

Received: 2021.02.23

Accepted: 2021.09.21

Available online: 2021.10.12

Published: 2021.11.12

# Concurrent Breast Carcinoma and Follicular Lymphoma: A Case Series

## Authors' Contribution:

Study Design A  
Data Collection B  
Statistical Analysis C  
Data Interpretation D  
Manuscript Preparation E  
Literature Search F  
Funds Collection G

EF 1 **Tabinda Saleem**EF 1,2 **Kaihong Mi**F 1 **Rajan Pathak**EF 1 **Kolsoum Yari**ADEF 1,2 **Kit Lu**

1 Department of Internal Medicine, University of Pittsburgh Medical Center (UPMC) Pinnacle, Harrisburg, PA, USA

2 Department of Hematology Oncology, University of Pittsburgh Medical Center (UPMC) Hillman Cancer Center, Harrisburg, PA, USA

**Corresponding Author:** Kit Lu, e-mail: [luky@upmc.edu](mailto:luky@upmc.edu)**Financial support:** None declared**Conflict of interest:** None declared**Case series****Patients:** Female, 72-year-old • Female, 60-year-old • Female, 74-year-old**Final Diagnosis:** Concurrent breast adenocarcinoma and follicular lymphoma**Symptoms:** Lymphadenopathy**Medication:** —**Clinical Procedure:** —**Specialty:** Oncology**Objective:** Rare coexistence of disease or pathology**Background:** The incidence of multiple primaries in cancer patients is 2-17%. However, the synchronous co-occurrence of adenocarcinoma of the breast and follicular lymphoma is rare.**Case Reports:** We describe a case series of 3 post-menopausal women who presented to our institute with a breast lump. On further investigations, 2 of them had invasive ductal carcinoma and 1 had invasive lobular carcinoma of the breast. All 3 cancers were estrogen/progesterone receptor (ER/PR)-positive and human epidermal growth factor receptor 2 (HER-2)-negative. During the staging PET scans, all 3 patients had increased FDG uptake in axillary, mesenteric, and inguinal lymph nodes, respectively, raising concerns for metastatic disease. However, subsequent biopsies revealed them as follicular lymphomas occurring as a second concurrent primary malignancy. All patients underwent radical mastectomies with sentinel lymph node dissection followed by chemotherapy and hormonal therapy. Most of the lymphomas were low grade, which the oncologist closely followed.**Conclusions:** Very few cases of breast cancer and follicular lymphoma co-occur; this is not limited to the axillary lymph nodes and can occur in any part of the lymphatic chain. Regional lymph node enlargement detected on examination or imaging does not always indicate metastasis. A high index of suspicion is needed followed by lymph node biopsy to rule out any second primary malignancy.**Keywords:** Breast Neoplasms • Lymphoma, Follicular • Neoplasms, Second Primary • AdenocarcinomaFull-text PDF: <https://www.amjcaserep.com/abstract/index/idArt/931772>

2206



3



6



18



## Background

Multiple synchronous or metachronous malignant primaries are known entities that occur in 2-17% of cancer cases [1-4]. However, the synchronous breast cancer and lymphomas is rare and can pose a significant diagnostic and management challenge to the treating physicians.

Herein, we report a series of 3 patients with synchronous breast adenocarcinoma and follicular lymphoma, their management, and outcome.

## Case Reports

Three patients presented to our institute over 12 months with synchronous breast adenocarcinoma and follicular lymphoma. Two patients were diagnosed with invasive ductal carcinoma and 1 with invasive lobular carcinoma of the breast. Coincidentally, all 3 patients were found to have follicular lymphoma of different anatomical sites during their staging evaluation. A detailed review of their presentation is summarized in **Table 1** and further discussed below.

### Case 1

A 72-year-old post-menopausal woman with no family history of breast carcinoma initially presented with a self-noticed right breast lump. A bilateral diagnostic mammogram revealed a high-density, irregularly shaped mass with spiculated margins in the right breast's outer region. Targeted bilateral ultrasound (US) confirmed the mass at 9 o'clock position, measuring 2.4×2.1×2.8 cm, BI-RADS 5.

Laboratory evaluation was unremarkable. Ultrasound-guided right breast biopsy and right axillary lymph node biopsy revealed invasive lobular carcinoma of the right breast, which was estrogen receptor (ER)- and progesterone receptor (PR)-positive (95/95%) and human epidermal growth factor receptor 2 (HER-2) receptor-negative.

The patient had enlarged bilateral superficial inguinal lymph nodes on staging computed tomography (CT) chest/abdomen/pelvis scans. These nodes had increased radiotracer uptake on the positron emission tomography (PET)/CT scan (**Figure 1**).

Biopsy of the right inguinal lymph node confirmed follicular lymphoma (FL). Immuno-staining revealed that AE1/3 was negative and CD3, CD5, and CD20 were positive. These cells were also positive for CD23, BCL-6, CD10, and BCL-2 and negative for cyclin D1, with a low proliferation index (10~20% by Ki-67 on average, with rare follicles showing 40%). CD23 additionally highlighted a residual follicular dendritic meshwork.

Bone marrow aspiration and core bone biopsy did not show any malignant process (**Figure 2**).

Given her limited disease and asymptomatic nature, it was decided to treat her stage IIIA breast cancer first. She underwent right modified radical mastectomy followed by chemotherapy with Docetaxel and cyclophosphamide. She was closely followed for her grade 1 follicular lymphoma by the hematologist-oncologist.

### Case 2

A 60-year-old post-menopausal woman presented with a self-noticed right palpable breast mass. She had a positive family history of breast, colon, lung, and esophageal cancers, all on the paternal side. A mammogram revealed a mass in the right breast's upper outer quadrant, corresponding to palpable mass on the examination and suspicious lymph nodes in the right axilla. Breast US revealed an irregular mass in the 10 o'clock position of the right breast that measured 3.8×3.0×3.0 cm, BI-RADS 5. Several lymph nodes in the right axilla were also detected.

Biopsy of the right breast and right axillary LN revealed a grade 3 invasive ductal carcinoma that was ER/PR-positive (90/90%) and HER-2-negative (2+). Biopsy of the right axillary LN was positive for metastatic disease. On genetic testing, she was positive for a variant of uncertain significance in the MSH6 gene on BRCA ½ analysis.

Staging CT of the abdomen/pelvis showed no solid organ metastasis in the abdomen or pelvis. However, it revealed multiple enlarged abdominal mesenteric lymph nodes within the left mid-abdomen, left lower quadrant, and lower abdomen extending into the upper pelvis, and the mesenteric fat had a misty appearance. The size and distribution of the lymph nodes were greater than expected. There was also enlargement of the left para-aortic lymph node, with an increased number of smaller retroperitoneal lymph nodes and nonenlarged lymph nodes within the posterior mediastinum within the lower left chest. These findings were highly suspicious for a second primary malignancy in the abdomen, likely a lymphoma (**Figure 3**).

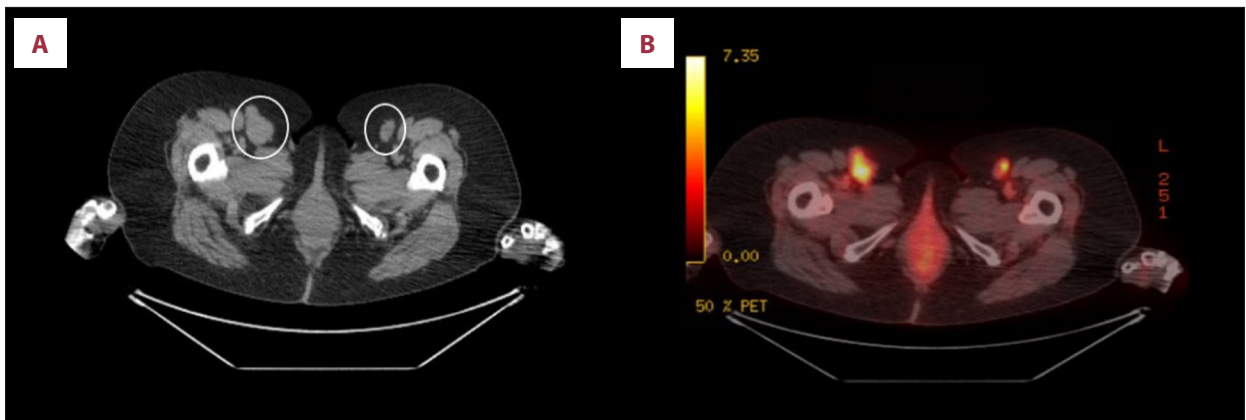
Biopsy of the abdominal mesenteric lymph node suggested a follicular lymphoma that was low grade (Gr 1-2) with high proliferation index by Ki-67 (70%), FLIPI score 2, low-risk category risk, radiographically stage 3, negative bone marrow biopsies, with normal flow cytometry (**Figure 4**).

In her case, although pathologically she was grade 1-2, the high proliferation index (>70%) was anticipated to behave more like grade 3 FL. It was recommended to treat her lymphoma. However, given low cure rates and asymptomatic nature, she initially proceeded with her stage IIB breast cancer

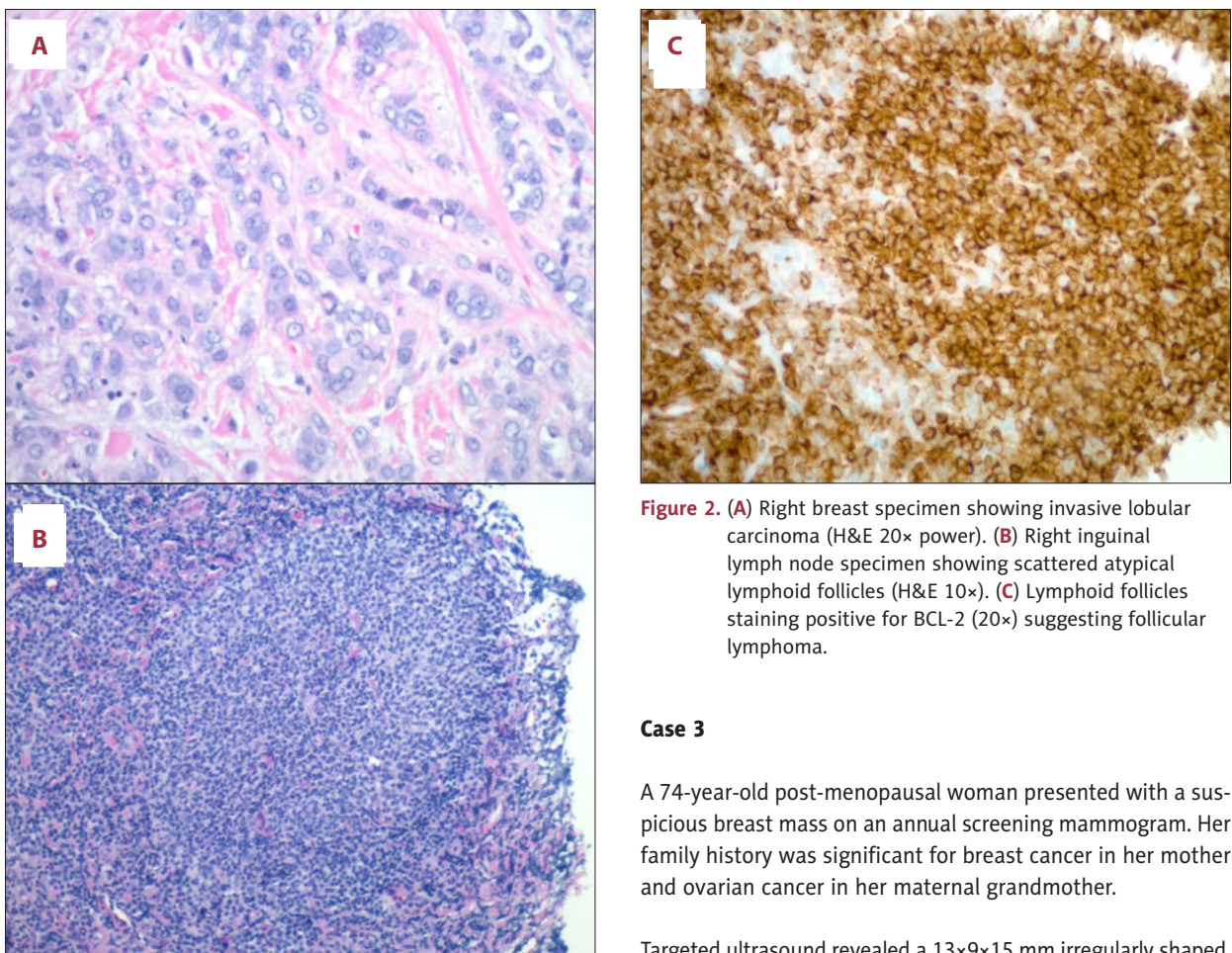
**Table 1.** Case descriptions.

	Case 1	Case 2	Case 3
Case description	72-year-old female with self-noticed right breast lump	60-year-old female with self-noticed right palpable breast mass	74-year-old female with mammographically detected left breast mass
Examination/imaging findings	High density irregular mass with spiculated margins in right breast at 9 o'clock position; BI-RADS 5	Irregular mass in right breast at 10 o'clock position, 3.8×3.0×3.0 cm; BI-RADS 5 with multiple suspicious lymph nodes in the right axilla	13×9×15 mm irregularly shaped, hypoechoic mass with angular margins in the left breast's at 1 o'clock position. BI-RADS 4
Breast pathology	Invasive lobular carcinoma of the right breast, ER/PR+ (95/95%) and HER2 -	Invasive ductal carcinoma, ER/PR+ (90/90%) and HER2-. Positive right axillary LN biopsy	Invasive ductal carcinoma, ER/PR+ (99/95%) and HER2-
Stage breast	Stage IIIA (pT2pN3cM0) 30 mm focus, 19/22 LN, +LVI, +PNI, no DLI, grade 2 invasive lobular carcinoma	Stage IIB (pT2pN2acM0-- 35 mm, 5/12 LN, LVI present, focal angiolymphatic invasion, grade 3 invasive ductal carcinoma metastasis to axillary LN	Multifocal Stage IB (pT1CpN2acM0--2 foci- 12 mm & 6mm, grade 2, 5/6 LN (3 macro/2 micros), LVI present, no PNI, grade 2 invasive ductal carcinoma
CT/PET findings indicative of second primary malignancy	Bilateral inguinal lymph node with increased FDG activity more prominent on the right than left	FDG activity in the thoracic inlet, anterior mediastinum, throughout the root of the mesentery and retroperitoneum	Multiple non-specific uptakes
Lymph node biopsy	Right inguinal lymph node+follicular lymphoma. Immuno-stains - for AE1/3. + for CD3, CD5, CD20, CD23, BCL-6, CD10, and BCL-2, and negative for cyclin D1, with a low proliferation index (10~20% by Ki67 on average, with rare follicles showing 40%)	Abdominal mesenteric lymph node+follicular lymphoma, low grade (Gr1-2) with high proliferation index by Ki67 (70%)	Follicular neoplasia in situ in two of her left dissected axillary LN. Immunoperoxidase staining within occasional follicles displayed BCL2 expression with co-expression of CD10. CD20 and CD3 reveal normal antigenic expression
FLIPI stage	Stage 2 (intermediate risk)	Stage 2 (intermediate risk)	Stage 1 (low risk)
Management	Right modified radical mastectomy followed by chemotherapy. Close surveillance for her grade 1 follicular lymphoma	Right mastectomy and right axillary LN dissection, followed by adjuvant chemotherapy and radiotherapy. Patient remained on close surveillance with aim to re-evaluate her grade 2 follicular in future for subsequent chemotherapy	Left mastectomy and complete left axillary dissection followed by chemotherapy and radiotherapy. 6 months surveillance for follicular carcinoma in situ

ER – estrogen receptor; PR – progesterone receptor; LVI – lymphovascular invasion; PNI – perineural invasion; DNI – dermal lymphatic invasion; LN – lymph node.



**Figure 1.** CT chest/abdomen/pelvis with PET axial views showing enlarged bilateral inguinal lymph nodes with right approximately 3.2 cm and left 2.6 cm in diameter (A) with corresponding increased FDG activity on the PET scan, right more prominent than the left (B).



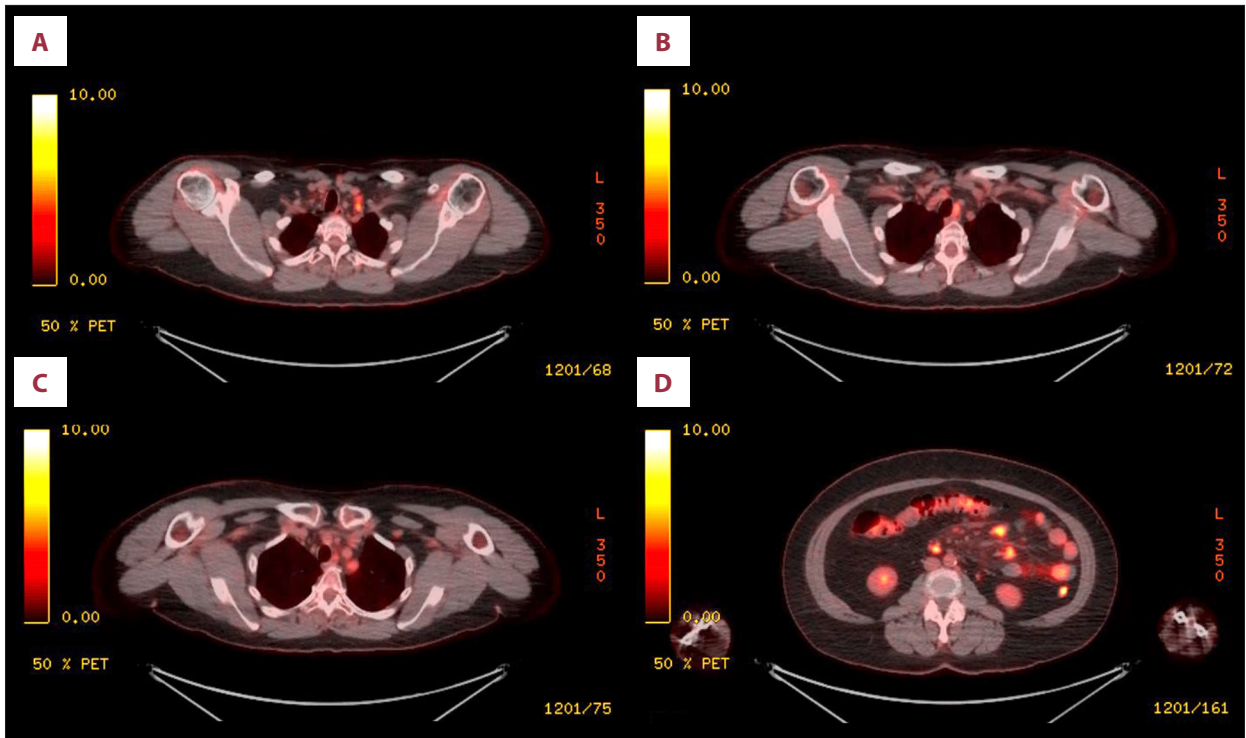
**Figure 2.** (A) Right breast specimen showing invasive lobular carcinoma (H&E 20× power). (B) Right inguinal lymph node specimen showing scattered atypical lymphoid follicles (H&E 10×). (C) Lymphoid follicles staining positive for BCL-2 (20×) suggesting follicular lymphoma.

### Case 3

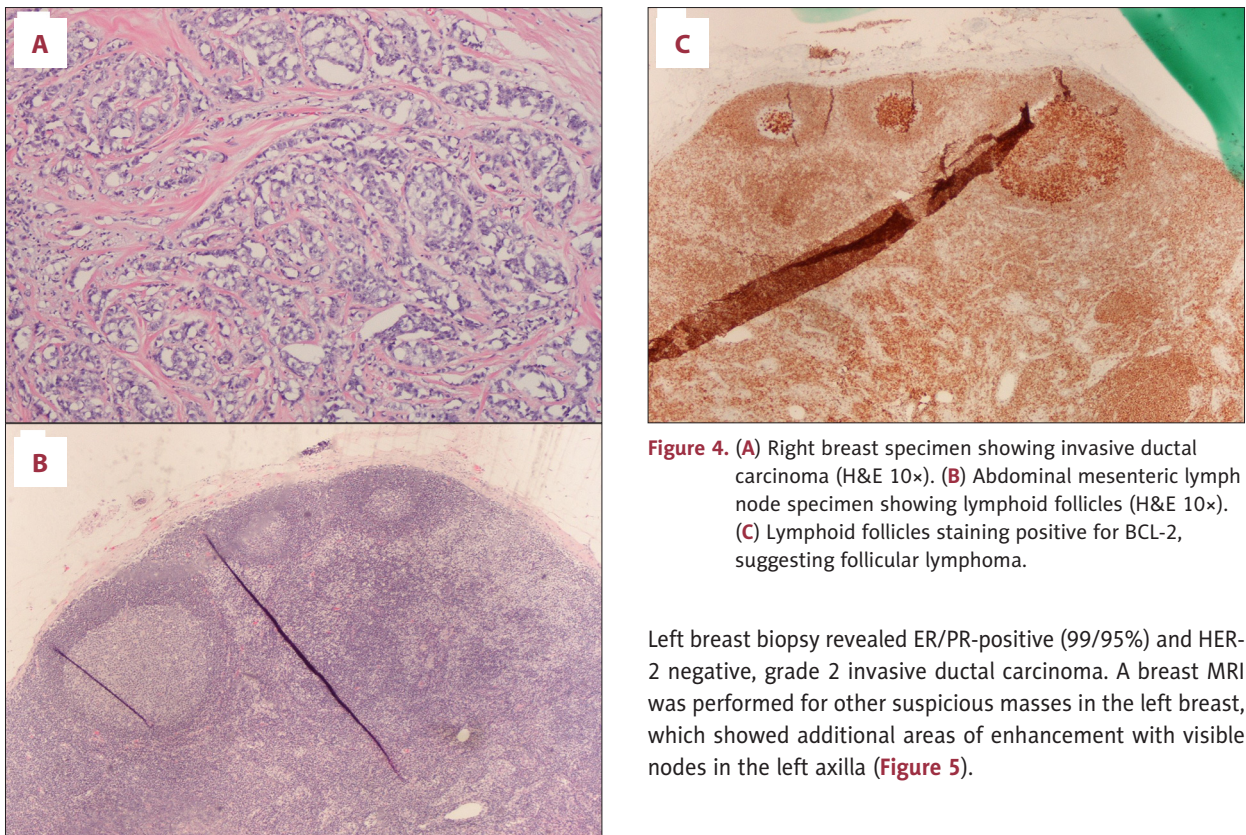
A 74-year-old post-menopausal woman presented with a suspicious breast mass on an annual screening mammogram. Her family history was significant for breast cancer in her mother and ovarian cancer in her maternal grandmother.

Targeted ultrasound revealed a 13×9×15 mm irregularly shaped, hypoechoic mass with angular margins in the left breast at 1 o'clock position, BI-RADS 4. Laboratory evaluation was unremarkable. On genetic testing, the patient had a variant of unknown significance on ATM p.c755Y.

management. She underwent a right mastectomy and right axillary lymph node dissection, followed by adjuvant chemotherapy and radiotherapy. The patient remained on close surveillance to re-evaluate her grade 2 follicular lymphoma for subsequent chemotherapy in the future.

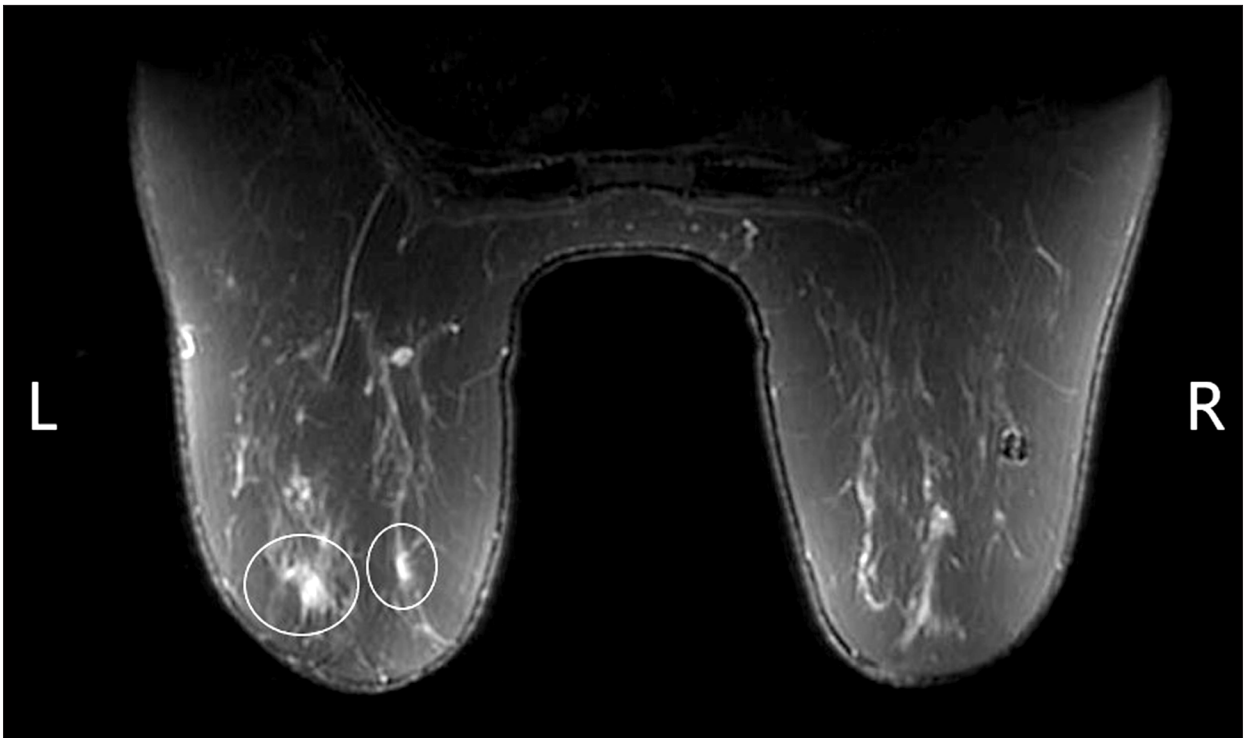

**Figure 3.** PET chest/abdomen/pelvis scan Axial views showing increase FDG uptake in multiple nodes in the thoracic inlet deep to left subclavian vein (A), left of upper trachea (B), superior to aortic arch (C) and numerous nodes along the root of the mesentery (D).

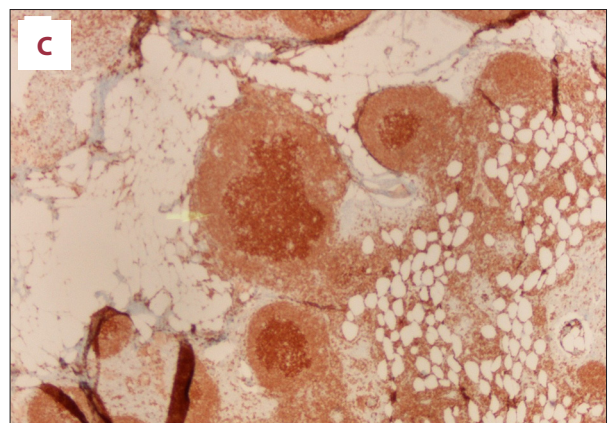
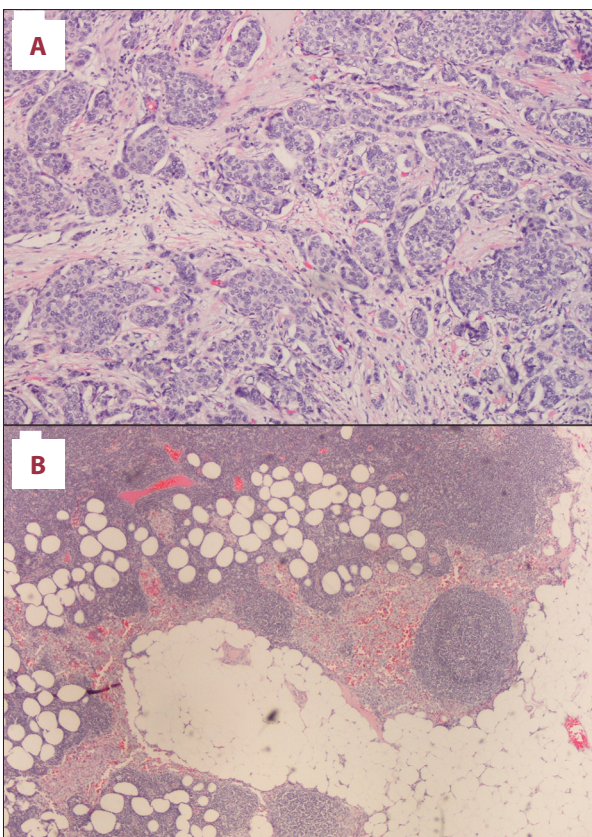


**Figure 4.** (A) Right breast specimen showing invasive ductal carcinoma (H&E 10x). (B) Abdominal mesenteric lymph node specimen showing lymphoid follicles (H&E 10x). (C) Lymphoid follicles staining positive for BCL-2, suggesting follicular lymphoma.

Left breast biopsy revealed ER/PR-positive (99/95%) and HER-2 negative, grade 2 invasive ductal carcinoma. A breast MRI was performed for other suspicious masses in the left breast, which showed additional areas of enhancement with visible nodes in the left axilla (Figure 5).



**Figure 5.** Breast MRI showing a 17 mm biopsy-proven invasive ductal carcinoma in the anterior left breast at 2 o'clock and a new 5-mm spiculated, enhancing mass in the posterior left breast at 11 o'clock, highly suspicious for a second invasive carcinoma. No evidence of malignancy on the right.



**Figure 6.** (A) Left breast specimen showing invasive ductal carcinoma (H&E 10×). (B) Left axillary lymph node sample suggesting in situ follicular neoplasia. (C) BCL2 expression.

Additional left breast mass biopsy demonstrated new foci of invasive ductal carcinoma, estrogen-positive and HER-2-negative, suggesting multifocal disease. A PET scan to evaluate the abnormal MRI and pathology did not show any other uptake focus.

She underwent left mastectomy with sentinel lymph node biopsy. She subsequently underwent complete axillary dissection

and was incidentally found to have follicular neoplasia in situ in 2 of her left dissected axillary LNs. Immunoperoxidase staining within occasional follicles displayed BCL2 expression with co-expression of CD10. CD20 and CD3 revealed normal antigenic expression (**Figure 6**).

As the patient had follicular neoplasia in situ, which was more consistent with pre-cancerous findings vs overt lymphoma, no further workup or treatment was indicated. The patient underwent adjuvant chemotherapy and radiation therapy for her stage IIB breast cancer, followed by hormonal therapy. She remained under surveillance by the hematologist-oncologist for 6 months.

## Discussion

Breast cancer is the most common worldwide malignancy in females and the second most common cause of cancer-related deaths after lung cancer. The development of lymphoma following chemotherapy and radiotherapy for breast cancer is a recognized occurrence. However, the synchronous occurrence of breast cancer and lymphoma is rare and can make the diagnostic and management approach very challenging. A summary of currently existing data on synchronous/metachronous occurrence of breast adenocarcinoma with lymphoma is listed in **Table 2** [5-12].

It is not clear if there is a direct relationship between lymphoma and breast carcinoma regarding our reported cases. It is theorized that, given that lymphomas can weaken the immune system and disable T cell-mediated antineoplastic pathways, successive carcinomas may occur. In a report regarding a rare presentation of diffuse large B cell lymphoma (DLBCL) and rectal carcinoma [11], it was thought that the coexisting lymphoma prepped the ground by defecting the cellular immune system that triggered the development of a second malignancy in the rectum, similar to the acquired reaction caused by the *Helicobacter pylori* causing MALT lymphoma of the stomach. However, given that we do not know which of the primary malignancy occurred first, further evidence is needed to elucidate specific cause-and-effect relationships.

Lymphoma is a diverse group of hematologic malignancies classified as Hodgkin lymphoma (HL) and non-Hodgkin lymphoma (NHL). NHL is more common in adults and is derived from B cell progenitors, T cells, and, rarely, natural killer cells. Breast cancer has been reported to co-occur with other rare forms of lymphoma like intravascular large B cell lymphoma [12]. However, the association between breast cancer and lymphoma is not specific to any pathological subtypes, as cases of synchronous breast cancer and DLBCL and HL have been reported [13,14].

The diagnosis of lymphoma and breast cancer is especially challenging with indolent lymphomas such as follicular lymphomas (FL). Cotswold's modified Ann Arbor staging for follicular lymphoma is described in **Table 3** [15]. Patients with early-stage FL typically do not have any significant symptoms or laboratory abnormalities. Adenopathy is a common presentation of FL. However, patients with breast cancer may also present with axillary adenopathy in addition to the breast mass. Atypical presentations such as early-stage breast cancer and distant adenopathy findings may prompt the treating physicians to think of synchronous cancer rather than metastatic disease. However, if adenopathy is only presented in the axillary lymph nodes or there is locally advanced breast cancer, the diagnosis of synchronous pathology may be missed. Therefore, pathologists should consider performing a variety of immunohistochemical stainings to distinguish the different diagnoses. When there is a suspicion for lymphoma, physicians should consider performing an adequate immunohistochemistry panel including CD20, CD3, CD10, BCL6, CD21 or CD23 with or without cell surface marker analysis by flow cytometry.

The management of follicular lymphoma and breast cancer is also significantly different, which poses another challenge. There are currently no guidelines available for the concurrent management of breast carcinoma and lymphoma. Best practice statements recommend multidisciplinary team discussions and treatment decisions based on the initial presentation of each cancer type and the staging and prognosis of the concurrent malignancy/condition.

The current NCCN guidelines for follicular lymphoma recommend clinical observation for stage I and II follicular lymphomas vs involved site radiotherapy (ISRT) plus anti-CD 20 monoclonal antibody (rituximab, Obinutuzumab) therapy +/- chemotherapy if the clinical benefit outweighs the risk of toxicity, whereas for stages III or IV, treatment is only indicated if the patient is symptomatic or there is rapid progression of the disease or threatened end-organ damage. First-line systemic therapy includes bendamustine + Obinutuzumab or rituximab alone, CHOP (cyclophosphamide, vincristine, prednisone) + Obinutuzumab/rituximab, or Lenalidomide + rituximab. Surveillance is indicated with repeat histopathology and labs every 3-6 months for 5 years and then annually. Imaging, including CT scan chest/abdomen/pelvis with contrast, is recommended every 6 months for up to 2 years and then annually after 2 years [16].

Follicular lymphoma is non-curable. Initiation of systemic therapy can improve failure-free survival (FFS) but has not been shown to improve overall survival (OS). Patients with low to intermediate-risk Follicular Lymphoma International Prognostic Index (FLIPI) have a median progression-free survival (PFS) of 70-84 months (about 7 years) and 2-year overall survival

**Table 2.** Previously reported cases.

Year	Author	Patient description	Primary breast carcinoma	Primary management	Second primary malignancy	Follow up management
2010	Laudenschlager et al [5]	52-year-old female	Invasive ductal carcinoma of the right breast	Mastectomy with sentinel LN biopsy	Low-grade follicular lymphoma 1/22 LN	Adjuvant chemo for breast CA with surveillance for FL
1998	Niedermayr et al [6]	87-year-old female	Invasive lobular carcinoma of right breast	Lumpectomy f/b tamoxifen therapy	Stage IV diffuse large B cell lymphoma	Lumpectomy f/b CHOP combination chemo with complete remission
2008	Al Hussaini et al [7]	50-year-old female	Invasive mucinous carcinoma of left breast	Mastectomy with sentinel LN dissection	Stage II SLL/CLL in dissected LN	Chemotherapy with cyclophosphamide and prednisolone for CLL resulting in complete remission
2005	Barranger et al [8]	61-year-old female	Invasive ductal carcinoma of left breast	Lumpectomy with axillary LN dissection	B cell follicular lymphoma in situ in non-sentinel LN	Essentially treated for breast CA
2004	Benoit et al [9]	53-year-old female	Adenocarcinoma of right breast	Sentinel LN biopsy	Co-occurrence of metastatic breast CA and Waldenstrom-type low grade lymphoma in non-sentinel LN	
2002	Frei et al [10]	63-year-old female	Invasive ductal carcinoma of left breast and DLBCL of right breast	Bilateral lumpectomies		Radiotherapy and tamoxifen therapy for left breast and CHOP therapy for right breast
2014	Nishikawa et al [11]	82-year-old female	Invasive lobular carcinoma of the left axillary accessory mammary gland	Mastectomy f/b tamoxifen therapy	Diffuse large B cell lymphoma (DLBCL) of left breast.	No chemo, 3-month surveillance, no metastasis of lymphoma but develop adenocarcinoma of rectum underwent Hartman's procedure
2019	Alakeel et al [12]	65-year-old female	Ductal carcinoma in Situ of left breast	Stereotactic biopsy	Intravascular large B cell lymphoma in adjacent breast tissue	Patient lost to follow up

DLBCL – diffuse large B cell lymphoma; SLL – small lymphocytic leukemia; CLL – chronic lymphocytic leukemia; LN – lymph node; FL – follicular lymphoma; CA – carcinoma; CHOP – cyclophosphamide, hydroxydaunorubicin, oncovin (vincristine), and prednisone.



**Table 3.** Cotswold's Modified Ann Arbor Staging system for follicular lymphoma.

Stage	Area of Involvement
I	Single LN group
II	Multiple LN groups on same side of the diaphragm
III	Multiple LN groups on both sides of the diaphragm
IV	Multiple extranodal site involvement with or without nearby LN
X	>10 cm bulk of lymphoma
E	Single or multiple extranodal extension of the disease
A/B	Presence/absence of B symptoms (>10% weight loss, fever, night sweats)

LN – lymph node.

(OS) of 94-98% [17]. In contrast, breast carcinoma is known to be curatable with currently available therapies. On average, breast cancer patients who have early-stage (I and II) breast cancer have over 90% PFS beyond 5 years [5]. Current treatment guidelines for breast cancer are complex and vary for invasive vs non-invasive disease. Our focus here is on the management of hormone receptor-positive invasive breast cancer in post-menopausal women.

Treatment for invasive breast carcinoma according to the NCCN guideline is based on TNM staging. The mainstay of treatment remains surgery with modified radical mastectomy or lumpectomy with radiation therapy (breast-conserving therapy [BCT]). Recent studies have shown no survival difference between these 2 strategies, and BCT is the preferred treatment for early-stage breast cancer. Post-menopausal women with nodal involvement (pN1) who are candidates for chemotherapy should be assessed with a recurrence score based on the 21 gene RT PCR assay. A patient with a score of 26 or above should be started on adjuvant chemotherapy followed by endocrine therapy. However, nodal involvement (pN2 or pN3) already indicates a high recurrence risk. Therefore, the patient can be started on chemotherapy followed by endocrine therapy and does not need gene assay. Chemotherapy regimens in hormone receptor (HR)-positive and HER 2-negative invasive breast cancer include:

1. dose-dense AC (doxorubicin+cyclophosphamide) followed by paclitaxel
2. TC (docetaxel+cyclophosphamide).

Adjuvant endocrine therapy with aromatase inhibitors (anastrozole, exemestane, letrozole) or selective estrogen receptor modulators (SERM) like tamoxifen is recommended in all patients with HR-positive breast cancer. Data suggest that these agents decrease mortality by about 30% and the risk of

recurrence by 50%. In post-menopausal women, aromatase inhibitors are preferred over SERM and are prescribed for a total of 5 years [18].

Therefore, the ideal approach is primarily to first treat the most biologically aggressive cancer, discussed by a multidisciplinary team including the surgeon, medical oncologist, pathologist, and radiation oncologist. All 3 of our patients presented with stage I-II follicular lymphomas with low to intermediate FLIPI and higher-risk breast cancer (stage II to III) requiring chemotherapy and surgical interventions. They were all hormone receptor-positive and HER-2 receptor-negative, with a good expected prognosis. Hence, it was decided to proceed with breast cancer treatment first and observe the FL. To date, all 3 patients tolerated their systemic chemotherapy for breast cancer and did not have any FL imaging progression. We plan to continue surveillance and monitoring for both types of cancers.

## Conclusions

The co-occurrence of breast cancer and lymphoma is rare and can pose a challenge to the treating oncologist, who should consider a second primary malignancy in cases of early breast cancer that presents with disseminated adenopathy. Choice of treatment should be based on the more aggressive disease and staging of the tumor, with close surveillance of the additional malignancy.

## Declaration of Figures' Authenticity

All figures submitted have been created by the authors who confirm that the images are original with no duplication and have not been previously published in whole or in part.

## References:

1. Coyte A, Morrison DS, McLoone P. Second primary cancer risk – the impact of applying different definitions of multiple primaries: Results from a retrospective population-based cancer registry study. *BMC Cancer*. 2014;14:272
2. Buiatti E, Crocetti E, Acciai S, et al. Incidence of second primary cancers in three Italian population-based cancer registries. *Eur J Cancer*. 1997;33(11):1829-34
3. Rosso S, De Angelis R, Ciccolallo L, et al. Multiple tumours in survival estimates. *Eur J Cancer*. 2009;45(6):1080-94
4. Weir HK, Johnson CJ, Thompson TD. The effect of multiple primary rules on population-based cancer survival. *Cancer Causes Control*. 2013;24(6):1231-42
5. Laudenschlager MD, Tyler KL, Geis MC, et al. A rare case of synchronous invasive ductal carcinoma of the breast and follicular lymphoma. *S D Med*. 2010;63(4):123-25
6. Niedermayr A, Gharehbaghi K, Pacher B, et al. Coincidence of primary non-Hodgkin's lymphoma and invasive lobular carcinoma of the breasts – clinical diagnosis and management. *Acta Oncol*. 1998;37(3):305-6
7. Al-Hussaini MA, Al-Masad JK, Awidi AA. Carcinoma of breast co-existing with non-Hodgkin's lymphoma of axillary lymph nodes. *Saudi Med J*. 2008;29(1):138-41
8. Barranger E, Marpeau O, Uzan S, Antoine M. Axillary sentinel node involvement by breast cancer coexisting with B-cell follicular lymphoma in non-sentinel nodes. *Breast J*. 2005;11(3):227-28
9. Benoit L, Arnould L, Collin F, et al. Concurrent lymphoma and metastatic breast carcinoma in the axillary, confounding sentinel lymph-node biopsy. *Eur J Surg Oncol*. 2004;30(4):462-63
10. Frei KA, Bonel HM, Forrer P, et al. Primary breast lymphoma, contralateral breast cancer, and bilateral Brenner tumors of the ovary. *Obstet Gynecol*. 2002;100(5 Pt 2):1079-82
11. Nishikawa A, Kasai H, Koyama Y, et al. Synchronous ipsilateral carcinoma of the accessory mammary gland and primary lymphoma of the breast with subsequent rectal carcinoma: Report of a case. *World J Surg Oncol*. 2014;12:286
12. Alakeel F, Lee E, Baird-Howell M, Easley S. Synchronous ductal carcinoma in situ and intravascular large B-cell lymphoma of the breast. *Appl Immunohistochem Mol Morphol*. 2019;27(9):e91-e92
13. Cuff KE, Dettrick AJ, Chern B. Synchronous breast cancer and lymphoma: A case series and a review of the literature. *J Clin Pathol*. 2010;63(6):555-57
14. Zhong J, Di L, Zheng W. Synchronous breast cancer and breast lymphoma: Two case reports and literature review. *Chin J Cancer Res*. 2014;26(3):355-59
15. Lister TA, Crowther D, Sutcliffe SB, et al. Report of a committee convened to discuss the evaluation and staging of patients with Hodgkin's disease: Cotswolds meeting. *J Clin Oncol*. 1989;7(11):1630-36
16. Network NCC. NCCN guidelines B-cell lymphoma. May 5, 2021; Available from: [https://www.nccn.org/professionals/physician\\_gls/pdf/b-cell.pdf](https://www.nccn.org/professionals/physician_gls/pdf/b-cell.pdf)
17. Kalli S, Semine A, Cohen S, et al. American Joint Committee on Cancer's Staging System for Breast Cancer, Eighth edition: What the radiologist needs to know. *Radiographics*. 2018;38(7):1921-33
18. Network NCC. NCCN guidelines breast cancer August 16, 2021; Available from: [https://www.nccn.org/professionals/physician\\_gls/pdf/breast.pdf](https://www.nccn.org/professionals/physician_gls/pdf/breast.pdf)