

# Combined robotic radical prostatectomy and laparoscopic proctectomy for synchronous prostate and rectal cancer

Zachary Tully<sup>a,\*</sup>, Jordan Richards<sup>b</sup>, Asgeir T. Masson<sup>c</sup>, Kristina L. Guyton<sup>c</sup>,  
Vignesh T. Packiam<sup>b</sup>

<sup>a</sup> Carver College of Medicine, University of Iowa, Iowa City, IA, USA

<sup>b</sup> University of Iowa, Department of Urology, Iowa City, IA, USA

<sup>c</sup> University of Iowa, Department of Surgery, Iowa City, IA, USA

## ARTICLE INFO

### Keywords:

Concurrent  
Robotic  
Prostatectomy  
Proctectomy  
Perirectal  
Nodes

## ABSTRACT

Prostatic adenocarcinoma is the second most common cause of cancer related mortality in men. Robotic-assisted laparoscopic prostatectomy represents a standard treatment option for localized disease. We present a case of a 63-year-old male with synchronous presentation of prostate and rectal cancer treated with combined robotic prostatectomy (RALP) and low anterior resection (LAR). Interestingly, a mesorectal lymph node contained metastatic prostate cancer.

## 1. Introduction

Prostatic adenocarcinoma remains the most common non-dermatologic malignancy in men globally and is the second most common cause of cancer-related mortality in men.<sup>1</sup>

## 2. Case presentation

A 63-year-old male with a history of insulin dependent type 2 diabetes mellitus, atrial fibrillation, obstructive sleep apnea, and prior bilateral inguinal hernia repair underwent a screening colonoscopy and was noted to have an upper rectal mass. Biopsy revealed invasive moderately differentiated adenocarcinoma. He was asymptomatic. A staging MRI of the pelvis was performed demonstrating a T1-T2N0 upper rectal cancer and an incidentally found prostate lesion. A prostate MRI demonstrated a PIRADS5 lesion in the left peripheral zone of the prostate. He denied any urologic complaints. Laboratory work-up revealed a CEA of 2.8mg/mL and an elevated PSA of 7.19 ng/mL. A transrectal MRI-fusion prostate biopsy showed Grade Group 5 (Gleason score 4 + 5) prostatic adenocarcinoma in 7/18 cores. There was over 10cm separation between the rectal mass and the prostate (Fig. 1). Bone scan and CT chest, abdomen and pelvis revealed no evidence of metastatic disease.

Due to size and location of the rectal mass, LAR with end-to-end anastomosis (EEA) was recommended. Given the early stage rectal cancer and the synchronous prostate cancer, neoadjuvant therapy was deferred in favor of combined LAR and RALP.<sup>2</sup>

The patient was prepped in the standard fashion with port sites as indicated in Fig. 2. Surgery began with posterior dissection and a bilateral pelvic lymph node dissection. The bladder was dropped the dorsal venous complex (DVC) was sutured. The bladder neck was divided and the pedicles were clipped and dissected off the prostate. The DVC and urethra were divided and the prostate was removed. The anastomosis was performed using a double armed 2-0 Quill suture in a running van Velthoven fashion. The bladder was irrigated with 180 cc of saline, and the anastomosis was confirmed watertight. The bladder was reapproximated to the anterior abdominal wall using a running 3-0 V-locc suture per preference of the colorectal team.

The procedure was turned over to the colorectal team. A laparoscopic approach was used. The splenic flexure was mobilized and an omental pedicle flap was created. A medial to lateral dissection of colon was completed with high ligation of the inferior mesenteric artery. The dissection was carried down into the pelvis and a total mesorectal excision (TME) was performed. A 12mm port in RLQ was added to accommodate an EndoGIA stapler. The rectum was transected below the previously placed tattoo and all specimens were removed through an

**Abbreviations:** LAR, Low Anterior Resection; EEA, End-to-End Anastomosis; CEA, Carcinoembryonic Antigen; ADT, Androgen Deprivation Therapy.

\* Corresponding author.

E-mail address: [ztully@uiowa.edu](mailto:ztully@uiowa.edu) (Z. Tully).

<https://doi.org/10.1016/j.eucr.2022.102043>

Received 22 December 2021; Received in revised form 15 February 2022; Accepted 24 February 2022

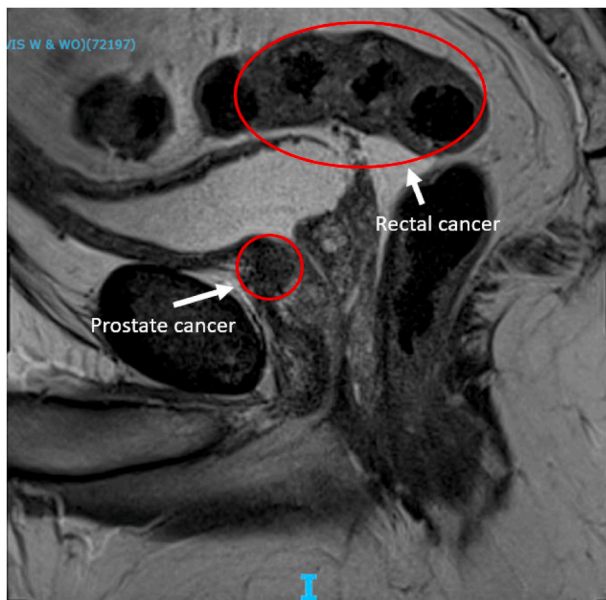
Available online 25 February 2022

2214-4420/© 2022 The Authors.

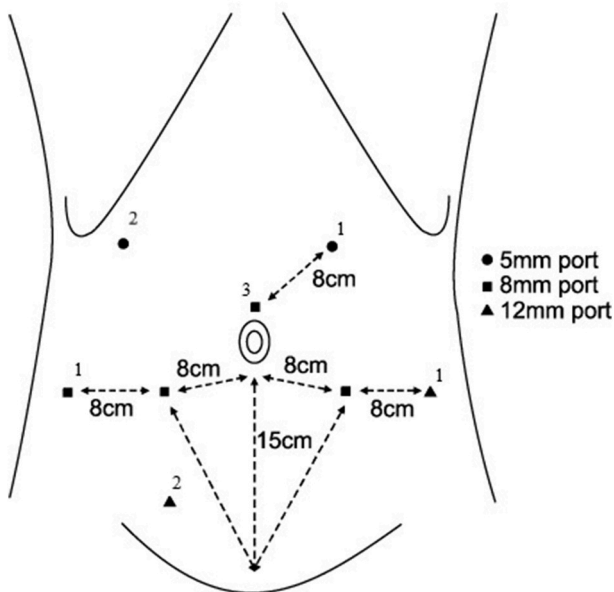
Published by Elsevier Inc.

This is an open access article under the CC BY-NC-ND license

(<http://creativecommons.org/licenses/by-nc-nd/4.0/>).



**Fig. 1.** Sagittal View Prostate MRI. Shows discrete prostate and high rectal masses.



**Fig. 2.** Port sites for the synchronous procedures. 1 indicates a site used solely by the urology team, the 2 indicates a site used solely by the colorectal team. 3 indicates a site used as an 8mm port by the urology team and upsized to 12mm by the colorectal team.

enlarged supraumbilical incision; the proximal colon was divided extracorporeally. An end-to-end anastomosis was created intracorporeally using a 31 mm EEA stapler. A flexible endoscopy was performed which demonstrated a negative anastomotic leak test. The omental flap was placed between the colorectal anastomosis and the bladder-urethral anastomosis. A diverting loop ileostomy was created in the right upper quadrant in the location previously marked by the ostomy team. The specimens were removed. There were no noted complications or injuries. Estimated blood loss was 180 cc with 544 minutes total operative time.

Final pathology demonstrated pT2N1R1 Grade Group 3 (Gleason score 4 + 3 with tertiary pattern 5) prostatic adenocarcinoma, with focal

1mm left posterior positive margin. There were 0/16 pelvic lymph nodes positive for malignancy. The colon specimen demonstrated 2.8cm pT3N1a moderately differentiated rectal adenocarcinoma with negative margins. Two of 23 lymph nodes from the LAR specimen were positive, one with metastatic colon cancer, the other with metastatic prostate cancer. Post-operative PSA was 0.04 at 3 months and 0.05 at 9 months. While the preoperative CEA was not elevated, the Signatera circulating tumor DNA assay was positive preoperatively and negative post-operatively. The decision was made not to proceed with adjuvant androgen deprivation therapy (ADT) at this time due greater competing risk of mortality from rectal cancer and concern for toxicity with ADT and adjuvant chemotherapy.

Postoperatively, his course was complicated by atrial fibrillation and hyperglycemia. Functionally, he has minimal stress urinary incontinence and is using one safety pad per day and reports erectile sensation with partial erections at nine months. He completed six cycles of adjuvant chemotherapy for colon cancer and following this his diverting ileostomy was reversed, with appropriate defecatory function. On postoperative surveillance imaging he was noted to have abnormal cervical lymph nodes and underwent biopsy with subsequent total thyroidectomy and lymph node dissection, demonstrating pT1bN1b papillary thyroid carcinoma. Germline genetic testing was performed and demonstrated a variant of unknown significance in the MSH3 gene.

### 3. Discussion

This report further demonstrates the feasibility of combined surgery for synchronous robotic prostate and colorectal malignancy in a well selected patient. There have been sporadic reports of this in the literature.<sup>3,4</sup>

Typically, radical prostatectomy and radiation therapy are first line recommendations for the treatment of high-risk prostate cancer. Concurrent prostatic and rectal surgery was favored in this patient due to several factors. First, the rectal tumor was early stage and within the proximal rectum, therefore LAR was recommended regardless of whether neoadjuvant therapy was given. Next, neoadjuvant and adjuvant radiation of the prostate may contribute to a more challenging dissection and higher risk of colorectal anastomotic leak and was discouraged by the colorectal team. Finally, it was anticipated there would be appropriate physical distance between the bladder anastomosis and the colorectal anastomosis to avoid fistula formation. To further limit the risk of fistula formation, an omental flap was placed between the two anastomoses and fecal diversion was performed.

Interestingly, while the pelvic lymph node specimen did not contain prostate cancer, a perirectal lymph node in the LAR specimen contained metastatic prostate cancer. Prostate cancer has rarely been noted in perirectal lymph nodes, and was discovered fortuitously in this case.<sup>5</sup> Future larger case series would provide greater insight toward best practice.

### 4. Conclusion

In select cases, concurrent prostate and colonic malignancies can be managed with a combined minimally invasive surgical approach. The risk of anastomotic fistula can be reduced with utilization of tissue interposition, temporary fecal diversion and avoidance of radiation. Our report demonstrates the feasibility and safety of combined robotic minimally invasive prostatectomy and proctectomy.

### References

- Rawla P. Epidemiology of prostate cancer. *World J Oncol.* 2019;10(2):63–89. <https://doi.org/10.14740/wjon1191>.
- National Comprehensive Cancer Network. Colon cancer (Version 3.2021). [http://www.nccn.org/professionals/physician\\_gls/pdf/colon.pdf](http://www.nccn.org/professionals/physician_gls/pdf/colon.pdf). Accessed October 15, 2021.

3. Park M, Kim SC, Chung JS, et al. Simultaneous robotic low anterior resection and prostatectomy for adenocarcinoma of rectum and prostate: initial case report. *SpringerPlus*. 2016;5(1):1768. <https://doi.org/10.1186/s40064-016-3456-y>. Published 2016 Oct 12.
4. Kojima Y, Sakamoto K, Horie S, et al. Simultaneous robot-assisted surgery for rectal cancer and prostatic lesions, 2020 *J Surg Case Rep*. 2020;(9):rjaa338. <https://doi.org/10.1093/jscr/rjaa338>. Published 2020 Sep. 21.
5. Murray SK, Breau RH, Guha AK, Gupta R. Spread of prostate carcinoma to the perirectal lymph node basin: analysis of 112 rectal resections over a 10-year span for primary rectal adenocarcinoma. *Am J Surg Pathol*. 2004;28(9):1154–1162. <https://doi.org/10.1097/01.pas.0000131543.80147.3d>.