

# Atelocollagen Injection Improves Tendon Integrity in Partial-Thickness Rotator Cuff Tears

## A Prospective Comparative Study

Jong-Ho Kim,\* MD, PhD, Dong-Jin Kim,<sup>†</sup> MD, Hyo-Jin Lee,<sup>†</sup> MD, PhD, Baek-Kyu Kim,<sup>‡</sup> MD, and Yang-Soo Kim,<sup>†§</sup> MD, PhD

*Investigation was performed at Seoul St Mary's Hospital, The Catholic University of Korea, Seoul, Republic of Korea*

**Background:** Ongoing controversy surrounds the best treatment modality for partial-thickness rotator cuff tears.

**Purpose:** To investigate the effects of atelocollagen injection in patients with small, symptomatic, intratendinous rotator cuff tears.

**Study Design:** Randomized controlled trial; Level of evidence, 1.

**Methods:** From January 2014 to December 2017, 94 patients who had small, symptomatic, intratendinous rotator cuff tears were enrolled and randomly allocated to 1 of 3 groups: intratendinous injection with 0.5 mL of type I atelocollagen (group 1, n = 32), intratendinous injection with 1 mL of type I atelocollagen (group 2, n = 30), and no injection of type I atelocollagen (group 3, n = 32). American Shoulder and Elbow Surgeons score, Constant Shoulder Score, visual analog scale pain score, and range of motion were evaluated before injection; at 3, 6, and 12 months after injection; and at final follow-up. Magnetic resonance imaging (MRI) was performed at least 6 months after injection to evaluate rotator cuff integrity.

**Results:** Demographic data did not differ significantly among the 3 groups before injection ( $P > .05$ ). The mean follow-up period was 24.7 months. The functional and pain scores in groups 1 and 2 were significantly improved at final follow-up ( $P < .05$ ). No significant improvement was seen in functional or pain scores at final follow-up in group 3 ( $P > .05$ ). Groups 1 and 2 had significantly better functional scores compared with group 3 at final follow-up ( $P < .05$ ). The proportion of patients with a decrease in size of the torn tendon on follow-up MRI at least 6 months after atelocollagen injection was significantly higher in group 1 (28.1%;  $P = .02$ ) and group 2 (36.7%;  $P = .003$ ) compared with group 3 (6.3%).

**Conclusion:** Atelocollagen injection can improve the functional outcome and integrity of the tendon in intratendinous rotator cuff tears.

**Keywords:** shoulder; rotator cuff; intratendinous tear; partial-thickness tear; atelocollagen; injection

Treatment of rotator cuff tears can be nonoperative or operative. The choice of treatment modality is affected by several factors, including tear degree and size, symptoms, and functional loss. Controversy remains regarding which method is the most effective for treatment of rotator cuff tears. Although a full-thickness tear is a well-known risk factor for progression of a rotator cuff tear,<sup>16</sup> some studies have demonstrated good results with nonoperative management of full-thickness rotator cuff tears.<sup>1,2</sup> Ongoing controversy surrounds the indication for surgical intervention of partial-thickness tears.<sup>5,10</sup> Close scrutiny and

observation are needed in symptomatic partial-thickness tears, which have a high possibility of tear size progression.<sup>16,19</sup> If the extent of a partial tear is less than 50% of the tendon depth, nonoperative treatments are recommended.<sup>16</sup> However, most nonoperative treatment modalities for partial-thickness tears focus on symptom relief, and fundamental treatments that help the tendon itself recover are lacking.

The supraspinatus tendon is composed of highly specialized mesenchymal-derived cells (tenocytes) embedded in a 3-dimensional network of extracellular matrix consisting predominantly of collagen type I (>95%).<sup>24</sup> Collagen is the main component of the extracellular matrix and has many functions, including delivering force, dispersing energy, and supporting connective tissues.<sup>23</sup> Some studies have

The Orthopaedic Journal of Sports Medicine, 8(2), 2325967120904012

DOI: 10.1177/2325967120904012

© The Author(s) 2020

This open-access article is published and distributed under the Creative Commons Attribution - NonCommercial - No Derivatives License (<https://creativecommons.org/licenses/by-nc-nd/4.0/>), which permits the noncommercial use, distribution, and reproduction of the article in any medium, provided the original author and source are credited. You may not alter, transform, or build upon this article without the permission of the Author(s). For article reuse guidelines, please visit SAGE's website at <http://www.sagepub.com/journals-permissions>.

described the effect of applying collagen sponges or patches with augmentation in rotator cuff repair in humans.<sup>4,9</sup> Atelocollagen is a collagen treated with proteolytic enzymes to remove the terminal telopeptides and is low in immunogenicity.<sup>18,22</sup> Highly purified atelocollagen has many advantages in terms of biocompatibilities and optimizing collagen-cell interactions for efficacy while at the same time reducing adverse effects.<sup>26</sup> Atelocollagen injection in patients with plantar fasciitis is an effective treatment for hardening of the plantar fascia and improving symptoms under sonoelastography.<sup>14</sup> In a rat model, applying atelocollagen membranes in periodontal defects yielded more satisfactory wound healing, and in a rabbit model, applying patch-type atelocollagen to tears of the supraspinatus tendon led to histological and biomechanical improvement.<sup>21,26</sup> To the best of our knowledge, no clinical studies have evaluated the effectiveness of atelocollagen injection for partial-thickness rotator cuff tears involving less than 50% of the tendon depth.

The purpose of this study was to evaluate the effect of atelocollagen injection in patients with small, symptomatic, intratendinous rotator cuff tears. We hypothesized that atelocollagen injection would decrease tear size and delay tear progression in partial-thickness rotator cuff tears over a short-term follow-up period.

## METHODS

### Inclusion and Exclusion Criteria

From January 2014 to December 2017, a total of 162 patients who were diagnosed with intratendinous rotator cuff tears by magnetic resonance imaging (MRI) were enrolled. Only intratendinous partial-thickness supraspinatus tears were included; articular or bursal side partial-thickness tears were excluded because of the lack of capacity for containment of collagen material after injection inside the tear site. We included patients who visited a hospital for the first time after having shoulder symptoms or who had received only medication or physical therapy. We excluded patients who had ever had any type of injection including corticosteroid, prolotherapy, or polydeoxyribonucleotide, which could change the quality of the torn rotator cuff. Patients who had history of trauma involving the affected shoulder or who were professional athletes were also excluded. Patients with a history of previous surgery on the affected arm or concomitant shoulder lesions such as glenohumeral arthritis, labral lesions, or fractures

were excluded from the study. Patients with shoulder stiffness with forward flexion less than 100° (maximum 150°; forward flexion is glenohumeral motion without scapulohumeral rhythm<sup>11</sup>), external rotation less than 45° (maximum 90°), or internal rotation at a level lower than the first lumbar spine (L1; maximum T7 level) were also excluded.<sup>17</sup> We used 1 mL of atelocollagen (3% RegenSeal; Sewon Cellontech) in this study. We divided patients into 3 groups: a 0.5-mL injection group (group 1), a 1-mL injection group (group 2), and a no-injection group (group 3) as the control to evaluate the dose effect on the final outcomes of rotator cuff tears. This prospective randomized controlled study was approved by the institutional review board of our institution.

### Sample Size Calculation

The primary outcome measure of our study was the change in tendon integrity assessed by MRI. A sample size of 94 participants was sufficient to detect an effect value of 0.358 (Cohen medium effect size) and degrees of freedom of 4 (3 [group 1, 2, 3] × 3 [decrease, no change, increase]) at a significance level of .05 (2-sided) with 80% power by chi-square test, and was calculated using G\*Power software 3.1.9.4 (<http://www.gpower.hhu.de/>). A 20% loss to follow-up was expected. Thus, a total of 114 patients were finally analyzed. Patients were allocated to 1 of 3 groups through use of computer-generated block-randomization numbers: intratendinous injection with 0.5 mL of type I atelocollagen (group 1), intratendinous injection with 1 mL of type I atelocollagen (group 2), and no injection of type I atelocollagen (group 3). All patients were blinded to treatment at the time of allocation. Ultimately, 32 patients from group 1, 30 patients from group 2, and 32 patients from group 3 were available at the last follow-up visit (Figure 1). Baseline characteristics of the enrolled patients are described in Table 1.

### Ultrasonography-Guided Injection Procedure

Type I atelocollagen injection into the tear site of the supraspinatus tendon was performed in groups 1 and 2. A single senior surgeon (Y.-S.K.) conducted all procedures using ultrasonography (HD11XE; Philips). A linear high-frequency probe (12 MHz) was used. Patients were asked to rotate their arm internally, extend it excessively, and attach their affected hand to their ipsilateral buttock in a sitting posture. The injection site was sterilized, and the needle was inserted through the deltoid muscle and the subacromial space, such that the location of the needle tip

§Address correspondence to Yang-Soo Kim, MD, PhD, Department of Orthopedic Surgery, Seoul St. Mary's Hospital, The Catholic University of Korea, Banpo-Daero 222, Secho-gu, Seoul 06591, Republic of Korea (email: kysoos@catholic.ac.kr).

\*Department of Orthopedic Surgery, Yeouido St Mary's Hospital, The Catholic University of Korea, Seoul, Republic of Korea.

†Department of Orthopedic Surgery, Seoul St Mary's Hospital, The Catholic University of Korea, Seoul, Republic of Korea.

‡Department of Orthopedic Surgery, Wonkwang University Sanbon Hospital, Wonkwang University of School of Medicine, Gunpo, Gyeonggi-do, Republic of Korea.

Final revision submitted November 7, 2019; accepted November 13, 2019.

One or more of the authors has declared the following potential conflict of interest or source of funding: Sewon Cellontech Co donated the RegenSeal product used in this study. AOSSM checks author disclosures against the Open Payments Database (OPD). AOSSM has not conducted an independent investigation on the OPD and disclaims any liability or responsibility relating thereto.

Ethical approval for this study was obtained from Seoul St Mary's Hospital, the Catholic University of Korea Institutional Review Board (study No. KC16DISI0584).

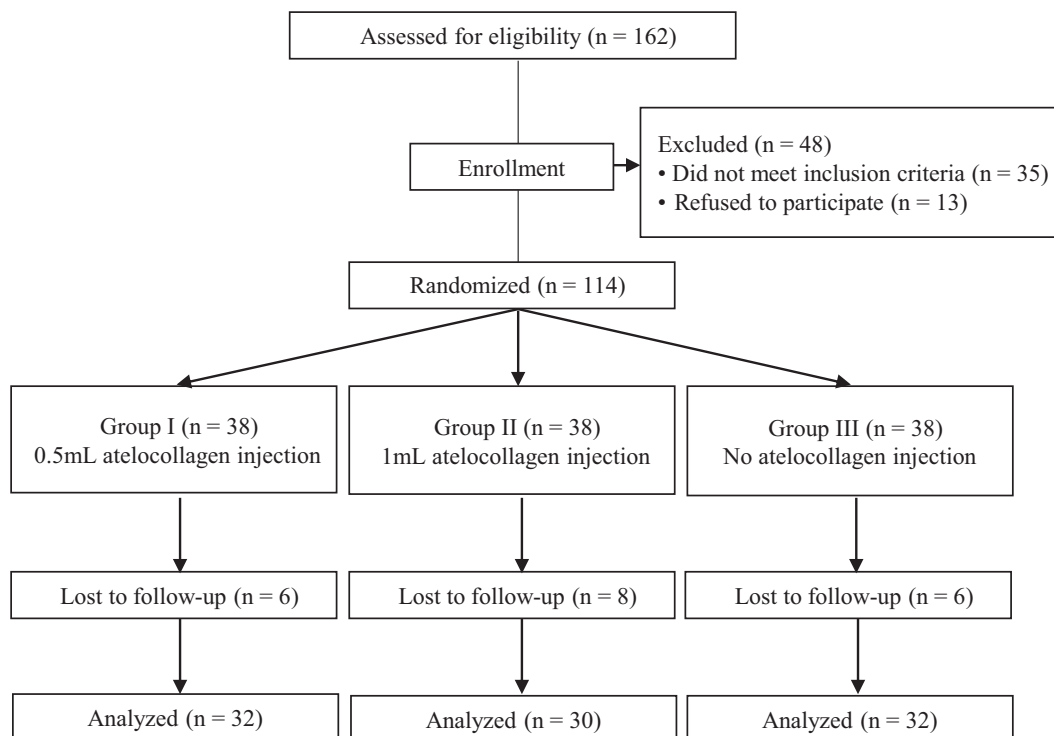


Figure 1. CONSORT (Consolidated Standards of Reporting Trials) guidelines flowchart.

TABLE 1  
Patient Demographics<sup>a</sup>

	Group 1	Group 2	Group 3	P Value
No. of patients	32	30	32	
Age, y, mean	58.5	58.2	60.4	.18
Sex, male/female, n	9/23	8/22	12/20	.61
Symptom duration, mo	9.2	9.3	8.9	.93
Follow-up, mo, mean ± SD	24.7 ± 2.9	24.4 ± 3.2	25.5 ± 4.1	.78
Follow-up MRI, mo, mean ± SD	9.3 ± 2.4	9.8 ± 2.7	11.7 ± 2.8	.19
Tear size, mm, mean ± SD				
Medial to lateral	5.5 ± 2.1	5.1 ± 2.0	4.9 ± 1.4	.52
Anterior to posterior	4.3 ± 1.5	4.5 ± 2.0	4.4 ± 2.2	.95
Initial clinical score				
VAS score for pain	4.1	3.6	3.4	.23
ASES score	61.9	63.5	62.9	.46
CSS	68.1	65.8	68.4	.71

<sup>a</sup>ASES, American Shoulder and Elbow Surgeons; CSS, Constant Shoulder Score; MRI, magnetic resonance imaging; VAS, visual analog scale.

within the tear site of supraspinatus tendon was identified through ultrasonography (Figure 2). Group 1 patients were treated with 0.5 mL of type I atelocollagen, and group 2 patients were treated with 1 mL of type I atelocollagen. In group 3, there was no injection.

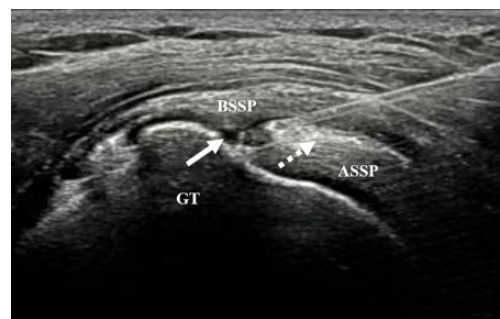

Figure 2. Ultrasonography-guided intratendinous injection. The needle tip is positioned at the intratendinous tear site (solid arrow). The injected atelocollagen spreads into the intratendinous tear gap between the bursal and articular layer of the torn rotator cuff (dotted arrow). ASSP, articular layer of supraspinatus tendon; BSSP, bursal layer of supraspinatus tendon; GT, greater tuberosity.

### Rehabilitation

All patients underwent the same rehabilitation. All enrolled patients received the same home exercise education program. First, gentle, progressive stretching exercises including the pendulum, sleeper’s stretch, and posterior capsular stretching were prescribed. Second, when the patient had achieved a comfortable passive range of motion (ROM) in the affected shoulder, strengthening exercises with resistance bands were carried out. Band resistance was increased incrementally. The patients did

not change to a higher resistance band until exercises on the current band were easy and painless. Nonsteroidal anti-inflammatory drugs were prescribed to patients who had unbearable pain during exercise.

### Clinical Assessment

Clinical status and treatment outcomes were evaluated at the initial visit (before injection in groups 1 and 2) and at 6 weeks, 3 months, 6 months, and 12 months after injection in groups 1 and 2 and at the initial visit. Assessments were carried out by a single senior surgeon. At these assessments, passive ROM of the affected shoulder, visual analog scale (VAS) score for pain at rest (0, no pain; 10, most severe pain), American Shoulder and Elbow Surgeons (ASES) score, and Constant Shoulder Score were evaluated. ROM, including forward flexion, external rotation at the side, and external rotation at 90° of abduction of the treated shoulder, was measured with a goniometer. Internal rotation was evaluated by the tip of the thumb reaching the vertebral level in the sitting position. The vertebral level was numbered serially: 0 for any level below the sacral region, with 1 point added for each level above the sacrum.<sup>15</sup> All data were collected prospectively by a clinical researcher (H.-J.L.) blinded to the study protocol, and the patients were also blinded during assessment.

### Image Evaluation

All enrolled patients underwent MRI to evaluate tendon integrity at least 6 months after injection. All MRI examinations were performed using a 3.0-T scanner (Magnetom Verio) at our hospital. Coronal oblique, sagittal oblique, axial fast spin-echo T2-weighted images (repetition time [TR]/echo time [TE], 2000-5000/76-12 ms) and coronal oblique T1-weighted images (TR/TE, 650-800/13-6 ms) were used to assess tear size, muscle volume, and fatty infiltration. The same MRI scanner was used to assess the integrity of the rotator cuff before and after injection. Tear size of the supraspinatus was measured on 2 plane images (sagittal oblique and coronal oblique).<sup>16</sup> The definition of a tear was a hyperintense signal and a filling defect in the tendon on T2-weighted images. A partial-thickness tear was defined as a partially connected tendon to the insertion site. Changes in tear size were divided into 3 categories because of the difficulty of detecting small changes in tear size on MRI: (1) greater than 2-mm increase, (2) greater than 2-mm decrease, and (3) less than 2-mm change.<sup>19</sup> We classified the tear as category 1 or 2 when there was a change of more than 2 mm in at least 1 image between the sagittal oblique and sagittal images.

The volume of the supraspinatus muscle was calculated by use of the occupying ratio (the percentage of supraspinatus muscle occupying the fossa suprascapularis) in sagittal oblique T1-weighted images.<sup>27,31</sup> No standard criteria are available to calculate changes in muscle volume. Chung et al<sup>3</sup> reported a mean value of intraobserver relative error of  $\pm 3.03\%$ . Thus, a cutoff value of 10% was set to cover intraobserver relative error. Changes in volume of the supraspinatus muscle were also divided into 3 categories comparing initial and follow-up MRIs: (1) more than 10%

TABLE 2  
Changes in Tear Size on Follow-up  
Magnetic Resonance Imaging<sup>a</sup>

	Decrease	No Change	Increase
Group 1	9 (28.1)	15 (46.9)	8 (25)
Group 2	11 (36.7)	15 (50)	4 (13.3)
Group 3	2 (6.3)	20 (62.5)	10 (31.3)

<sup>a</sup>Values are expressed as n (%).

increase, (2) less than 10% change, and (3) more than 10% decrease. Fatty infiltration was measured through use of the Goutallier classification on MRI.<sup>6</sup>

Changes in tear sizes were independently measured by 2 orthopaedic surgeons who were blinded to group allocation: one with 11 years of orthopaedic experience (H.-J.L.) and the other with 7 years of orthopaedic experience (D.-J.K.). When the 2 surgeons determined different degrees of change in tear size, a surgeon with 13 years of orthopaedic experience reassessed the grade. The change in tear size on which 2 surgeons agreed was used for this study. Interobserver reliability was determined by intraclass correlation coefficients (ICCs). At 1 month after the initial measurement, a single surgeon remeasured the changes in tear size to assess intraobserver reliability.

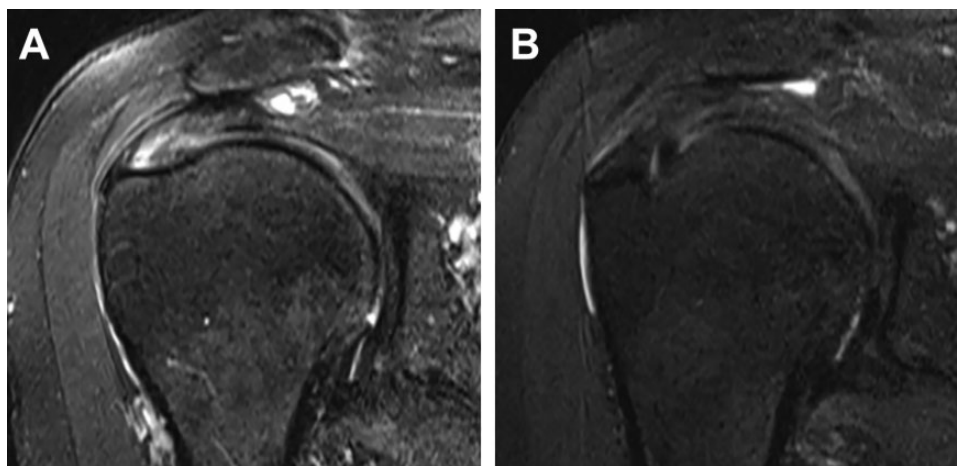
### Statistical Analysis

Statistical analysis was performed with SPSS software (Version 21.0; IBM Corp). A 1-way analysis of variance (ANOVA) was used to compare differences in demographic data and functional scores of the 3 groups. We checked normality of demographic data and functional scores of the 3 groups using the Shapiro-Wilks test. Then, we performed a 1-way ANOVA post hoc test (Tukey honestly significant difference). A paired *t* test was used to compare differences in ROM and functional scores between initial and final follow-up in each group. The chi-square test was used to evaluate the association between changes of tear size and dosages of atelocollagen. Reliability was evaluated through use of ICCs and a 2-way mixed-effect model assuming a single measurement and absolute agreement.<sup>25</sup> Significance was set at  $P < .05$ .

## RESULTS

Demographic data, including age, sex, mean follow-up period, size of rotator cuff tear, and initial ROM, and clinical scores before injection were not significantly different among the 3 groups. The mean  $\pm$  SD follow-up period was  $24.7 \pm 2.9$  months for group 1,  $24.4 \pm 3.2$  months for group 2, and  $25.5 \pm 4.1$  months for group 3. All patients were followed for at least 12 months. The mean interval of follow-up MRI was  $9.3 \pm 2.4$  months for group 1,  $9.8 \pm 2.7$  months for group 2, and  $11.7 \pm 2.8$  months for group 3 (Table 1).

Changes in tear size between the initial and follow-up MRI are summarized in Table 2. In group 1 ( $n = 32$ ),



**Figure 3.** A 66-year-old woman with an intratendinous rotator cuff tear experienced a decreased tear size of the tendon on 9-month follow-up magnetic resonance imaging (MRI) scan after injection of 1 mL of atelocollagen (T2-weighted fat suppression image). (A) MRI before injection. (B) 6-month follow-up MRI after injection.

**TABLE 3**  
Changes in Supraspinatus Muscle Volume and Fatty Infiltration on Follow-up Magnetic Resonance Imaging<sup>a</sup>

	Muscle Volume			Fatty Infiltration		
	Increased <sup>b</sup>	No Change	Decreased	Improvement	No Change	Progression
Group 1	0	31	1	0	31	1
Group 2	0	29	1	0	29	1
Group 3	0	31	1	0	31	1

<sup>a</sup>Data presented as number of tears.

<sup>b</sup>Increased more than 10% compared with initial magnetic resonance image.

9 patients (28.1%) showed a decrease in tear size, whereas 8 patients (25%) showed an increase and 15 patients (46.9%) showed no change. In group 2 ( $n = 30$ ), 11 patients (36.7%) showed a decrease in tear size (Figure 3), 4 patients (13.3%) showed an increase, and 15 patients (50%) showed no change. In contrast, group 3 ( $n = 32$ ) contained only 2 patients (6.3%) with a decrease in size. Most group 3 patients showed no change (62.5%) or had an increase in size (31.3%) without injection. Decreased tear size was significantly different in group 1 ( $P = .02$ ) and group 2 ( $P = .003$ ) when compared with group 3 but was not significantly different between groups 1 and 2 ( $P = .47$ ). Interobserver intraclass reliability was 0.89, and intraobserver reliability was 0.92.

Changes of muscle volume and fatty infiltration between the initial and follow-up MRI scan are summarized in Table 3. No significant difference was found among the 3 groups for changes of muscle volume or fatty infiltration ( $P > .99$ ).

Functional shoulder scores evaluated at the final follow-up visit showed significant improvement compared with initial scores in groups 1 and 2 but not group 3 (Table 4). The initial functional shoulder scores were not significantly different among the 3 groups (ASES,  $P = .81$ ; Constant,  $P = .72$ ; VAS,  $P = .21$ ). However, groups 1 and 2 showed significantly better functional scores compared with group 3 at the final follow-up visit (ASES: group 1,  $P < .001$ ; group

2,  $P = .01$ ; Constant: groups 1 and 2,  $P < .001$ ; VAS: group 1,  $P = .03$ ; group 2,  $P = .01$ ). No significant differences were found in functional shoulder scores between groups 1 and 2 at the last follow-up visit (ASES,  $P = .63$ ; Constant,  $P = .56$ ; VAS,  $P = .37$ ). No significant differences were found in ROM (forward flexion,  $P = .91$ ; external rotation at side,  $P = .95$ ; external rotation at 90° of abduction,  $P = .49$ ; internal rotation,  $P = .79$ ) among the 3 groups at the final follow-up visit.

## DISCUSSION

We have demonstrated that intratendinous atelocollagen injection for partial-thickness tears led to improvements in functional outcomes and decreased tear size. These results suggest that type I atelocollagen injection inside a supraspinatus tendon tear site deserves consideration as an optional treatment for delaying tear progression and decreasing tear size.

The precise mechanism of tendon healing after injection of atelocollagen is unknown. Some studies have reported immunohistochemical and histopathological results after type I atelocollagen patch or implant. The process of tendon healing involves inflammation, repair, and remodeling in 3 phases. During the final remodeling

TABLE 4  
Changes in Functional Outcomes and ROM Between Preoperative Assessment and Last Follow-up in the 3 Groups<sup>a</sup>

	Group 1			Group 2			Group 3		
	Preoperative	Last	P Value	Preoperative	Last	P Value	Preoperative	Last	P Value
ASES	61.9 ± 13.7	82.5 ± 12.3	<.001	63.5 ± 15.9	79.3 ± 8.3	<.001	62.9 ± 13.5	65.5 ± 8.5	.52
CSS	68.1 ± 10.5	89.0 ± 6.9	<.001	65.8 ± 16.5	82.0 ± 10.1	<.001	68.4 ± 10.5	62.5 ± 11.5	.14
VAS for pain	4.1 ± 2.0	2.1 ± 1.2	.03	3.6 ± 1.6	1.4 ± 1.1	.01	3.4 ± 1.5	3.3 ± 2.5	≥.999
ROM, deg									
FF	140.1 ± 14.1	145.7 ± 10.7	.14	144.1 ± 4.9	148.0 ± 4.5	.50	142.8 ± 6.8	145.3 ± 9.2	.65
ER <sub>a</sub>	84.3 ± 4.6	87.0 ± 5.5	.39	82.9 ± 3.9	89 ± 1.3	.37	86.7 ± 7.6	88.0 ± 5.6	.75
ER <sub>s</sub>	82.6 ± 7.5	85.1 ± 9.5	.41	84.0 ± 8.9	88.3 ± 3.9	.21	84.4 ± 7.3	87.3 ± 7.0	.51
IR	9.1 ± 3.8	10.1 ± 1.3	.55	9.1 ± 4.1	10.9 ± 2.3	.08	9.7 ± 2.1	10.7 ± 2.7	.71

<sup>a</sup>Values are expressed as mean ± SD. ASES, American Shoulder and Elbow Surgeons score; CSS, Constant Shoulder Score; ER<sub>a</sub>, external rotation at 90° of abduction; ER<sub>s</sub>, external rotation at side; FF, forward flexion; IR, internal rotation; ROM, range of motion; VAS, visual analog scale.

phase, scar tissue is formed, remodeling type III to type I collagen.<sup>29</sup> Applying a type I atelocollagen patch at the rotator cuff tendon tear site in a rabbit model led to better tendon healing and earlier progression to the remodeling phase, based on immunohistochemistry.<sup>26</sup> Histopathologically, type I collagen implants facilitated continuity of injured tendons, decreased peritendinous adhesion, and improved muscle activity in Achilles tendons of rabbits.<sup>20</sup> Therefore, we assumed that atelocollagen might contribute to tendon healing through extracellular matrix remodeling.

Spontaneous healing of the torn supraspinatus tendon is unlikely to occur.<sup>5,8,16</sup> Yamaguchi et al<sup>30</sup> found no decrease in tear size among patients with asymptomatic rotator cuff tears when followed by ultrasonography over 5 years. Fukuda<sup>7</sup> reported that partial-thickness rotator cuff tears did not seem to heal spontaneously. Kim et al<sup>16</sup> reported that the tear size was spontaneously decreased in 6.8% of patients with partial-thickness rotator cuff tears without any treatment on follow-up MRI. In the current study, 36.7% of patients who underwent 1.0-mL atelocollagen injection in the torn tendon showed decreased size of the tear. Thus, atelocollagen injection in the torn tendon greatly increased healing in patients with intratendinous rotator cuff tear. Furthermore, functional outcomes of patients with atelocollagen injections were significantly higher at final follow-up than those who did not receive an injection in our study.

To our knowledge, this is the first prospective, randomized clinical trial to evaluate tear size after type I atelocollagen injection for the treatment of partial-thickness rotator cuff tears. We used atelocollagen to promote healing of torn tendons in this study because highly purified atelocollagen has cytocompatible, biocompatible, and biodegradable effects that can influence interactions with extracellular matrix and healing of torn tendons.<sup>26</sup> We enrolled only patients with intratendinous rotator cuff tears to maximize the containment of atelocollagen in the injected rotator cuff. If there were passage in the bursal or articular layer of the rotator cuff tendon, the injected atelocollagen could leak.

Our study has several strengths. This study is the first trial examining the effect of atelocollagen injection on human rotator cuff tendon tears. There has been only 1 animal study using patch-type atelocollagen on the rotator cuffs of rabbits.<sup>26</sup> One study in humans revealed the effectiveness of atelocollagen injection in patients with plantar fasciitis using sonoelastography for imaging.<sup>14</sup> In contrast, we used MRI to precisely assess tendon integrity. Most important, injection of atelocollagen is less time-consuming, more cost-effective, and easier compared with surgery to treat intratendinous rotator cuff tears. This convenient treatment modality can avoid the complications of surgical repair of rotator cuff tears.

This study had several limitations. First, patients in group 3 received no sham injections such as saline or dry needling due to ethical concerns. Thus, this was not a double-blinded study. However, as a prospective comparative cohort study, the results are meaningful because the effects of atelocollagen injection on rotator cuff tendon tears should be compared with natural progression of the torn rotator cuff tendon. Second, the sample size was relatively small and included only small- to medium-sized, intratendinous, partial-thickness supraspinatus tendon tears. Third, the mean follow-up period was relatively short. Follow-up radiological evaluation of the tendons was performed by MRI at least 6 months after injection in our study. Many studies have looked at tendon integrity by MRI at 6 months after treatment,<sup>12,13,28</sup> so we considered radiological examination at 6-month follow-up sufficient to evaluate the integrity of the injected tendon. Fourth, a learning curve was required to accurately inject atelocollagen inside the tear site under ultrasonography. For successful injection, the tear site first needed to be found on the long axis view of the supraspinatus tendon, and the approach of the tip of needle inside the tear site was then guided by ultrasonography. Fifth, the results of our study can be applied to only intratendinous partial tears of the supraspinatus tendon. We did not gather evidence for applying atelocollagen in articular or bursal side partial-thickness tear or full-thickness rotator cuff tears. Sixth, it is difficult to know whether changed signals on MRI

showing decreased tear size actually indicate regeneration of tendon tissue rather than scar tissue formation. Further biological studies are required to determine what leads to changes in signal lesions in the supraspinatus tendon.

## CONCLUSION

Atelocollagen injection can improve the functional outcome and integrity of tendons in intratendinous rotator cuff tears.

## REFERENCES

- Boorman RS, More KD, Hollinshead RM, et al. The rotator cuff quality-of-life index predicts the outcome of nonoperative treatment of patients with a chronic rotator cuff tear. *J Bone Joint Surg Am*. 2014;96(22):1883-1888.
- Boorman RS, More KD, Hollinshead RM, et al. What happens to patients when we do not repair their cuff tears? Five-year rotator cuff quality-of-life index outcomes following nonoperative treatment of patients with full-thickness rotator cuff tears. *J Shoulder Elbow Surg*. 2018;27(3):444-448.
- Chung SW, Kim SH, Tae SK, Yoon JP, Choi JA, Oh JH. Is the supraspinatus muscle atrophy truly irreversible after surgical repair of rotator cuff tears? *Clin Orthop Surg*. 2013;5(1):55-65.
- Ciampi P, Scotti C, Nonis A, et al. The benefit of synthetic versus biological patch augmentation in the repair of posterosuperior massive rotator cuff tears: a 3-year follow-up study. *Am J Sports Med*. 2014;42(5):1169-1175.
- Finnan RP, Crosby LA. Partial-thickness rotator cuff tears. *J Shoulder Elbow Surg*. 2010;19(4):609-616.
- Fuchs B, Weishaupt D, Zanetti M, Hodler J, Gerber C. Fatty degeneration of the muscles of the rotator cuff: assessment by computed tomography versus magnetic resonance imaging. *J Shoulder Elbow Surg*. 1999;8(6):599-605.
- Fukuda H. Partial-thickness rotator cuff tears: a modern view on Codman's classic. *J Shoulder Elbow Surg*. 2000;9(2):163-168.
- Fukuda H. The management of partial-thickness tears of the rotator cuff. *J Bone Joint Surg Br*. 2003;85(1):3-11.
- Greiner S, Ide J, Van Noort A, et al. Local rhBMP-12 on an absorbable collagen sponge as an adjuvant therapy for rotator cuff repair—a phase 1, randomized, standard of care control, multicenter study: safety and feasibility. *Am J Sports Med*. 2015;43(8):1994-2004.
- Hawkins RH, Dunlop R. Nonoperative treatment of rotator cuff tears. *Clin Orthop Relat Res*. 1995;321:178-188.
- Inman VT, Saunders JB, Abbott LC. Observations of the function of the shoulder joint. 1944. *Clin Orthop Relat Res*. 1996;330:3-12.
- Jeong JY, Pan HL, Song SY, Lee SM, Yoo JC. Arthroscopic subscapularis repair using single-row mattress suture technique: clinical results and structural integrity. *J Shoulder Elbow Surg*. 2018;27(4):711-719.
- Jeong JY, Yoon YC, Lee SM, Yoo JC. Arthroscopic incomplete repair using a "hybrid technique" for large to massive rotator cuff tears: clinical results and structural integrity. *Arthroscopy*. 2018;34(7):2063-2073.
- Kim M, Choi YS, You MW, Kim JS, Young KW. Sonoelastography in the evaluation of plantar fasciitis treatment: 3-month follow-up after collagen injection. *Ultrasound Q*. 2016;32(4):327-332.
- Kim YS, Chung SW, Kim JY, Ok JH, Park I, Oh JH. Is early passive motion exercise necessary after arthroscopic rotator cuff repair? *Am J Sports Med*. 2012;40(4):815-821.
- Kim YS, Kim SE, Bae SH, et al. Tear progression of symptomatic full-thickness and partial-thickness rotator cuff tears as measured by repeated MRI. *Knee Surg Sports Traumatol Arthrosc*. 2017;25(7):2073-2080.
- Kim YS, Lee HJ, Park I, Im JH, Park KS, Lee SB. Are delayed operations effective for patients with rotator cuff tears and concomitant stiffness? An analysis of immediate versus delayed surgery on outcomes. *Arthroscopy*. 2015;31(2):197-204.
- Lynn AK, Yannas IV, Bonfield W. Antigenicity and immunogenicity of collagen. *J Biomed Mater Res B Appl Biomater*. 2004;71(2):343-354.
- Maman E, Harris C, White L, Tomlinson G, Shashank M, Boynton E. Outcome of nonoperative treatment of symptomatic rotator cuff tears monitored by magnetic resonance imaging. *J Bone Joint Surg Am*. 2009;91(8):1898-1906.
- Meimandi-Parizi A, Oryan A, Moshiri A. Role of tissue engineered collagen based tridimensional implant on the healing response of the experimentally induced large Achilles tendon defect model in rabbits: a long term study with high clinical relevance. *J Biomed Sci*. 2013;20:28.
- Minabe M, Kodama T, Hori T, Watanabe Y. Effects of atelocollagen on the wound healing reaction following palatal gingivectomy in rats. *J Periodontol Res*. 1989;24(3):178-185.
- Miyata T, Taira T, Noishiki Y. Collagen engineering for biomaterial use. *Clin Mater*. 1992;9(3-4):139-148.
- Pins GD, Christiansen DL, Patel R, Silver FH. Self-assembly of collagen fibers: influence of fibrillar alignment and decorin on mechanical properties. *Biophys J*. 1997;73(4):2164-2172.
- Schulze-Tanzil G, Mobasher A, Clegg PD, Sendzik J, John T, Shaki-baei M. Cultivation of human tenocytes in high-density culture. *Histochem Cell Biol*. 2004;122(3):219-228.
- Shrout PE, Fleiss JL. Intraclass correlations: uses in assessing rater reliability. *Psychol Bull*. 1979;86(2):420-428.
- Suh DS, Lee JK, Yoo JC, et al. Atelocollagen enhances the healing of rotator cuff tendon in rabbit model. *Am J Sports Med*. 2017;45(9):2019-2027.
- Thomazeau H, Rolland Y, Lucas C, Duval JM, Langlais F. Atrophy of the supraspinatus belly: assessment by MRI in 55 patients with rotator cuff pathology. *Acta Orthop Scand*. 1996;67(3):264-268.
- Walsh MR, Nelson BJ, Braman JP, et al. Platelet-rich plasma in fibrin matrix to augment rotator cuff repair: a prospective, single-blinded, randomized study with 2-year follow-up. *J Shoulder Elbow Surg*. 2018;27(9):1553-1563.
- Weeks KD III, Dines JS, Rodeo SA, Bedi A. The basic science behind biologic augmentation of tendon-bone healing: a scientific review. *Instr Course Lect*. 2014;63:443-450.
- Yamaguchi K, Tetro AM, Blam O, Evanoff BA, Teefey SA, Middleton WD. Natural history of asymptomatic rotator cuff tears: a longitudinal analysis of asymptomatic tears detected sonographically. *J Shoulder Elbow Surg*. 2001;10(3):199-203.
- Zanetti M, Gerber C, Hodler J. Quantitative assessment of the muscles of the rotator cuff with magnetic resonance imaging. *Invest Radiol*. 1998;33(3):163-170.