


# Intravitreal Faricimab for Previously Treated Neovascular Age-Related Macular Degeneration

Abraham Hang, Taylor Ngo, Jaipreet Singh Virk, Kareem Moussa, Ala Moshiri, Parisa Emami-Naeini, Susanna S Park 

Department of Ophthalmology & Vision Science, University of California Davis Eye Center, Sacramento, CA, USA

Correspondence: Susanna S Park, Department of Ophthalmology & Vision Science, University of California Davis Eye Center, Ernest E. Tschannen Eye Institute, 4860 Y Street, Sacramento, CA, 95817, USA, Tel +1-916-734-6080, Email [sscpark@ucdavis.edu](mailto:sscpark@ucdavis.edu)

**Purpose:** To report our real-world experience using intravitreal faricimab, a novel anti-vascular endothelial growth factor (anti-VEGF) therapy, in eyes with neovascular age-related macular degeneration (nAMD) previously treated with other anti-VEGF therapy.

**Patients and Methods:** A retrospective, single-center study of previously treated nAMD eyes treated with faricimab.

**Results:** In 88 eyes (73 patients), mean baseline best-corrected visual acuity (BCVA) was 20/63 (range 20/20 to CF) with mean anti-VEGF injection interval of  $6.1 \pm 2.0$  weeks. Mean baseline central subfield thickness (CST) was  $291 \pm 73$   $\mu\text{m}$ . During mean follow-up of  $30.1 \pm 13.5$  (range 7.0 to 50.3) weeks on faricimab, the eyes received an average of  $5.1 \pm 2.4$  injections (range 1 to 11). Mean BCVA remained at 20/63 ( $p=0.11$ ), but injection interval increased to  $7.4 \pm 2.6$  weeks ( $p<0.001$ ), and CST decreased to  $262 \pm 63$   $\mu\text{m}$  ( $p<0.001$ ). Multiple linear regression analysis revealed that higher number of different anti-VEGF drugs used at baseline was associated with a lower decrease in CST on faricimab ( $p=0.04$ ) while total number of anti-VEGF injections at baseline ( $p=0.56$ ) and time on faricimab ( $p=0.68$ ) were not associated. Faricimab was discontinued in 23 eyes (26.1%), including 8 eyes for poor response, 2 eyes for persistent new floaters and 4 eyes for new vision decrease which reversed after stopping faricimab.

**Conclusion:** In previously treated nAMD eyes, intravitreal faricimab was associated with increased mean treatment interval and decreased CST but no improvement in mean BCVA. The benefit of faricimab on CST reduction may be diminished in eyes previously treated with multiple different types of anti-VEGF therapy.

**Keywords:** anti-VEGF therapy, intravitreal therapy, real-world experience, central subfield thickness, optical coherence tomography

## Introduction

The most common cause of irreversible blindness in the developed world is age-related macular degeneration (AMD). It is projected that by 2040, there will be over 300 million people in the world with AMD.<sup>1</sup> Intravitreal anti-vascular endothelial growth factor (anti-VEGF) therapy has become a mainstay in treatment of neovascular age-related AMD (nAMD). It inhibits bleeding and exudation associated with choroidal neovascularization (CNV), thereby limiting vision loss. The number of anti-VEGF medications that can be used as therapy continues to grow, as several new medications have been approved by the Food and Drug Administration (FDA) in recent years.<sup>2</sup> Several other new drugs aiming to increase durability and efficacy are undergoing clinical trials.<sup>2</sup>

Intravitreal faricimab is one of the newest anti-VEGF agents to receive FDA approval. In 2022, this drug was approved for treatment of diabetic macular edema (DME) and nAMD,<sup>3</sup> it was also approved for treatment of macular edema associated with retinal vein occlusion (RVO) in 2023.<sup>4</sup> Faricimab is a bispecific antibody that targets VEGF-A and Angiopoietin-2 (Ang-2). Ang-2 is a pro-angiogenic factor that plays a role in vascular leakage and inflammation; it is theorized to play a complementary or even synergistic role with VEGF in nAMD or macular edema from retinal vasculopathy.<sup>3,5</sup> The TENAYA and LUCERNE Phase III clinical trials demonstrated non-inferiority of intravitreal faricimab compared to intravitreal aflibercept in treatment of eyes with treatment-naïve nAMD in terms of best corrected visual acuity (BCVA).<sup>6</sup> At week 48, approximately 80% of study eyes treated with faricimab in both trials could have

their treatment interval extended to 12 or 16 week. In contrast, eyes treated with aflibercept had treatment interval maintained at 8 weeks for the study duration as per study protocol. Although these studies were not designed to compare durability of faricimab vs aflibercept, the study observations highlight the potential durability of intravitreal faricimab therapy.

Since TENAYA and LUCERNE phase III clinical trials included only treatment-naïve eyes with nAMD, this study was conducted to evaluate real-world experience using intravitreal faricimab in treating eyes with nAMD previously treated with other anti-VEGF therapies. This will provide information regarding the relative efficacy and durability of intravitreal faricimab when compared to other available anti-VEGF therapies. This is a single-center retrospective study of all eyes treated with intravitreal faricimab for nAMD after being on other anti-VEGF therapy. We evaluated visual and anatomic outcomes of these eyes on faricimab therapy when compared to baseline.

## Material and Methods

This study included all patients with nAMD that received faricimab therapy between August 2020 and November 2023 at the Department of Ophthalmology and Vision Science, University of California Davis Health, Sacramento, California. Ethical approval of the study protocol and waiver of patient informed consent was obtained from the Office of Human Research (Institutional Review Board) at the University of California, Davis Health as this retrospective study involved minimal risk to participants. All data was de-identified and stored securely with access restricted to authorized personnel only. This study complied with accepted-standard research guidelines set forth by the Declaration of Helsinki.

The study population included all patients diagnosed with nAMD who initiated faricimab therapy, had previously been treated with another anti-VEGF agent, and exhibited intraretinal and/or subretinal fluid on optical coherence tomography (OCT) within 6 months prior to their first faricimab injection. A 6-month cutoff was used to capture patients with inadequate control of their nAMD but may have visits with intermittent resolution of the fluid on OCT. Patients were excluded if they had a concurrent diagnosis that they were also receiving intravitreal anti-VEGF injections for. To obtain outcome information, only eyes with at least one follow-up visit after switching to faricimab were included. All eyes with nAMD were treated using a treat-and-extend protocol on anti-VEGF therapy, without a loading dose. The treatment interval was extended by 1 to 2 weeks at the discretion of the treating retina physician, both prior to and after switching to faricimab, once maximum improvement in OCT and BCVA was achieved.

Patient demographics, including age, sex, and history of concurrent or past retinal conditions, were obtained from the electronic medical record. Clinical data collected included BCVA, macular OCT central subfield thickness (CST), and presence or absence of intraretinal fluid (IRF) or subretinal fluid (SRF) at both the initial faricimab injection visit and the final visit. Information on the number of faricimab injections and injection interval at the last visit was also collected. Additionally, reasons for switching from the previous anti-VEGF therapy were recorded.

To evaluate drug safety, data collected included number and types of ocular adverse effects on faricimab treatment, in addition to information on all eyes where faricimab was discontinued and reason for discontinuation.

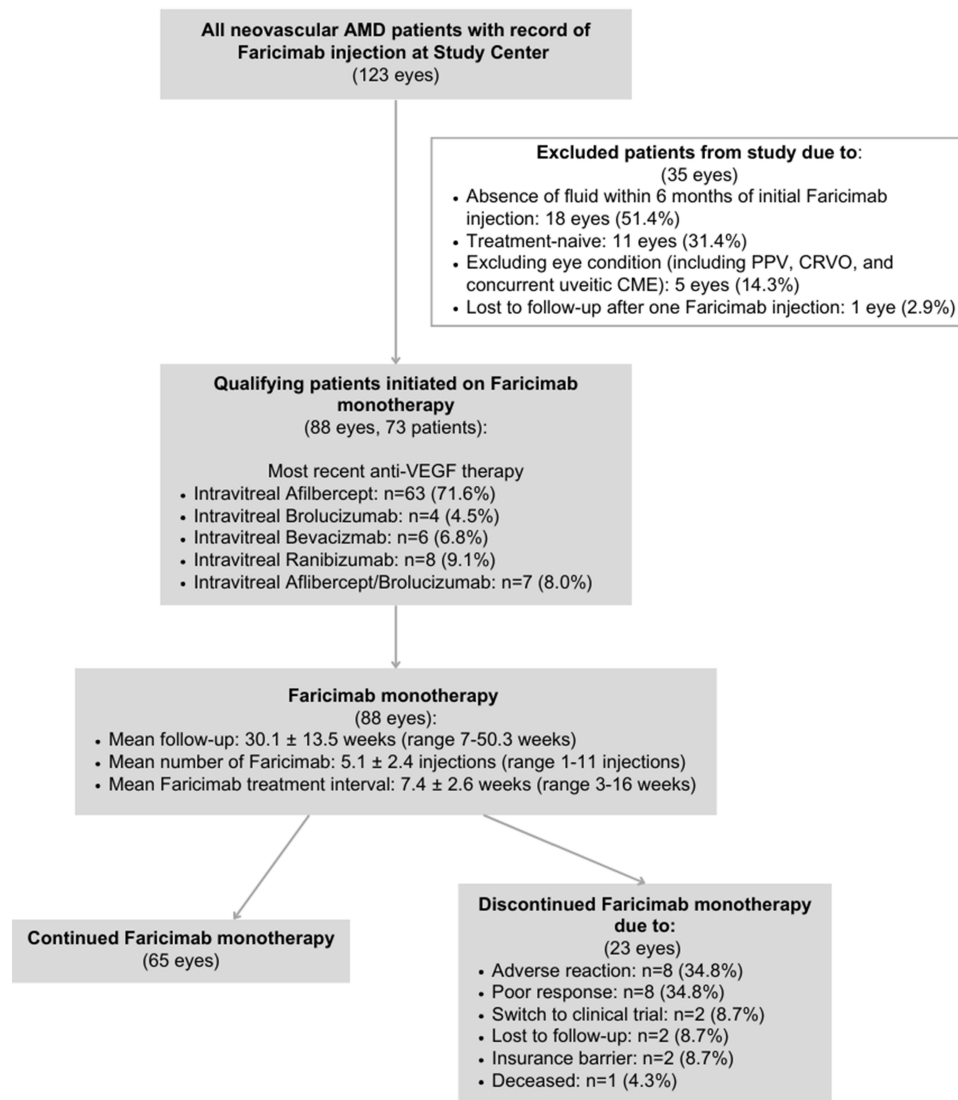
## Statistical Analysis

Summary statistics were generated to describe patient demographic and clinical characteristics of our study population. Paired *t*-tests were used to compare BCVA and CST before and after starting faricimab. A multiple linear regression model was used to evaluate factors associated with a decrease in CST. Tests for multicollinearity were performed using variance inflation factor values, and tests for clustering were performed by confirming there were no significant changes in results when one eye was removed in a patient with both eyes included in the study.

## Results

### Patient Population

A total of 123 eyes were identified as having been treated with faricimab at the study center during the study period, and 35 eyes were excluded (Figure 1). Of the 35 excluded eyes, 18 eyes had nAMD but no demonstrated fluid on OCT in the past 6 months, 11 eyes had treatment-naïve nAMD, 5 eyes had pre-existing ocular condition (pars plana vitrectomy,



**Figure 1** Flow diagram summarizing the distribution of eyes with neovascular age-related macular degeneration on faricimab identified in the study center and selection of the study eyes.

concurrent central retinal vein occlusion, and concurrent uveitic cystoid macular edema), and 1 eye received one faricimab injection without follow-up.

After excluding those eyes, 88 eyes (73 patients) fit our study inclusion criteria. All 88 study eyes had intraretinal or subretinal fluid on OCT within 6 months prior to starting faricimab (Table 1) and had been treated with other anti-VEGF therapy. 14.8% of eyes had no IRF/SRF on OCT at baseline visit. The indication for starting faricimab therapy was for treatment of recalcitrant IRF/SRF fluid on OCT and/or desire to extend treatment interval. Average age was  $82 \pm 9$  (range 57–101), and 65.9% were female. The average number and duration of anti-VEGF therapy prior to starting faricimab were 27.5 injections (range 1–127) and 41.9 months (range 1–169), respectively. Among these 88 eyes, 24 eyes (27.3%) had been treated with one anti-VEGF medication prior to starting faricimab, 47 eyes (53.4%) had been on two different anti-VEGF drugs, 12 eyes (13.6%) had been treated with three different anti-VEGF drugs, and 5 eyes (5.7%) had been on four different anti-VEGF drugs at baseline. The four different anti-VEGF medications used prior to starting faricimab included bevacizumab, aflibercept, ranibizumab, and brolucizumab. Prior to switching to faricimab, 63 eyes (71.6%) were on aflibercept, 8 eyes (9.1%) were on ranibizumab, 6 eyes (6.8%) were on bevacizumab, 4 eyes (4.5%) were on brolucizumab, and 7 eyes (8%) were on a monthly treatment alternating between aflibercept and brolucizumab.

**Table 1** Demographic and Baseline Clinical Feature of Eyes with nAMD Treated with Faricimab

<b>Total number of eyes (patients)</b>	88 (73)
<b>Mean age, years (SD)</b>	82 (9)
<b>Sex (%)</b>	
Female	58 (65.9)
Male	30 (34.1)
<b>Laterality (%)</b>	
Right	45 (51.1)
Left	43 (48.9)
<b>Most recent anti-VEGF therapy prior to switch (%)</b>	
Aflibercept	63 (71.6)
Brolucizumab	4 (4.5)
Bevacizumab	6 (6.8)
Ranibizumab	8 (9.1)
Alternating Aflibercept/Brolucizumab	7 (8.0)
<b>Mean duration of prior anti-VEGF therapy, months (SD), range</b>	41.9 (39.4) 1–169
<b>Mean number of injections of prior anti-VEGF therapy, (SD), range</b>	27.5 (26.6) 1–127
<b>Indication for switch to faricimab (%)</b>	
Persistent macular fluid	31 (35.2)
Treatment interval extension	35 (40.7)
Both	22 (25)
<b>Number of different anti-VEGF therapies used prior to faricimab (%)</b>	
1	24 (27.3)
2	47 (53.4)
3	12 (13.6)
4	5 (5.7)
<b>Baseline macular fluid status (%)</b>	
Subretinal fluid (SRF) only	38 (43.2)
Intraretinal fluid (IRF) only	24 (27.3)
Concurrent SRF and IRF	13 (14.8)
No fluid	13 (14.8)

**Abbreviations:** nAMD, neovascular age-related macular degeneration; SD, standard deviation; anti-VEGF, drugs that inhibit vascular endothelial growth factor; SRF, subretinal fluid; IRF, intraretinal fluid; OCT, optical coherence tomography.

## Anatomic and Visual Outcomes

Table 2 summarizes the anatomical and visual outcomes in the study eyes before and after starting faricimab. Mean baseline logMAR BCVA prior to starting faricimab was  $0.5 \pm 0.3$  (Snellen equivalent 20/63) with a mean anti-VEGF injection interval of  $6.06 \pm 2.0$  weeks (range 4–15 weeks). On macular OCT, the mean baseline CST was  $291 \pm 73$   $\mu\text{m}$ . All patients had either subretinal or intraretinal fluid on at least one OCT within 6 months prior to starting faricimab. At the baseline visit when faricimab was initiated, 38 (43.2%) patients had subretinal fluid (SRF), 24 (27.3%) had intraretinal fluid (IRF), 13 (14.8%) had both, and 13 (14.8%) had no fluid (Table 1). One eye had no OCT done at the baseline visit, so the most recent OCT from the prior visit was used for analysis since the patient had been maintained on the same anti-VEGF therapy. In addition, CST was not available in 1 patient in 2 eyes at both baseline and follow-up due to poor patient cooperation with imaging, resulting in only a 5-line raster scan being obtained. For this OCT, an estimate of the CST was obtained by manual measurements of 5 points from the internal limiting membrane to Bruch's membrane at the center of the fovea and 0.5 mm superior, inferior, nasal, and temporal, and taking the average. In 1 eye at follow-up, a CST could not be obtained due to poor OCT signal with an erroneous CST reading and was not included in the analysis.

**Table 2** Anatomical and Visual Acuity in the Study Eyes Before and After Starting Faricimab

	Study eyes on Faricimab (n=88)		
	Baseline	Final follow-up	p-value*
Mean BCVA (logMAR), (SD)	0.5±0.3	0.5±0.4	0.11
Mean CST (µm), (SD)	291±73	262±63	<0.001
Mean treatment interval, weeks (SD)	6.06±2.0	7.44±2.6	<0.001
Mean number of Faricimab injections (SD)	5.1±2.4		

**Abbreviations:** BCVA, best corrected visual acuity; CST, central subfield thickness; SD, standard deviation.

\*p-value based on paired student t test.

During a mean follow-up of 30.1±13.5 weeks (range 7.0 to 50.3 weeks) after starting faricimab, the study eyes received a mean of 5.1±2.4 injections (range 1–11). At the latest visit, mean logMAR BCVA remained at 0.5±0.4 (Snellen equivalent 20/63) (p=0.11), but mean injection interval increased by 1.38 weeks to 7.44±2.6 weeks (p<0.001), and mean CST decreased to 262±63 µm (p<0.001) with an average decrease of 28.3 µm in CST (Table 2). At last study visit, 25 (28.4%) eyes had SRF, 22 (25.0%) eyes had IRF, 6 (6.8%) had both, 35 (39.8%) had no fluid. Of the 75 eyes with fluid on OCT at baseline, 27 (36%) had complete resolution of IRF/SRF at the latest visit on faricimab, and 47 (64%) had persistent intraretinal or subretinal fluid.

Multiple linear regression analysis revealed that the total number of anti-VEGF injections at baseline was not significantly associated with CST reduction after initiating faricimab (p=0.56), and neither was the amount of time on faricimab (p=0.68). However, higher number of different types of anti-VEGF drugs used before starting faricimab was significantly associated with a lesser decrease in CST after starting faricimab (p=0.04).

## Safety

Faricimab was discontinued in 23 eyes (19 patients) (26%). Eight eyes (35%) were switched to a different anti-VEGF drug due to poor response on faricimab, 2 eyes (9%) were switched due to joining a clinical trial, 2 eyes (9%) were switched due to insurance barriers, 2 eyes (9%) were discontinued due to loss to follow-up, and 1 patient became deceased during this time period.

Faricimab was stopped in 8 eyes (9.1%) due to adverse events, including eye irritation (2 eyes in 1 patient), persistent new floaters (2 eyes in 2 patients) and new subjective vision loss (4 eyes in 3 patients). 2 patients (2 eyes) with new floaters had persistent floaters lasting up to 9 to 11 weeks and occurring after the first or second faricimab injection. Both patients declined further treatment with faricimab. All 3 patients with subjective vision loss after starting faricimab had measured vision loss after 1 or 2 faricimab injections with no new change on eye exam or worsening of fluid on OCT to explain the vision loss. All 3 patients had at least partial improvement in vision after stopping faricimab and resuming treatment with other anti-VEGF therapy. These 3 patients are described in more detail below.

The first patient is an 81-year-old monocular woman with nAMD in the right eye who received one dose of faricimab. She had previously been treated with monthly alternating doses of brolucizumab and aflibercept. When seen 5 weeks later, her BCVA had improved from 20/70 to 20/50 with an unchanged exam and OCT. However, she noted multiple new scotomas in her central vision starting a few days after the faricimab injection. She declined further treatment with faricimab and was switched to brolucizumab. The following month, her BCVA dropped to 20/150. She subsequently underwent cataract surgery and BCVA improved to 20/20 while being maintained on alternating doses of brolucizumab and aflibercept. The blind spots fully resolved over a couple months after discontinuing faricimab.

The second patient had nAMD in both eyes, with an end-stage disciform scar in the left eye. Her right eye had been treated with monthly alternating doses of brolucizumab and aflibercept and was switched to faricimab for chronic mild residual IRF and to extend treatment interval. Five weeks after the second dose of faricimab, she noted new vision loss,

with her BCVA dropping from 20/100 to 20/300. Her eye exam and OCT were unchanged. Faricimab was discontinued, and the patient was restarted on alternating brolocizumab and aflibercept. Her BCVA returned to baseline 4 weeks later.

The third patient is a 94-year-old woman with nAMD in both eyes and trace IRF in both eyes on aflibercept every 5 weeks. She was started on faricimab in both eyes for residual fluid and to extend the treatment interval. Four weeks after receiving one dose of faricimab, she noted new blurry vision in both eyes. Her BCVA declined in both eyes to 20/400 from 20/100 in the right eye and 20/150 in the left eye, with stable OCT OU and eye exam findings. Faricimab was discontinued, and aflibercept was restarted in both eyes. Over the next 3 months, BCVA gradually improved to 20/200 in both eyes.

## Discussion

Due to advances in drug development, we have a growing number of anti-VEGF drugs that can be administered intravitreally for treatment of nAMD. All of these drugs are effective in reducing vision loss associated with complications of CNV. However, the effects of all anti-VEGF drugs are reversible and require frequent, often indefinite, intravitreal injections to maintain therapeutic effect. In addition, some eyes with nAMD become resistant to anti-VEGF therapy, requiring higher frequency dosing, sometimes as often as 4 weeks. Even then, some eyes with nAMD may become recalcitrant to anti-VEGF therapy with persistent macular fluid on OCT. Persistent residual intraretinal fluid in eyes with nAMD on anti-VEGF therapy has been associated with poorer visual outcome.<sup>7</sup>

It is not entirely clear why certain eyes with nAMD have macular fluid that is resistant to anti-VEGF treatments. A couple of studies have suggested that presence of pigment epithelial detachment, large choroidal neovascular membrane (CNV), and type 1 CNV or non-classic CNV may be associated with poorer response to treatment with ranibizumab or bevacizumab.<sup>8,9</sup> Other studies have shown that nAMD eyes that do not demonstrate a reduction in CST on OCT after 4 weeks on anti-VEGF therapy may have a significant response on OCT that can be detected at 2 or 3 weeks, indicating that the eye is responding to therapy but with shorter duration of effect than expected.<sup>10</sup> The percentage of “non-responders” to intravitreal anti-VEGF therapy is significant and can be as high as 45% depending on the study population, type of anti-VEGF therapy, and how “non-response” is defined.<sup>8,9,11</sup> As such, anti-VEGF agents with greater durability and efficacy are highly desirable for both patients and providers.

The TENAYA and LUCERNE phase III clinical trials for faricimab demonstrated non-inferiority of faricimab to aflibercept in terms of BCVA in treating newly diagnosed nAMD. In these trials, 80% of eyes on faricimab had treatment interval extended to 12 or 16 weeks, while all eyes on aflibercept were maintained at a treatment interval of 8 weeks as per study protocol. This finding suggests that faricimab may have long durability.<sup>6</sup> However, TENAYA and LUCERNE studies were not designed to evaluate superiority of faricimab over aflibercept. In addition, these studies enrolled only treatment-naïve nAMD eyes.

It is well-recognized that clinical trial data with well-defined study criteria often result in better outcomes in comparison to real-world data.<sup>12–16</sup> Thus, our study was conducted to evaluate real-world experience using intravitreal faricimab in nAMD eyes previously treated with other anti-VEGF therapies. In our study, we selected only eyes with nAMD that had demonstrated recalcitrant IRF/SRF on OCT within the 6 months prior to initiation of faricimab. At the time of switching to faricimab, most eyes (85%) had persistent IRF/SRF on OCT in the study eye on maximum anti-VEGF therapy. After starting faricimab treatment, the number of eyes in our study with no IRF/SRF increased from 14.8% to 40.2%. A statistically significant reduction in mean CST was observed at the last follow-up visit on faricimab compared to baseline visit before starting faricimab. We also found a significant increase in the treatment interval at the last visit on faricimab compared to baseline. Faricimab therapy resulted in a mean increase of 1.3 weeks in treatment interval when compared to the treatment interval on other anti-VEGF therapies. These findings support the hypothesis that faricimab may have a longer duration of effect and greater efficacy in treating eyes with nAMD compared to other currently available anti-VEGF therapies.

In our study, we used multiple linear regression analysis to identify baseline clinical features that may be associated with improved response on faricimab. We found that the benefit of faricimab in reducing CST in eyes with nAMD previously treated with other anti-VEGF may depend on the number of different anti-VEGF drugs used prior to starting faricimab. In particular, the benefit of faricimab may be diminished in eyes that had been on multiple types of anti-VEGF

medications ( $p=0.04$ ). This benefit of using faricimab was not affected by the total number of anti-VEGF injections administered prior to switching to faricimab, and was also not affected by the amount of time on faricimab. This is noteworthy because a majority of our study eyes had  $> 10$  anti-VEGF injections, with a mean of 27 injection, prior to starting faricimab; most study eyes had been treated with at least 2 different anti-VEGF drugs before starting faricimab. Eyes treated with multiple other anti-VEGF agents before starting faricimab in our study population likely represent eyes that are most resistant to anti-VEGF therapy.

Despite improvement in IRF/SRF and mean CST on OCT on faricimab, there were no significant changes in BCVA on faricimab therapy when compared to baseline in our study population. This is in contrast to the TENAYA and LUCERNE clinical trials, which showed a mean improvement in BCVA after starting faricimab or aflibercept in treatment-naïve eyes with nAMD. Our study finding is not unexpected, as all the eyes in our study had already been on anti-VEGF therapy. Gain in BCVA on anti-VEGF therapy in eyes with nAMD is usually seen in the first 3 to 4 months after treatment initiation. In eyes with nAMD with chronic macular fluid, it has been shown that vision loss and structural macular damage can result.<sup>17</sup> In addition, prior long-term follow-up studies have demonstrated that in eyes with nAMD being treated with anti-VEGF therapy, BCVA gain that is initially noted with anti-VEGF treatment is often lost due to disease progression and progression of geographic atrophy.<sup>14,16</sup>

Our study findings are consistent with several other real-world outcome studies on faricimab in previously treated eyes with nAMD.<sup>18–20</sup> These studies, including the TRUCKEE study,<sup>21</sup> showed that, on average, switching to faricimab improved anatomic outcome on OCT, as indicated by a reduction in CST, IRF and SRF.<sup>18–20</sup> However, this benefit was not observed in all eyes in our study and another real-world study by Rush.<sup>22</sup> In our study, we performed multiple linear regression analysis to determine factors that may predict eyes that will respond less well to a switch in therapy to faricimab. We found that eyes previously treated with a higher number of different anti-VEGF therapies tended to experience less additional benefit after switching to faricimab.

The potential superior efficacy of faricimab in decreasing CST and increasing treatment intervals when compared to other anti-VEGF drugs is attributed to its novel dual inhibition of VEGF and Ang-2. In neovascular diseases, such as nAMD, multiple pro-angiogenic and inflammatory proteins and signaling factors may play a role in pathogenesis. Ang-2 is involved in vascular stability, inflammation, pericyte apoptosis, and changes in the endothelial cell cytoskeleton, which leads to vascular instability.<sup>22–24</sup> Thus, inhibition of Ang-2 is thought to have a complementary, or perhaps synergistic effect to anti-VEGF in decreasing angiogenesis and vascular permeability.

Our study also evaluated safety of faricimab therapy in real world patients with nAMD previously treated with other anti-VEGF agents. The TENAYA and LUCERNE trials for nAMD demonstrated a non-inferior safety profile compared to aflibercept for serious ocular adverse events.<sup>6</sup> However, there is a theoretical risk of new adverse events from using faricimab, which blocks new pathways in addition to VEGF-A.<sup>22</sup> In our study, a few patients experienced vision loss or changes soon after starting faricimab. This has not been reported previously in other real-world studies.<sup>18–20,25</sup> These patients had a decrease in BCVA in the treated eye without significant change on OCT or examination to explain the vision loss. Fortunately, all these patients in our study had gradual recovery of vision and resolution of symptoms after stopping faricimab and switching back to their prior anti-VEGF treatment regimen. It is unclear whether these visual changes could be related to effects of faricimab in modulating ang-2. As we gain more real-world experience using faricimab, we can learn more about potential adverse effects of this new therapy. Recently, there was a report of severe vision loss in 3 eyes with nAMD from severe intraocular inflammation after starting faricimab treatment.<sup>26</sup> In our study eyes, no intraocular inflammation was observed.

The limitations of our study include the limited sample size as well as the retrospective study design. Although the treat-and-extend regimen was used by all participating retinal specialists, it varied slightly based on the physician as well as the patient's history of response to prior anti-VEGF therapy. In addition, all study eyes had IRF and/or SRF within 6 months of starting faricimab, but only 14.8% of study eyes had no IRF or SRF on OCT at baseline. Despite this, our study found a significant reduction in mean macular thickness after starting faricimab.

In summary, this study provides additional real-world data and insights on treatment outcomes using faricimab in eyes with nAMD previously treated with other anti-VEGF agents. Faricimab demonstrates improved anatomical outcomes in patients with nAMD while decreasing the frequency of injections. The benefit of faricimab over other anti-VEGF

therapies may be diminished in eyes with nAMD that have been refractory to multiple different types of anti-VEGF therapies. Faricimab appears to be well tolerated in most eyes, but a few eyes had new vision change or worsening soon after starting faricimab despite stable exam and OCT; these changes appear to resolve after stopping faricimab. Since faricimab is a relatively new therapy for nAMD, future larger studies are important to fully characterize the efficacy, safety, and long-term effects of faricimab in eyes with nAMD.

## Funding

This work was supported in part by the Barbara A and Alan M Roth MD Endowed Chair in Visual Science from the University of California Davis (S.S.P.). There was no other funding support.

## Disclosure

S.S.P. has received contracted research grants via an employer from the industry to investigate anti-VEGF therapy for retinal disorders (Allergan, Greybug, Ophthea Ltd., Roche/Novartis, Eyepoint). P.E. is a consultant for Genentech. None of the other authors have any conflicts of interest to report.

## References

1. Vyawahare H, Shinde P. Age-Related Macular Degeneration: epidemiology, Pathophysiology, Diagnosis, and Treatment. *Cureus*. 2022;14(9):e29583. doi:10.7759/cureus.29583
2. Hang A, Feldman S, Amin AP, Ochoa JAR, Park SS. Intravitreal Anti-Vascular Endothelial Growth Factor Therapies for Retinal Disorders. *Pharmaceuti*. 2023;16(8). doi:10.3390/ph16081140
3. Shirley M. Faricimab: first Approval. *Drugs*. 2022;82(7):825–830. doi:10.1007/s40265-022-01713-3
4. FDA Approves Genentech's Vabysmo for the Treatment of Retinal Vein Occlusion (RVO); 2023. Available from: <https://www.gene.com/media/press-releases/15009/2023-10-26/fda-approves-genentechs-vabysmo-for-the->. Accessed December 10, 2024
5. Khanani AM, Russell MW, Aziz AA, et al. Angiopoietins as Potential Targets in Management of Retinal Disease. *Clin Ophthalmol*. 2021;15:3747–3755. doi:10.2147/oph.S231801
6. Heier JS, Khanani AM, Quezada Ruiz C, et al. Efficacy, durability, and safety of intravitreal faricimab up to every 16 weeks for neovascular age-related macular degeneration (TENAYA and LUCERNE): two randomised, double-masked, Phase 3, non-inferiority trials. *Lancet*. 2022;399(10326):729–740. doi:10.1016/s0140-6736(22)00010-1
7. Core JQ, Pistilli M, Hua P, et al. Predominantly Persistent Intraretinal Fluid in the Comparison of Age-related Macular Degeneration Treatments Trials. *Ophthalmol Retina*. 2022;6(9):771–785. doi:10.1016/j.oret.2022.03.024
8. Suzuki M, Nagai N, Izumi-Nagai K, et al. Predictive factors for non-response to intravitreal ranibizumab treatment in age-related macular degeneration. *Br J Ophthalmol*. 2014;98(9):1186–1191. doi:10.1136/bjophthalmol-2013-304670
9. Lux A, Llacer H, Heussen FM, Jousseaume AM. Non-responders to bevacizumab (Avastin) therapy of choroidal neovascular lesions. *Br J Ophthalmol*. 2007;91(10):1318–1322. doi:10.1136/bjo.2006.113902
10. Bontzos G, Bagheri S, Ioanidi L, et al. Nonresponders to Ranibizumab Anti-VEGF Treatment Are Actually Short-term Responders: a Prospective Spectral-Domain OCT Study. *Ophthalmol Retina*. 2020;4(12):1138–1145. doi:10.1016/j.oret.2019.11.004
11. Krebs I, Glittenberg C, Ansari-Shahrezaei S, Hagen S, Steiner I, Binder S. Non-responders to treatment with antagonists of vascular endothelial growth factor in age-related macular degeneration. *Br J Ophthalmol*. 2013;97(11):1443–1446. doi:10.1136/bjophthalmol-2013-303513
12. Schmidt-Erfurth U, Kaiser PK, Korobelnik JF, et al. Intravitreal aflibercept injection for neovascular age-related macular degeneration: ninety-six-week results of the VIEW studies. *Ophthalmology*. 2014;121(1):193–201. doi:10.1016/j.ophtha.2013.08.011
13. Brown DM, Michels M, Kaiser PK, Heier JS, Sy JP, Ianchulev T. Ranibizumab versus verteporfin photodynamic therapy for neovascular age-related macular degeneration: two-year results of the ANCHOR study. *Ophthalmology*. 2009;116(1):57–65.e5. doi:10.1016/j.ophtha.2008.10.018
14. Maguire MG, Martin DF, Ying GS, et al. Five-Year Outcomes with Anti-Vascular Endothelial Growth Factor Treatment of Neovascular Age-Related Macular Degeneration: the Comparison of Age-Related Macular Degeneration Treatments Trials. *Ophthalmology*. 2016;123(8):1751–1761. doi:10.1016/j.ophtha.2016.03.045
15. Khanani AM, Gahn GM, Koci MM, Dang JM, Brown SM, Hill LF. Five-year outcomes of intravitreal drug therapy for neovascular age-related macular degeneration in eyes with baseline vision 20/60 or better. *Clin Ophthalmol*. 2019;13:347–351. doi:10.2147/oph.S191170
16. Rofagha S, Bhisitkul RB, Boyer DS, Sadda SR, Zhang K. Seven-year outcomes in ranibizumab-treated patients in ANCHOR, MARINA, and HORIZON: a multicenter cohort study (SEVEN-UP). *Ophthalmology*. 2013;120(11):2292–2299. doi:10.1016/j.ophtha.2013.03.046
17. Metrangola C, Donati S, Mazzola M, et al. OCT Biomarkers in Neovascular Age-Related Macular Degeneration: a Narrative Review. *J Ophthalmol*. 2021;2021:9994098. doi:10.1155/2021/9994098
18. Raimondi R, Falfeli T, Bogdanova-Bennet A, et al. Real-world outcomes of treatment resistant neovascular-age related macular degeneration switched from Aflibercept to Faricimab. *Ophthalmol Retina*. 2023. doi:10.1016/j.oret.2023.11.015
19. Pandit SA, Momenaie B, Wakabayashi T, et al. Clinical Outcomes of Faricimab in Patients with Previously Treated Neovascular Age-Related Macular Degeneration. *Ophthalmol Retina*. 2023. doi:10.1016/j.oret.2023.10.018
20. Szigiato A, Mohan N, Talcott KE, et al. Short-Term Outcomes of Faricimab in Patients with Neovascular Age-Related Macular Degeneration on Prior Anti-VEGF Therapy. *Ophthalmol Retina*. 2024;8(1):10–17. doi:10.1016/j.oret.2023.08.018
21. Khanani AM, Aziz AA, Khan H, et al. The real-world efficacy and safety of faricimab in neovascular age-related macular degeneration: the TRUCKEE study - 6 month results. *Eye*. 2023;37(17):3574–3581. doi:10.1038/s41433-023-02553-5



22. Larsen HO, Grauslund J, Efficacy VAS. Durability and Safety of Faricimab in Neovascular Age-Related Macular Degeneration and Diabetic Macular Oedema: lessons Learned from Registration Trials. *Ophthalmol Ther*. 2023;12(5):2253–2264. doi:10.1007/s40123-023-00753-6
23. Jousseaume AM, Ricci F, Paris LP, Korn C, Quezada-Ruiz C, Zarbin M. Angiopoietin/Tie2 signalling and its role in retinal and choroidal vascular diseases: a review of preclinical data. *Eye*. 2021;35(5):1305–1316. doi:10.1038/s41433-020-01377-x
24. Regula JT, Lundh von Leithner P, Foxton R, et al. Targeting key angiogenic pathways with a bispecific CrossMAb optimized for neovascular eye diseases. *EMBO Mol Med*. 2016;8(11):1265–1288. doi:10.15252/emmm.201505889
25. Grimaldi G, Cancian G, Rizzato A, et al. Intravitreal faricimab for neovascular age-related macular degeneration previously treated with traditional anti-VEGF compounds: a real-world prospective study. *Graefes Arch Clin Exp Ophthalmol*. doi:10.1007/s00417-023-06319-3
26. Li Y, Chong R, Fung AT. Association of Occlusive Retinal Vasculitis With Intravitreal Faricimab. *JAMA Ophthalmology*. 2024. doi:10.1001/jamaophthalmol.2024.0928

## Clinical Ophthalmology

Dovepress

### Publish your work in this journal

Clinical Ophthalmology is an international, peer-reviewed journal covering all subspecialties within ophthalmology. Key topics include: Optometry; Visual science; Pharmacology and drug therapy in eye diseases; Basic Sciences; Primary and Secondary eye care; Patient Safety and Quality of Care Improvements. This journal is indexed on PubMed Central and CAS, and is the official journal of The Society of Clinical Ophthalmology (SCO). The manuscript management system is completely online and includes a very quick and fair peer-review system, which is all easy to use. Visit <http://www.dovepress.com/testimonials.php> to read real quotes from published authors.

Submit your manuscript here: <https://www.dovepress.com/clinical-ophthalmology-journal>