

The Role of the Acromioclavicular Ligament in Acromioclavicular Joint Stability

A Cadaveric Biomechanical Study

Shimpei Kurata,^{*†} MD, Kazuya Inoue,[†] MD, PhD, Hideo Hasegawa,[†] MD, PhD, Takamasa Shimizu,[†] MD, PhD, Akio Iida,[†] MD, PhD, Kenji Kawamura,[†] MD, PhD, Shohei Omokawa,[‡] MD, PhD, Pasuk Mahakkanukrauh,^{§||} MD, PhD, and Yasuhito Tanaka,[†] MD, PhD

Investigation performed at Chiang Mai University, Chiang Mai, Thailand

Background: Acromioclavicular (AC) joint dislocation is evaluated using the radiologically based Rockwood classification. The relationship between ligamentous injury and radiological assessment is still controversial.

Purpose/Hypothesis: To investigate how the AC ligament and trapezoid ligament biomechanically contribute to the stability of the AC joint using cadaveric specimens. The hypothesis was that isolated sectioning of the AC ligament would result in increased instability in the superior direction and that displacement >50% of the AC joint would occur.

Study Design: Controlled laboratory study.

Methods: Six shoulders from 6 fresh-frozen cadavers were used in this study. Both the scapula and sternum were solidly fixed on a customized wooden jig with an external fixator. We simulated distal clavicular dislocation with sequential sectioning of the AC and coracoclavicular (CC) ligaments. Sectioning stages were defined as follows: stage 0, the AC ligament, CC ligament, and AC joint capsule were left intact; stage 1, the anteroinferior bundle of the AC ligament, joint capsule, and disk were sectioned; stage 2, the superoposterior bundle of the AC ligament was sectioned; and stage 3, the trapezoid ligament was sectioned. The distal clavicle was loaded with 70 N in the superior and posterior directions, and the magnitudes of displacement were measured.

Results: The amounts of superior displacement averaged 3.7 mm (stage 0), 3.8 mm (stage 1), 8.3 mm (stage 2), and 9.5 mm (stage 3). Superior displacement >50% of the AC joint was observed in stage 2 (4/6; 67%) and stage 3 (6/6; 100%). The magnitudes of posterior displacement were 3.7 mm (stage 0), 3.7 mm (stage 1), 5.6 mm (stage 2), and 9.8 mm (stage 3). Posterior displacement >50% of the AC joint was observed in stage 3 (1/6; 17%).

Conclusion: We found that the AC ligaments contribute significantly to AC joint stability, and superior displacement >50% of the AC joint can occur with AC ligament tears alone.

Clinical Relevance: The AC ligament plays an important role not only in horizontal stability but also in vertical stability of the AC joint.

Keywords: biomechanical study; fresh-frozen cadaveric study; acromioclavicular joint dislocation; acromioclavicular ligament; Rockwood classification

Numerous treatment approaches have been reported for acromioclavicular (AC) joint dislocation; however, no consensus is available regarding the most appropriate surgical treatment. The radiologically based Rockwood classification is commonly used for AC joint dislocation.¹⁸ The classification usually corresponds to ligamentous injury; for example, both the AC ligament and the coracoclavicular (CC) ligaments are injured in type 3 Rockwood injuries.

Beitzel et al³ subclassified type 3 injuries as 3A and 3B, in which a type 3A injury was defined as a stable AC joint without overriding of the clavicle on a cross-body adduction view and without significant scapular dysfunction. A type 3B injury was defined as an unstable AC joint with overriding clavicles on the cross-body adduction view; this is associated with refractory scapular dysfunction. The relationship between ligamentous injury and radiological assessment via Rockwood classification is still controversial.^{7,11} Debski et al^{4,5} reported on the importance of the AC capsule and CC ligaments; the AC, conoid, and trapezoid ligaments provide translational, superior, and

The Orthopaedic Journal of Sports Medicine, 9(2), 2325967120982947
DOI: 10.1177/2325967120982947
© The Author(s) 2021

This open-access article is published and distributed under the Creative Commons Attribution - NonCommercial - No Derivatives License (<https://creativecommons.org/licenses/by-nc-nd/4.0/>), which permits the noncommercial use, distribution, and reproduction of the article in any medium, provided the original author and source are credited. You may not alter, transform, or build upon this article without the permission of the Author(s). For article reuse guidelines, please visit SAGE's website at <http://www.sagepub.com/journals-permissions>.

posterior stability of the AC joint, respectively. Lee et al¹⁰ reported that the trapezoid and conoid ligaments play major roles in the superior and posterior directions. However, Urist²⁰ reported that when the superior AC ligament and entire joint capsule were sectioned, superior displacements of approximately 50% occurred in the AC joint.

We speculated that the AC ligament plays an important role in not only translational stability but also the superior stability of the AC joint. Using fresh-frozen cadaveric models, this study aimed to investigate how injuries of the AC and trapezoid ligaments biomechanically contribute to instability of the AC joint. We hypothesized that cutting the AC ligament would result in increased instability in the superior direction and that displacement >50% of the AC joint would occur.

METHODS

Specimen Preparation

Six shoulders from 6 fresh-frozen cadavers were used in this study (2 men and 4 women; mean age, 74 years; range, 57–93 years). All specimens were donated to the Chiang Mai University anatomy program. The specimens were thawed overnight at room temperature. The skin, fat, and muscle surrounding the sternoclavicular (SC) joint, AC joint, and CC interval were removed. Only the sternum, clavicle, scapula, SC ligament, AC ligament, CC ligaments, AC joint capsule, and disk were preserved. All specimens were kept moist by spraying them with normal saline during the experiment. Standard anteroposterior (AP) radiographs were obtained for each specimen, and no specimens had any indications of osteoarthritis.

Experimental Setup

In the connected specimens of the sternum, clavicle, and scapula, the scapula and sternum were solidly fixed on a customized wooden jig with an external fixator (Orthofix Japan Medicalnext). The AC and SC joints of the connected specimens were kept in the same position as the predissection position. The positions of the sternum and scapula were confirmed by an AP radiograph in the sitting posture before dissection, and the sternum and scapula were fixed on the wooden jig in the same position. Two 6 mm–diameter, fully threaded stainless steel rods were inserted into the sternum parallel to the ground. The same 2 rods were inserted into the scapula (1 into the inferior angle and the other into the glenoid) (Figure 1). We used an

electromagnetic tracking device (trakSTAR; Ascension Technology) to measure the displacement of the distal end of the clavicle relative to the acromion. Sensors were inserted into the distal end of the clavicle as well as the acromion. The appropriate position of the inserted sensors was confirmed using AP radiographs (BV Pulsera; Philips).

Sectioning of Distal Clavicle Stabilizers

We simulated distal clavicle dislocation by sequential sectioning of the AC ligament and trapezoid ligament, and the AC joint displacement model was created (Figure 2). Sectioning stages were defined as follows: stage 0, the AC ligament, CC ligament, and AC joint capsule were intact; stage 1, the anteroinferior bundle of the AC ligament, joint capsule, and disk were sectioned; stage 2, the AC ligament, joint disk, and capsule were sectioned completely; and stage 3, the AC ligament and trapezoid ligament were sectioned. Further sectioning of the conoid ligament resulted in excessive clavicular motion because of the lack of a stabilizer aside from the SC joint. The sectioning sequence of the ligaments was performed in accordance with a previous biomechanical study.¹⁵ In a previous anatomic study, the superoposterior bundle of the AC ligament (mean, 3.0 mm) was found to be thicker than its anteroinferior bundle (mean, 1.6 mm).¹⁴ We surmised that the anteroinferior bundle of the AC ligament would be injured first in a clinical setting because of the more fragile structure, and we therefore sectioned this bundle first in the current experiment.

Load Testing and Data Acquisition

As in previous biomechanical studies, the clavicle was loaded with 70 N in the superior and posterior directions.^{4,5,6,8,11,12} This force approximates the stress applied during weighted radiographs. The amount of displacement was measured by the difference between the values of each sensor in the acromion and the distal end of the clavicle. The x-axis was defined as the direction parallel to the AC joint, the y-axis was the perpendicular direction to the AC joint, and the z-axis was in the perpendicular direction to the ground. The magnitude of displacement was measured in each direction. We additionally performed Zanca view radiographs to confirm the degree of AC joint displacement (Figure 3). After all measurements were completed, all the soft tissues around the AC joint, including the AC ligament and joint disk, were removed. The height and anteroposterior width of the AC joint were measured on a scale, and the superior or posterior displacement rate was calculated as

*Address correspondence to Shimpei Kurata, MD, 840 Shijoutyou, Kashihara City, Nara 634-5822, Japan (email: kurashin24@gmail.com).

[†]Department of Orthopaedic Surgery, Nara Medical University, Kashihara, Nara, Japan.

[‡]Department of Hand Surgery, Nara Medical University, Kashihara, Nara, Japan.

[§]Department of Anatomy, Faculty of Medicine, Chiang Mai University, Chiang Mai, Thailand.

^{||}Excellence Center in Osteology Research and Training Center (ORCT), Chiang Mai University, Chiang Mai, Thailand.

Final revision submitted August 14, 2020; accepted August 31, 2020.

The authors declared that they have no conflicts of interest in the authorship and publication of this contribution. AOSSM checks author disclosures against the Open Payments Database (OPD). AOSSM has not conducted an independent investigation on the OPD and disclaims any liability or responsibility relating thereto.

Ethical approval for this study was waived by the Faculty of Medicine; Chiang Mai University approved the study (study code: ANA-2561-06031).

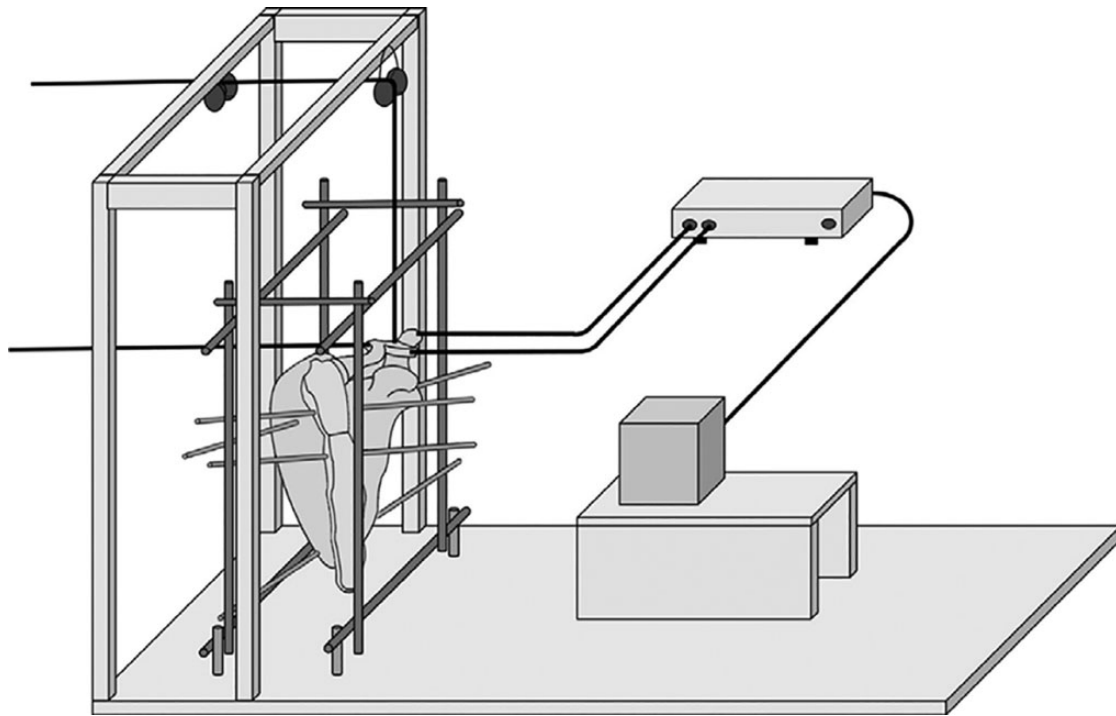


Figure 1. Experimental setup: the scapula and sternum were solidly fixed on a customized wooden jig with an external fixator (Orthofix Japan Medicalnext). We used an electromagnetic tracking device (trakSTAR; Ascension Technology) to measure the displacement of the distal end of the clavicle relative to the acromion. Sensors were inserted into the distal end of the clavicle and acromion.

$[(\text{change in superior or posterior displacement from stage 0}) / (\text{AC joint height or anteroposterior width})] \times 100$.

Statistical Analysis

Differences in displacement values between each stage were compared using 1-way analysis of variance, and post hoc tests were performed using the Tukey-Kramer method. The significance level was set at 5%. Statistical analysis was performed using SPSS Statistics for Windows Version 22 (IBM).

RESULTS

Table 1 shows the results of the load testing at 70 N for each sectioning stage.

Superior Displacement

There was no statistically significant difference in the amount of superior displacement among stages 0, 1, and 2, but the amount of displacement increased significantly between stages 0 and 2 ($P < .001$) and between stages 0 and 3 ($P < .001$). There was no statistically significant difference between stages 2 and 3.

There was no statistically significant difference in the rate of displacement between stages 0 and 1. However, the displacement rate increased significantly in stage 2

compared with stages 0 ($P < .001$) and 1 ($P < .001$), and it increased significantly in stage 3 compared with stages 0 ($P < .001$), 1 ($P < .001$), and 2 ($P = .044$).

Posterior Displacement

There was no statistically significant difference in the amount of displacement among stages 0, 1, and 2. The amount of displacement increased significantly in stage 3 compared with stages 0 ($P < .001$), 1 ($P < .001$), and 2 ($P = .002$).

There was no statistically significant difference among stages 0, 1, and 2 in the rate of posterior displacement. In the comparison between stage 3 and the other stages, the displacement rate increased significantly in stage 3 compared with stages 0 ($P < .001$), 1 ($P < .001$), and 2 ($P = .001$).

DISCUSSION

The most important finding of this study was that the AC ligament contributes significantly to AC joint stability in the superior direction, and displacement $>50\%$ of the AC joint can occur with isolated AC ligamentous injury.

Previous authors have reported on the importance of the AC ligament, especially the role of horizontal stability.^{4,6,8,10,12} Recently, the role of the AC ligament in rotational stability of the AC joint has been mentioned.^{6,10,12} Debski et al⁵ reported that disruption of the AC capsule

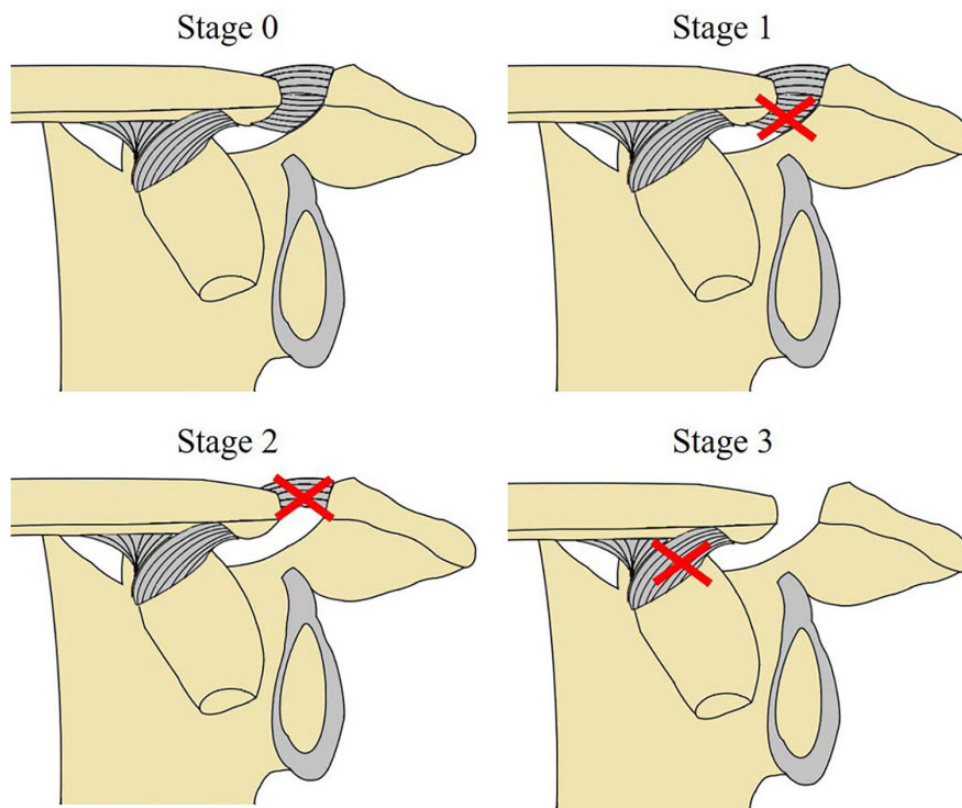


Figure 2. Sectioning of the distal clavicle stabilizers. Stage 0: The acromioclavicular ligament, coracoclavicular ligament, and acromioclavicular joint capsule were intact. Stage 1: The superoposterior bundle of the acromioclavicular ligament and coracoclavicular ligament were left intact (the anteroinferior bundle of the acromioclavicular ligament, joint capsule, and disk were sectioned). Stage 2: The coracoclavicular ligament was left intact (the acromioclavicular ligament, joint disk, and capsule were sectioned completely). Stage 3: The conoid ligament was left intact (the acromioclavicular ligaments and trapezoid ligament were sectioned). The sectioned ligaments in each stage are indicated by a cross mark.

does not result in a significant increase in translation in the superior translation. Fukuda et al⁸ reported contributions of individual ligaments to joint stability by performing biomechanical loading experiments with fixed displacement and sequential ligament sectioning. At small displacements, the AC ligament is a primary restraint to the superior direction of the AC joint. The role of the AC ligament in superior stability of the AC joint is controversial. In the current study, we found that the AC ligament contributes to superior stability of the AC joint. We also found superior displacement >50% of the AC joint in stage 2 (54.5%) and stage 3 (69.1%). Our results suggest that when deciding on what type of injury has occurred, the determination should not be based solely on the radiographic appearance of the AC joint. We should include examination of the AC joint to diagnose the dislocation correctly. For example, magnetic resonance imaging¹ and weighted radiographs with checking bilateral CC distance² would better discriminate between type 2 and 3 injuries. The AC ligament is said to help the horizontal stability of the AC joint; our results demonstrate that it also aids in superior stability. This fact emphasizes the importance of AC ligament reconstruction when treating AC joint dislocations. However, the difference in percentage displacement between the specimens

might be influenced by the difference in AC joint shapes and the strength of the individual ligaments of each specimen.

Concerning the contribution of the AC ligament, our results show that neither significant superior nor posterior displacement was observed in the current stage 1 experiment, where the anteroinferior fibers of the AC ligament were sectioned and the superoposterior bundles were left intact. This result indicates that no kinematic changes in the AC joint (superior and posterior directions) would occur after only sectioning the anteroinferior bundle and that preserving the superoposterior bundle can maintain AC joint stability in these directions. Klimkiewicz et al⁹ reported that the anteroinferior part of the AC capsule is of no significant importance for posterior stability. This report supports the current result.

AC joint arthritis is widely treated with arthroscopic distal clavicle resection, preserving the superoposterior bundle of the AC ligament.^{16,17} This procedure does not impair the stability of the AC joint in either the superior or posterior direction.

In stage 3 (sectioning of both the AC and trapezoid ligaments), significant posterior displacement was found. This result indicates that the trapezoid ligament contributes to

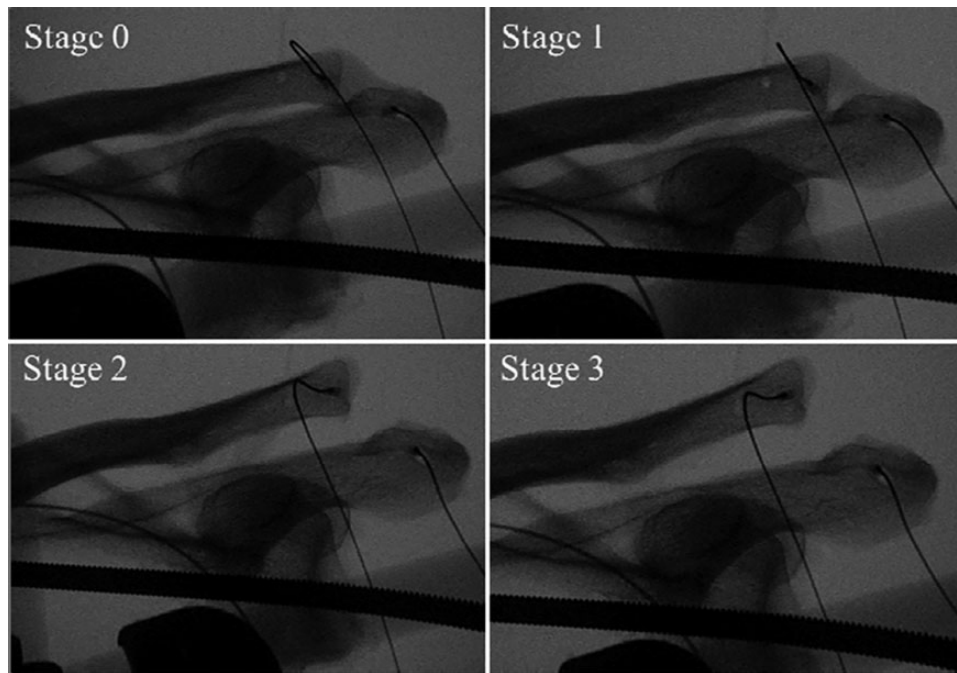


Figure 3. Zanca view radiographs for each sectioning stage.

TABLE 1
Superior and Posterior AC Joint Displacement for Each Sectioning Stage at 70-N Load Level^a

	Superior AC Joint Displacement ^b		Posterior AC Joint Displacement ^c	
	Amount of Displacement, mm	% of Superior Displacement ^d	Amount of Displacement, mm	% of Posterior Displacement ^e
Stage 0	3.7 ± 1.0 (2.0 to 5.0)	0	3.7 ± 1.1 (2.4 to 4.7)	0
Stage 1	3.8 ± 1.1 (2.2 to 5.3)	1.9 ± 1.8 (-1 to 4.0)	3.7 ± 1.1 (2.4 to 4.8)	0.4 ± 0.2 (0.2 to 0.8)
Stage 2	8.3 ± 1.6 (6.6 to 10.2)	54.5 ± 11.7 (38.7 to 73.0)	5.6 ± 2.0 (3.2 to 7.8)	9.6 ± 6.5 (5.0 to 22.2)
Stage 3	9.5 ± 1.5 (7.8 to 11.3)	69.1 ± 13.1 (57.2 to 93.0)	9.8 ± 3.0 (6.5 to 13.8)	29.7 ± 13.3 (14.5 to 53.8)

^aData are reported as mean ± SD (range). Stage 0, the acromioclavicular (AC) ligament, coracoclavicular ligament, and AC joint capsule were intact; stage 1, the anteroinferior bundle of the AC ligament, joint capsule, and disk were sectioned; stage 2, the AC ligament, joint disk, and capsule were sectioned completely; and stage 3, the AC ligament and trapezoid ligament were sectioned.

^bAC joint height = 8.7 ± 2.4 mm (range, 7.1-13.4 mm).

^cAC joint anteroposterior width = 20.7 ± 3.3 mm (range, 17.0-25.0 mm).

^dCalculated as [(change in superior displacement from stage 0)/(AC joint height)] × 100. Shown are mean values.

^eCalculated as [(change in posterior displacement from stage 0)/(AC joint anteroposterior width)] × 100. Shown are mean values.

posterior joint stability. In a previous study, Debski et al⁵ reported that the trapezoid ligament provides posterior stability to the AC joint. Lee et al¹⁰ reported that the trapezoid and conoid ligaments play major roles in the superior and posterior directions. The findings of the current study agree with the findings of these previous biomechanical studies. The trapezoid ligament originates from the posterolateral aspect of the coracoid process and attaches to the anterolateral undersurface of the clavicle. Anatomic directions of the trapezoid ligament fibers correspond to contribution of horizontal stability.^{13,19} Rockwood type 4 AC joint dislocation is defined as posterior displacement of the distal clavicle into the trapezius muscles.¹⁸ Although posterior displacement >50% of the AC joint was observed in only 1 specimen in stage 3, the displacement ratio was 53.8%,

which was not large enough to displace the distal clavicle into the trapezius muscles. Thus, more severe injury, such as rupture of both the AC and CC ligaments, may happen during type 4 AC joint dislocation.

The present study has several limitations. First, although ligament sectioning was performed according to a previous biomechanical study,¹⁵ it is still unclear whether the sequence of ligament sectioning is different from the clinical scenario of an AC joint dislocation. Second, specimens tested were from donors with a mean age of 74 years, whereas patients with AC dislocation are usually younger. Degenerative joint changes in elderly specimens may affect the joint kinematics. Third, the scapula was fixed solidly, and the actual movement of the scapula could not be accurately reproduced. Although AC joint dislocation is presumed to

be caused by abnormal mobility of the scapula,¹⁵ the current experiment of stress testing of the clavicle only does not replicate the clinical mechanism of injury. Fourth, the trapezius, deltoid, and subclavius muscles, which are dynamic stabilizers of the AC joint, were removed and not assessed in the current experimental model. Fifth, we did not evaluate anterior and rotational stability of the AC joint. Sixth, we could not show the data of the conoid ligament section model because the distal clavicle moved excessively because of the lack of a stabilizer aside from the SC joint. Seventh, serial testing may have stretched/damaged intact ligaments. Last, we did not measure CC distance (usually 20%-100% increased with type 3 injuries).

CONCLUSION

In the current cadaveric model study, we found that the AC ligaments contribute significantly to AC joint stability, and superior displacement >50% of the AC joint can occur with isolated AC ligamentous injury. The trapezoid ligament has a significant contribution to the posterior stability.

ACKNOWLEDGMENT

The authors thank the staff of the surgical training center for their extensive help in this study.

REFERENCES

1. Alyas F, Curtis M, Speed C, Saifuddin A, Connell D. MR imaging appearances of acromioclavicular joint dislocation. *Radiographics*. 2008;28(2):463-479.
2. Azar F, Pfeifer C, Alt V, et al. Clavicle elevation or shoulder girdle depression in acromioclavicular joint dislocation: a radiological investigation. *Orthop J Sports Med*. 2019;7(11):2325967119879927.
3. Beitzel K, Mazzocca AD, Bak K, et al. ISAKOS Upper Extremity Committee consensus statement on the need for diversification of the Rockwood classification for acromioclavicular joint injuries. *Arthroscopy*. 2014;30:271-278.
4. Debski RE, Parsons IM III, Fenwick J, Vangura A. Ligament mechanics during three-of-freedom motion at the acromioclavicular joint. *Ann Biomed Eng*. 2000;28:612-618.
5. Debski RE, Parsons IM IV, Woo SL, Fu FH. Effect of capsular injury on acromioclavicular joint mechanics. *J Bone Joint Surg Am*. 2001;83:1344-1351.
6. Dyrna FGE, Imhoff FB, Voss A, et al. The integrity of the acromioclavicular capsule ensures physiological centering of the acromioclavicular joint under rotational loading. *Am J Sports Med*. 2018;46(6):1432-1440.
7. Eschler A, Rösler K, Rotter R, Gradl G, Mittlmeier T, Gierer P. Acromioclavicular joint dislocations: radiological correlation between Rockwood classification system and injury patterns in human cadaver species. *Arch Orthop Trauma Surg*. 2014;134:1193-1198.
8. Fukuda K, Craig EV, An KN, Cofield RH, Chao EY. Biomechanical study of the ligamentous system of the acromioclavicular joint. *J Bone Joint Surg Am*. 1986;68:434-440.
9. Klimkiewicz JJ, Williams GR, Sher JS, Karduna A, Des Jardins J, Lannotti JP. The acromioclavicular capsule as a restraint to posterior translation of the clavicle: a biomechanical analysis. *J Shoulder Elbow Surg*. 1999;8(2):119-124.
10. Lee KW, Debski RE, Chen CH, Woo SL, Fu FH. Functional evaluation of the ligaments at the acromioclavicular joint during anteroposterior and superoinferior translation. *Am J Sports Med*. 1997;25(6):858-862.
11. Mazzocca AD, Spang JT, Rodriguez RR, et al. Biomechanical and radiographic analysis of partial coracoclavicular ligament injuries. *Am J Sports Med*. 2008;36:1397-1402.
12. Morikawa D, Dyrna F, Cote MP, et al. Repair of the entire superior acromioclavicular ligament complex best restores posterior translation and rotational stability. *Knee Surg Sports Traumatol Arthrosc*. 2019;27:3764-3770.
13. Nakazawa M, Koizumi M, Nimura A, Sato T, Akita K. Functional aspects of the coracoclavicular space. *Surg Radiol Anat*. 2011;33:913-918.
14. Nakazawa M, Nimura A, Mochizuki T, Koizumi M, Sato T, Akita K. The orientation and variation of the acromioclavicular ligament: an anatomic study. *Am J Sports Med*. 2016;44:2690-2695.
15. Oki S, Matsumura N, Iwamoto W, et al. The function of the acromioclavicular and coracoclavicular ligaments in shoulder motion: a whole-cadaver study. *Am J Sports Med*. 2012;40:2617-2626.
16. Park TS, Lee KW. Arthroscopic resection of the distal clavicle in osteoarthritis of the acromioclavicular joint. *Indian J Orthop*. 2016;50:379-383.
17. Robertson WJ, Griffith MH, Carroll L, O'Donnell T, Gill TJ. Arthroscopic versus open distal clavicle excision: a comparative assessment at intermediate-term follow-up. *Am J Sports Med*. 2011;39:2415-2420.
18. Rockwood CA, Williams GR, Young DC. Disorders of the acromioclavicular joint. In: Rockwood CA, Matsen FA, Wirth MA, Lippitt SB, eds. *The Shoulder*. WB Saunders; 2018:365-451.
19. Takase K. The coracoclavicular ligaments: an anatomic study. *Surg Radiol Anat*. 2010;32:683-688.
20. Urist MR. Complete dislocation of the acromioclavicular joint. *J Bone Joint Surg Am*. 1963;45:1750-1753.