

## CASE REPORT

# Flap demise reversed after central venous access device removal: A case report

Morgan M. Sandelski<sup>1</sup>  | Cyrus C. Rabbani<sup>2</sup> | Michael G. Moore<sup>2</sup> | Michael W. Sim<sup>2</sup> <sup>1</sup>Indiana University School of Medicine, Indianapolis, IN, USA<sup>2</sup>Department of Otolaryngology – Head and Neck Surgery, Indiana University School of Medicine, Indianapolis, IN, USA**Correspondence**

Michael W. Sim, Department of Otolaryngology – Head and Neck Surgery, Indiana University School of Medicine, 355 W 16th St Suite 3000, Indianapolis, IN 46202

Email: mwsim@iu.edu

**Abstract**

Patients undergoing head and neck free flap reconstruction should be evaluated for radiation-induced venous stenosis and presence of central venous port as a potential risk for flap failure.

**KEYWORDS**

head and neck oncology, microvascular reconstruction

## 1 | INTRODUCTION

A 62-year-old male with a treatment history of oral cancer and esophageal cancer presented with a new left tongue cancer. The patient had a subclavian port for recent adjuvant chemoradiation for esophageal cancer treatment. The patient underwent left partial glossectomy, left modified neck dissection, and right ulnar forearm free flap that failed from venous congestion. The secondary free flap subsequently developed venous congestion as well. Intraoperatively, imaging review showed possible stenosis of the subclavian vein and occlusion of the vein by the port catheter as the underlying cause of venous outflow obstruction. The catheter was removed with immediate resolution of the venous congestion. This report highlights the importance of considering radiation-induced venous stenosis and presence of a port as a significant risk factor for free flap failure.

Failure of microvascular free tissue transfer is an uncommon, but serious complication in head and neck reconstruction. Prior radiation, previous surgery, diabetes, tobacco use, and older age are well-recognized risk factors.<sup>1-6</sup> Precautions are taken to maximize success including optimizing preoperative nutrition, limiting tobacco use, and maintaining adequate control of chronic conditions.

A subset of patients may present to surgery with an implanted central venous access port for long-term intravenous access. There are little, if any, reports discussing free flap outcomes in association with ipsilateral ports. We present a case of venous congestion attributed to radiation-induced subclavian vein stenosis and occlusive presence of central venous port in head and neck microvascular free flap transfer.

## 2 | CASE

A 62 year-old male with an extensive head and neck cancer history and recent lower esophageal cancer presented for treatment of T3N0M0 squamous cell carcinoma of the left lateral tongue. He had a history of right tongue cancer surgically treated 20 years ago via right partial glossectomy, right modified radical neck dissection, and reconstructed with a left radial forearm free flap followed by adjuvant radiation therapy. He subsequently developed osteoradionecrosis of the mandible requiring a right fibula free flap. More recently, he was diagnosed with esophageal cancer treated with esophagectomy and gastric pull-up followed by chemoradiation. Patient had a left subclavian port placed for

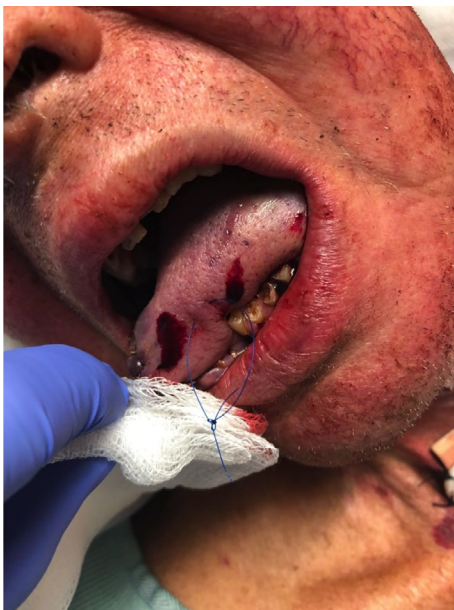This is an open access article under the terms of the Creative Commons Attribution-NonCommercial License, which permits use, distribution and reproduction in any medium, provided the original work is properly cited and is not used for commercial purposes.

© 2020 The Authors. *Clinical Case Reports* published by John Wiley & Sons Ltd

administration of chemotherapy, which remained until he presented for treatment of the new squamous cell carcinoma of the left oral tongue five months later.

The patient's case was presented at our multidisciplinary head and neck oncology conference, and recommendation was made to perform left partial glossectomy, left neck dissection, tracheostomy, and right ulnar forearm free flap. Intraoperatively, radiation-induced fibrosis was apparent during the left neck dissection but adequate vessels for microvascular surgery were identified. A right ulnar fasciocutaneous free flap was harvested, and microvascular anastomosis was performed to the left facial artery and left external jugular vein in end-to-end fashion. Initially, there was appropriate color and vascularity of the flap with no issues with the microvascular anastomosis. Progressive venous congestion of the flap, however, was recognized within several hours after procedure end. The patient returned to the operating room for neck exploration with revision of the venous anastomosis. Despite no evidence of thrombosis or kinking of the flap vein and a detectable flow with a Doppler, the flap remained congested. The vein was disconnected, and an end-to-side anastomosis to the left internal jugular vein was performed. Adequate venous flow was achieved, and the patient returned to the intensive care unit for monitoring.

Venous congestion of the flap recurred (Figure 1) within a few hours, and the patient was brought back to the operating room for exploration and free flap revision. At this point, the ulnar flap could not be salvaged. A left lateral arm free flap was then elevated to salvage the reconstruction. Again, microvascular re-anastomosis was uneventful with end-to-side anastomosis to the left internal jugular vein. Of note, the



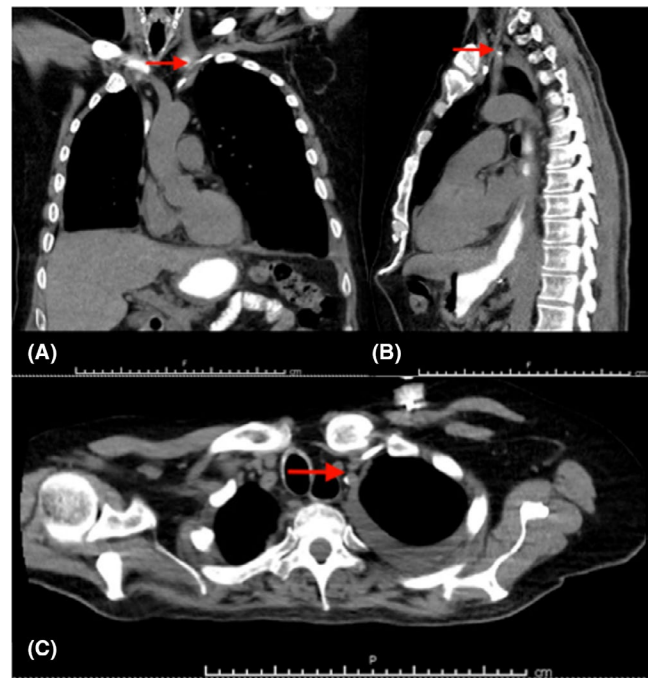
**FIGURE 1** Evidence of venous congestion in the ulnar forearm free flap despite revision of the venous anastomosis

right neck was not explored for new recipient vessels due to likely vessel depletion on that side from prior neck dissection and two prior free flaps on that side as previously mentioned. Despite patent vessels as confirmed by visualization, palpation, and Doppler, there were still signs of early venous congestion intraoperatively. At this point, it was deduced that the left subclavian port was potentially contributing to elevated back pressure of the internal jugular vein. Review of a preoperative contrasted CT scan of the neck and chest revealed relative narrowing of the internal jugular vein and the subclavian vein at their junction point consistent with radiation-induced venous stenosis. The port catheter appeared to occupy most of the lumen of the subclavian vein causing occlusion of flow (Figure 2A,B,C). The port was subsequently removed intraoperatively, at which point the venous congestion immediately resolved.

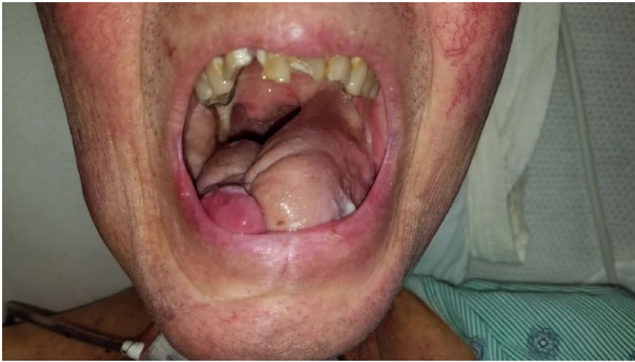The remaining postoperative course was uneventful. The left lateral arm free flap remained viable through the inpatient stay with discharge on postoperative day 10. The flap has healed well on long-term follow-up (Figure 3).

### 3 | DISCUSSION

Adequate perfusion and circulation are obviously essential to flap survival and are largely dependent on the quality of the recipient vessels. Recipient vessels chosen for the free flap is determined by length, caliber, and proximity



**FIGURE 2** Noncontrast CT scan with arrow indicating the internal jugular vein. A, coronal section with internal jugular vein partially obscured by the clavicle. B, axial section. C, sagittal section



**FIGURE 3** Five months postoperation

to defect.<sup>2,7</sup> Internal and external jugular veins are commonly used given their length and diameter allowing reach to most defects and sufficient drainage.<sup>8</sup> Many factors have been identified in decreasing arterial patency, such as atherosclerosis, diabetes, and smoking tobacco. Venous patency is less affected by these, but can be diminished from fibrosis and endothelial damage following radiation and surgery.<sup>7,9</sup> However, the effects of preoperative radiation on vasculature in head and neck free flaps are controversial. Some recent studies have found no difference in postoperative complications, including flap failure, between patients with prior head and neck radiation and those without it.<sup>4,7,10,11</sup> Other studies have found prior radiation or neck dissection to be independent risk factors in flap failure and serious complications.<sup>1,5,9,12</sup> Tall et al described how radiation causes an inflammatory response that alters the vascular biology through endothelial damage and activation of coagulation cascade.<sup>9</sup>

We surmise that the multiple prior radiation treatment courses, both for the right tongue cancer and for the esophageal cancer, caused radiation-induced venous stenosis of the recipient great vessels. With an in-dwelling port catheter present within the stenotic segment of the left subclavian vein, there was significantly reduced venous outflow via the left internal jugular vein. We conjecture that these were the causative factors of venous congestion in all three instances outlined in this case. Even at the initial re-exploration for the first episode of venous congestion, there was no evidence of obstruction of the donor vein or the external jugular vein, indicative of decreased venous flow rate as the etiology. There was rapid recovery of the second free flap after port removal, and it maintained viability thereafter. As previously mentioned, the right neck, contralateral to the port, was deemed vessel-depleted due to prior right neck dissection, two microvascular operations, and radiation therapy and, thus, was not pursued as a reliable source of recipient vessels.

Ports improve the quality of life of patients receiving chemotherapy and spare them multiple punctures necessary for establishing venous access at each therapy session. Studies have shown that ports lessened the burden of chemotherapy

and resulted in high rates of patient satisfaction.<sup>13,14</sup> They are associated with complications, though, as 1.2%–13.7% of patients have been reported to develop central vein stenosis after port placement.<sup>15–17</sup> Moreover, patients are nine times more likely to develop central vein stenosis with a left internal jugular vein port compared to the right.<sup>16</sup> Gonsalves et al performed routine screening of central vein stenosis after central venous access device placement and found that those with central venous abnormalities were all asymptomatic. Many patients with ports are not routinely evaluated for vessel stenosis or placed in situations where adequate venous drainage is critical, as in our patient, and thus, the actual incidence of venous stenosis following port placement is likely underestimated.

Radiation-induced venous stenosis is also a well-known sequela of radiotherapy due to associated endothelial injury and fibrosis.<sup>18</sup> In the current case, the patient had significant radiotherapy history having undergone adjuvant treatment for prior right oral tongue cancer and esophageal cancer. Both the port placement and radiation-induced vasculopathy likely contributed to central venous stenosis of the subclavian vein. This, coupled with the presence of the port catheter traversing the stenotic segment of the vein and occluding the lumen further, ultimately lead to venous congestion of the free flap.

It is not uncommon for patients undergoing cancer resection with free flap reconstruction to have a central venous access device in the setting of previous or current systemic therapy. Given our experience presented in this case report, we recommend that patients with central venous catheters undergo careful preoperative review of neck and chest CT scans to evaluate for occlusion or stenosis of recipient great vessels, especially if the vessels contralateral to the venous catheters are not accessible or depleted. Obviously, neck vessels contralateral to the central venous catheter should be considered the primary option first for microvascular anastomosis unless there are extenuating circumstances as in our case. Careful consideration should also be made to remove the port prior to the operation as it can contribute to occlusion of the central veins if there is stenosis. Moving forward, systemic therapy options will expand and improve. The likelihood of performing complex reconstructive operations in patients with prior treatment histories and port placements will increase, further highlighting the importance of the findings and considerations made in this report.

## CONFLICTS OF INTEREST

We have no conflicts of interest to disclose.

## AUTHOR CONTRIBUTION

MMS: Contributed to original draft preparation and manuscript editing. CCR: Contributed to manuscript editing. MGM: contributed to manuscript editing. MWS: contributed to conception of design and manuscript editing.

## ORCID

Morgan M. Sandelski  <https://orcid.org/0000-0002-0914-6968>

Michael W. Sim  <https://orcid.org/0000-0001-6571-9452>

## REFERENCES

- Zhou W, Zhang WB, Yu Y, et al, Risk factors for free flap failure: a retrospective analysis of 881 free flaps for head and neck defect reconstruction. *Int J Oral Maxillofac Surg*. 2017;46(8):941-945.
- Wong CH, Wei FC. Microsurgical free flap in head and neck reconstruction. *Head Neck*. 2010;32(9):1236-1245.
- Lin Y, He JF, Zhang X, Wang HM. Intraoperative factors associated with free flap failure in the head and neck region: a four-year retrospective study of 216 patients and review of the literature. *Int J Oral Maxillofac Surg*. 2018;48(4):447-451.
- Las DE, de Jong T, Zuidam JM, Verweij NM, Hovius SE, Mureau MA. Identification of independent risk factors for flap failure: A retrospective analysis of 1530 free flaps for breast, head and neck and extremity reconstruction. *J Plast Reconstr Aesthet Surg*. 2016;69(7):894-906.
- Farquhar DR, Masood MM, Pappa AK, Patel SN, Hackman ATG. Predictors of adverse outcomes in free flap reconstruction: a single-institution experience. *Otolaryngol Head Neck Surg*. 2018;159(6):973-980.
- Kinzinger MR, Bewley AF. Perioperative care of head and neck free flap patients. *Curr Opin Otolaryngol Head Neck Surg*. 2017;25(5):405-410.
- Nahabedian MY, Singh N, Deune EG, Silverman R, Tufaro AP. Recipient vessel analysis for microvascular reconstruction of the head and neck. *Ann Plast Surg*. 2004;52(2):148-155; discussion 156-147.
- Hiller A, Davis J, Schulz S, Henderson J, Wilhelmi BJ. Recipient vessel selection in head and neck reconstruction. *Eplasty*. 2017;17:e42.
- Tall J, Bjorklund TC, Skogh AC, Arnander C, Halle M. Vascular complications after radiotherapy in head and neck free flap reconstruction: clinical outcome related to vascular biology. *Ann Plast Surg*. 2015;75(3):309-315.
- Tan NC, Lin PY, Chiang YC, et al, Influence of neck dissection and preoperative irradiation on microvascular head and neck reconstruction-Analysis of 853 cases. *Microsurgery*. 2014;34(8):602-607.
- Lin S, Dutra J, Keni J, Dumanian GA, Fine N, Pelzer H. Preoperative radiation therapy and its effects on outcomes in microsurgical head and neck reconstruction. *Otolaryngol Head Neck Surg*. 2005;132(6):845-848.
- Herle P, Shukla L, Morrison WA, Shayan R. Preoperative radiation and free flap outcomes for head and neck reconstruction: a systematic review and meta-analysis. *ANZ J Surg*. 2015;85(3):121-127.
- Minichsdorfer C, Fuereder T, Maehr B, et al, A cross-section study evaluating patients' satisfaction with totally implanted access ports (PAC) assessing the PAC-related complication rate at two tertiary care centres in Austria. *J Clin Oncol*. 2014;32(15\_suppl):e17574.
- Ignatov A, Hoffman O, Smith B, et al, An 11-year retrospective study of totally implanted central venous access ports: complications and patient satisfaction. *Eur J Surg Oncol*. 2009;35(3):241-246.
- Song MG, Seo TS, Kim YH, et al, Effect of catheter diameter on left innominate vein in breast cancer patients after totally implantable venous access port placement. *J Vasc Access*. 2018;19(6):615-619.
- Song MG, Seo TS, Kang EY, Yong HS, Seo JH, Choi YY. Innominate vein stenosis in breast cancer patients after totally implantable venous access port placement. *J Vasc Access*. 2015;16(4):315-320.
- Gonsalves CF, Eschelman DJ, Sullivan KL, DuBois N, Bonn J. Incidence of central vein stenosis and occlusion following upper extremity PICC and port placement. *Cardiovasc Intervent Radiol*. 2003;26(2):123-127.
- Zhou W, Bush RL, Lin PH, Lumsden AB. Radiation-associated venous stenosis: endovascular treatment options. *J Vasc Surg*. 2004;40(1):179-182.

**How to cite this article:** Sandelski MM, Rabbani CC, Moore MG, Sim MW. Flap demise reversed after central venous access device removal: A case report. *Clin Case Rep*. 2020;8:1631-1634. <https://doi.org/10.1002/ccr3.2970>