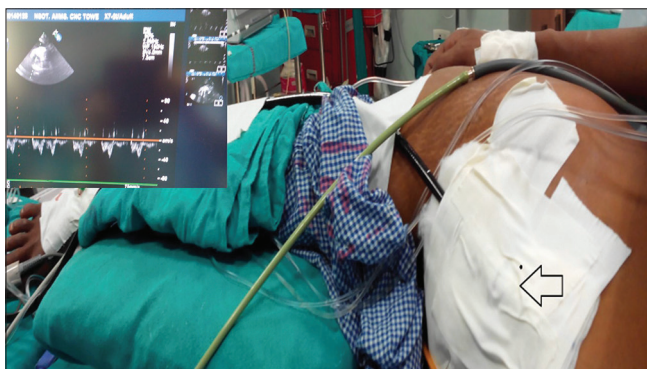


## Novel use of transoesophageal echocardiography in a pregnant patient undergoing neurosurgery

Sir,

Transoesophageal echocardiography (TEE) is a sensitive monitoring device used in neuroanaesthesia practice to detect venous air embolism and patent foramen ovale. In this article, we describe the extended use of the TEE probe for continuous monitoring of the foetal heart rate (FHR) of a pregnant patient undergoing neurosurgery.

A 25-year-old, 53 kg female in her 25<sup>th</sup> week of pregnancy presented to the outpatient department with the chief complaints of headache and hearing loss on the right side for 6 months with gait ataxia with facial asymmetry for 2 months. She was diagnosed with a right cerebellopontine acoustic schwannoma of size 4 cm × 3.5 cm × 5.1 cm and was scheduled for resection in left lateral position. After obtaining written informed consent from the patient, abdominal ultrasound recorded before surgery revealed the presence of a live foetus of gestational age 25 weeks. During surgery, continuous FHR monitoring was done with the help of a transoesophageal echocardiography (TEE) probe attached to the abdominal wall of the patient [Figure 1] since the ultrasonography Doppler machine was non-functional at that time. The foetal and maternal intraoperative haemodynamic or respiratory parameters were stable throughout the procedure. Obstetric evaluation was done throughout the Intensive Care Unit stay. Postoperatively, the patient had right-sided grade-3



**Figure 1:** Transoesophageal echocardiography probe attached to the abdominal wall of patient for continuous foetal heart rate monitoring (within inset image)

facial nerve paresis that gradually improved with time. The patient underwent caesarean section under general anaesthesia at the 35<sup>th</sup> week of her pregnancy and gave birth to a child with low Apgar scores at 1 min.

The pregnant patient presenting for neurosurgery is not uncommon and a search for contemporary literature regarding anaesthetic management yields both case reports<sup>[1-4]</sup> and series,<sup>[5]</sup> but a definitive evidence-based guideline is still limited by traditional practices, lack of significant data and paucity of cases. Recent recommendations from the American College of Obstetricians and Gynecologists suggest that intraoperative foetal well-being monitoring may be appropriate in the presence of viable foetus, logistic support to perform foetal monitoring, trained qualified obstetrician to intervene intraoperatively for foetal emergencies, consent to caesarean section by the patient and consent from surgeon to allow the safe interruption of the routine surgery to provide access to perform emergency delivery.<sup>[6]</sup>

Fukuda *et al.* reported utility of intraoperative FHR monitoring for cerebral arteriovenous malformation surgery during pregnancy in different trimesters: TEE (during the 2<sup>nd</sup> trimester) and cardiotocography (during the 3<sup>rd</sup> trimester) to avoid adverse effects of systemic maternal hypotension and unexpected bleeding on the foetus during surgery.<sup>[7]</sup> We have demonstrated continuous foetal monitoring with TEE probe intraoperatively in the lateral position. Intraoperative use of the TEE probe for foetal monitoring in pregnant patients has few distinct advantages over foetal tococardiography and Doppler transducer devices as it allows continuous beat-to-beat monitoring of heart rate and hands-free operation without need to engage any additional personnel. On account of its length, narrow and small probe surface, the TEE probe could easily be attached to the abdominal wall. This monitoring helped us intraoperatively in assessing the foetal well-being. Nevertheless despite foetal monitoring in the perioperative period, the child was subsequently born with low Apgar scores. The cause of this poor foetal outcome can be multifactorial. We conclude that continuous FHR monitoring in pregnant patients using the TEE probe intraoperatively is a useful addition to the armamentarium of the anaesthesiologist.

### Acknowledgement

The authors are very much thankful to Dr. Shweta Kedia, Department of Neurosurgery, All India Institute of

Medical Sciences, New Delhi, for her kind assistance in managing case intraoperatively.

**Financial support and sponsorship**

Nil.

**Conflicts of interest**

There are no conflicts of interest.

**Keshav Goyal, Kunal Singh<sup>1</sup>, Ranadhir Mitra, Gaurav Singh Tomar**

Department of Neuroanaesthesiology and Critical Care, Neuroscience Centre, All India Institute of Medical Sciences, New Delhi,

<sup>1</sup>Department of Anaesthesiology, Himalayan Institute of Medical Sciences, Dehradun, Uttarakhand, India

**Address for correspondence:**

Dr. Gaurav Singh Tomar,  
Department of Neuroanaesthesiology and Critical Care,  
Neuroscience Centre, All India Institute of Medical  
Sciences, New Delhi - 110 029, India.  
E-mail: spunkygst@gmail.com

**REFERENCES**

1. Balki M, Manninen PH. Craniotomy for suprasellar meningioma in a 28-week pregnant woman without fetal heart rate monitoring. *Can J Anesth* 2004;51:573-6.
2. Chow MS, Mercier PA, Omahen DA, Wood SL, Johnson JA. Recurrent exophytic meningioma in pregnancy. *Obstet Gynecol* 2013;121:475-8.
3. Rodríguez-Porcel F, Hughes I, Anderson D, Lee J, Biller J.

Foster Kennedy syndrome due to meningioma growth during pregnancy. *Front Neurol* 2013;4:183.

4. Giannini A, Bricchi M. Posterior fossa surgery in the sitting position in a pregnant patient with cerebellopontine angle meningioma. *Br J Anaesth* 1999;82:941-4.
5. Kanaan I, Jallu A, Kanaan H. Management strategy for meningioma in pregnancy: A clinical study. *Skull Base* 2003;13:197-203.
6. Committee on Obstetric Practice and the American Society of Anesthesiologists. Committee opinion No. 696: Nonobstetric surgery during pregnancy. *Obstet Gynecol* 2017;129:777-8.
7. Fukuda K, Masuoka J, Takada S, Katsuragi S, Ikeda T, Iihara K, *et al.* Utility of intraoperative fetal heart rate monitoring for cerebral arteriovenous malformation surgery during pregnancy. *Neurol Med Chir (Tokyo)* 2014;54:819-23.

This is an open access article distributed under the terms of the Creative Commons Attribution-NonCommercial-ShareAlike 3.0 License, which allows others to remix, tweak, and build upon the work non-commercially, as long as the author is credited and the new creations are licensed under the identical terms.

Access this article online	
Quick response code	Website: www.ijaweb.org
	DOI: 10.4103/ija.IJA_332_17

**How to cite this article:** Goyal K, Singh K, Mitra R, Tomar GS. Novel use of transoesophageal echocardiography in a pregnant patient undergoing neurosurgery. *Indian J Anaesth* 2017;61:681-2.  
© 2017 Indian Journal of Anaesthesia | Published by Wolters Kluwer - Medknow