

# The efficacy and safety of low-dose Apatinib in the management of stage IV luminal-type breast cancer: a case report and literature review

Xingxing Lv\*, Juan Chen\*, Tingwu Yi, Hong Lu, Juan Liu and Danfei Yu

Advanced breast cancer (ABC) is incurable. Previous studies have shown that vascular endothelial growth factor (VEGF) inhibitors play a significant role in the angiogenesis of breast carcinoma. Apatinib, a highly selective orally administered small-molecule tyrosine kinase inhibitor that targets vascular endothelial growth factor receptor-2 (VEGFR2) has successfully been used as a second- and third-line agent in the management of ABC. There are also multiple reported cases where Apatinib was miraculously effective in the management of triple-negative and HER2-positive tumors. However, case reports of its effectiveness against luminal-type tumors are rare. Here, we report the case of a 34-year-old woman with hormone receptor-positive and HER2-negative ABC who was successfully treated with low-dose Apatinib. Owing to necrosis of the center of the tumor due to the effective anticancer effect of Apatinib, a large cavity

formed rapidly in the primary lesion; thus, the quality of life of the patient was seriously affected. This report aims to caution physicians about this unique phenomenon when using Apatinib in clinical practice. *Anti-Cancer Drugs* 32: 773–778 Copyright © 2021 The Author(s). Published by Wolters Kluwer Health, Inc.

*Anti-Cancer Drugs* 2021, 32:773–778

**Keywords:** advanced breast cancer, Apatinib, cavity formed, luminal type, significant effect

Department of Oncology and Hematology, people's Hospital of Leshan, Leshan, Sichuan

Correspondence to Xingxing Lv, Department of Oncology and Hematology, People's Hospital of Leshan, 238 Baita Street, Leshan, Sichuan Province, 614000, P.R. China

Tel: +86 18398614332; e-mail: xingxingkl@126.com

\*Xingxing Lv and Juan Chen contributed equally to the writing of this article.

Received 19 May 2021 Revised form accepted 30 May 2021

## Introduction

In 2020, breast cancer displaced lung cancer and became the most diagnosed cancer worldwide. According to the International Agency for Research on Cancer [1], about 5–10% of patients with breast had distant metastases at initial presentation [2,3], and a higher proportion of such cases occurred in low- and middle-income areas [4,5]. The goals of therapy at this stage of the disease are to optimize the patient's quality of life and, if possible, prolong the time to progression of disease and delay death, but it is not curative.

Apatinib is an oral, small-molecular receptor tyrosine kinase inhibitor (TKI) that selectively targets vascular endothelial growth factor receptor-2 (VEGFR2). It inhibits VEGF-stimulated endothelial cell migration and proliferation and reduces tumor microvascular density. It has been successfully used in the management of several advanced cancers including metastatic gastric, lung, esophageal and colon cancer [6,7]. Several studies have also shown that Apatinib has encouraging antitumor activity and manageable toxicities in the management of advanced breast cancer (ABC) [8–10]; however, only a

few studies have reported the efficacy of Apatinib in the management of luminal-type ABC. Herein, we report the case of a young woman with hormone receptor-positive and HER2-negative ABC, who was treated with low-dose Apatinib, and brilliant results were observed. She presented with a lump that shrank significantly just after one cycle of Apatinib. Owing to necrosis of the center of the tumor due to the anticancer effect of Apatinib, a large cavity formed rapidly in the primary lesion after the tumor subsided. Although the cavity got progressively smaller after endocrine therapy, it was not healed after 4 months of treatment, but the hole finally healed after radiotherapy (RT). The dressing on the wound was changed frequently and this seriously affected the quality of life of the patient. After conducting a literature review, we found that a similar phenomenon occurred in some other cases [7,18–20]. We suggest that this may be related to the mechanism of action of Apatinib, as it induced apoptosis and inhibits cell proliferation by blocking the VEGF pathway. This report seeks to bring this phenomenon to the attention of clinicians who use Apatinib in the management of patients with ABC.

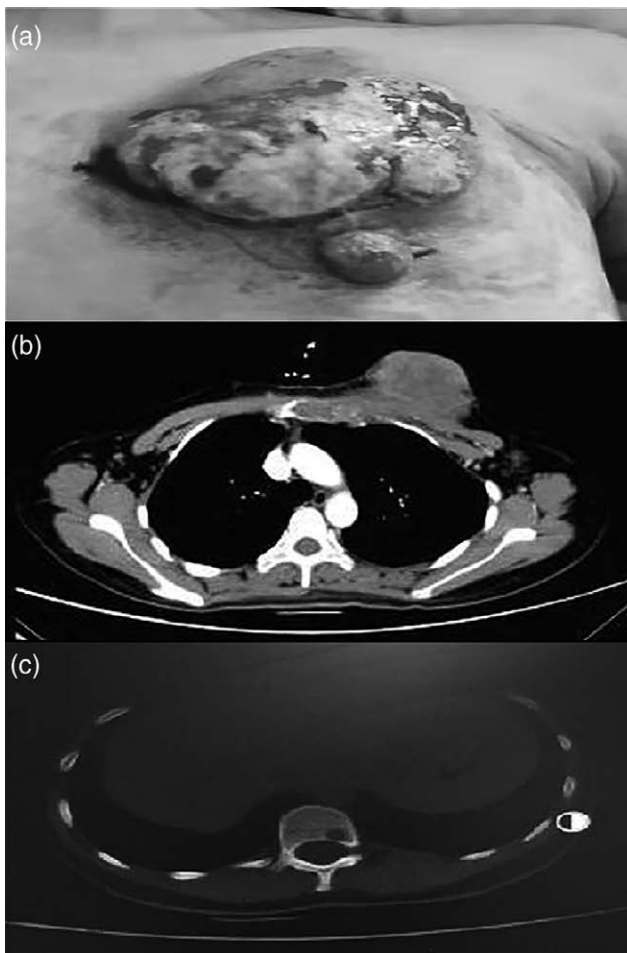
## Case report

In August 2019, a 34-year-old woman who had a left breast tumor was admitted to the people's hospital of Leshan (Leshan, Sichuan, China) due to hemorrhage and discharged from her left breast. The mass was noticed

This is an open-access article distributed under the terms of the Creative Commons Attribution-Non Commercial-No Derivatives License 4.0 (CCBY-NC-ND), where it is permissible to download and share the work provided it is properly cited. The work cannot be changed in any way or used commercially without permission from the journal.

two years prior, but she was yet to visit a hospital. She was admitted, and physical examination revealed an irregular huge mass (100 × 80 mm, Fig. 1a) in the left breast, with bleeding and was foul-smelling. Color Doppler ultrasonography and computed tomography (CT) revealed a huge tumor in the left breast and several enlarged lymph left axillary and internal mammary lymph node (Fig. 1b), and metastasis to the 12th thoracic vertebrae (T12) was detected by both whole-body bone scanning and CT (Fig. 1c), no other metastatic lesions in other organs were found. Because the left breast was bleeding, and there were a lot of necrosed tissues inside the tumor, we chose decided to biopsy the left lymph node. The pathological evaluation confirmed that it was an invasive grade II ductal carcinoma (ER 80%+, PR 80%+, HER2-, Ki67 60%), and the clinical stage of the disease was cT4N3M1 stage IV. She has no history of hypertension, cardiovascular diseases or bleeding from any other organ, and had

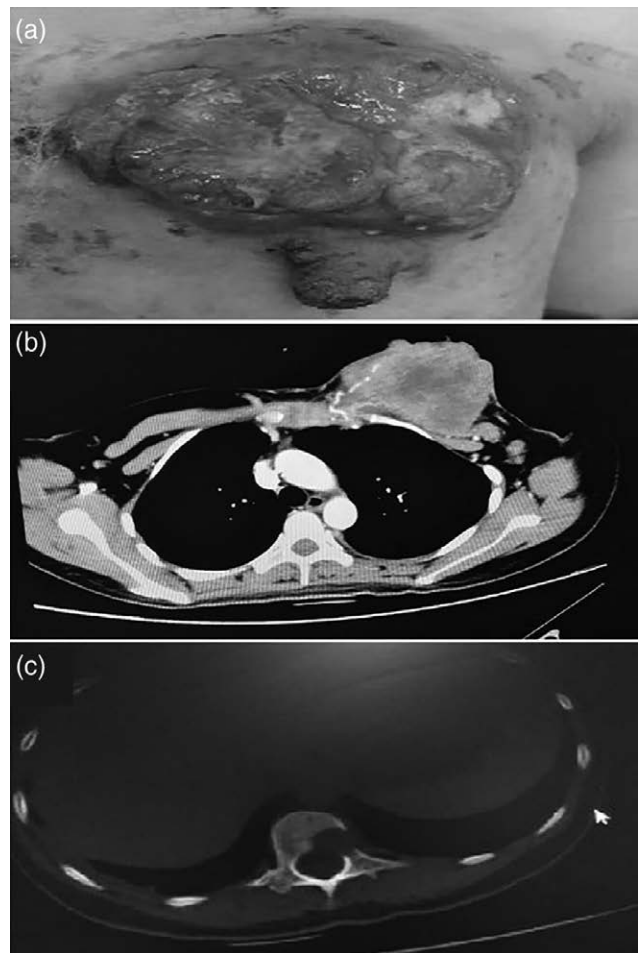
Fig. 1



(a) Physical examination revealed an irregular huge mass (100 × 80 mm) in the left breast; (b) computed tomography (CT) revealed a huge tumor in the left breast; (c) metastasis to the 12th thoracic vertebrae (T12) by CT.

no family history of cancer. According to guidelines we recommend that she should be treated with a CDK4/6 inhibitor combined with endocrine therapy, but the patient declined treatment because of her poor economic status. She then received chemotherapy comprising TEC (docetaxel 75 mg/m<sup>2</sup>, epirubicin 75 mg/m<sup>2</sup> and cyclophosphamide 500 mg/m<sup>2</sup>) every 3 weeks, simultaneously. She also received bisphosphonate routinely, and the wound was dressed every 2–3 days. After two cycles of treatment, the patient mentioned that the bleeding had significantly reduced (Fig. 2a), but a CT scan showed no reduction in the size of the breast tumor (Fig. 2b), and the metastases of T12 had progressed (Fig. 2c). In November 2019, her chemotherapy regimen was changed to cisplatin (75 mg/m<sup>2</sup>) and vinorelbine (40 mg/m<sup>2</sup>, on day 1 and day 8) every 3 weeks. After receiving one cycle, the patient complained that the breast mass had enlarged slightly and she was found to have grade two leukopenia. In December

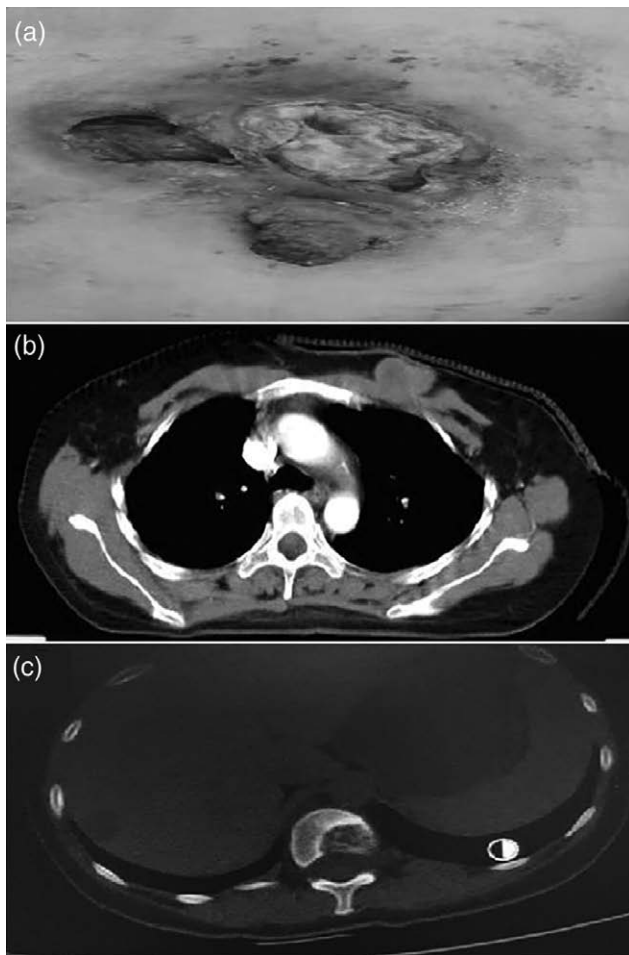
Fig. 2



(a) Physical examination revealed bleeding had significantly reduced but the no reduction in the size of the breast tumor; (b) computed tomography (CT) scan showed no reduction in the size of the breast tumor; (c) CT scan showed the metastases of T12 had progressed.

2019, we placed her on oral Apatinib (250 mg, daily) and continued to administer chemotherapy comprising cisplatin and Vinorelbine after myelosuppression was controlled. After one cycle, the lump shrank significantly, and a clear cavity was formed (Fig. 3a). CT revealed a partial response of the breast tumor (Fig. 3b) and ossification at the site of the bone metastasis (Fig. 3c) after the second cycle. Because of the spread of COVID-19 in whole China, it is inconvenient for patients to routinely visit hospitals from home frequently, so we suggested she stopped the chemotherapy and treated her with a single agent, Apatinib (250 mg, daily). Three months after commencing Apatinib monotherapy, impressive reductions in the size of the tumor were noticed (Fig. 4b), but progressive wound necrosis was observed (Fig. 4a). After a multidisciplinary treatment discussion, we advised her to undergo modified radical surgery and dermatoplasty and change the treatment to endocrine therapy, but the

**Fig. 3**



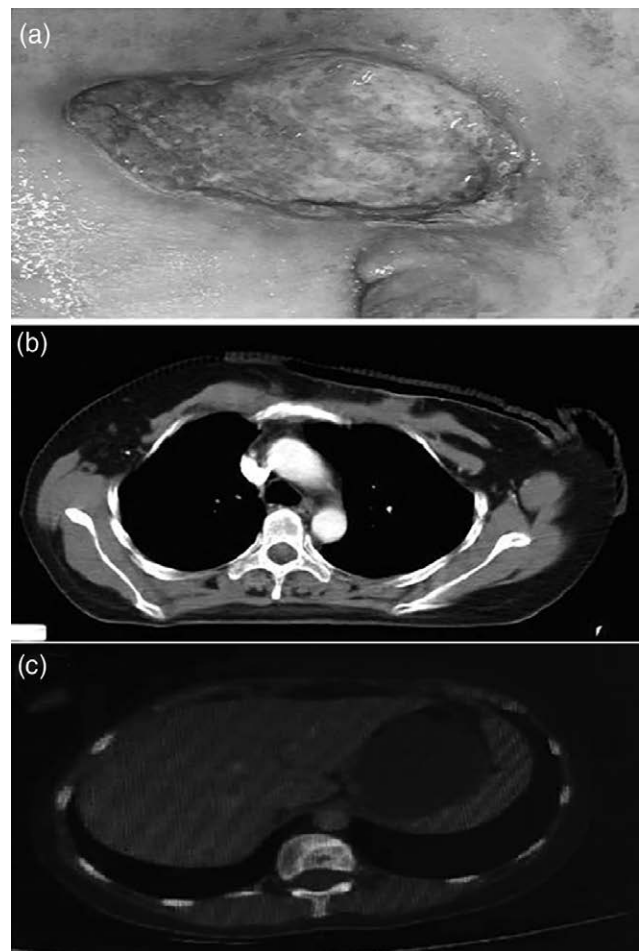
(a) Physical examination revealed the lump shrank significantly, and a clear cavity was formed; (b) computed tomography (CT) revealed a partial response of the breast tumor; (c) CT shows ossification at the site of the bone metastasis.

patient declined surgery. Thus, she was treated with Letrozole and Leuporelin in April 2020. After 4 months of treatment, the cavity becomes progressively smaller (Fig. 5a,b), and the breast lump almost disappeared as shown in a chest CT (Fig. 5c). In September 2020, local RT (60 Gy/30 fractions) for the primary tumor and regional lymph nodes was finally conducted in combination with endocrine therapy, and in November 2020, wound healing was observed after RT (Fig. 6). Currently, the patient is still being managed and is receiving endocrine therapy.

## Discussion

The ABC, National Comprehensive Cancer Network and the Chinese Society Clinical Oncology guidelines recommend CDK4/6 inhibitors combined with endocrine therapy as first-line therapy in patients with hormone receptor-positive/HER2-negative ABC. However, according to the ABC consensus, in patients who have

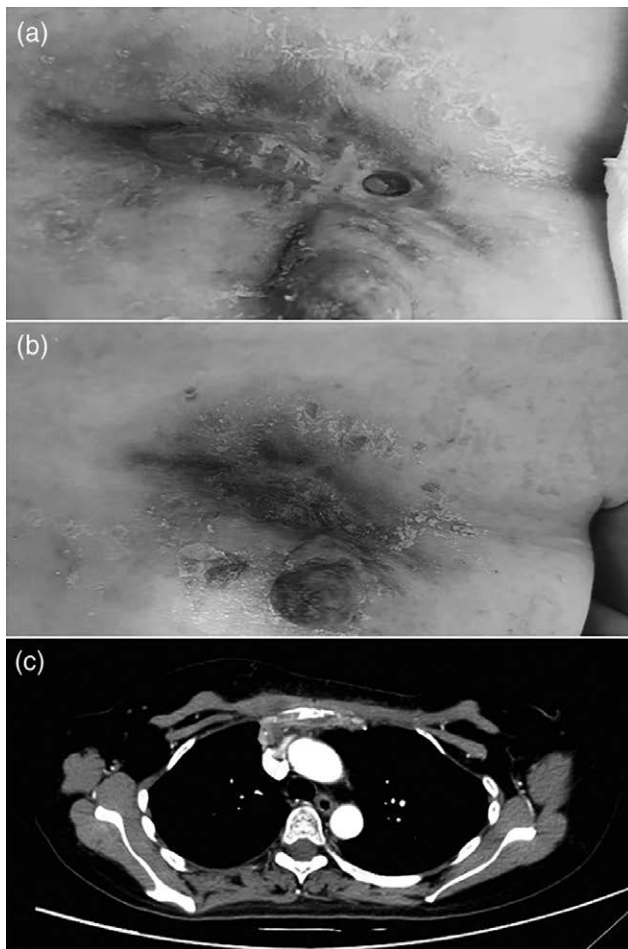
**Fig. 4**



(a) Physical examination observed progressive wound necrosis; (b) impressive reductions in the size of the tumor were noticed by computed tomography; (c) ossification at the site of the bone metastasis.



Fig. 5

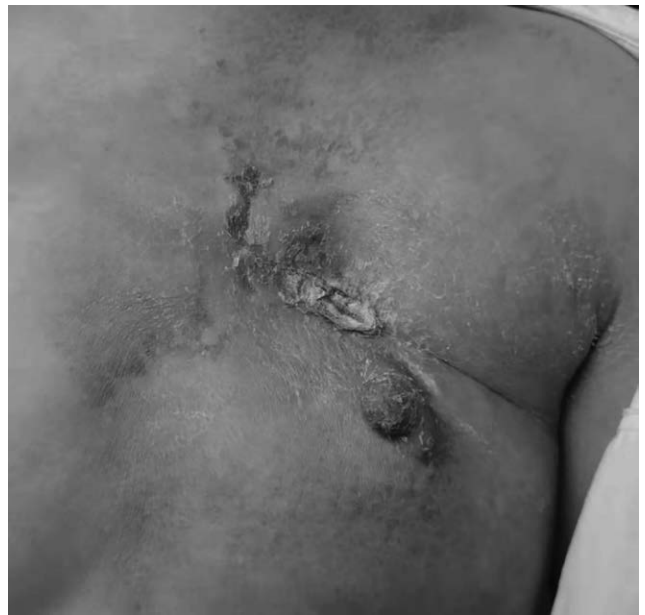

(a,b) The cavity becomes progressively smaller and smaller. (c) The breast lump almost disappeared as shown in chest computed tomography.

visceral risk, severe symptoms and rapid disease progression, chemotherapy can be chosen to relieve symptoms quickly and improve the patient's quality of life [11]. In our case, we needed to stop the bleeding and growth of tumor quickly but she could not afford the expensive costs of drugs, such as CDK4/6 inhibitors which were suggested by the guidelines. Therefore, we chose chemotherapy as the first line of treatment. Even though the bleeding stopped, the breast tumor did not shrink and the bone metastasis progressed after chemotherapy commenced.

Angiogenesis is considered to be an important component of tumor growth, invasion, and metastasis. Many studies have proved that vascular endothelial growth factor (VEGF), and its receptors (VEGFRs) play a significant role in the angiogenesis of breast carcinoma. Bevacizumab, an anti-VEGF mAb, has been successfully used in MBC to improve the objective response rate and the progression-free survival (PFS) of patients when

Fig. 6



Wound healing was observed after RT.

combined with chemotherapy more than chemotherapy alone in the first line, but it does not prolong overall survival (OS) [12,13]. Other anti-VEGF receptor (VEGFR) TKIs, such as sunitinib and sorafenib, have demonstrated no significant effects in MBC [14,15].

Apatinib is a highly selective oral, small-molecule TKI that binds to and inhibits VEGFR2, and this may lead to inhibition of VEGF-mediated endothelial cell migration, proliferation and tumor microvascular density [7]. Previous studies have shown that not only Apatinib monotherapy but a combination of Apatinib and chemotherapy have objective efficacy and acceptable toxicity. Two-phase II studies found that Apatinib monotherapy used in the management of MBC gains a median PFS of 3.3–4.0 months and OS of 10.3–10.6 months [8,9]. When it comes to combined with chemotherapy, Li [16] reported that treatment with Apatinib combined with capecitabine achieves a better efficacy and similar rate of serious adverse events compared with capecitabine alone as a third-line treatment for advanced triple-negative breast cancer. Another study showed that Apatinib combined with chemotherapeutic agents in patients with ABC who were previously exposed to chemotherapy achieved a PFS of 4.4 months and an OS of 11.3 months [17].

Based on these lines of evidence, our clinical experience and because the tumor of this patient had an abundant blood supply, we proposed that anti-angiogenic therapy may be effective. Surprisingly, she had exciting results and no toxicity due to Apatinib during the whole course of treatment, include hypertension, proteinuria and hand-foot syndrome that are the most frequent adverse events

**Table 1** Summary of the wound necrosis or cavity formation by use of apatinib

Author	Type of cancer	site	Dose of apatinib	Observed phenomena after use of apatinib	Time from therapy to evaluation
Liu <i>et al.</i> [20]	Advanced triple-negative breast cancer	Right breast	250 mg qd	The fungated, cauliflower-like tumor occupied the entire right breast	2 months
Danni <i>et al.</i> [18]	Advanced her2-positive breast cancer	right chest wall and Bilateral lung metastasis	500 mg qd	Right chest wall and the left lung metastasis demonstrated clear cavitation	3 months
Zhou <i>et al.</i> [17]	Osteosarcoma	left upper crus area	500 mg qd	Progressive wound necrosis appeared	1.5 months
Li <i>et al.</i> [16]	Metastatic rectal cancer	Bilateral lung metastasis	750 mg qd	Cavity formation	2 months

reported in former clinical studies [8,9,16,17]. This is probably due to the low dose of the drug used. The severe adverse reaction observed was three-degree bone marrow suppression, but we assumed that this was due to the chemotherapy. But due to the significant anticancer of Apatinib, a large cavity formed rapidly in the primary tumor after the size of the tumor reduced, and this is not the first report of such an occurrence. A few case reports have also mentioned a similar phenomenon [7,18–20], and we summarize have these cases in Table 1. Surgery or RT is generally palliative when cavities and necrosis occur. Compare to surgery, locoregional RT is less invasive and does not require general anesthesia; therefore, RT is more likely to be chosen in most cases. Yee *et al.* [21] reported that in cases of unresectable locally-ABC, ulceration and bleeding improved following RT in 13 (54%) of the 24 applicable cases. Liu [20] reported that the cavity gradually healed after hypofractionated irradiation of 40 Gy/8 fractions was delivered to the tumor. In our patient, the cavity became progressively smaller after endocrine therapy was commenced; however, she was not cured after 4 months of treatment, but the wound finally healed after RT. We consider that RT contributed greatly to wound healing.

### Conclusion

Considering its manageable toxicity and efficacy, Apatinib is a good management option in some cases of luminal-type ABC, but we should note that if the tumor recedes too quickly, wound ulceration that does not heal easily may occur, and this may be ameliorated by RT.

### Acknowledgements

We would like to thank the patient for his agreement to publication of this report and Editage (www.editage.cn) for English language editing.

This case report and the study design were approved by Ethics Committee of people's Hospital of Leshan.

Written informed consent was obtained from the patient for publication of this case report and accompanying images.

### Conflicts of interest

There are no conflicts of interest.

### References

- Ferlay J, Colombet M, Soerjomataram I, Parkin DM, Piñeros M, Znaor A, Bray F. Cancer statistics for the year 2020: an overview. *Int J Cancer* 2021; doi: 10.1002/ijc.33588
- Silber JH, Rosenbaum PR, Clark AS, Giantonio BJ, Ross RN, Teng Y, *et al.* Characteristics associated with differences in survival among black and white women with breast cancer. *JAMA* 2013; **310**:389–97.
- Siegel RL, Miller KD, Jemal A. Cancer statistics, 2015. *CA Cancer J Clin* 2015; **65**:5–29.
- Verdial FC, Etzioni R, Duggan C, Anderson BO. Demographic changes in breast cancer incidence, stage at diagnosis and age associated with population-based mammographic screening. *J Surg Oncol* 2017; **115**:517–522.
- Panieri E. Breast cancer screening in developing countries. *Best Pract Res Clin Obstet Gynaecol* 2012; **26**:283–90.
- Li J, Qin S, Xu J, Guo W, Xiong J, Bai Y, *et al.* Apatinib for chemotherapy-refractory advanced metastatic gastric cancer: results from a randomized, placebo-controlled, parallel-arm, phase II trial. *J Clin Oncol* 2013; **31**:3219–3225.
- Li J, Zhao X, Chen L, Guo H, Lv F, Jia K, *et al.* Safety and pharmacokinetics of novel selective vascular endothelial growth factor receptor-2 inhibitor YN968D1 in patients with advanced malignancies. *BMC Cancer* 2010; **10**:529.
- Hu X, Zhang J, Xu B, Jiang Z, Ragaz J, Tong Z, *et al.* Multicenter phase II study of apatinib, a novel VEGFR inhibitor in heavily pretreated patients with metastatic triple-negative breast cancer. *Int J Cancer* 2014; **135**:1961–1969.
- Hu X, Cao J, Hu W, Wu C, Pan Y, Cai L, *et al.* Multicenter phase II study of apatinib in non-triple-negative metastatic breast cancer. *BMC Cancer* 2014; **14**:820.
- Lin Y, Wu Z, Zhang J, Hu X, Wang Z, Wang B, *et al.* Apatinib for metastatic breast cancer in non-clinical trial setting: satisfying efficacy regardless of previous anti-angiogenic treatment. *Tumour Biol* 2017; **39**:1010428317711033.
- Untch M, Würstlein R, Lüftner D, Haidinger R, Fasching PA, Augustin D, *et al.* ABC5 International Consensus Conference on Advanced Breast Cancer, Lisbon, 16 November 2019: commentary by the German panel of experts on the ABC5 voting results. *Geburtshilfe Frauenheilkd* 2020; **80**:588–600.
- Pivot X, Schneeweiss A, Verma S, Thomssen C, Passos-Coelho JL, Benedetti G, *et al.* Efficacy and safety of bevacizumab in combination with docetaxel for the first-line treatment of elderly patients with locally recurrent or metastatic breast cancer: results from AVADO. *Eur J Cancer* 2011; **47**:2387–95.
- Robert NJ, Diéras V, Glaspy J, Brufsky AM, Bondarenko I, Lipatov ON, *et al.* RIBBON-1: randomized, double-blind, placebo-controlled, phase III trial of chemotherapy with or without bevacizumab for first-line treatment of human epidermal growth factor receptor 2-negative, locally recurrent or metastatic breast cancer. *J Clin Oncol* 2011; **22**:412–413.
- Moreno-Aspitia A, Morton RF, Hillman DW, Lingle WL, Rowland KM Jr, Wiesenfeld M, *et al.* Phase II trial of sorafenib in patients with metastatic breast cancer previously exposed to anthracyclines or taxanes: North Central Cancer Treatment Group and Mayo Clinic Trial N0336. *J Clin Oncol* 2009; **27**:11–15.
- Yardley DA, Dees EC, Myers SD, Li S, Healey P, Wang Z, *et al.* Phase II open-label study of sunitinib in patients with advanced breast cancer. *Breast Cancer Res Treat* 2012; **136**:759–767.
- Li Y-H, Zhou Y, Wang Y-W, Tong L, Jiang R-X, Xiao L, *et al.* Comparison of apatinib and capecitabine (Xeloda) with capecitabine (Xeloda) in advanced triple-negative breast cancer as third-line therapy: a retrospective study. *Medicine (Baltimore)* 2018; **97**:e12222.
- Zhu A, Yuan P, Wang J, Fan Y, Luo Y, Cai R, *et al.* Apatinib combined with chemotherapy in patients with previously treated advanced breast cancer: An observational study. *Oncol Lett* 2019; **17**:4768–4778.

- 18 Danni L, Lingyun Z, Jian W, Hongfei Y, Lu X, Peng Y, *et al*. Significant response to apatinib monotherapy in heavily pretreated advanced HER2-positive breast cancer: a case report and literature review. *Cancer Biol Ther* 2020; **21**:590–596.
- 19 Zhou Y, Zhang W, Tang F, Luo Y, Min L, Zhang W, *et al*. A case report of apatinib in treating osteosarcoma with pulmonary metastases. *Medicine (Baltimore)* 2017; **96**:e6578.
- 20 Liu H, Liu B, Ma Y, Guo L, Wu D, Shi A, Liu M. Giant fungated locally advanced breast carcinoma responded to hypofractionated radiotherapy combined with apatinib: a case report and literature review. *Cancer Manag Res* 2021; **13**:605–611.
- 21 Yee C, Alayed Y, Drost L, Karam I, Vesprini D, McCann C, *et al*. Radiotherapy for patients with unresected locally advanced breast cancer. *Ann Palliat Med* 2018; **7**:373–384.