



Knot-Tying versus Knotless Suture Anchors for Arthroscopic Bankart Repair: A Comparative Study

Jae Woo Shim, Tae Wan Jung, Il Su Kim, and Jae Chul Yoo

Department of Orthopedic Surgery, Sungkyunkwan University College of Medicine, Samsung Medical Center, Seoul, Korea.

Purpose: This study aimed to compare the results of using knotless and knot-tying suture anchors in arthroscopic Bankart repair.

Materials and Methods: The patients who underwent arthroscopic Bankart repair between 2011 and 2017 using knot-tying and knotless suture anchors were retrospectively reviewed. We collected demographic data, clinical scores (pain visual analogue scale), functional visual analogue scale, American Shoulder and Elbow Society scores, and Rowe score), and range of motion (ROM). Re-dislocation and subjective anterior apprehension test rates between the two techniques were also analyzed.

Results: Of the 154 patients who underwent arthroscopic Bankart repair, 115 patients (knot-tying group: n=61 and knotless group: n=54) were included in this study. Of the 115 patients, 102 were male and 13 were female. The mean patient age was 27 years (range: 17-60), and the mean follow-up period was 43 months (range: 24-99). There were no significant differences in the final clinical scores and ROM between the two groups. Re-dislocation was observed in 6 (9.8%) and 4 (7.3%) patients in the knot-tying and knotless groups, respectively. Apprehension was observed in 11 (18.0%) and 12 (22.2%) patients in the knot-tying and knotless groups, respectively. There were no significant differences between the two groups in regards to re-dislocation and anterior apprehension.

Conclusion: Re-dislocation rates and clinical scores were similar with the use of knotless and knot-tying suture anchors in arthroscopic Bankart repair after a minimal 2 year follow-up.

Key Words: Shoulder, arthroscopy, joint instability, bankart lesions, suture anchors

INTRODUCTION

Arthroscopic Bankart repair using suture anchors is a widely accepted method for restoring the labrum to the glenoid rim.^{1,2} Improvements in both arthroscopic technique and implant quality have significantly improved clinical outcomes associated therewith.³ However, traditional knot-tying suture anchors are highly dependent on knot security, which raises concerns for quality, consistency, and other technical challenges posed

by the procedure. Concerns have also been raised in regards to harmful abrasion to both cartilage surfaces of the glenohumeral joint from knots and other suture materials.⁴⁻⁶ Meanwhile, knotless suture anchors confer advantages of being easier to employ with new devices and less concerns for cartilage abrasion due to low profile suture materials and no knots all while providing adequate knot security and tension.⁴

Several studies have reported that re-dislocation rates and clinical outcomes are similar with the use of knot-tying and knotless suture anchors in arthroscopic Bankart repair.⁷⁻¹⁰ In a study by Wu, et al.,¹⁰ the knotless suture anchor group had lower recurrent subluxation rates than the knot-tying suture anchor group, while re-dislocation rates were similar between the groups during a mean follow-up of 5 years. However, other studies have reported inferior results with knotless suture anchors, compared to knot-tying suture anchors.¹¹⁻¹³ These reports, however, may be outdated with newer and better technique for knotless anchors now available. Indeed, in a biomechanical study by Nho, et al.,¹³ knotless suture anchors required less single load to achieve a displacement of 2 mm than knot-tying suture anchors.

Received: April 2, 2021 **Revised:** June 2, 2021

Accepted: June 7, 2021

Corresponding author: Jae Chul Yoo, MD, Department of Orthopedic Surgery, Samsung Medical Center, Sungkyunkwan University School of Medicine, 81 Irwon-ro, Gangnam-gu, Seoul 06351, Korea.

Tel: 82-2-3410-3509, Fax: 82-2-3410-3501, E-mail: shoulderyoo@gmail.com

•The authors have no potential conflicts of interest to disclose.

© Copyright: Yonsei University College of Medicine 2021

This is an Open Access article distributed under the terms of the Creative Commons Attribution Non-Commercial License (<https://creativecommons.org/licenses/by-nc/4.0>) which permits unrestricted non-commercial use, distribution, and reproduction in any medium, provided the original work is properly cited.

As more clinical studies comparing the use of knot-tying and knotless suture anchors are being performed, more evidence supporting the use of knotless suture anchors is emerging. This study aimed to compare clinical scores and re-dislocation rates between knot-tying and knotless suture anchors in arthroscopic Bankart repairs. We hypothesized that re-dislocation rates and clinical scores would be similar between knotless suture anchors and knot-tying suture anchors.

MATERIALS AND METHODS

Patient selection

This retrospective, non-randomized, comparative study was approved by our Institutional Review Board (IRB No. SMC 2019-07-017-005), and the requirement for informed patient consent was waived. We enrolled consecutive patients who underwent arthroscopic Bankart repair at our center from January 2011 to August 2017. All patients included in this study had a history of anterior shoulder dislocation due to trauma. In all patients, the presence of a Bankart lesion was confirmed using MRI. Patients with a bony Bankart lesion requiring an additional procedure for bone fixation, those with a glenoid bone loss of >20%, those with a concomitant rotator cuff tear, those with humeral avulsion of the glenohumeral ligament, those with revision case, those with compensation, and those who were followed up for <2 years were excluded.

The patients were divided into a knot-tying or knotless group depending on the type of suture anchor used. The classical knot-tying technique was performed from 2011 to 2014, while the knotless method using knotless suture anchors (PushLoc, Ar-

threx, Naples, FL, USA) was performed from March 2015.

Surgical procedure

All surgical procedures were performed by a single senior surgeon. After induction of general anesthesia, the patient was placed in a semi-lateral decubitus position with a 30° posterior tilt. Three standard portals were used: the posterior portal served as a viewing portal, while the anteroinferior and anterosuperior portals served as working portals. Diagnostic arthroscopy was performed to identify anteroinferior glenoid lesions and Hill-Sachs lesions. Concomitant lesions, such as rotator cuff tears, SLAP lesions, and biceps lesions, were also evaluated. After diagnostic arthroscopy, the capsulolabral complex was mobilized, and the labral edge was debrided using a motorized shaver. All of the capsulolabral complex was mobilized to the 7 o'clock position (Right shoulder) (Fig. 1A). This was identical in both the knot-tying and knotless groups. The anterior glenoid neck was decorticated using rasps and burrs. Additional troughs were made along the margin of the glenoid at sites planned for use in reattaching the labrum.¹⁴

The first suture anchor was inserted into the anterior glenoid approximately at the 5:30-6 o'clock position and 1-2 mm from the glenoid rim. Either double-loaded SutureTak (Arthrex) or Bio Mini-Revo (Linvatec, Largo, FL, USA) suture anchors were used. In order to decrease the inferior pouch, a mattress stitch was used as the most inferior stitch and secured using a non-sliding knot tying technique (Revo knot) (Fig. 1B).

In the knot-tying group, the second and third anchors were inserted at the 4:30 and 3 o'clock positions, respectively, in the same manner as the first anchor. Additional anchors were placed as necessary up to the 1 o'clock position (Fig. 1B). A minimum of

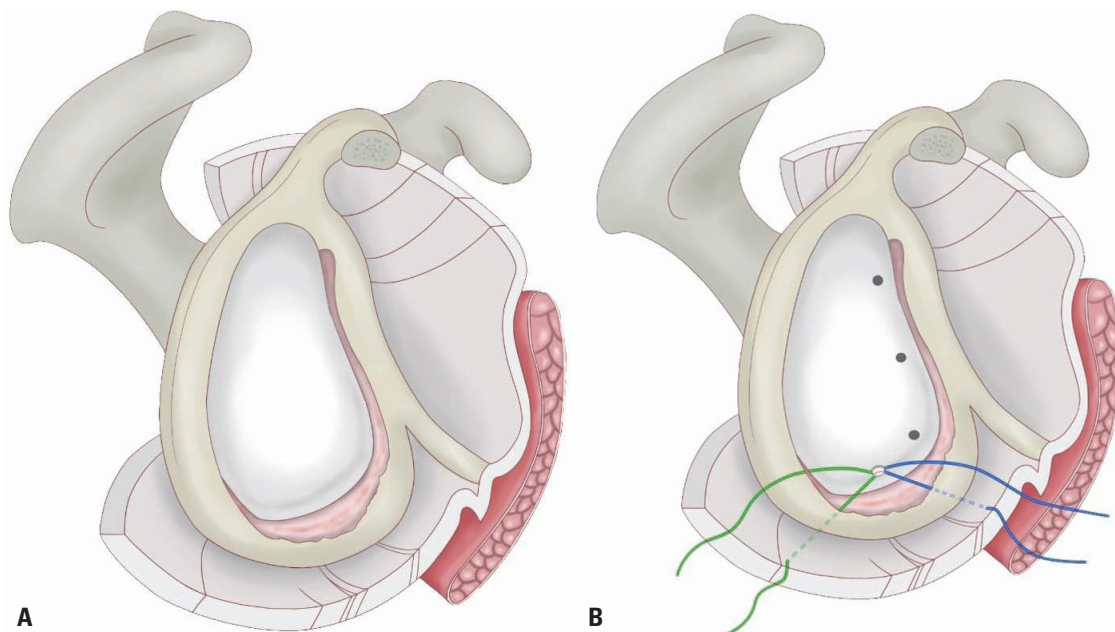


Fig. 1. (A) All of the capsulolabral complex was mobilized to the 7 o'clock position. The most inferior suture anchors was inserted at the 5:30-6 o'clock position, and a mattress stitch was used. (B) Additional anchors were inserted at the 4:30, 3, and 1 o'clock positions.

three-four suture anchors were used for each patient. Depending on the tissue, either a mattress stitch or a simple stitch was used and secured using a non-sliding knot tying technique (Fig. 2A). In the knotless group, the most inferior suture anchor was a knot-tying suture anchor secured using a mattress stitch in the same manner used in the knot-tying group. PushLock (Arthrex) anchors were used for the remaining anchors. The labrum was sutured with Fiberwire (Arthrex) using a simple stitch for 4:30 and 3:00 anchors with both ends of the suture fixed using a PushLock anchor (Fig. 2B).

Postoperative rehabilitation

All patients underwent the same rehabilitation protocol. A sling with an abduction pillow conferring 20° abduction with a neutral rotation was applied for 6 weeks postoperatively; during this period, the patients were not allowed to perform any passive or active range of motion (ROM) exercises. After 6 weeks of immobilization, the sling and pillow were removed, and gentle passive ROM exercises were started. As the patients gained confidence and started to achieve nearly full passive ROM, they were allowed to perform active or active-assisted motion exercises. Strengthening exercises were started 13 weeks after the surgery using graduated elastic bands; the previous stretching exercises were continued. Six months after the surgery, all other activities, including sport activities, were allowed if the patient experienced only minimal pain.

Clinical evaluation

The preoperative demographic data and operative findings for each patient were collected. Clinical evaluations were performed the day before surgery; at 6 months, 1 year, and 2 years postoperatively; and during the final follow-up. The pain visual analogue scale (pVAS), functional visual analogue scale (fVAS), American Shoulder and Elbow Society (ASES), and Rowe score and ROM

were collected. The clinical scores were collected by a single physiotherapist who was unaware of this study. ROM was measured by the surgeon during regular follow-up using the following maneuvers: forward elevation, external rotation at the side, and internal rotation using the vertebral level method. For statistical analysis, we converted the buttocks to 1, L5-L1 to 2-6, and T12-T4 to 7-15. Any history of re-dislocation and subjective anterior apprehension were investigated. Subjective anterior apprehension was defined as an apprehension or pain reported by the patient during 90° abduction and maximal external rotation of the shoulder.

Statistical analysis

In a previous study,¹⁵ the standard deviation of postoperative Rowe score was 7.0, and the minimal clinically important difference was 9.7. A sample size of 32 subjects for each group was sufficient to detect five different Rowe score with an α -error of 0.05 and 80% statistical power.

The preoperative and postoperative values of the measured variables were analyzed using the paired t-test. To compare results between the two groups, the chi-square test was used for categorical variables, while two sample t-tests or the Wilcoxon rank sum test were used for continuous variables. To compare postoperative Rowe score between the two groups, an equivalence test was performed with a clinical margin of 9.¹⁵ A Cox proportional hazards model was used to analyze re-dislocation and subjective anterior apprehension rates while considering differences in follow-up periods. The Cox proportional hazards model was used to adjust demographic and preoperative data that differed significantly between the two groups. Sufficient statistical power (>0.80) was required to perform these comparisons. A p value of <0.05 was considered statistically significant. All statistical analysis was performed using SAS version 9.4 (SAS institute, Cary, NC, USA).

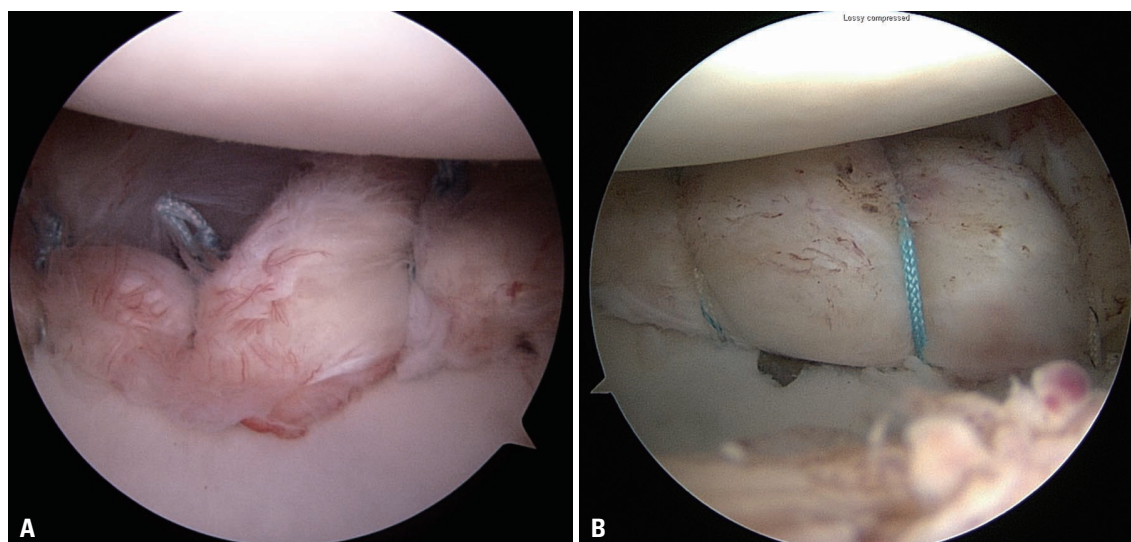


Fig. 2. Arthroscopic Bankart repair using knot-tying (A) vs. knotless (B) anchors.

RESULTS

Sixty-one patients in the knot-tying group and 54 patients in the knotless group were ultimately included in this study (Fig. 3). Of the 115 patients, 102 were male and 13 were female. The mean patient age was 27 years (range: 17–60), and the mean follow-up period was 43 months (range: 24–99).

Of the 115 patients, 81 (37 in knot-tying group and 44 in knotless group) were available for final follow-up at our outpatient clinic at a minimum of 2 years postoperatively. The other 34 patients were followed up through a telephonic survey. Dislocation history, subjective anterior apprehension, and pVAS, fVAS, and ASES scores were analyzed in all patients, including those surveyed over the telephone. ROM and Rowe score were analyzed in the 81 patients who visited the outpatient clinic for the last follow-up.

The demographic data of all patients are summarized in Table 1. The follow-up period of the knot-tying group was significantly longer than that of the knotless group, and the proportion of heavy workers was significantly higher in the knotless group than in the knot-tying group. The preoperative and operative data are summarized in Table 2. The concomitant remplissage procedures performed were significantly higher in the knotless group than in the knot-tying group.

Clinical scores and ROM

The preoperative and postoperative clinical scores of all patients are summarized in Table 3. Clinical scores improved significantly after surgery. The preoperative and postoperative clinical scores and ROM measurements of each group are summarized in Table 4. There were no statistically significant differences in postoperative clinical scores between the two groups. The postoperative Rowe score between the two groups were also similar (statistical power: 0.934) because of performing an equivalence test using a clinical margin of 9.

Re-dislocation and subjective anterior apprehension

Re-dislocation occurred in 10 patients (8.7%), and subjective

anterior apprehension was observed in 23 patients (20.0%). Of the 10 patients who experienced re-dislocation, five underwent revision surgery: revision arthroscopic Bankart repair was performed on 2 patients, while the Latarjet procedure was performed on the remaining 3 patients.

As shown in Table 2, there was a significant difference between the two groups in the number of patients who underwent a remplissage procedure. The proportion of patients with a first-time dislocation injury was not significantly different between the two groups. However, we considered first-time dislocation as an important variable. Adjustment was performed for this. A Cox proportional hazards model was used to adjust for remplissage procedures and first-time dislocation injuries, and there was no difference between the two groups after adjustment (Table 5). The subjective anterior apprehension rate in the knotless group was higher than that in the knot-tying group (hazard ratio: 2.523); however, there was no statistically significant difference between the two groups.

DISCUSSION

We compared re-dislocation rates and clinical scores between knot-tying and knotless groups. The re-dislocation rates of the knot-tying and knotless groups were 9.8% and 7.3%, respectively. There were no statistically significant differences in the re-dislocation rates and postoperative clinical scores between the

Table 1. Patient Demographic Data

	Knot-tying group (n=61)	Knotless group (n=54)	p value
Sex, male/female	55/6	47/7	0.597
Age, yr	26±11	27±9	0.273
Follow-up period in months	54±23	30±6	<0.001
Dominant arm involvement	38 (62)	29 (54)	0.351
Heavy labor worker	33 (54)	40 (74)	0.026
Athlete	5 (8)	2 (4)	0.444

Values are presented as n (%) or means±standard deviations.

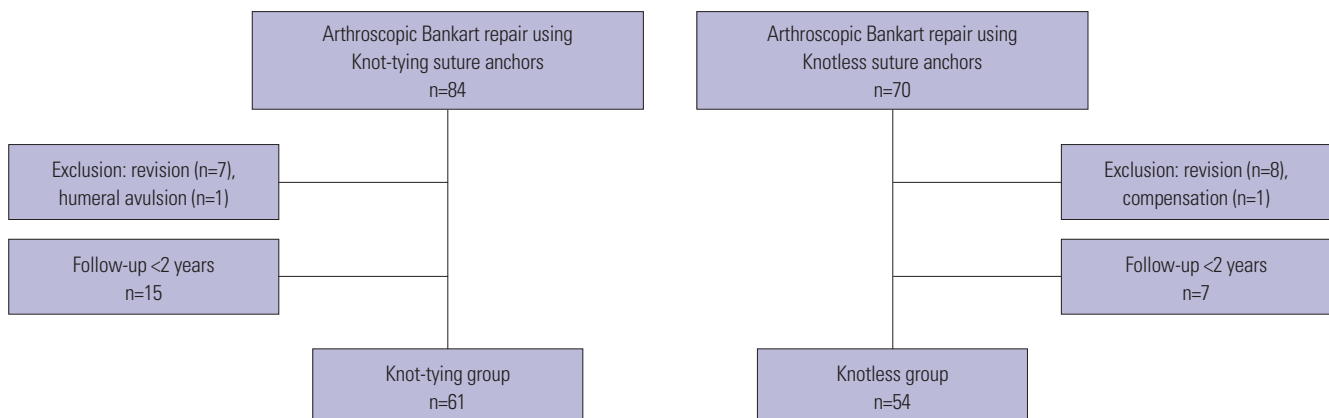


Fig. 3. Flowchart for patient selection.

Table 2. Patient Preoperative and Operative Data

	Knot-tying group (n=61)	Knotless group (n=54)	p value
Period from first dislocation to operation in months [median (25–75%)]	37 (14–74)	26 (10–63)	0.436
Total number of dislocations [median (25–75%)]	6 (3–10)	4 (2–10)	0.228
Patients with first-time shoulder dislocation	8 (14)	12 (23)	0.535
Operation time, min	64±15	60±14	0.195
No. of anchors	3.8±0.6	4.0±0.3	0.057
No. of stitches	4.9±0.7	4.8±0.7	0.634
Concomitant remplissage procedure performed	13 (21)	25 (46)	0.004
Glenoid bone loss of <20%	23 (38)	20 (36)	0.831
Concomitant SLAP lesion	1 (2)	1 (2)	0.726

SLAP, superior labrum from anterior to posterior. Values are presented as n (%) or means±standard deviations.

Table 3. Preoperative and Postoperative Clinical Scores for All Patients

	pVAS	fVAS	ASES	Rowe*
Preoperative	4.1±4.5	5.5±2.8	62±20	35±18
Final follow-up	1.1±1.3	8.1±1.2	86±13	91±9.5
p value	<0.001	<0.001	<0.001	<0.001

pVAS, pain visual analog scale; fVAS, functional visual analog scale; ASES, American Shoulder and Elbow Society.

Values are presented as means±standard deviations.

*Data of 81 patients, excluding those followed up through a telephonic survey.

two groups.

The incidence of re-dislocation is an important outcome since shoulder dislocation is the primary indication for performing Bankart repairs. Other studies^{6,9,10,16} have reported a 2–13% re-dislocation rate with the use of knotless suture anchors. In a previous study by Wu, et al.,¹⁰ 34 patients in the knotless suture anchor group were followed for an average of 4.8 years, and a re-dislocation rate of 9% was noted. In a study by Ng and Kumar,⁹ 1 of 42 patients in the knotless suture anchor group experienced re-dislocation. In our study, the average follow-up period was 30 months, and the re-dislocation rate was 7.3%. Using one knot-tying suture anchor with two or three knotless suture anchors in the knotless group, we obtained re-dislocation rates that were comparable with other studies.

The subjective anterior apprehension rates in our study were 18% and 22% in the knot-tying and knotless groups, respectively. In a study by Wu, et al.,¹⁰ the positive apprehension test rates were 28% and 9% in the knot-tying and knotless groups, respectively. Furthermore, the knot-tying group had a higher subluxation rate than the knotless group. Although we included subjective apprehension, subjective anterior apprehension rates in our study were comparable to those reported in other studies. Nevertheless, subjective anterior apprehension was more commonly noted in the knotless group than in knot-tying group, although the difference was not statistically significant. Also, the occurrence of re-dislocation tended to occur earlier in the knotless group. In our study, the proportion of patients working as heavy workers was higher in the knotless group than in the knot-tying group; this factor may have affected the increases in re-dislocation and apprehension. A remplissage procedure was also

Table 4. Preoperative and Postoperative Clinical Data for Each Group

	Knot-tying group	Knotless group	p value
pVAS			
Preoperative	4.3±3.1	3.8±5.7	0.070
Final follow-up	1.0±1.4	1.3±1.2	0.115
fVAS			
Preoperative	5.4±3.1	5.6±2.4	0.883
Final follow-up	8.2±1.2	8.0±1.1	0.399
ASES			
Preoperative	58±22	66±16	0.056
Final follow-up	87±15	85±11	0.065
Rowe*			
Preoperative	38±20	33±17	0.326
Final follow-up	92±9	90±10	0.087
ROM* (forward elevation), °			
Preoperative	155±21	164±13	0.003
Final follow-up	164±8	165±8	0.475
ROM* (external rotation), °			
Preoperative	56±18	66±10	0.002
Final follow-up	65±21	63±13	0.793
ROM*[†] (internal rotation), °			
Preoperative	11.5±3.5	12.1±3.1	0.377
Final follow-up	12.2±2.3	11.8±2.0	0.512

pVAS, pain visual analog scale; fVAS, functional visual analog scale; ASES, American Shoulder and Elbow Society; ROM, range of motion.

Values are presented as means±standard deviations.

*Data of 81 patients excluding those followed up through a telephone survey, [†]We converted the buttocks to 1, L5-L1 to 2-6, and T12-T4 to 7-15.

performed more often in the knotless group, which is likely due to the new trend toward remplissage on Bankart repair and broader indications during the period of knotless repair. This also thought to have been related to more severe cases of Hill-Sachs lesions than in the knot-tying group. While the remplissage procedure is advantageous for stability, humeral bone defects are disadvantageous.¹⁷ This factor may also have increased the re-dislocation and apprehension rates.

There were several biases in comparing re-dislocation rates in our study. In a previous study on the long-term outcomes of arthroscopic Bankart repair,¹⁸ a re-dislocation rate of 64% was

Table 5. Postoperative Re-Dislocation and Subjective Anterior Apprehension

	Knot-tying group	Knotless group	p value	p value after adjustment*
Re-dislocation	6 (9.8)	4 (7.3)	0.710	0.539
Months to 1st dislocation	30±30	23±12		
Subjective anterior apprehension	11 (18.0)	12 (22.2)	0.415	0.061

Values are presented as n (%) or means±standard deviations.

*Adjustment for remplissage procedure and first-time dislocation history using a Cox proportional hazards model.

recorded within the first 2 years, and all patients experienced re-dislocation within 5 years. In our study, the average follow-up periods of the knot-tying and knotless groups were 54 and 30 months (due to different cohort period), respectively, which is a statistically significant difference. To account for this, a Cox proportional hazards model was applied. Meanwhile, previous studies have shown that the use of the remplissage procedure can lower re-dislocation rates.¹⁹ In our study, a remplissage procedure was performed more often in the knotless group than in the knot-tying group. Also, having a first-time dislocation can also affect the re-dislocation rate,^{20,21} and there were more patients with first-time dislocations in the knotless group than in the knot-tying group, although this difference was not statistically significant. Cox proportional hazards model was performed to adjust for the use of the remplissage procedure and the presence of first-time dislocations, and there were no significant differences in re-dislocation and positive anterior apprehension test rates after adjustment (Table 5).

There was also a bias in collecting the results. About 30% of patients were investigated through telephone surveys. The knot-tying group showed a higher rate of telephone surveys than the knotless group. However, we defined re-dislocation and apprehension subjectively, and we determined that it could be accurately investigated through a telephone survey. There was no statistical difference in re-dislocation and subject anterior apprehension rates when analyzed only in patients with outpatient follow-up.

The use of knotless suture anchors has several advantages; it offers a simple but reliable fixation method, the knots are unexposed, and operation times are shorter.^{4,9,10,22} Our center started using knotless suture anchors in 2015. However, we were not certain on the mattress type stitch in the 6 o'clock position, where we used double load sutures: we did use a knot-tying suture anchor for the 6 o'clock position. Although we did not use knotless sutures for all anchors, there were no differences in re-dislocation rates. Several studies^{6,9,23} have also reported comparable re-dislocation rates and clinical outcomes between knotless and knot-tying suture anchors. Based on these results, our center has been performing Bankart repairs exclusively using knotless suture anchors since 2017. While we expected that operation times would be shorter in the knotless group, there was no statistical difference in the operation times between groups: perhaps, performing more remplissage procedures in the knotless group may have lengthened the operation times.

We observed statistically significant improvements in clinical

outcomes in both groups, and there was no difference in preoperative and postoperative clinical scores between the two groups. In a study by Ng and Kumar,⁹ patients in the knotless group reported an improvement in pVAS scores from 2.8 preoperatively to 0.9 postoperatively. In a study by Wu, et al.,¹⁰ the postoperative pVAS and Rowe score in the knotless group were 1.3 and 90.5, respectively. The clinical scores observed in our study were similar to those reported in other studies.^{9,10}

Our study has several limitations. First, it has a retrospective design. Second, there were differences between the two groups regarding the follow-up period and the rate in which concomitant remplissage procedures were performed. To reduce possible bias, we analyzed these variables after statistical adjustment was performed. However, after a longer follow-up period, the clinical results might differ. Third, knot-tying suture anchors were still used in the 6 o'clock position for patients in the knotless group; this makes the comparison of knotless with knot-tying suture anchors unclear. Finally, the level of sports activity for each patient was not accurately evaluated.

In conclusion, re-dislocation rates and clinical scores were similar with the use of knotless and knot-tying suture anchors in arthroscopic Bankart repairs. This study supports the use of knotless suture anchors in Bankart repair.

AUTHOR CONTRIBUTIONS

Conceptualization: Jae Chul Yoo. **Data curation:** Jae Woo Shim, Tae Wan Jung, and Il Su Kim. **Formal analysis:** Jae Woo Shim, Tae Wan Jung, and Il Su Kim. **Funding acquisition:** Jae Woo Shim and Jae Chul Yoo. **Investigation:** Jae Woo Shim, Tae Wan Jung, and Il Su Kim. **Methodology:** Jae Woo Shim and Jae Chul Yoo. **Project administration:** Jae Woo Shim and Jae Chul Yoo. **Resources:** Jae Woo Shim, Tae Wan Jung, and Il Su Kim. **Software:** Jae Woo Shim, Tae Wan Jung, and Il Su Kim. **Supervision:** Jae Chul Yoo. **Validation:** Jae Woo Shim and Jae Chul Yoo. **Visualization:** Jae Woo Shim and Jae Chul Yoo. **Writing—original draft:** Jae Woo Shim, Tae Wan Jung, and Il Su Kim. **Writing—review & editing:** Jae Woo Shim and Jae Chul Yoo. **Approval of final manuscript:** all authors.

ORCID iDs

Jae Woo Shim <https://orcid.org/0000-0002-3169-5197>
 Tae Wan Jung <https://orcid.org/0000-0002-3954-4318>
 Il Su Kim <https://orcid.org/0000-0002-6683-5276>
 Jae Chul Yoo <https://orcid.org/0000-0001-8378-1583>

REFERENCES

1. Gao B, DeFroda S, Bokshan S, Ready LV, Sullivan K, Etzel C, et al. Arthroscopic versus open bankart repairs in recurrent anterior shoulder instability: a systematic review of the association between publication date and postoperative recurrent instability in systematic reviews. *Arthroscopy* 2020;36:862-71.
2. Owens BD, Harrast JJ, Hurwitz SR, Thompson TL, Wolf JM. Surgical trends in bankart repair: an analysis of data from the American Board of Orthopaedic Surgery certification examination. *Am J Sports Med* 2011;39:1865-9.
3. Brown L, Rothermel S, Joshi R, Dhawan A. Recurrent instability after arthroscopic bankart reconstruction: a systematic review of surgical technical factors. *Arthroscopy* 2017;33:2081-92.
4. Thal R. Knotless suture anchor: arthroscopic bankart repair without tying knots. *Clin Orthop Relat Res* 2001;390:42-51.
5. Riboh JC, Heckman DS, Glisson RR, Moorman CT 3rd. Shortcuts in arthroscopic knot tying: do they affect knot and loop security? *Am J Sports Med* 2012;40:1572-7.
6. Cooke SJ, Starks I, Kathuria V. The results of arthroscopic anterior stabilisation of the shoulder using the bioknotless anchor system. *Sports Med Arthrosc Rehabil Ther Technol* 2009;1:2.
7. Alentorn-Geli E, Álvarez-Díaz P, Doblas J, Steinbacher G, Seijas R, Ares O, et al. Return to sports after arthroscopic capsulolabral repair using knotless suture anchors for anterior shoulder instability in soccer players: minimum 5-year follow-up study. *Knee Surg Sports Traumatol Arthrosc* 2016;24:440-6.
8. Kocaoglu B, Guven O, Nalbantoglu U, Aydin N, Haklar U. No difference between knotless sutures and suture anchors in arthroscopic repair of bankart lesions in collision athletes. *Knee Surg Sports Traumatol Arthrosc* 2009;17:844-9.
9. Ng DZ, Kumar VP. Arthroscopic bankart repair using knot-tying versus knotless suture anchors: is there a difference? *Arthroscopy* 2014;30:422-7.
10. Wu IT, Desai VS, Mangold DR, Camp CL, Barlow JD, Sanchez-Sotelo J, et al. Comparable clinical outcomes using knotless and knot-tying anchors for arthroscopic capsulolabral repair in recurrent anterior glenohumeral instability at mean 5-year follow-up. *Knee Surg Sports Traumatol Arthrosc*. 2020 May 18 [Epub]. Available at: <https://doi.org/10.1007/s00167-020-06057-7>.
11. Cho NS, Lubis AM, Ha JH, Rhee YG. Clinical results of arthroscopic bankart repair with knot-tying and knotless suture anchors. *Arthroscopy* 2006;22:1276-82.
12. Zumstein M, Jacob HA, Schneeberger AG. In vitro comparison of standard and Knotless metal suture anchors. *Arthroscopy* 2004;20:517-20.
13. Nho SJ, Frank RM, Van Thiel GS, Wang FC, Wang VM, Provencher MT, et al. A biomechanical analysis of anterior bankart repair using suture anchors. *Am J Sports Med* 2010;38:1405-12.
14. Shim SB, Jeong JY, Keum DH, Yoo JC. Does creating a trough on the anterior glenoid rim make a difference in Arthroscopic bankart repair using suture anchors? A mid-term follow-up retrospective study. *J Orthop Sci* 2019;24:250-7.
15. Park I, Oh MJ, Shin SJ. Minimal clinically important differences and correlating factors for the Rowe score and the American Shoulder and Elbow Surgeons score after arthroscopic stabilization surgery for anterior shoulder instability. *Arthroscopy* 2019;35:54-9.
16. Hayashida K, Yoneda M, Mizuno N, Fukushima S, Nakagawa S. Arthroscopic bankart repair with knotless suture anchor for traumatic anterior shoulder instability: results of short-term follow-up. *Arthroscopy* 2006;22:620-6.
17. Park I, Oh MJ, Shin SJ. Effects of glenoid and humeral bone defects on recurrent anterior instability of the shoulder. *Clin Orthop Surg* 2020;12:145-50.
18. Voos JE, Livermore RW, Feeley BT, Altchek DW, Williams RJ, Warren RF, et al. Prospective evaluation of arthroscopic bankart repairs for anterior instability. *Am J Sports Med* 2010;38:302-7.
19. Pandey V, Gangadharaiah L, Madi S, Acharya K, Nayak S, Karegouda LH, et al. A retrospective cohort analysis of arthroscopic bankart repair with or without remplissage in patients with off-track Hill-Sachs lesion evaluated for functional outcomes, recurrent instability, and range of motion. *J Shoulder Elbow Surg* 2020;29:273-81.
20. Lee SH, Lim KH, Kim JW. Risk factors for recurrence of anterior-inferior instability of the shoulder after arthroscopic bankart repair in patients younger than 30 years. *Arthroscopy* 2018;34:2530-6.
21. Wang SI. Management of the first-time traumatic anterior shoulder dislocation. *Clin Shoulder Elb* 2018;21:169-75.
22. Cho NS, Shim HS, Nam JH, Rhee YG. Clinical and structural outcomes of arthroscopic intraarticular knotless fixation for upper subscapularis tendon tears: a preliminary report. *Clin Shoulder Elbow* 2016;19:130-6.
23. Thal R, Nofziger M, Bridges M, Kim JJ. Arthroscopic bankart repair using Knotless or BioKnotless suture anchors: 2- to 7-year results. *Arthroscopy* 2007;23:367-75.