

Traumatic Gallbladder Rupture Treated by Laparoscopic Cholecystectomy

Noriyuki Egawa^a Junji Ueda^a Masatsugu Hiraki^a Takao Ide^a
Satoshi Inoue^b Yuichiro Sakamoto^b Hirokazu Noshiro^a

Departments of ^aSurgery and ^bEmergency and Critical Care Medicine, Faculty of Medicine, Saga University, Saga, Japan

Key Words

Gallbladder rupture · Trauma · Laparoscopic cholecystectomy

Abstract

Gallbladder rupture due to blunt abdominal injury is rare. There are few reports of traumatic gallbladder injury, and it is commonly associated with other concomitant visceral injuries. Therefore, it is difficult to diagnose traumatic gallbladder rupture preoperatively when it is caused by blunt abdominal injury. We report a patient who underwent laparoscopic cholecystectomy after an exact preoperative diagnosis of traumatic gallbladder rupture. A 43-year-old man was admitted to our hospital due to blunt abdominal trauma. The day after admission, abdominal pain and ascites increased and a muscular defense sign appeared. Percutaneous drainage of the ascites was performed, and the aspirated fluid was bloody and almost pure bile. He was diagnosed with gallbladder rupture by the cholangiography using the endoscopic retrograde cholangiopancreatography technique. Laparoscopic cholecystectomy was performed safely, and he promptly recovered. If accumulated fluids contain bile, endoscopic cholangiography is useful not only to diagnose gallbladder injury but also to determine the therapeutic strategy.

© 2016 The Author(s)
Published by S. Karger AG, Basel

Introduction

Traumatic gallbladder rupture occurs rarely and the incidence is reported to amount to approximately 2% of all blunt abdominal injuries [1, 2]. The main reason for the low incidence is that the gallbladder is protected by the surrounding organs, including the liver, in-

testines, omentum, and ribs. Preoperative diagnosis of gallbladder rupture is generally difficult because no specific symptoms are observed and other concomitant organ injuries are common [1, 2]. Gallbladder rupture is usually diagnosed at laparotomy because emergency operation is necessary due to other organ injuries. However, even in the isolated gallbladder rupture which does not need an emergency operation, prompt diagnosis of gallbladder rupture is quite challenging due to the lack of specific symptoms [1, 2]. It is very difficult to detect a defect in the gallbladder wall even when using imaging such as ultrasonography, computed tomography (CT), and magnetic resonance imaging (MRI). The prompt and exact diagnosis with gallbladder rupture is challenging. However, such images can detect the accumulation of intraperitoneal fluid including hemorrhage and bile. The presence of intraperitoneal fluid after blunt trauma needs to be interpreted [3]. If accumulated fluids contain bile, endoscopic cholangiography is useful not only to diagnose the gallbladder injury but also to determine the therapeutic strategy.

We present the details of a patient who underwent laparoscopic cholecystectomy after an exact preoperative diagnosis of traumatic gallbladder rupture.

Case Report

A 43-year-old man fell off a tractor and was subsequently run over by the tractor. On admission to our emergency department, his vital signs were stable and he was alert. Physical examination revealed right upper quadrant tenderness without signs of muscular defense. Complete blood count revealed a white blood cell count of 21,800/mm³ and a hemoglobin level of 14.0 g/dl. Enhanced abdominal CT suggested a mild liver laceration in hepatic segment 5 and a small amount of hemorrhagic ascites around the liver (fig. 1). The tentative diagnosis was liver injury with Edward's classification grade I, and conservative treatment was initiated. The day after admission, the right upper quadrant pain and ascites increased and a muscular defense sign appeared. Percutaneous drainage of the ascites was performed, and the aspirated fluid was bloody and almost pure bile. Although his abdominal pain improved after continuous drainage, the amount of biliary discharge reached 800 ml/day. MRI and ultrasonography revealed little about the source of the bile leakage; therefore, on the 10th day after abdominal blunt injury, endoscopic retrograde cholangiography was performed, and a diagnosis of gallbladder rupture was made (fig. 2).

Laparoscopic cholecystectomy was subsequently performed and revealed biliary ascites accumulated in the upper right abdomen with the gallbladder covered by edematous greater omentum. There were no injuries in other abdominal organs and no obvious injury in segment 5 of the liver. After isolating the gallbladder, a perforation was seen in the gallbladder body, as suggested by endoscopic retrograde cholangiography (fig. 3). The perforation in the gallbladder wall was sutured closed, and then standard cholecystectomy was performed. Histopathological examination of the excised gallbladder showed no specific findings except for mild inflammation. Inflammatory cells and granulation tissues were observed in the gallbladder wall. The postoperative course was uneventful and without complications.

Discussion

Gallbladder injury is most commonly caused by a penetrating wound [1]. Blunt traumatic gallbladder injury is rare, and the most common causes are accidents associated with motor vehicles, falls, blows, kicks, or industrial work [1, 2]. Blunt gallbladder injury is classified

into three types: contusion, avulsion, and laceration (rupture or perforation), and lacerations are the most common after blunt injury [2, 4]. The gallbladder injury in our case was categorized as a laceration with an exact preoperative diagnosis.

Preoperative diagnosis of gallbladder injury is challenging. CT scan is the most useful examination when diagnosing abdominal injuries, and avulsion gallbladder injuries can easily be diagnosed by CT because the gallbladder is torn from the liver and hemorrhage is obvious. However, no specific signs are revealed on CT for laceration gallbladder injuries [3, 5]. Despite the substantial leakage of bile into the peritoneal cavity in our case, we could not determine whether it was caused by a gallbladder injury or liver laceration, and further examinations and treatments were required because of the persistent high-volume bile leakage. As magnetic resonance cholangiopancreatography revealed little about the origin of the bile leakage, endoscopic retrograde cholangiopancreatography was planned [3].

Because gallbladder rupture is often associated with multiple organ injuries leading to peritonitis, laparotomy is recommended as soon as possible after the diagnosis [1, 2]. However, ruptured gallbladder alone has no associated hemodynamic disorders after successful abdominal drainage; therefore, emergent laparotomy is not required, and patients are good candidates for laparoscopic surgery. Also, the final diagnosis of gallbladder rupture can be confirmed laparoscopically and simultaneous minimally invasive treatment can then be performed.

In conclusion, management of gallbladder injuries varies with the presence of other concomitant organ injuries and the degree and type of gallbladder injury. In cases with gallbladder rupture simply diagnosed by direct cholangiography, laparoscopic cholecystectomy is the recommended treatment.

Statement of Ethics

The authors have no ethical conflicts to declare.

Disclosure Statement

The authors declare that they have no conflicts of interest.

References

- 1 Sharma O: Blunt gallbladder injuries: presentation of twenty-two cases with review of the literature. *J Trauma* 1995;39:576–580.
- 2 Soderstrom CA, Maekawa K, DuPriest RW Jr, Cowley RA: Gallbladder injuries resulting from blunt abdominal trauma: an experience and review. *Ann Surg* 1981;193:60–66.
- 3 Sondenaa K, Horn A, Nedrebo T: Diagnosis of blunt trauma to the gallbladder and bile ducts. *Eur J Surg* 2000;166:903–907.
- 4 Smith SW, Hasting TN: Traumatic rupture of the gallbladder. *Ann Surg* 1954;139:517–520.
- 5 Salzman S, Lutfi R, Fishman D, Doherty J, Merlotti G: Traumatic rupture of the gallbladder. *J Trauma* 2006;61:454–456.

Egawa et al.: Traumatic Gallbladder Rupture Treated by Laparoscopic Cholecystectomy

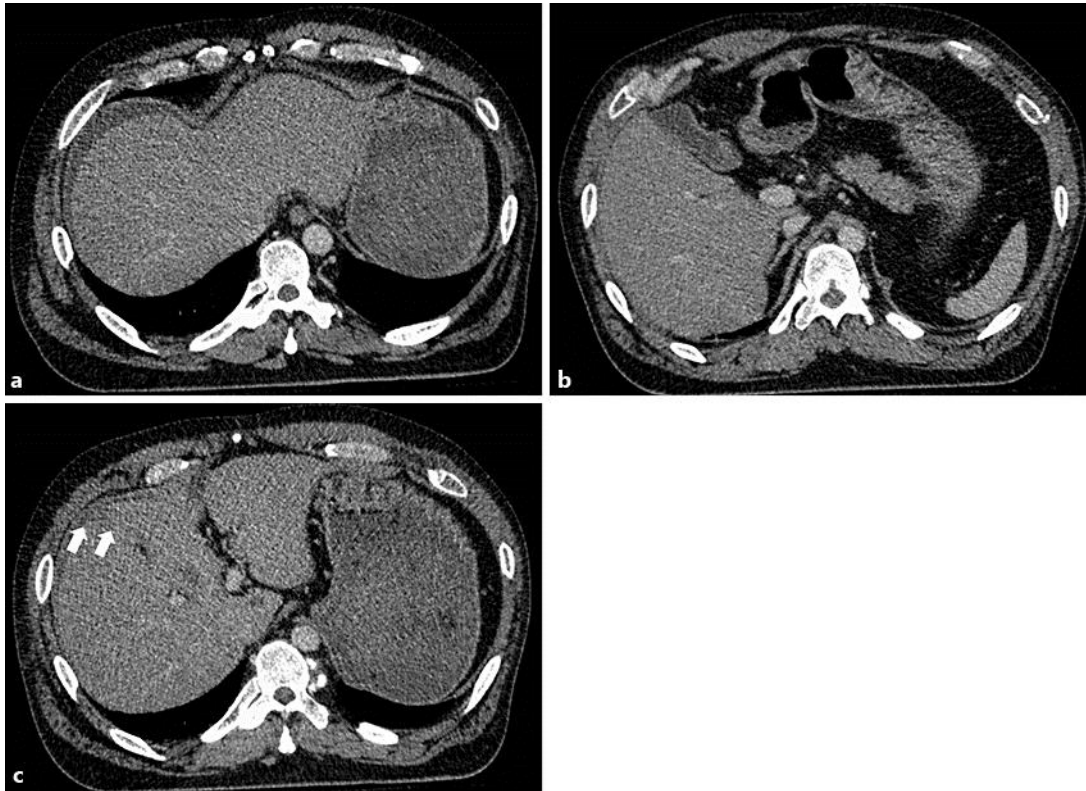


Fig. 1. **a** Enhanced abdominal CT on admission revealing hemorrhagic accumulation around the liver. **b** No apparent abnormal gallbladder findings were observed, but a costal cartilage fracture was seen. **c** Liver laceration was suspected (arrows).

Egawa et al.: Traumatic Gallbladder Rupture Treated by Laparoscopic
Cholecystectomy

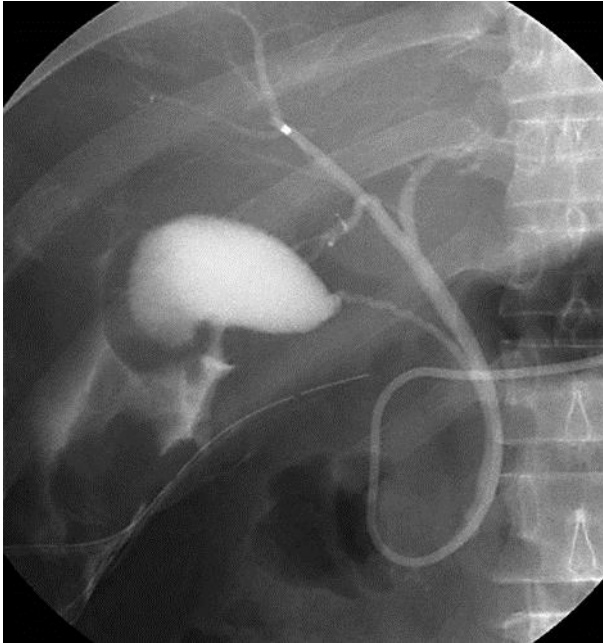


Fig. 2. Cholangiogram clearly revealing leakage of Urografin from the gallbladder.

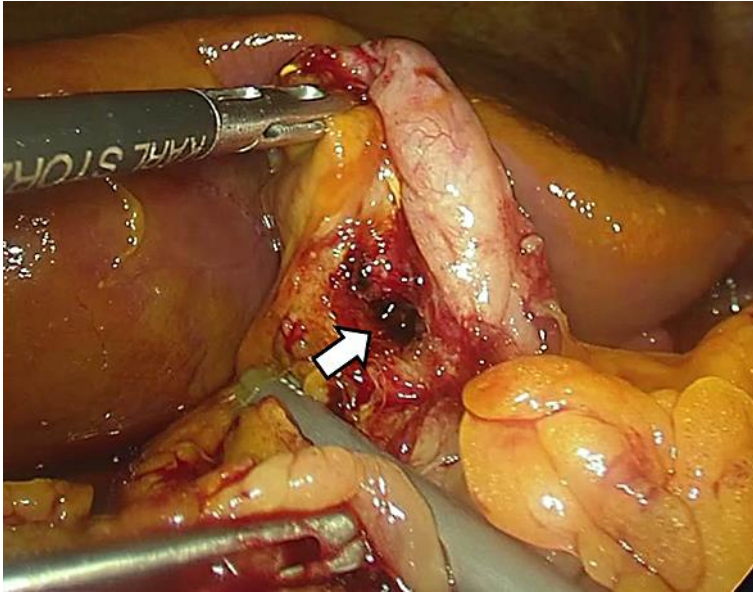


Fig. 3. Laparoscopy confirmed a perforation in the gallbladder body (arrow).