



Long-Term Result of Tibioperoneal Trunk Bypass with an Autogenous Graft Using the Varicose Great Saphenous Vein for Acute Limb Ischemia

Hyung-Kee Kim, Deokbi Hwang, and Seung Huh

Division of Vascular Surgery, Department of Surgery, Kyungpook National University Hospital, Kyungpook National University School of Medicine, Daegu, Korea

For the management of acute limb ischemia (ALI) and multilevel arterial occlusive disease, tibial bypass using the saphenous vein has been considered a mainstay due to the long-term durability in selected patients with acceptable saphenous veins and comorbid conditions. Traditionally, bypass using a varicose autogenous graft has been contraindicated due to the risk of late aneurysmal dilation and rupture. Here, we describe a patient who presented with ALI and received tibioperoneal trunk bypass using a varicose autogenous graft. The patient has been doing well during the 72-month follow-up without recurrent symptoms or revision. The follow-up images showed a favorably patent graft with mild aneurysmal changes at the valve cusp adjacent to the knee. If there are no other appropriate autologous veins for revascularization, a varicose autogenous vein graft may be a useful option for limb salvaging in selected patients with multilevel arterial occlusive diseases.

Received May 18, 2020

Revised July 16, 2020

Accepted August 18, 2020

Corresponding author: Hyung-Kee Kim

Division of Vascular Surgery, Department of Surgery, Kyungpook National University Hospital, 130 Dongdeok-ro, Jung-gu, Daegu 41944, Korea

Tel: 82-53-420-5605

Fax: 82-53-421-0510

E-mail: hkkim6260@knu.ac.kr

<https://orcid.org/0000-0002-4436-7424>

Key Words: Peripheral arterial disease, Operative therapy, Varicose veins, Ischemia

Copyright © 2020, The Korean Society for Vascular Surgery

This is an Open Access article distributed under the terms of the Creative Commons Attribution Non-Commercial License (<http://creativecommons.org/licenses/by-nc/4.0>) which permits unrestricted non-commercial use, distribution, and reproduction in any medium, provided the original work is properly cited.

Vasc Specialist Int 2020;36(3):170-173 • <https://doi.org/10.5758/vsi.200033>

INTRODUCTION

For the management of acute limb ischemia (ALI) and multilevel arterial occlusive diseases, distal bypass using a vein graft has been considered a mainstay due to the long-term durability in selected patients with an acceptable saphenous vein conduit and comorbid conditions [1,2]. In these cases, the great saphenous vein (GSV) has been regarded as the first choice for bypass conduits. However, the use of the GSV may be limited due to small caliber, previous harvest, and varicose degeneration of various extents. Traditionally, it is recommended that varicose vein grafts not be used for bypass conduits because of the risk of immediate rupture or long-term aneurysmal change [3,4]. However, a few case studies have been reported with successful varicose autogenous vein graft results [5,6]; there-

fore, it is difficult to draw firm conclusions about varicose vein grafts currently. Here, we describe our treatment and surgical consideration of a patient who presented with ALI due to prosthetic graft occlusion and received femoro-tibioperoneal trunk bypass using a varicose autogenous graft.

CASE

A 61-year-old male complained of right leg rest pain that had persisted for 5 hours. His medical history was significant for hypertension, diabetes mellitus, hyperlipidemia, and 40 years of smoking. Thirteen months ago, he had received a right femoropopliteal bypass to the below-knee popliteal artery with an ipsilateral reversed GSV due to his first toe ulcer at another hospital. However, the next day, the vein graft had occluded, and he received the same

bypass surgery with a prosthetic graft. One month ago, the prosthetic graft had also occluded, and he received a thrombectomy with distal patch angioplasty using polytetrafluoroethylene (PTFE). Before presenting to our hospital, he had visited another hospital due to right leg pain and undergone duplex ultrasonography (DUS). On DUS, the prosthetic graft had re-occluded, and, thus, he had been transferred. Therefore, we suspected that this patient's symptoms were associated with ALI due to thrombotic occlusion of the PTFE graft in the setting of previous chronic limb-threatening ischemia (CLTI).

On physical examination, the right femoral pulse was palpable but no pulsation was noted at the ankle. Both calf

varicosities were also noted. Computed tomography (CT) scans revealed a long-segment femoropopliteal occlusion with prosthetic graft occlusion (Fig. 1). Urgent right femoro-tibioperoneal trunk bypass was planned under general anesthesia due to rest pain and a history of operation in this patient. However, the ipsilateral GSV had already been harvested for previous bypass surgery and a preoperative DUS evaluation revealed that the left GSV was complicated with varicose veins. The diameter of the left GSV was approximately 5 to 7 mm with some aneurysms measuring up to 9 mm, and reflux was noted in the whole length of the GSV (Fig. 2). The right small saphenous vein also demonstrated reflux, and there were no other appropriate arm veins for femoro-tibioperoneal trunk bypass. Therefore, we decided to use the left varicose GSV graft for bypass for limb salvaging instead of a prosthetic graft because tibioperoneal

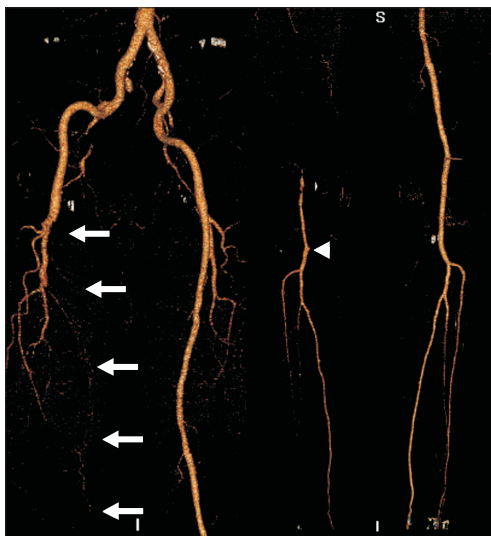


Fig. 1. Preoperative computed tomography angiography demonstrated long-segment femoropopliteal occlusion with total graft occlusion (white arrows). The stump of the previous distal anastomosis was located at the below-knee popliteal artery (arrowhead).

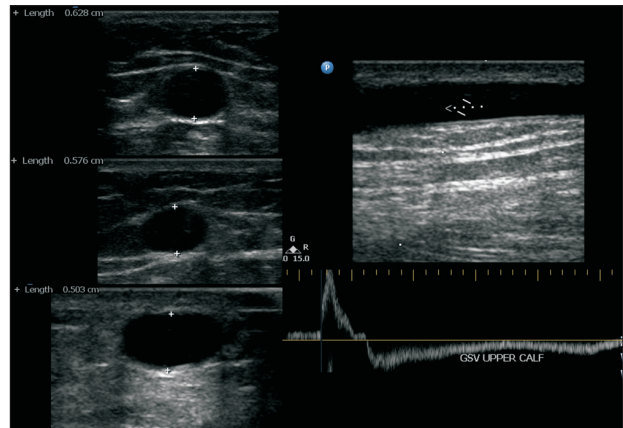


Fig. 2. Preoperative duplex ultrasonography for saphenous vein evaluation. The diameter of the left great saphenous vein (GSV) was about 5 to 7 mm, and reflux was noted in the whole length of the GSV.

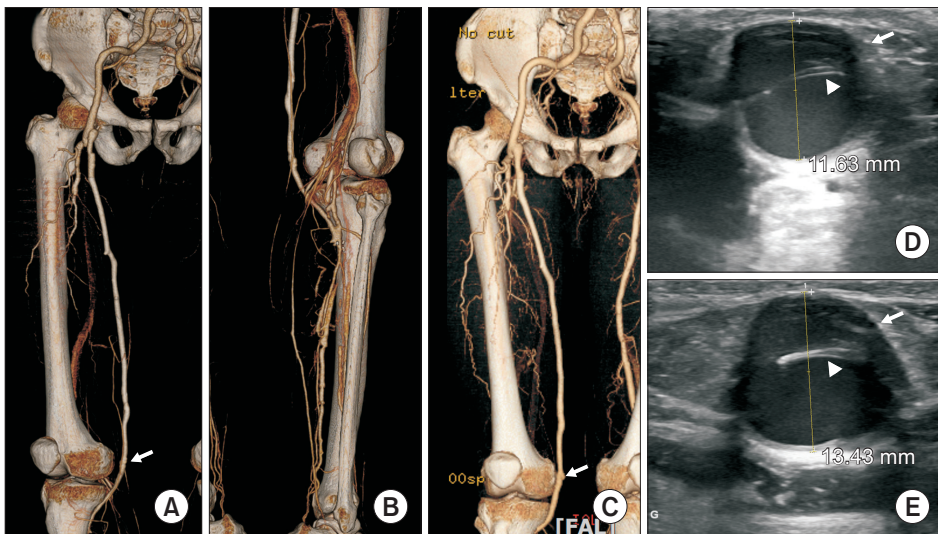


Fig. 3. Serial follow-up images of computed tomography angiography (CTA) and duplex ultrasonography (DUS). One segment of the valve cusp in the great saphenous vein demonstrated progressive aneurysmal dilatation during follow-up (arrow) and a further hypertrophied valve cusp (arrowhead). (A) Postoperative CTA; (B) posterior view of postoperative CTA; (C) CTA 1 year after operation; (D) DUS 3 years after operation; and (E) DUS 6 years after the operation.

trunk bypass was expected. While the vein graft was gently dilated with heparinized saline, one segment of aneurysmal dilatation was repaired with aneurysmorrhaphy by a plication suture. The remaining varicose vein graft was used at full length without splicing. As the whole length of the GSV demonstrated reflux, the harvested GSV was anastomosed in a non-reversed translocated fashion, and the graft was tunneled subcutaneously after proximal anastomosis. Valvulotomy was not performed.

The postoperative clinical course was uneventful and the rest pain disappeared immediately after the operation. The patient was discharged 7 days after operation, and the ankle-brachial index increased to 1.09 before discharge. Antiplatelet therapy consisted of dual therapy with aspirin and clopidogrel for one year, followed by aspirin monotherapy. He has been doing well during the 72 months of follow-up without recurrent symptoms or revision operation, and the follow-up images showed a favorably patent bypass graft (Fig. 3). The diameter of the GSV at the valve cusp adjacent to knee showed mild aneurysmal changes on CT scan measuring 9.4 mm immediately postoperatively, 10.8 mm at 1 year, 11.6 mm at 3 years, and 13.4 mm at 6 years on follow-up imaging (Fig. 3).

DISCUSSION

In general, bypass using a varicose autogenous vein graft has been considered to be complicated with aneurysmal dilatation and subsequent rupture. Therefore, many vascular surgeons are reluctant to use varicose vein grafts for bypass surgery. Few reports have demonstrated the immediate rupture or late aneurysmal degeneration of a varicose vein graft during follow-up [4]; however, the exact incidence and risk factors of aneurysmal dilatation of a varicose vein graft has not been well studied at this point. In cases with above-knee bypass surgery, a prosthetic graft is considered an alternative acceptable bypass conduit if there are no possible vein conduits with comparable long-term patency. In contrast, if the distal anastomosis of the bypass graft is to be made in the below-knee arteries, the results of prosthetic graft patency are considered to be poor. Therefore, guidelines recommend the saphenous vein graft as a conduit for bypass of this region [1,2]. In patients needing bypass surgery for CLTI and complex peripheral arterial occlusive diseases with no acceptable bypass conduit except a varicose vein, the decision for a prosthetic graft with distal modification or varicose autogenous vein graft is controversial and must be made according to surgeons' preference and patients' condition.

In our case, there were some notable points for discussion. First, follow-up duration was relatively long. Most of the anecdotal case reports regarding a varicose vein graft

reported short to mid-term results regarding the patency and aneurysmal changes [5,6]. However, the most important concern in using a varicose autogenous vein graft was late aneurysmal dilatation and subsequent rupture. We followed up this patient with radiologic imaging for 72 months. During the follow-up period, the vein graft was widely patent without stenosis, and revision operation had not been necessary. However, one GSV segment at the valve cusp near the knee joint showed progressive mild aneurysmal dilatation. Therefore, the varicose autogenous vein graft may be a viable option in selected patients without other appropriate autologous veins for revascularization; however, long-term follow-up is mandatory for the development of late aneurysmal changes. There are currently no specific recommendations about the technique and time for revision surgery. However, thrombus formation within aneurysmal changes can be an indication for revision since it can be a source of distal embolization, such as popliteal artery aneurysms. Second, the preferred location of the vein graft can be subcutaneous rather than the usual intermuscular location. As shown in this case, although not significant, one segment at the valve cusp of the varicose vein graft demonstrated progressive aneurysmal change over the 6 years of follow-up. Compared with intermuscular locations, subcutaneous bypass grafts have some benefits such as monitoring graft patency and aneurysmal changes. In addition, if aneurysmal dilatation needs revision operation, it is easier to approach and can even be performed under local anesthesia.

There exists another technical point for using the varicose autogenous vein graft for bypass surgery. In general, a vein graft can be used in 3 different configurations; in situ, reversed, and non-reversed translocated fashions. However, in situ bypass should not be performed in patients with the varicose GSV. To prevent vein graft aneurysm and rupture, all vein segments should be inspected thoroughly, and any aneurysmal changes or weak valve areas should be repaired. In addition, blind valvulotomy is at high risk of injuring the aneurysmal vein segments. Therefore, varicose vein grafts can be used in a reversed configuration [7] or a non-reversed translocated fashion as in the current case. In our case, preoperative DUS demonstrated reflux in the whole length of the GSV. During the operation, heparin solution was flushed through the proximal end of the GSV near the saphenofemoral junction after harvesting the contralateral GSV. During this process, it was determined that there was no interference in blood flow, and, thus, bypass surgery was performed in a non-reversed fashion with the advantage of a better size match. After proximal anastomosis, pulsatile arterial flow was demonstrated at the distal end of the vein graft; therefore, we did not perform valvulotomy. However, the vein being varicose does not mean that all

the valves in the GSV show reflux, and refluxed valves also have cusps which may interfere with the flow. Therefore, careful inspection for adequate flow is important and additional valvulotomy may be necessary in cases with non-reversed transposed varicose vein grafts.

There have been a few reports regarding the reinforcement of the varicose vein graft for bypass surgery. Minor limited dilatation of the varicose vein can be corrected by plication, tuck stitching, and resection with anastomosis. Furthermore, prosthetic external reinforcement can be applied to all or a part of the vein graft depending on the extent of venous dilatation [4,8-10]. Recently, Neufang et al. [4] reported good late graft patency and limb salvage (54% primary patency and 83% limb salvage rate at 5 years) combined with a low rate of late vein graft degeneration using external PTFE reinforcement of varicose autogenous vein grafts. In addition, Carella et al. [9] reported acceptable patency and amputation-free survival (57% primary patency and 86% amputation-free survival at 2 years) using a polyester external mesh. In our case, we did not use an external mesh or prosthetic graft for reinforcement because aneurysmal dilatation of the GSV was thought not to be severe in the operative field. However, mild progressive dilatation of one segment of the valve cusp was noted during follow-up. Therefore, external reinforcement using a prosthetic mesh or graft may be helpful in preventing late aneurysmal changes, especially in the valve cusp if varicose

veins are used for bypass surgery.

In summary, if there are no other appropriate autologous veins for revascularization, a varicose autogenous vein graft may be a useful option for limb salvage in selected patients with severe ischemic symptoms and multilevel arterial occlusive disease.

CONFLICTS OF INTEREST

The authors have nothing to disclose.

ORCID

Hyung-Kee Kim

<https://orcid.org/0000-0002-4436-7424>

Deokbi Hwang

<https://orcid.org/0000-0003-0050-6434>

Seung Huh

<https://orcid.org/0000-0002-0275-4960>

AUTHOR CONTRIBUTIONS

Conception and design: HKK, SH. Analysis and interpretation: HKK, SH. Data collection: DH, HKK. Writing the article: DH, HKK. Critical revision of the article: SH. Final approval of the article: all authors. Statistical analysis: none. Obtained funding: none. Overall responsibility: HKK.

REFERENCES

- 1) Aboyans V, Ricco JB, Bartelink MEL, Björck M, Brodmann M, Cohnert T, et al. Editor's choice-2017 ESC Guidelines on the Diagnosis and Treatment of Peripheral Arterial Diseases, in collaboration with the European Society for Vascular Surgery (ESVS). *Eur J Vasc Endovasc Surg* 2018;55:305-368.
- 2) Lawrence PF, Gloviczki P. Global Vascular Guidelines for patients with critical limb-threatening ischemia. *J Vasc Surg* 2019;69(6S):1S-2S.
- 3) Panetta TF, Marin ML, Veith FJ, Goldsmith J, Gordon RE, Jones AM, et al. Unsuspected preexisting saphenous vein disease: an unrecognized cause of vein bypass failure. *J Vasc Surg* 1992;15:102-110; discussion 110-112.
- 4) Neufang A, Espinola-Klein C, Savvidis S, Schmiedt W, Poplawski A, Vahl CF, et al. External polytetrafluoroethylene reinforcement of varicose autogenous vein grafts in peripheral bypass surgery produces durable bypass function. *J Vasc Surg* 2018;67:1778-1787.
- 5) Guntani A, Yoshiga R, Mii S. Distal bypass with a varicose vein graft for critical limb ischemia: report of a case. *Surg Case Rep* 2019;5:193.
- 6) Mun YS, Cho BS, Jang JH, Lee MS, Kwon OS. Femoropopliteal bypass with varicose greater saphenous vein. *Int J Angiol* 2016;25:e108-e110.
- 7) Chung CTY, Ko H, Kim HK, Mo H, Han A, Ahn S, et al. Thrombosis of a long-segment aneurysm from the iliac to popliteal artery associated with arteriovenous malformation and varicose veins. *Vasc Specialist Int* 2019;35:165-169.
- 8) Soury P, Peillon C, Watelet J, Planet M, Plissonnier D, Del Gallo G, et al. Prosthetic reinforcement of varicose saphenous vein grafts for infrainguinal bypass. *Ann Vasc Surg* 1999;13:290-293.
- 9) Carella GS, Stilo F, Benedetto F, David A, Risitano DC, Buemi M, et al. Femoro-distal bypass with varicose veins covered by prosthetic mesh. *J Surg Res* 2011;168:e189-e194.
- 10) Melliere D, Le Chevillier B, Kovarsky S. Wrapped autologous greater saphenous vein bypass for severe limb ischemia in patients with varicose veins. Preliminary report. *J Cardiovasc Surg (Torino)* 1995;36:117-120.