

Pathogenesis of Diarrhoea Caused by Astrovirus Infections in Lambs

By

D. R. SNODGRASS¹, K. W. ANGUS¹, E. W. GRAY¹, J. D. MENZIES¹, and G. PAUL²

¹ Animal Diseases Research Association, Moredun Institute,
Edinburgh, Scotland

² Wolfson Gastrointestinal Laboratories, Western General Hospital,
Edinburgh, Scotland

With 6 Figures

Accepted January 23, 1979

Summary

Experimental infection of 2-day-old gnotobiotic lambs with lamb astrovirus produced mild diarrhoea after an incubation period of about 48 hours. No other clinical symptoms developed. Infection was studied by immunofluorescent and histological examination of tissues from the lambs. Astroviruses infected only mature villus epithelial cells and subepithelial macrophages in the small intestine, where they produced partial villus atrophy. Infected enterocytes were replaced with cuboidal cells from the crypts, and the lesion gradually healed by 5 days after infection. No serological relationship was detected by immunofluorescence between lamb astrovirus antigen in gut sections and antisera to either calf or human astrovirus.

Introduction

Viruses of 28—30 nm diameter with a circular outline and stellate surface structure have been observed in faeces from diarrhoeic children (7, 14), lambs (15) and calves (19). The name astrovirus has been suggested for these morphologically distinctive viruses (6) and will be used in this paper.

Little is known of the pathogenic potential of these viruses. After oral inoculation they produced mild diarrhoea in lambs (15), and partial villus atrophy in calves (19) and inconsistently caused diarrhoea in adult human volunteers (5). This paper reports findings made on the pathogenesis of astrovirus infections in gnotobiotic lambs.

Materials and Methods

Infection of Lambs

Six gnotobiotic lambs were infected orally when approximately 24 hours old with intestinal contents from the third passage of lamb astrovirus in gnotobiotic lambs (15). Five of the lambs received 1.5 ml of a 0.22 μ m filtrate of a 20 per cent suspension of

these intestinal contents, while the sixth (that killed 120 hours after infection) received 1.5 ml of unfiltered bacteria-free contents. The inoculum appeared by electron microscopic examination to contain many fewer astroviruses after filtration. One lamb was killed at each of the following hours after infection (p.i.): 14, 23, 38, 45, 70 and 120. Five gnotobiotic lambs killed between 72 and 144 hours of age served as controls for the histology. Six gnotobiotic lambs between 72 and 408 hours of age were controls for lactase estimations.

Necropsy Procedures

Lambs were deeply anaesthetised with sodium pentobarbitone or halothane. Segments were obtained from jejunum (about 10 cm distal to the duodeno-jejunal flexure); from midgut; and from ileum (about 50 cm proximal to the ileo-caecal junction, from an area free of Peyer's patches). The lambs were then killed by exsanguination, and tissues collected from caecum, colon, kidney, liver and lung.

Histological Methods

Tissues for histological examination were fixed in 10 per cent formal saline and processed as described previously (16). Additional small (1 mm³) blocks of intestine were fixed in 3 per cent glutaraldehyde in phosphate buffer (pH 7.4) and processed to Araldite. Sections 1 µm thick were cut and stained by 10 per cent Giemsa, at 60° C.

Villus heights and crypt depths in HE-stained sections were measured by ocular micrometer on ten vertically-cut, full length villi and crypts at each site of small intestine.

Immunofluorescence

Additional portions of all tissues were frozen in a CO₂-ethanol freezing mixture. Lengths of small intestine and colon were filled with embedding medium (Tissue-Tek II, Lab-Tek Products) prior to freezing, to aid proper orientation of villi. Frozen tissues were mounted on microtome chucks and 6 µm sections cut on a cryostat. An antiserum to lamb astrovirus was prepared as follows:—a gnotobiotic lamb was infected orally with astrovirus, and reinfected 10 days later. After a further 4 days the lamb was given by intramuscular inoculation an astrovirus preparation partially purified by differential centrifugation of intestinal contents. Blood was collected for serum preparation 5 days after final inoculation. Tissue sections were treated with this antiserum, followed by fluorescein-conjugated rabbit anti-sheep globulin. Control sections were treated with gnotobiotic lamb antiserum to lamb rotavirus, followed by the conjugated anti-sheep globulin.

For purposes of serological comparison, astrovirus-containing gut sections were stained with calf antiserum to calf astrovirus (kindly supplied by Dr. J. C. Bridger, Compton, Berkshire) or human antiserum to human astrovirus (kindly supplied by Dr. J. B. Kurtz, Churchill Hospital, Oxford), followed by the appropriate fluorescein-conjugated globulins.

Enzyme Analysis

Additional portions of tissue from the three sites of small intestine were collected and stored at -20° C. Lactase estimations used the methods of DAHLQVIST (1).

Virus Detection

Faeces samples were collected daily from all lambs, and suspensions examined by electron microscopy for the presence of astrovirus (15).

Results

Clinical and Virological

The lambs killed at 14, 23 and 38 hours p.i. did not develop diarrhoea. The other three infected lambs developed diarrhoea 44–48 hours after infection, faeces changing from firm and dark brown in character to very loose and yellow.

Voluntary milk intake remained normal. Astrovirus was not observed in faeces from the lambs killed 14 and 23 hours p.i., but was first seen in the faeces of all other infected lambs between 38 and 48 hours p.i. At necropsy, astrovirus was detected in intestinal contents of all lambs except that killed 14 hours p.i.

The control lambs remained clinically normal, and passed firm brown faeces throughout the duration of the experiment. No virus particles were detected in their faeces.

Immunofluorescence

Specific immunofluorescent staining was detected only in scattered epithelial and subepithelial cells on small intestinal villi (Fig. 1). The immunofluorescence was usually fine and stippled in appearance (Fig. 1 b). Infected cells were present between 14 and 70 hours p.i. (Table 1). Fewer infected cells were present in jejunum than in midgut or posterior ileum. The greatest number of infected cells was present early in infection, during the incubation period from 14 to 38 hours p.i. The infected enterocytes were generally scattered through the apical half of the villi. Occasional infected cells were observed in the villus lamina propria. No specific reaction was observed when the rotavirus antiserum was used. Tissues other than small intestine showed no specific reaction.

No immunofluorescence was observed with lamb astrovirus-infected intestinal sections and the antisera to either calf or human astrovirus.

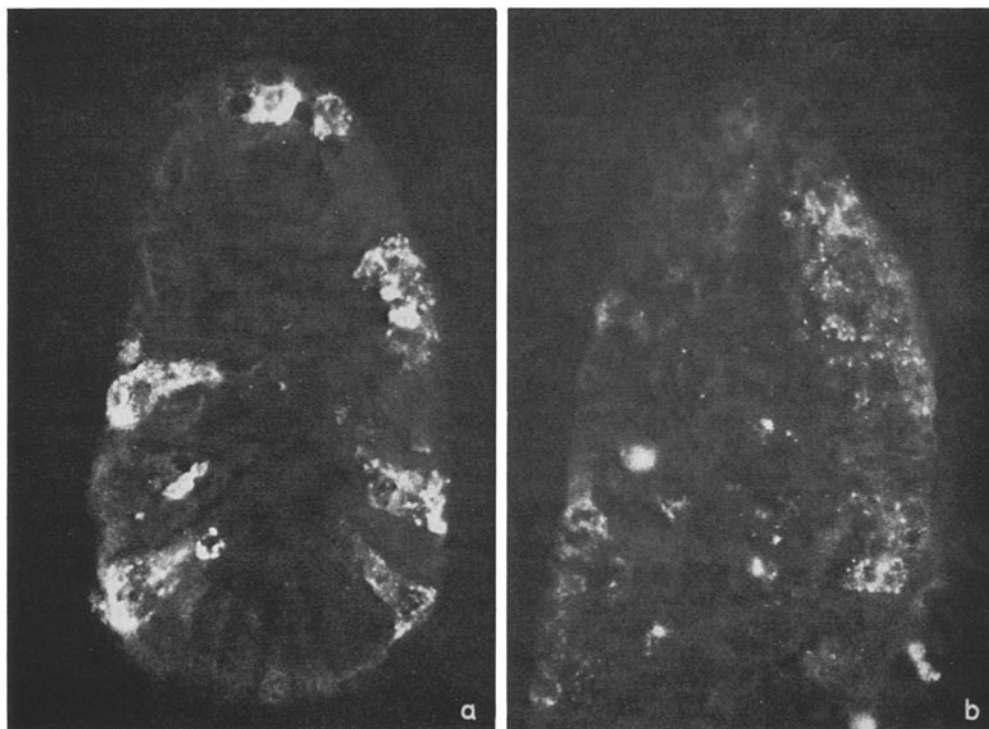


Fig. 1. Astrovirus immunofluorescence in midgut. *a* 23 hours p.i., transverse villus section. *b* 38 hours p.i., longitudinal villus section

Table 1. *Astrovirus immunofluorescence detected in the small intestine*

Time killed (hours p.i.)	Site		
	Jejunum	Midgut	Posterior ileum
14	++	++	++
23	+ ^a	++ ^b	+++ ^c
38	+	+++	++
45	+	+	—
70	+	+	—
120	—	—	—

^a + Very occasional infected epithelial cells (less than 1 per villus section)

^b ++ Infected cells on most villus sections

^c +++ Several infected cells on all villus sections

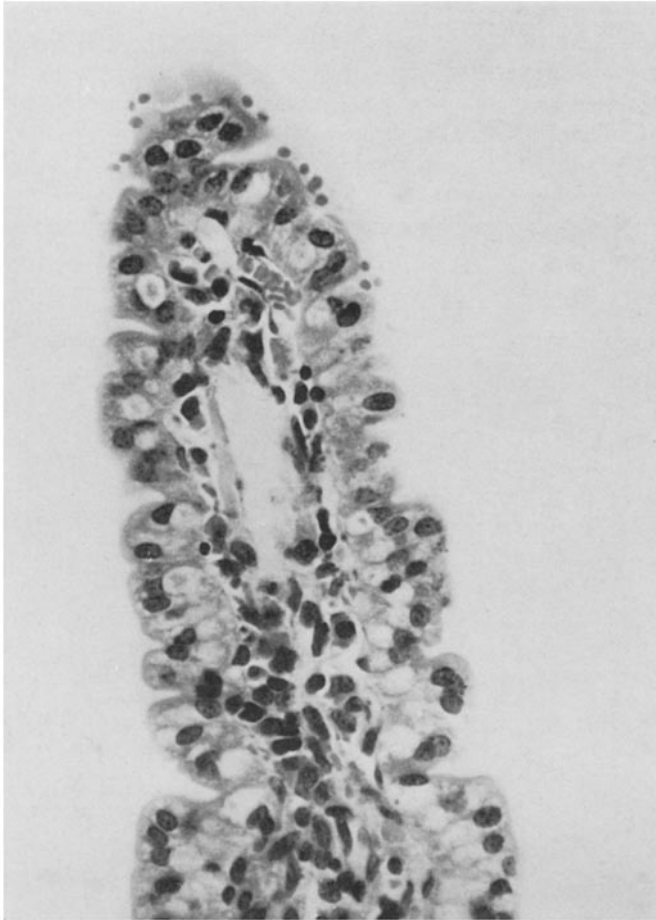

Fig. 2. Villus from midgut, 23 hours p.i. The lateral epithelia contain numerous clefts or microcrypts, and many enterocytes have rounded apical margins. Compare with control (Fig. 3). H & E $\times 950$ (total magnification)

Histology

The proximal intestine was unchanged throughout the experiment. No morphological alterations were seen in the midgut at 14 hours p.i. Many enterocytes in the ileum at 14 hours p.i. contained large ovoid vacuoles apical to the nucleus, although the villi were long and slender. Changes were first observed at 23 hours p.i. in the midgut. Here the villi were long and their lateral margins contained many clefts or microcrypts (Fig. 2), compared with control villi (Fig. 3). The enterocytes lining the lower one-third of the villi appeared normal, but those of the apical two-thirds had rounded margins and were cuboidal rather than columnar.

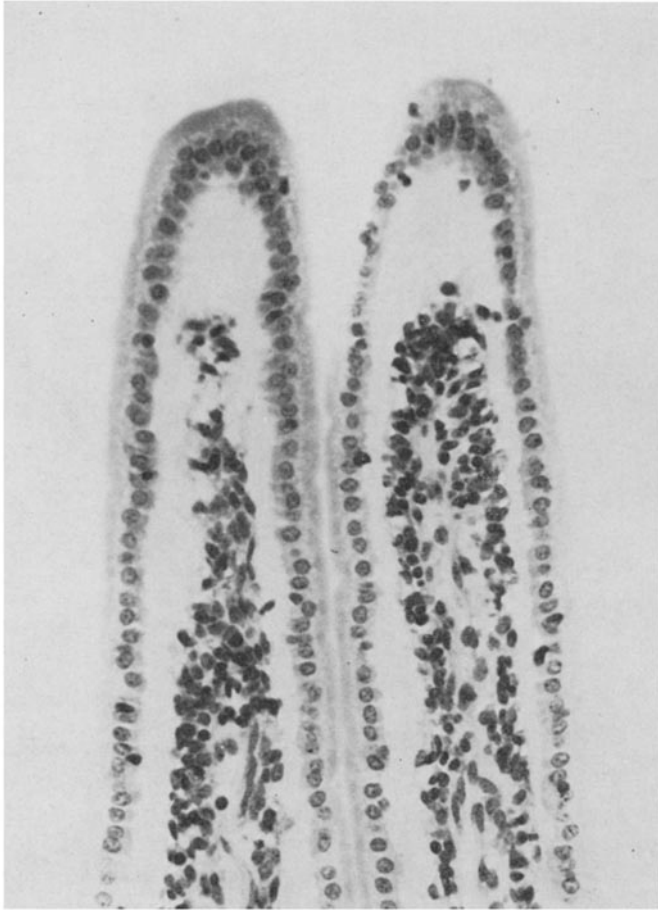

Fig. 3. Villi from midgut, 3 day-old control lamb. H & E $\times 380$

Many enterocytes contained large single basal vacuoles and multiple small apical vacuoles (Fig. 4). The apical vacuoles often impinged upon and indented the nucleus, which consequently appeared collapsed or pyknotic. Both apical and basal vacuoles contained pleomorphic Schiff-negative bodies which stained deep mahogany-red by Pollak's trichrome method. Similar intra-cytoplasmic bodies

were also seen in some enterocytes and subepithelial macrophages, usually close to the nucleus. These bodies were most clearly demonstrated in araldite sections (Fig. 5), and have been shown subsequently (GRAY, E. W., in preparation) to contain arrays of astrovirus particles. The lamina propria of affected villi contained moderate numbers of macrophages with abundant cytoplasm. Goblet cell numbers were comparable to controls. The ileum was unaffected at this stage; single clear apical vacuoles were present in many of the enterocytes.

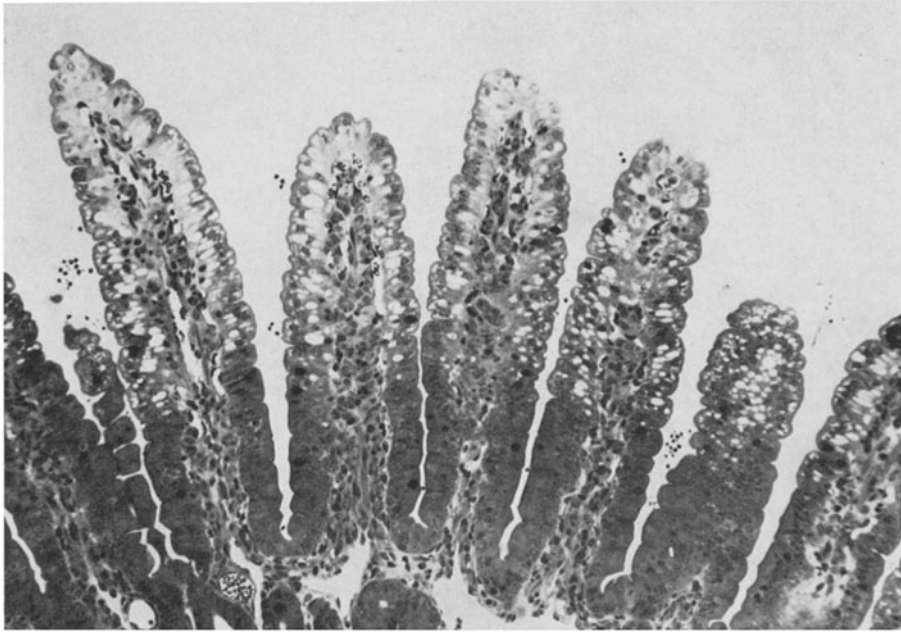


Fig. 4. Araldite section of villi, midgut site, 23 hours p.i. The basal portions of the villi are lined by normal columnar cells, while the apical two-thirds are lined by vacuolated cells with rounded margins. Microcrypts are numerous in distal villous margins. Giemsa $\times 140$

By 38 hours p.i., villi in midgut and ileum were obviously shorter and more spatulate than those in equivalent control sites, or at earlier stages of the infection. At 45 hours p.i., villi in the midgut and ileum were short and blunt with crenated epithelium, and crypts which were elongated contained numerous mitotic figures. The lamina propria contained infiltrates of macrophages, lymphocytes and neutrophils, as well as eosinophils in similar numbers to the control lambs. None of the enterocytes in the midgut contained the multiple apical vacuoles and granular bodies seen at 23 hours p.i. However, single apical vacuoles were seen in the ileum of the infected lambs at 38 and 45 hours p.i. By 70 hours p.i. the villi in the midgut site were long and slender and indistinguishable from normal intestine, but those in the ileum were stunted and lined by a crenated, partly cuboidal epithelium. At 5 days p.i., however, all three intestinal sites were morphologically normal.

Large basal vacuoles were seen in midgut enterocytes of control lambs at 72 and 96 hours of age, but apical vacuoles were confined to the ileum of control lambs. These findings are in accord with those made in normal calves (8, 9) and piglets (2, 11, 12). The vacuolated cells may be absorptive with a marked pinocytotic capacity (11).

A few neutrophils were present in both caecal and colonic mucosa of the lambs killed 23 hours p.i., but not in any other lamb. No changes were found in any of the other tissues at any stage.

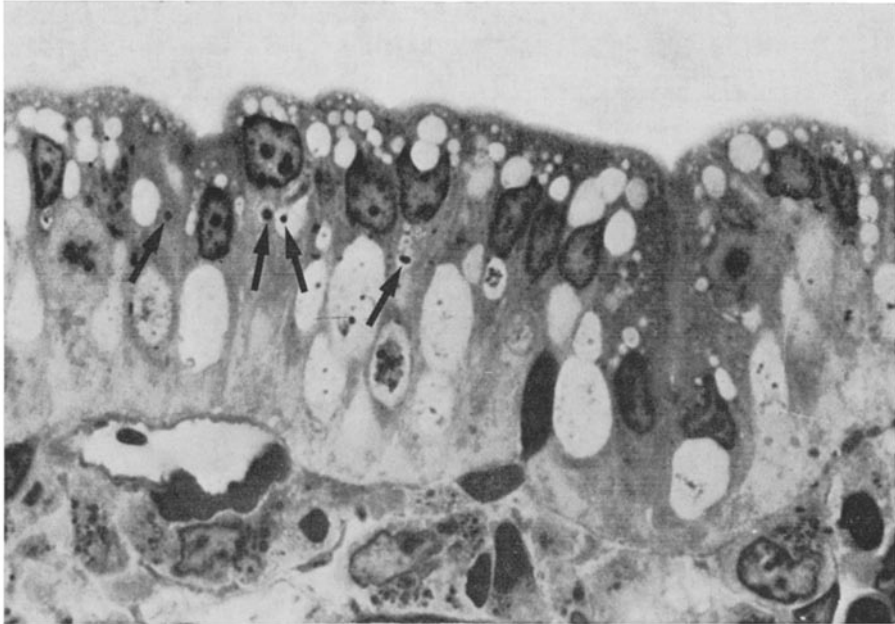


Fig. 5. Higher magnification of part of villus from Figure 4. Brush borders of enterocytes are intact. The apical cytoplasm contains numerous vacuoles which indent the nuclei. Dense bodies (arrows) can be seen in the cytoplasm or in small vacuoles close to the nucleus of some cells. Several of the large basal vacuoles contain coarse granular material. Large macrophages can be seen in the lamina propria. Giemsa. Oil immersion $\times 3800$

Villus and Crypt Measurements

The villus heights and crypt depths at the three sampling sites in the five control lambs did not vary significantly with age. Normal measurements for villi and crypts at each site were therefore obtained by pooling observations for all five lambs. Measurements from individual infected lambs were compared with these normal values (Table 2).

The length of the villi in jejunum did not differ significantly from normal. Villus atrophy was observed at 38 and 45 hours p.i. in midgut, and from 38 to 120 hours p.i. in ileum. The crypts in all three sites showed a progressive elongation throughout the experiments. The most marked changes were observed in ileum, and are illustrated in Figure 6.

Table 2. *Histological measurements of villi and crypts*

Time of sample (hours p.i.)	Villi (μm , mean \pm SE)			Crypts (μm , mean \pm SE)		
	Jejunum	Midgut	Posterior ileum	Jejunum	Midgut	Posterior ileum
Controls	690 \pm 14	613 \pm 17	687 \pm 15	124 \pm 4	115 \pm 3	105 \pm 3
14	702 \pm 23	581 \pm 13	613 \pm 20	159 \pm 6 ^c	139 \pm 4 ^b	122 \pm 5 ^a
23	771 \pm 34 ^a	589 \pm 37	590 \pm 17 ^a	150 \pm 8 ^b	133 \pm 8 ^a	119 \pm 8
38	683 \pm 25	438 \pm 17 ^c	324 \pm 24 ^c	174 \pm 5 ^c	154 \pm 5 ^c	117 \pm 5
45	732 \pm 16	306 \pm 21 ^c	351 \pm 20 ^c	167 \pm 8 ^c	161 \pm 10 ^c	129 \pm 6 ^b
70	684 \pm 20	540 \pm 27	359 \pm 10 ^c	218 \pm 7 ^c	165 \pm 8 ^c	153 \pm 4 ^c
120	713 \pm 24	804 \pm 5 ^c	439 \pm 10 ^c	225 \pm 10 ^c	176 \pm 7 ^c	172 \pm 8 ^c

Significance of deviation from control value

- ^a $p < 0.05$
^b $p < 0.01$
^c $p < 0.001$

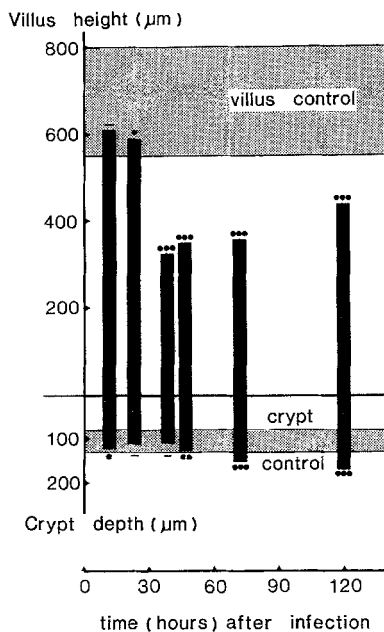


Fig. 6. Villus height and crypt depth in ileum. The crypt and villus controls are represented by a band for mean \pm sd. The significance of the deviations from these control values are shown. — not significant, • $p < 0.05$, •• $p < 0.01$, ••• $p < 0.001$

Enzyme Analyses

Lactase levels in the 6 control lambs were 4.5 ± 0.5 , 5.1 ± 0.6 , and 2.4 ± 1.2 units/g tissue for the proximal, mid, and distal small intestinal sites respectively. In midgut of infected lambs, observations were consistently below those of the controls, falling to a minimum of 1.2 units/g tissue at 23 hours p.i. No consistent change was observed in lactase concentrations in proximal and distal sites.

Discussion

These experiments confirmed the ability of lamb astrovirus to multiply in the intestinal tract of gnotobiotic lambs, and to cause diarrhoea. The site of multiplication was shown by immunofluorescence and electron microscopy (GRAY, E. W., in preparation) to be the small intestine, and these same techniques failed to find evidence of astrovirus infection in any other site. Immunofluorescence showed less evidence of virus multiplication in jejunum than in other levels of small intestine, and this was reflected in the absence of histological change. Crypt hypertrophy was, however, as marked in jejunum as at more distal sites, but the stimulus for this is not known. Lamb rotaviruses have similarly been found to cause least damage in the jejunum (16).

Damage produced by astrovirus infection could be demonstrated by histopathology and estimations of lactase, and was consistently associated with a mild transient diarrhoea. A sequence of events with initial epithelial cell infection and destruction leading to partial villus atrophy, reclothing of the villi with relatively immature cells, and eventual healing of the lesion, can be postulated. This effect is similar to that of other viral infections of villus epithelial cells, particularly rotavirus (16, 18) and coronavirus (3, 10, 13) infections. In the lamb, astrovirus infection is at each stage less severe than rotavirus infection (16, 17), with fewer enterocytes infected, a lesser degree of villus atrophy and a milder clinical disease.

The astroviruses of lambs, calves, and man have not been shown to be serologically related by immunofluorescence. Further serological and biochemical studies are necessary to investigate the relationships between these viruses.

This study has confirmed that lamb astrovirus is a pathogen of the small intestine of lambs. However, the only information available on the epidemiology of any of the astroviruses is that antibody to bovine astrovirus was detected in cattle in 11 or 22 herds (19), so no attempt can be made as yet to define their role in causing diarrhoea under natural conditions.

Acknowledgments

The excellent technical assistance of Messrs J. Redmond and N. Inglis is gratefully acknowledged.

References

1. DAHLQVIST, A.: Method for assay of intestinal disaccharidases. *Anal. Biochem.* **7**, 18—25 (1964).
2. HALL, G. A., BRIDGER, J. C., CHANDLER, R. L., WOODE, G. N.: Gnotobiotic piglets experimentally infected with neonatal calf diarrhoea reovirus-like agent (rotavirus). *Vet. Pathol.* **13**, 197—210 (1976).
3. KEENAN, K. P., JEVIS, H. R., MARCHWICKI, R. H., BINN, L. N.: Intestinal infection of neonatal dogs with canine coronavirus 1—71: studies by virologic, histologic histochemical and immunofluorescent techniques. *Amer. J. vet. Res.* **37**, 247—256 (1976).
4. KURTZ, J. B., LEE, T. W., PICKERING, D.: Astrovirus associated gastroenteritis in a children's ward. *J. clin. Pathol.* **30**, 948—952 (1977).
5. KURTZ, J. B., LEE, T. W., CRAIG, J. W., REED, S. E.: Astrovirus infection in volunteers. *J. med. Virol.* (in press).
6. MADELEY, C. R., COSGROVE, B. P.: 28 nm particles in faeces in infantile gastroenteritis. *Lancet* **ii**, 451—452 (1975).

7. MADELEY, C. R., COSGROVE, B. P., BELL, E. J., FALLON, R. J.: Stool viruses in babies in Glasgow. *J. Hyg. (Camb.)* **78**, 261—273 (1977).
8. MEBUS, C. A., STAIR, E. L., UNDERDAHL, N. R., TWIEHHAUS, M. J.: Pathology of neonatal calf diarrhoea induced by a reolike virus. *Vet. Pathol.* **8**, 490—505 (1971).
9. MEBUS, C. A., NEWMAN, L. E., STAIR, E. L.: Scanning electron, light and transmission electron microscopy of intestine of gnotobiotic calf. *Amer. J. vet. Res.* **36**, 985—993 (1975).
10. MEBUS, C. A., NEWMAN, L. E., STAIR, E. L.: Scanning electron, light and immunofluorescent microscopy of intestine of gnotobiotic calf infected with calf diarrheal coronavirus. *Amer. J. vet. Res.* **36**, 1719—1725 (1975).
11. MOON, H. W.: Vacuolated villous epithelium of the small intestine of young pigs. *Vet. Pathol.* **9**, 3—21 (1972).
12. PEARSON, G. R., McNULTY, M. S.: Pathological changes in the small intestine of neonatal pigs infected with a pig reovirus-like agent (rotavirus). *J. comp. Pathol.* **87**, 363—375 (1977).
13. PENSART, M., HAELTEMAN, E. O., BURNSTEIN, T.: Transmissible gastroenteritis of swine: Virus-intestinal cell interactions. *Arch. ges. Virusforsch.* **31**, 321—334 (1970).
14. SCHNAGL, R. D., HOLMES, I. H., MACKAY-SCOLLAY, E. M.: A survey of rotavirus associated with gastroenteritis in Aboriginal children in Western Australia. *Med. J. Aust.* **i**, 304—307 (1978).
15. SNODGRASS, D. R., GRAY, E. W.: Detection and transmission of 30 nm virus particles (astroviruses) in faeces of lambs with diarrhoea. *Arch. Virol.* **55**, 287—291 (1977).
16. SNODGRASS, D. R., ANGUS, K. W., GRAY, E. W.: Rotavirus infection in lambs: pathogenesis and pathology. *Arch. Virol.* **55**, 263—274 (1977).
17. SNODGRASS, D. R., HERRING, J. A., GRAY, E. W.: Experimental rotavirus infection in lambs. *J. comp. Pathol.* **86**, 637—642 (1976).
18. THEIL, K. W., BOHL, E. H., CROSS, R. F., KOHLER, E. M., AGNES, A. G.: Pathogenesis of porcine rotaviral infection in experimentally inoculated gnotobiotic pigs. *Amer. J. vet. Res.* **39**, 213—220 (1978).
19. WOODE, G. N., BRIDGER, J. C.: Isolation of small viruses, astrovirus-like and calicivirus-like, from acute enteritis of calves. *J. med. Microbiol.* **11**, 441—452 (1978).

Authors' address: Dr. D. R. SNODGRASS, Animal Diseases Research Association, Moredun Institute, 408 Gilmerton Road, Edinburgh, Scotland.

Received December 14, 1978