



Contents lists available at ScienceDirect

JPRAS Open

journal homepage: <http://www.journals.elsevier.com/jpras-open>

## Original Article

# Microbiological and functional outcomes after open extremity fractures sustained overseas: The experience of a UK level I trauma centre

B. Ardehali<sup>a</sup>, L. Geoghegan<sup>a,\*</sup>, A. Khajuria<sup>a</sup>, D. Reissis<sup>a</sup>,  
G. Lawton<sup>a</sup>, A. Jain<sup>a</sup>, J. Simmons<sup>a</sup>, S. Naique<sup>b</sup>, R. Bhattacharya<sup>b</sup>,  
M. Pearse<sup>b</sup>, D. Nathwani<sup>b</sup>, S. Hettiaratchy<sup>a</sup>

<sup>a</sup> Department of Plastic & Reconstructive Surgery, Imperial College Healthcare NHS Trust, Praed Street, W2 1NY, London, United Kingdom

<sup>b</sup> Department of Orthopaedic Surgery, Imperial College Healthcare NHS Trust, Praed Street, W2 1NY, London, United Kingdom

## ARTICLE INFO

*Article history:*

Received 21 August 2017

Accepted 22 September 2017

Available online 21 November 2017

*Keywords:*

Trauma

Limb reconstruction

Limb salvage

Microbiology

Infection

Osteomyelitis

## ABSTRACT

**Background:** Open extremity fractures carry a high risk of limb loss and poor functional outcomes. Transfer of extremity trauma patients from developing countries and areas of conflict adds further layers of complexity due to challenges in the delivery of adequate care. The combination of extensive injuries, transfer delays and complex microbiology presents unique challenges.

**Methods:** A retrospective review was conducted to analyse the surgical and microbiological themes of patients with open extremity fractures transferred from overseas to our institution (Imperial College NHS Trust) between January 2011 and January 2016.

**Results:** Twenty civilian patients with 21 open extremity fractures were referred to our unit from 11 different countries. All patients had poly-microbial wound contamination on initial surveillance cultures. Five patients (25%) underwent amputation depending on the extent of osseous injury; positive surveillance cultures did not preclude limb reconstruction, with seven patients undergoing complex reconstruction and eight undergoing simple reconstruction to achieve wound coverage. Hundred percent of patients demonstrated infection-free fracture union on discharge.

\* Corresponding author. Department of Plastic & Reconstructive Surgery, St. Mary's Hospital, Imperial College Healthcare NHS Trust, Praed Street, W2 1NY, London, United Kingdom.  
E-mail address: [lg1813@ic.ac.uk](mailto:lg1813@ic.ac.uk) (L. Geoghegan).

<https://doi.org/10.1016/j.jpra.2017.09.003>

2352-5878/© 2017 The Author(s). Published by Elsevier Ltd on behalf of British Association of Plastic, Reconstructive and Aesthetic Surgeons. This is an open access article under the CC BY-NC-ND license (<http://creativecommons.org/licenses/by-nc-nd/4.0/>).

*Conclusion:* Patients with open extremity fractures transferred from overseas present the unique challenge of poly-microbial infection in addition to extensive traumatic wounds. Favourable outcomes can be achieved despite positive microbiological findings on tissue culture with adequate antimicrobial therapy. The decision to salvage the limb and the complexity of reconstruction used should be based on the chance of achieving meaningful functional recovery, mainly determined by the extent of bony injury. The complexity of reconstruction was based on the predicted long-term functionality of the salvaged limb.

© 2017 The Author(s). Published by Elsevier Ltd on behalf of British Association of Plastic, Reconstructive and Aesthetic Surgeons. This is an open access article under the CC BY-NC-ND license (<http://creativecommons.org/licenses/by-nc-nd/4.0/>).

## Introduction

Trauma to the extremities represents one of the most common injury patterns encountered by both civilian and military orthoplastic teams.<sup>1</sup> In both instances, a multidisciplinary team (MDT) approach is warranted to achieve optimal outcomes for patients in the form of a stable, painless limb capable of supporting the functional aspirations of patients. Collectively, open extremity fractures signify high-energy transfer, which carry a significant risk of limb loss or dysfunction. However, the differences in the incidence, nature and severity of extremity trauma between military and civilian settings must be considered.

In the military setting, the advent of improvised explosive devices has altered the pattern of injuries seen in both mounted and dismounted personnel. The complexity of resultant extremity injuries and the need to optimise functionality has seen an increasing role for plastic surgeons in military trauma teams, with plastic surgeons involved in 40% of all surgical cases in the Afghanistan conflict.<sup>2</sup> Injuries to the upper and lower extremity form a significant part of the military plastic surgeon's caseload, accounting for 64% and 40% of all cases, respectively.<sup>1–3</sup> The vast majority of long bone fractures sustained in the military setting are open (82%),<sup>3</sup> with high velocity and penetrating mechanisms producing an outside to inside pattern of extremity trauma, implicating multiple functional components.

In the civilian setting, significant extremity injury has been reported in 58.6% of patients admitted following major trauma.<sup>4</sup> Civilian extremity trauma is often blunt in nature, most commonly occurring because of falls, industry-related accidents and road traffic collisions. Regional epidemiological studies demonstrate the incidence of open fractures to be 11.5 per 100,000 individuals, with an estimated 3.3% of all upper limb and 3.7% of all lower limb fractures open at the time of presentation.<sup>5</sup> Anatomical variation exists, with reports of up to 21% of tibial fractures presenting as open, largely due to the paucity of soft tissue covering the anteromedial border of the tibia.<sup>6</sup>

In both military and civilian domains, direct communication between fracture and external environment carries high morbidity, with increased incidence of fracture non-union, soft tissue infection and osteomyelitis in open fractures compared to closed counterparts.<sup>7–10</sup> The correlation between infection risk and degree of soft tissue injury is well documented, with reports demonstrating 27–77% of type III open tibia fractures ending up with deep wound infection.<sup>11,12</sup> The debilitating sequelae of open fractures carries significant physical, psychological and social burden for those concerned. Early transfer to Level 1 Trauma Centres followed by prompt debridement and reconstruction by orthoplastic specialists can improve the overall functional outcome.<sup>13</sup>

The extent of primary wound contamination is dependent on the mechanism of injury and the environment in which the injury was sustained.<sup>14</sup> However, primary colonisation rates for such injuries are high regardless of aetiology, with reported rates reaching 70–80%.<sup>15–17</sup> The degree of primary contamination is associated with delayed presentation to appropriate healthcare facilities. Scarred and oedematous soft tissues present significant challenges to reconstructive trauma surgeons following

delayed presentation of injuries, principally through difficulties in the delineation of anatomical tissue planes.<sup>18</sup>

Overseas evacuation of extremity trauma from areas of conflict adds another layer of complexity. Inadequate soft tissue and/or bony stabilisation is commonplace because of lack of resources and expertise in the management of extremity trauma, producing a clinical picture akin to combat-related extremity injuries with heavy contamination, often with multidrug-resistant organisms.<sup>19</sup> The combination of challenging injuries, delayed presentation to appropriate services and complex microbiology necessitate a distinct management approach, separate from what is currently implemented following acute presentation of civilian trauma to specialist centres with established orthoplastic services. The purpose of this study was to analyse patients with open extremity injuries transferred from overseas to our institution (Imperial College Healthcare NHS Trust) following both civilian and combat-related injuries over a 5-year period from January 2011 and January 2016 and determine the surgical and microbiological themes.

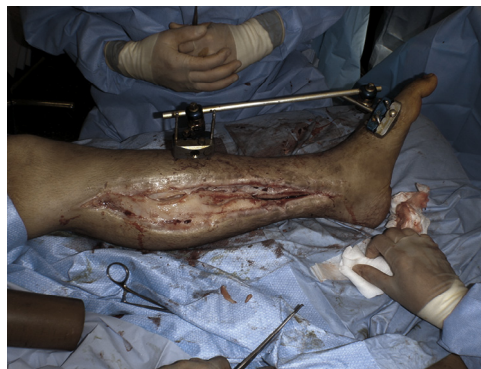## Methods

Patients treated within the Department of Plastic & Reconstructive Surgery at Imperial College Healthcare NHS trust following an injury sustained overseas between January 2011 and November 2015 were identified through a departmental database, designed and maintained by one of the co-investigators (JS). Medical health records and operative notes were retrospectively reviewed for demographics, country of referral, mechanism of injury, presenting microbiology, and soft tissue and bony management alongside frequency and duration of antimicrobial therapy. This study was approved by the local audit department.

Patients, both adult and paediatric, who sustained open extremity fractures secondary to traumatic injury outside the United Kingdom were eligible for study inclusion. All patients had initial surgical treatment in the country of injury, with variation in bone and soft tissue management. Patients were subsequently transferred to our department at a variable time point following initial injury. (Figures 1–4)

### *Treatment algorithm*

The decision to pursue limb salvage versus amputation was made after thorough multidisciplinary assessment and discussion. Two critical decisions guided management in our cohort. The extent of osseous injury was used to determine whether salvage efforts should be pursued in the first instance. If there was an unreconstructable bone defect, particularly with bone loss at the joint surface, then amputation would be advised. Where salvage was clinically appropriate, the anticipated level of functionality was used to inform the reconstructive modality. If a poor functional outcome was likely,



**Figure 1.** Clinical photograph demonstrating deep wound infection of a Gustilo-Anderson grade III tibial fracture following delayed presentation from overseas.

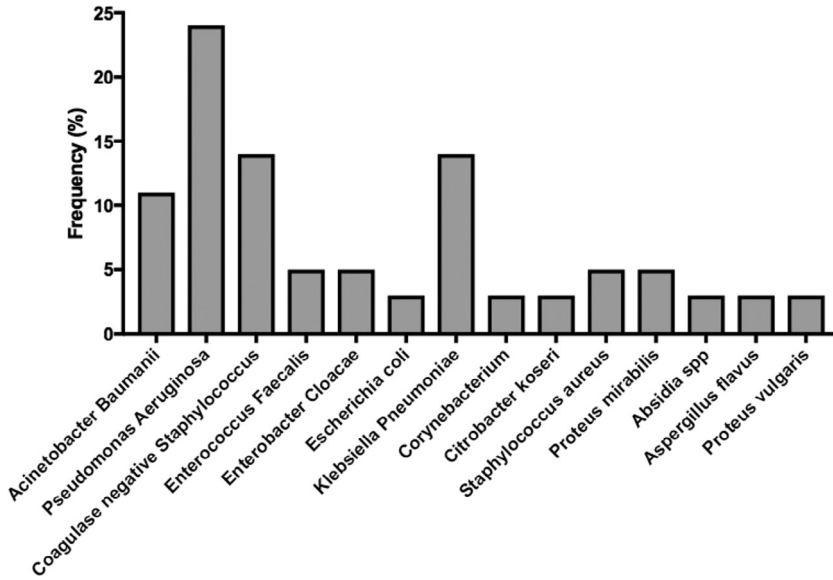


Figure 2. Overall microbial profile.

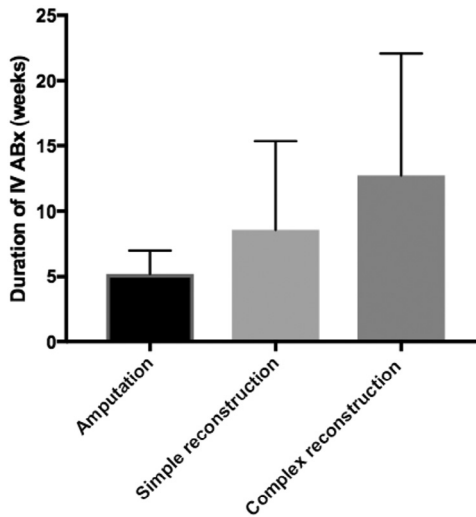
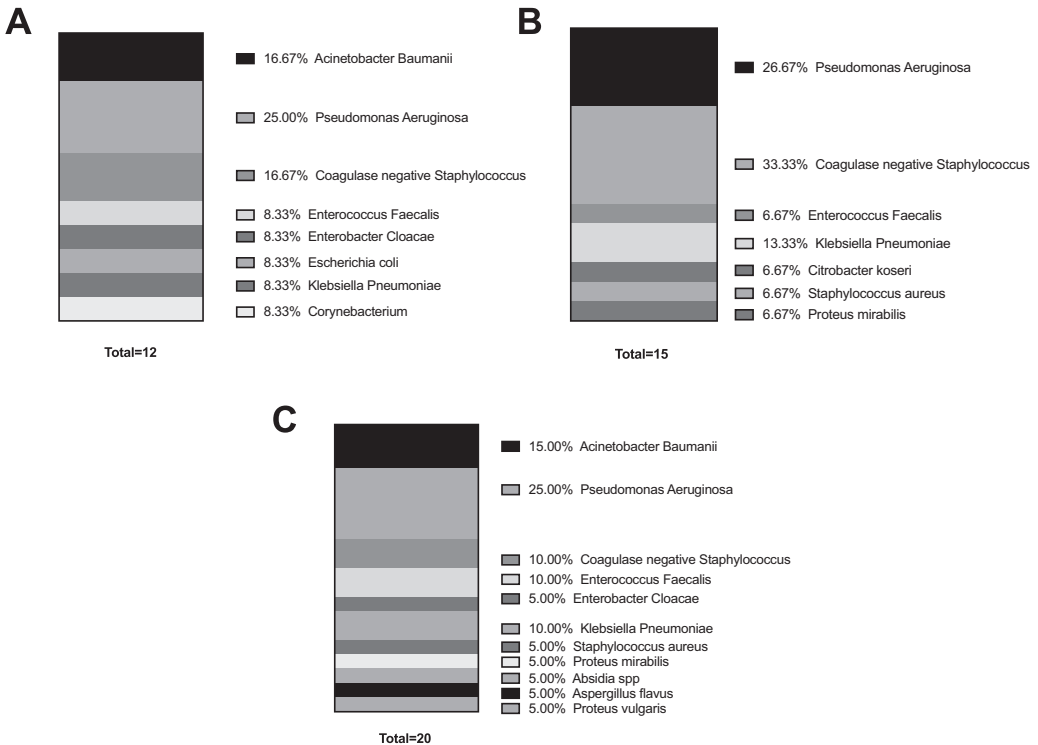


Figure 3. Duration of antimicrobial treatment stratified by treatment group.

simple techniques were used to achieve osseous union and wound coverage, such as external fixation, negative pressure therapy and split skin grafting, to mitigate the risk of iatrogenic complications related to further reconstructive procedures. If a good functional outcome was possible, then complex reconstruction, such as free tissue transfer, internal fixation and extensive antimicrobial therapy, was utilised. Surveillance cultures were obtained at the time of initial debridement according to the surgeon preference within 72 h of presentation to our unit. It must be reiterated that presence of infection



**Figure 4.** Microbial profiles on initial sampling of patients who underwent A) Amputation, B) Complex reconstruction and C) Simple reconstruction.

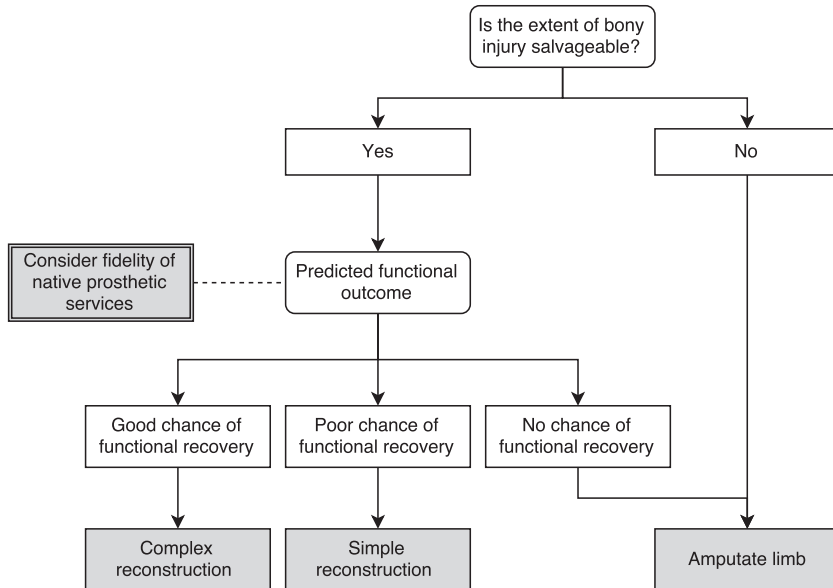
did not influence the decision-making process for this patient cohort. The decision process map in [Figure 5](#) illustrates the treatment algorithm.

## Results

Twenty patients were referred to our unit: 17 adults and three children, 15 males and five females. The average age was 34 years (range 6–65). Patients were transferred from 11 different countries: Bolivia, Libya, Nigeria, Turkey, Laos, Argentina, Thailand, Egypt, Greece, Senegal and Mauritius. Demographic and management modalities for all patients are outlined in [Table 1](#).

Ten patients had sustained shrapnel and gunshot wound injuries. Eight patients were involved in road traffic accidents, one patient had a fall from height and one patient sustained a propeller injury in a speedboat accident.

Thirteen patients sustained lower limb injuries, six patients sustained upper limb injuries and one patient sustained both upper and lower limb injuries, both requiring surgical intervention. Open fractures of the lower extremity were the most common presenting injury within our cohort, with 12 patients presenting with a Gustillo IIIB injury and one with a Gustillo IIIC injury. The varying mechanisms of injury and the extent of surgical input within a patient's native country produced a heterogeneous cohort. The extent of the presenting injury demonstrated paralleled heterogeneity, with 10 (50%) patients sustaining peripheral nerve injury. Patients were followed up for an average of 16.9 months after surgical intervention (range 2–33) to establish definitive reconstructive outcomes.



**Figure 5.** Treatment algorithm, for heavily contaminated wounds transferred from overseas in our cohort, used to guide the decision for salvage or amputation in the first instance and reconstructive modality in the second instance.

### Reconstructive outcomes

Eight patients had simple reconstruction, seven had complex reconstruction and five underwent amputation. The decision to perform simple reconstruction was taken when the chance of functional recovery was poor. This group tended to have a more delayed presentation (average 43.4 days). This sub-group generally required serial debridement and subsequent split skin graft to cover wounds. It is of note that one patient (patient 18) presented with a previously performed complex reconstruction with a latissimus dorsi flap following initial injury. Failure of this free flap necessitated presentation to our unit.

Complex reconstruction was performed if there was a good chance of functional recovery, which would justify the use of more extensive surgical techniques. This group tended to include patients with early injuries, averaging 20 days from the time of initial injury to presentation at our unit. Five patients required anterolateral thigh fasciocutaneous flap free tissue transfer, and the remaining two patients required latissimus dorsi myocutaneous and radial forearm flaps to achieve definitive wound closure.

The decision to amputate was taken because of the subjective MDT opinion of future poor functional prognosis conferred by the extent and severity of both soft tissue and bony injury. Prognostic limb scoring systems were not used to inform clinical management within our cohort. None were amputated because of uncontrolled infection. All amputations were performed after extensive discussion with the patients and preoperative planning with prosthetic services.

In the simple reconstruction group, five patients had healed and three patients had an infected non-union, which subsequently healed after prolonged antimicrobial treatment. Of the six patients in the complex reconstruction group, one patient had an infective relapse, which eventually healed with prolonged focused antibiotic therapy. All patients had infection-free fracture union on discharge. Patients in the amputation cohort demonstrated good functional outcomes at final follow-up.

**Table 1**  
Demographic and surgical management for all patients referred from overseas.

Patient	Age/sex	Referring country	Mechanism of injury	Anatomical defect	AO soft tissue classification grade	Orthopaedic management	Reconstructive management	Complications
<b>1</b>	22 F	Bolivia	RTA	IIIB	IO4	BKA	Amputation	-
<b>2</b>	30 M	Libya	GSW	IIIB	IO4	BKA	Amputation	-
<b>3</b>	59 F	Nigeria	RTA	Open humeral fracture	IO4	AEA	Amputation	-
<b>4</b>	53 M	Nigeria	RTA	IIIB	IO4	BKA	Amputation	-
<b>5</b>	23 M	Turkey	RTA	IIIB	IO4	BKA	Amputation	-
<b>6</b>	25 M	Laos	RTA	IIIB	IO3	ORIF	CR(ALT)	-
<b>7</b>	13 F	Mauritius	Propeller (motor boat)	IIIB	IO4	External fixation	CR (LD)	-
<b>8</b>	38 M	Argentina	Fall	Open humeral fracture	IO4	ORIF	CR (ALT)	-
<b>9</b>	65 M	Thailand	RTA	IIIB	IO3	External fixation (?)	CR (RFF)	-
<b>10</b>	6 F	Nigeria	GSW	IIIB	IO3	External fixation	CR (ALT)	-
<b>11</b>	22 M	Egypt	Blast wound	IIIB	IO4	External fixation (TSF)	CR (ALT)	Infectious non-union
<b>12</b>	53 F	Greece	RTA	Open radial fracture	IO4	External fixation, ORIF/IC bone graft	CR (ALT)	-
<b>13</b>	42 M	Senegal	RTA	Degloving injury	IO3	ORIF	SR	Infectious non-union
<b>14</b>	39 M	Libya	GSW	IIIB	IO4	External fixation	SR	Infectious non-union
<b>15</b>	32 M	Libya	GSW	IIIB	IO4	External fixation	SR	-
<b>16</b>	37 M	Libya	GSW	Open humeral fracture	IO3	External fixation (TSF)	SR	-
<b>17</b>	37 M	Libya	GSW	Open humeral fracture	IO3	External fixation	SR	-
<b>18</b>	33 M	Egypt	Blast wound	IIIB + Open phalangeal fracture	IO4	External fixation	SR	-
<b>19</b>	38 M	Egypt	GSW	IIIC	IO4	External fixation	SR	Infectious non-union
<b>20</b>	25 M	Egypt	GSW	Open humeral fracture	IO4	External fixation	SR	-

RTA = road traffic accident; GSW = gunshot wound; IIIB = Gustilo-Anderson grade IIIB fracture; IIIC = Gustilo-Anderson grade IIIC fracture; IO3 = AO soft tissue classification open skin lesion grade 3; IO4 = AO soft tissue classification open skin lesion grade 4; BKA = below knee amputation; AEA = above elbow amputation; ORIF = open reduction internal fixation; IC = iliac crest; CR = Complex reconstruction; SR = Simple reconstruction; ALT = Anterolateral thigh fasciocutaneous free flap; LD = latissimus dorsi myocutaneous free flap; RFF = radial forearm free flap.

## Microbiological outcomes

All wounds demonstrated poly-microbial contamination on initial sampling. The majority of the organisms cultured were gram negative; *Pseudomonas aeruginosa* was the most commonly cultured microorganism across all three treatment groups. High-energy penetrating injuries caused by blast and gunshot wounds demonstrated predominance of *Pseudomonas* sp. and *Acinetobacter baumannii*, both intrinsic multidrug resistant pathogens.<sup>20</sup> Low-energy injuries predominantly caused by road traffic collisions and falls demonstrated predominance of coagulase-negative *Staphylococcus* on microbial culture. The average duration of antibiotic treatment was 6 weeks, ranging from 2 to 24 weeks, with complex reconstruction cases requiring a more complex antimicrobial regime.

## Discussion

Clinical management of the traumatic extremity is multifaceted, and the decision to amputate or attempt limb salvage must be considered in view of the repeat hospitalisation, extensive complications and poor functional outcome that may ensue. Discordance between the decision to amputate or attempt salvage is long standing; however, delayed amputation is associated with poor functional outcomes, more surgical procedures and increased health-related costs.<sup>21,22</sup> Huh et al. (2011) reported significantly higher incidence of deep wound infection, osteomyelitis and free flap failure in those undergoing late amputation in their cohort of lower extremity trauma sustained following combat-inflicted injury, concluding infectious complications and soft tissue injury as precursors to late amputation.<sup>23</sup>

Further work conducted by Burns et al (2012) correlated the extent of soft tissue injury with the degree of contamination, time to wound closure, definitive stabilisation and subsequent complications. Notably, a higher amputation rate was observed in patients with positive initial surveillance cultures. However, a predominance of *A. baumannii* was demonstrated in surveillance and infection cultures taken from type III fractures sustained following combat-related lower extremity injury.<sup>11</sup> As acknowledged by the authors, nosocomial transmission following prolonged hospital stay and multiple revision procedures coupled with the predominant nature of penetrating injuries may have affected the emergence of virulent microbial strains.

Our results demonstrate that reasonable outcomes can be achieved in extensive lower limb traumatic injuries sustained following both military- and civilian-type trauma despite extensive deep wound contamination. This experience led to the development of a decision process map, which outlines the management rationale used within our cohort. In the first instance, the decision to amputate or attempt limb salvage was based on the extent of bony damage, considering the wider psychosocial, social and resource implications of individual patients. Given the unique nature of patients in our cohort, the anticipated robustness of prosthetic services in the patients' country of origin was utilised to temper expectations regarding acceptable functional outcomes. In such instances where native prosthetic services were presumed to be comparatively sub-optimal to the services provided in established healthcare systems and the extent of bony injury permitted a degree of functionality, limb salvage was pursued with the choice of reconstructive modality further guided by the anticipated functional outcomes. The presence of positive microbial cultures was not used as an indication for amputation in the first instance. Much of the current evidence base for the treatment of open extremity fractures stems from observations exclusively made in the civilian or military domain; the cohort described presents a challenge of poly-microbial infection and injury mechanisms seldom encountered by the civilian trauma team.

Further aspects of care must be considered in the management of such patients. Evacuation of injured overseas patients from geographically challenging and often hostile environments is a source of concern for both patients and the acute transfer team, with the importance of risk minimisation to both casualty and evaluation team previously emphasised.<sup>24</sup> The overseas patients transferred from conflict zones find themselves in a foreign environment, understandably traumatised, anxious and often with limb-threatening injuries that require urgent specialised treatment. Their concerns must equally be addressed as often they have unrealistic expectations, given the gravity of their injuries and the



limitations in possible functional recovery, with cultural and language barriers adding additional barriers to communication.<sup>25</sup>

The receiving team faces complex and challenging open wounds with on-going contamination that often require revision. Delay in treatment can complicate salvage efforts through contamination of hardware and infection of autologous tissues.<sup>23,26</sup> Our results have demonstrated that adequate antimicrobial treatment coupled with stratification of reconstructive technique based on likely functional recovery leads to optimal outcomes on a patient-specific basis. It must be reiterated that the decision to amputate the five cases in our series was taken because of the extent and severity of bony and soft tissue injury and associated poor chance of good functional recovery. Equally, amputation must not be considered a failed procedure, with injuries considered on an individual basis with treatment options tempered against likely subsequent functional outcomes.<sup>27</sup>

Our results must be considered in view of the study limitations. Notably, the cohort presented is small, with marked heterogeneity in the type of injury sustained, and there is a distinct lack of long-term follow-up data. Such limitations are inherent, given the unique nature of our patient cohort and the challenges associated with gathering adequate follow-up data after discharge of patients back to services in their country of origin.

Our experience of management of open extremity fracture patients transferred from overseas has been positive. This patient group presents the unique challenge of poly-microbial infection in addition to extensive traumatic wounds, akin to military-grade extremity trauma in certain cases. Favourable outcomes can be achieved despite positive microbiological findings on tissue culture, with adequate antimicrobial therapy in a civilian setting. The decision to salvage the limb should be based on the likely long-term functional outcome. The most important factor in this is the extent of bony injury. If limb salvage is advocated, the choice of either complex or simple reconstruction should be guided by anticipated functional recovery.

### Conflict of interest

None.

### Funding

None.

### References

- Owens BD, Kragh JF Jr, Wenke JC, et al. Combat wounds in operation Iraqi Freedom and operation Enduring Freedom. *J Trauma*. 2008;64:295–299.
- Maitland L, Lawton G, Baden J, et al. The role of military plastic surgeons in the management of modern combat trauma: an analysis of 645 cases. *Plast Reconstr Surg*. 2016;137:717e–724e.
- Belmont PJ, Schoenfeld AJ, Goodman G. Epidemiology of combat wounds in Operation Iraqi Freedom and Operation Enduring Freedom: orthopaedic burden of disease. *J Surg Orthop Adv*. 2010;19:2–7.
- Banerjee M, Bouillon B, Shafizadeh S, et al. Epidemiology of extremity injuries in multiple trauma patients. *Injury*. 2013;44:1015–1021.
- Court-Brown CM, Bugler KE, Clement ND, Duckworth AD, McQueen MM. The epidemiology of open fractures in adults. A 15-year review. *Injury*. 2012;43:891–897.
- Jordan DJ, Malahias M, Khan W, Hindocha S. The ortho-plastic approach to soft tissue management in trauma. *Open Orthop J*. 2014;8:399–408.
- Antonova E, Le TK, Burge R, Mershon J. Tibia shaft fractures: costly burden of nonunions. *BMC Musculoskelet Disord*. 2013;14:42.
- Gross T, Kaim AH, Regazzoni P, Widmer AF. Current concepts in posttraumatic osteomyelitis: a diagnostic challenge with new imaging options. *J Trauma*. 2002;52:1210–1219.
- Tsukayama DT. Pathophysiology of posttraumatic osteomyelitis. *Clin Orthop Relat Res*. 1999;22–9.
- Neubauer T, Bayer GS, Wagner M. Open fractures and infection. *Acta Chir Orthop Traumatol Cech*. 2006;73:301–312.
- Burns TC, Stinner DJ, Mack AW, et al. Microbiology and injury characteristics in severe open tibia fractures from combat. *J Trauma Acute Care Surg*. 2012;72:1062–1067.
- Johnson EN, Burns TC, Hayda RA, Hospenthal DR, Murray CK. Infectious complications of open type III tibial fractures among combat casualties. *Clin Infect Dis*. 2007;45:409–415.
- Wordsworth M, Lawton G, Nathwani D, et al. Improving the care of patients with severe open fractures of the tibia: the effect of the introduction of major trauma networks and national guidelines. *Bone Joint J*. 2016;98-b:420–424.

14. Ficke JR, Pollak AN. Extremity war injuries: development of clinical treatment principles. *J Am Acad Orthop Surg.* 2007;15:590–595.
15. Zalavras CG, Marcus RE, Levin LS, Patzakis MJ. Management of open fractures and subsequent complications. *Instr Course Lect.* 2008;57:51–63.
16. Russell GG, Henderson R, Arnett G. Primary or delayed closure for open tibial fractures. *J Bone Joint Surg Br.* 1990;72:125–128.
17. Kindsfater K, Jonassen EA. Osteomyelitis in grade II and III open tibia fractures with late debridement. *J Orthop Trauma.* 1995;9:121–127.
18. Bhandari PS, Maurya S, Mukherjee MK. Reconstructive challenges in war wounds. *Indian J Plast Surg.* 2012;332–339.
19. Yun HC, Murray CK, Nelson KJ, Bosse MJ. Infection after orthopaedic trauma: prevention and treatment. *J Orthop Trauma.* 2016;30.
20. Zavascki AP, Carvalhaes CG, Picao RC, Gales AC. Multidrug-resistant *Pseudomonas aeruginosa* and *Acinetobacter baumannii*: resistance mechanisms and implications for therapy. *Expert Rev Anti Infect Ther.* 2010;8:71–93.
21. Harris AM, Althausen PL, Kellam J, et al. Complications following limb-threatening lower extremity trauma. *J Orthop Trauma.* 2009;23:1–6.
22. Bondurant FJ, Cotler HB, Buckle R, Miller-Crotchett P, Browner BD. The medical and economic impact of severely injured lower extremities. *J Trauma.* 1988;28:1270–1273.
23. Huh J, Stinner DJ, Burns TC, Hsu JR. Late Amputation Study T. Infectious complications and soft tissue injury contribute to late amputation after severe lower extremity trauma. *J Trauma.* 2011;71:S47–S51.
24. Patel D, Easmon CJ, Dow C, Snashall DC, Seed PT. Medical repatriation of British diplomats resident overseas. *J Travel Med.* 2000;7:64–69.
25. Jefferies NJ, Ramage C, Bristow A. International repatriation following overseas disasters. *Arch Emerg Med.* 1991;8:92–96.
26. Trampuz A, Zimmerli W. Diagnosis and treatment of infections associated with fracture-fixation devices. *Injury.* 2006;37(suppl 2):S59–S66.
27. Bosse MJ, MacKenzie EJ, Kellam JF, et al. An analysis of outcomes of reconstruction or amputation after leg-threatening injuries. *N Engl J Med.* 2002;347:1924–1931.