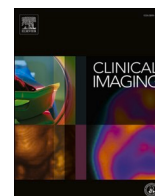




Since January 2020 Elsevier has created a COVID-19 resource centre with free information in English and Mandarin on the novel coronavirus COVID-19. The COVID-19 resource centre is hosted on Elsevier Connect, the company's public news and information website.

Elsevier hereby grants permission to make all its COVID-19-related research that is available on the COVID-19 resource centre - including this research content - immediately available in PubMed Central and other publicly funded repositories, such as the WHO COVID database with rights for unrestricted research re-use and analyses in any form or by any means with acknowledgement of the original source. These permissions are granted for free by Elsevier for as long as the COVID-19 resource centre remains active.



## Cardiothoracic Imaging

# Aorto-iliac/right leg arterial thrombosis necessitating limb amputation, pulmonary arterial, intracardiac, and ilio-caval venous thrombosis in a 40-year-old with COVID-19

Mohammad H. Madani<sup>\*</sup>, Ann N.C. Leung, Hans-Christoph Becker, Frandics P. Chan, Dominik Fleischmann

Stanford University School of Medicine, Department of Radiology, 300 Pasteur Drive, S078, Stanford, CA 94305, United States of America



## ARTICLE INFO

## Keywords:

COVID-19  
Aorto-iliac thrombosis  
Lower extremity arterial thrombosis  
Acute limb ischemia  
Intracardiac thrombus  
Pulmonary arterial thromboembolism  
Ilio-caval venous thrombosis

## ABSTRACT

We describe a 40-year-old man with severe COVID-19 requiring mechanical ventilation who developed aorto-bi-iliac arterial, right lower extremity arterial, intracardiac, pulmonary arterial and ilio-caval venous thromboses and required right lower extremity amputation for acute limb ischemia. This unique case illustrates COVID-19-associated thrombotic complications occurring at multiple, different sites in the cardiovascular system of a single infected patient.

## 1. Introduction

Coronavirus disease 2019 (COVID)-19 is a global pandemic which has affected millions of people throughout the world. Severe Acute Respiratory Syndrome Coronavirus 2 (SARS-CoV-2) is the virus that causes COVID-19. SARS-CoV-2 virus predominately targets the respiratory system which can lead to pneumonia or acute respiratory distress syndrome although may also involve other organ systems or vessels and result in increased thromboembolic risk. COVID-19 related venous thromboembolism as well as thrombosis of the lower extremity arterial vasculature, mesenteric arterial vasculature, aorto-iliac, coronary arterial and cerebral arterial vasculature have been described.<sup>1–6</sup> A few cases of thrombosis involving different vascular territories in the same patient with COVID-19 have been reported in the literature including a 79-year-old woman with portal venous/mesenteric arterial thrombus,<sup>7</sup> a 75-year-old man with descending thoracic aortic and superior mesenteric arterial thrombus,<sup>4</sup> and a 58-year-old man with pulmonary arterial, intracardiac and peripheral arterial thrombosis.<sup>8</sup> To the best of our knowledge, we report the first case of aorto-bi-iliac arterial thrombosis with associated right lower extremity arterial thrombosis requiring limb amputation in a 40-year-old patient with COVID-19 who also developed thrombotic disease in the right ventricle, pulmonary arteries, and ilio-caval venous system.

## 2. Case report

A 40-year-old man was referred to our hospital after presenting initially at an outside medical facility with a two-week history of dyspnea, fever and dry cough. Past medical history included hypertension and diabetes mellitus type 2. At the outside medical facility, he tested positive for COVID-19, received prophylactic low molecular weight heparin and was found to have decreased right leg pulses six days after initial presentation. After initiation of therapeutic low molecular weight heparin for suspected arterial thrombosis, he was intubated for respiratory failure and transferred for further management. At time of admission, the patient was tachycardic with a heart rate in the 140 bpm range and had cold, mottled lower extremities with a pulseless right leg. Labs were notable for leukocytosis at 53.7 K/ $\mu$ L, elevated D-Dimer at 7.02  $\mu$ g/mL, and elevated total creatine kinase at 3399 U/L. Computed tomography angiography (CTA) showed aorto-bi-iliac arterial thrombus, occlusion of the right common/proximal external iliac arteries, and lack of right lower extremity arterial perfusion beyond the right mid superficial femoral artery (Fig. 1). There was no evidence of significant pre-existing atherosclerotic disease. Right lower lobe subsegmental pulmonary arterial thromboembolism and suspected right ventricular thrombus were also present (Fig. 2). Diffuse, bilateral ground glass opacities with peripheral posterior consolidation were present in

<sup>\*</sup> Corresponding author at: 300 Pasteur Drive, S078, Stanford, CA 94305, United States of America.

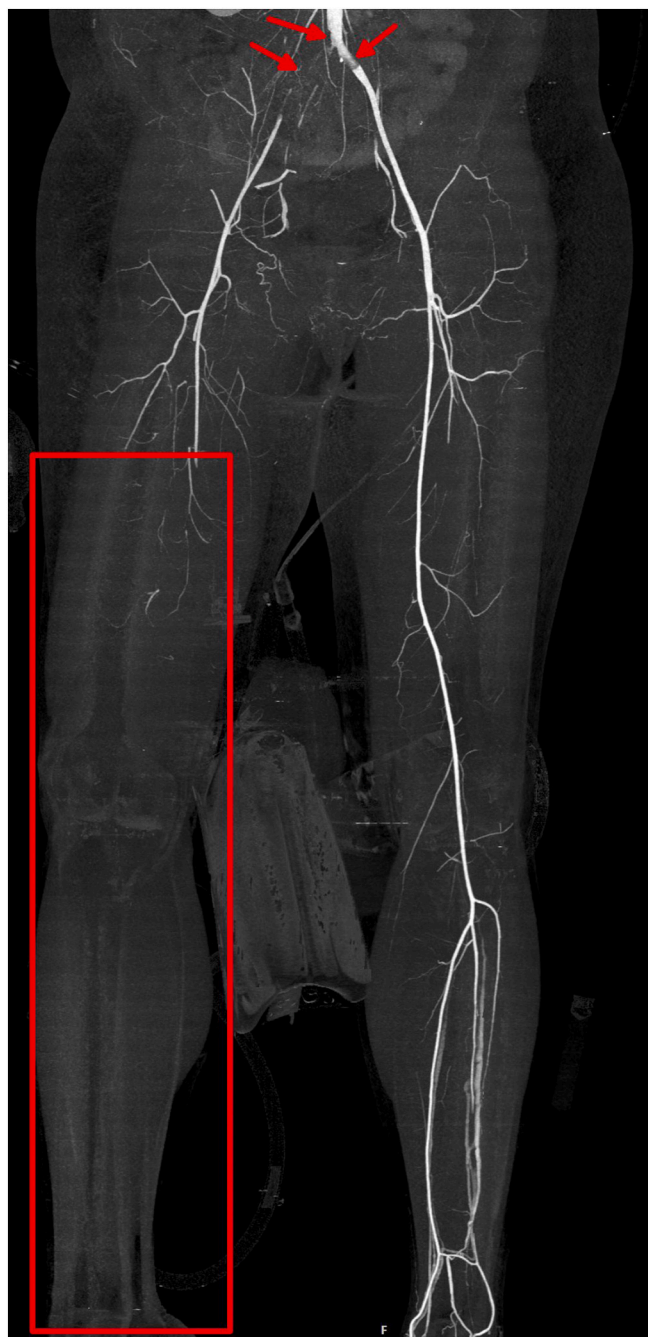E-mail address: [mmadani@stanford.edu](mailto:mmadani@stanford.edu) (M.H. Madani).

<https://doi.org/10.1016/j.clinimag.2020.12.036>

Received 15 October 2020; Received in revised form 20 November 2020; Accepted 30 December 2020

Available online 14 January 2021

0899-7071/© 2021 Elsevier Inc. All rights reserved.



**Fig. 1.** Maximum intensity projection (MIP) image of the lower limb CT angiography shows aorto-bi-iliac arterial thrombus and occlusion of the right common/proximal external iliac arteries (arrows) as well as occlusion of the right mid superficial femoral artery with lack of right lower extremity arterial perfusion distally (rectangle).

the lungs in an acute lung injury pattern which could be seen in patients with COVID-19 (Fig. 3). A clinical decision was made to amputate the right lower extremity due to evidence of irreversible acute limb ischemia on physical exam with a cold, mottled right leg having absent sensorimotor function and no detectable pulses. Bilateral iliac/femoral arterial thrombectomies and right lower extremity through the knee amputation were performed within the first 24 h of hospital admission. Mechanical ventilation was continued with administration of remdesivir, dexamethasone and empiric antibiotics. During the hospital course, the patient was dialyzed for rhabdomyolysis and remained on mechanical ventilation for hypoxemic respiratory failure. Echocardiogram agitated

saline study was negative for patent foramen ovale or atrial septal defect. Labs were negative for JAK2 mutation, antiphospholipid syndrome and lipoprotein(a). Combined CTV (computed tomography venography)/CTA (computed tomography angiography) one week following admission demonstrated thrombus in the inferior vena cava/left common iliac vein (Fig. 4), similar right lower lobe subsegmental pulmonary emboli/right ventricular thrombus, and interval decreased burden of aorto-bi-iliac arterial thrombus. Revision of the right lower extremity amputation was later performed to the above-the-knee level with resection of phlegmonous changes. With continued ventilatory and parenteral support, the patient's clinical status slowly improved and he was discharged from the hospital 41 days from time of transfer.

### 3. Discussion

Lung conditions such as pneumonia or acute respiratory distress syndrome are features of COVID-19.<sup>9</sup> However, the coronavirus SARS-CoV-2 causing COVID-19 can result in various other forms of pathology including hypercoagulability.<sup>10</sup> Venous thromboembolism (VTE) is a commonly reported thrombotic event associated with COVID-19.<sup>11</sup> A recent meta-analysis estimates the incidence of pulmonary embolism and deep venous thrombosis in COVID-19 patients to be 14% and 12% respectively.<sup>12</sup> In contrast, the incidence of other thrombotic events such as systemic arterial embolism, ischemic stroke and limb ischemia are lower at 2%, 2% and 1% respectively.<sup>12</sup>

We present a rare case of thrombosis involving the aortoiliac/right lower extremity arterial vasculature resulting in acute limb ischemia requiring amputation in a patient who also developed pulmonary arterial, right ventricular and ilio-caval venous thromboses. There have been recently proposed hypotheses related to the pathophysiology underlying COVID-19 associated hypercoagulability. Release of inflammatory cytokines may activate endothelial cells, neutrophils and monocytes resulting in a prothrombotic environment.<sup>11</sup> Also, direct SARS-CoV-2 viral infection of the endothelium via the ACE2 (angiotensin-converting enzyme 2) receptor is thought to ultimately induce formation of thrombin and fibrin clot.<sup>11</sup> ACE2 was found in both arterial and venous endothelial cells in multiple different organs.<sup>13</sup> Published guidelines suggest that thromboprophylaxis anticoagulation be used in acutely ill hospitalized or critically ill patients with COVID-19 in the absence of contraindications.<sup>14</sup> However, the optimal approach to management of anticoagulation in patients with COVID-19 is not certain.<sup>15</sup> Of note, our patient had reportedly received prophylactic low molecular weight heparin at an outside medical facility prior to presentation to our hospital. The failure of thromboprophylaxis in COVID-19 patients has been described in the literature previously and may be due to multiple prothrombotic factors.<sup>16</sup>

### 4. Conclusion

This case highlights that thrombosis may affect different sites and types of vasculature within the same individual with COVID-19. A high index of clinical suspicion is required for potential complications related to hypercoagulability in the setting of COVID-19. Imaging has a pivotal role for diagnosis of these complications.

### Declaration of competing interest

None.

### References

- [1] Wichmann D, et al. Autopsy findings and venous thromboembolism in patients with COVID-19: a prospective cohort study. *Ann Intern Med* 2020. <https://doi.org/10.7326/M20-2003>.
- [2] Goldman IA, Ye K, Scheinfeld MH. Lower-extremity arterial thrombosis associated with COVID-19 is characterized by greater thrombus burden and increased rate of

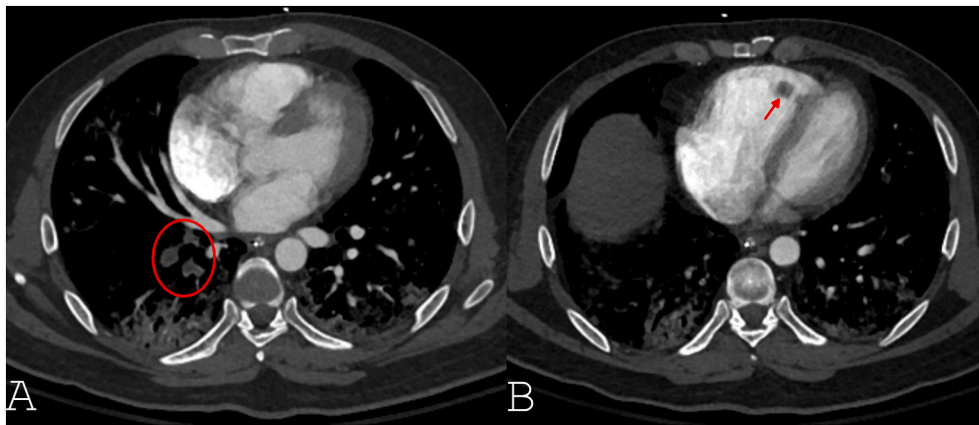


Fig. 2. Axial CT angiography of the chest. A) Multiple filling defects in the right lower lobe subsegmental pulmonary arteries (circle) consistent with pulmonary thromboembolism. B) Right ventricular mass (arrow) suspicious for intracardiac thrombus.

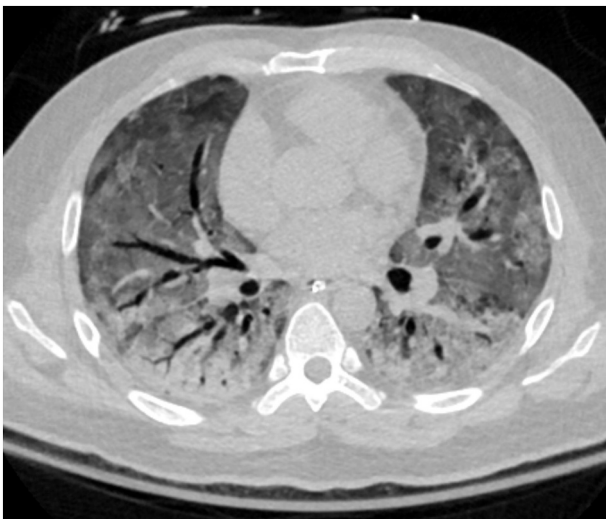


Fig. 3. Axial CT angiography of the chest in lung window. Diffuse bilateral ground glass pulmonary opacities with dependent consolidation and dilated airways, suggestive of diffuse alveolar damage.

amputation and death. *Radiology*. 2020;297(2):E263–9. <https://doi.org/10.1148/radiol.2020202348>.

- [3] Beccara LA, Pacioni C, Ponton S, Francavilla S, Cuzzoli A. Arterial mesenteric thrombosis as a complication of SARS-CoV-2 infection. *Eur J Case Rep Intern Med* 2020;7(5). [https://doi.org/10.12890/2020\\_001690](https://doi.org/10.12890/2020_001690). 001690.
- [4] Vulliamy P, Jacob S, Davenport RA. Acute aorto-iliac and mesenteric arterial thromboses as presenting features of COVID-19. *Br J Haematol* 2020;189(6): 1053–4. <https://doi.org/10.1111/bjh.16760>.
- [5] Dominguez-Erquicia P, Dobarro D, Raposeiras-Roubin S, Bastos-Fernandez G, Iniguez-Romo A. Multivessel coronary thrombosis in a patient with COVID-19 pneumonia. *Eur Heart J* 2020;41:2132.
- [6] Hess DC, Eldahshan W, Rutkowski E. COVID-19-related stroke. *Transl Stroke Res* 2020;7:1–4. <https://doi.org/10.1007/s12975-020-00818-9>.
- [7] de Barry O, Mekki A, Diffre C, Seror M, Hajjam ME, Carlier RY. Arterial and venous abdominal thrombosis in a 79-year-old woman with COVID-19 pneumonia. *Radiol Case Rep* 2020;15:1054–7.
- [8] Ferguson K, Quail N, Kewin P, Blyth K. COVID-19 associated with extensive pulmonary arterial, intracardiac and peripheral arterial thrombosis. *BMJ Case Reports CP* 2020;13:e237460.
9. Hu B, Guo H, Zhou P, et al. Characteristics of SARS-CoV-2 and COVID-19. *Nat Rev Microbiol* 2020. <https://doi.org/10.1038/s41579-020-00459-7>.
- [10] Haime MA. Pathogenesis and treatment strategies of COVID-19-related hypercoagulant and thrombotic complications. *Clin Appl Thromb Hemost* 2020;26. <https://doi.org/10.1177/1076029620944497>. 1076029620944497.
- [11] Abou-Ismaïl MY, Diamond A, Kapoor S, Arafah Y, Nayak L. The hypercoagulable state in COVID-19: incidence, pathophysiology, and management. *Thromb Res* 2020;194:101–15.
- [12] Kunutsor Setor K, Laukkanen Jari A. Incidence of venous and arterial thromboembolic complications in COVID-19: a systematic review and meta-analysis. *Thromb Res* 2020;196:27–30. <https://doi.org/10.1016/j.thromres.2020.08.022>.
- [13] Hamming I, Timens W, Bulthuis ML, Lely AT, Navis G, van Goor H. Tissue distribution of ACE2 protein, the functional receptor for SARS coronavirus. A first step in understanding SARS pathogenesis. *J. Pathol.* 2004;203:631–7.

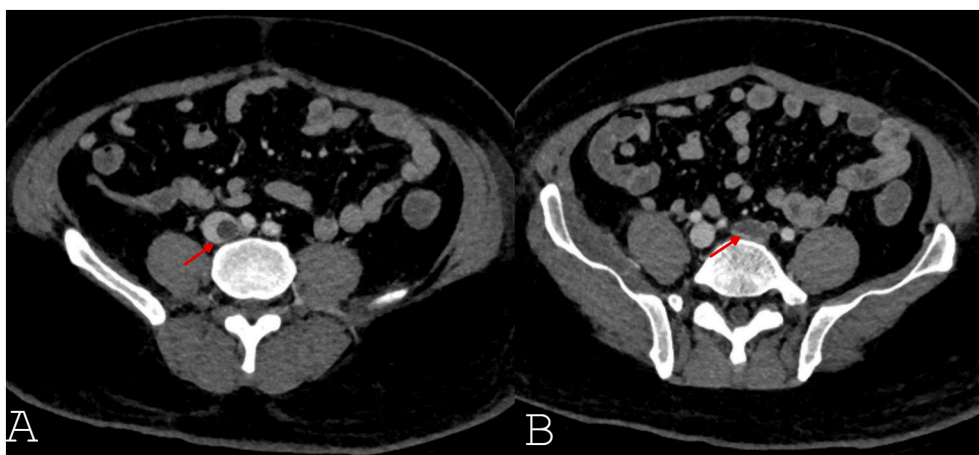


Fig. 4. Axial CT venogram of the lower extremity following bilateral iliofemoral arterial thrombectomies. A) Filling defect in the infrarenal inferior vena cava representing nonocclusive thrombus. B) Occlusive thrombus in the left common iliac vein.

- [14] Moores LK, Tritschler T, Brosnahan S, et al. Prevention, diagnosis and treatment of venous thromboembolism in patients with COVID-19: CHEST guideline and expert panel report. *Chest* 2020;S0012–3692(20):31625. <https://doi.org/10.1016/j.chest.2020.05.559>.
- [15] Mondal S, et al. Thromboembolic disease in COVID-19 patients: a brief narrative review. *J Intensive Care* 2020;8:70. <https://doi.org/10.1186/s40560-020-00483-y>.
- [16] Kow CS, Hasan SS. Use of low-molecular-weight heparin in COVID-19 patients. *J Vasc Surg Venous Lymphat Disord* 2020;8(5):900–1. <https://doi.org/10.1016/j.jvsv.2020.06.006>.