

# Fluoroscopy-Guided Suture Anchor Placement for Acetabular Labrum Repair



Paul Kenneth Herickhoff, M.D., and Jason Eric Mascoe, B.S.

**Abstract:** A narrow safe angle exists for placing suture anchors into the acetabular rim during arthroscopic acetabular labrum repair. Intra-articular suture anchor placement has been reported, and cadaver studies have shown the highest risk of errant suture anchor placement at the anterior acetabular rim. We describe a technique using intraoperative fluoroscopy to guide suture anchor placement into the anterior and superior acetabular rim, which may reduce the risk of iatrogenic injury during arthroscopic acetabular labrum repair.

**H**ip arthroscopy is a technically demanding procedure with a steep learning curve and reoperation rates as high as 15.4%.<sup>1</sup> For acetabular labrum repairs, improper suture anchor placement may result in damage to intrapelvic anatomical structures, iatrogenic cartilage injury, or intra-articular anchor placement.<sup>2</sup> Previous publications have demonstrated fluoroscopy-guided suture anchor placement into the superior acetabulum. This surgical technique uses fluoroscopy to guide suture anchor placement in the anterior and superior acetabular rim, which may reduce the risk of iatrogenic injury during arthroscopic acetabular labrum repair.

## Surgical Technique

The patient is positioned supine on a traction table (Steris OT 1000, Mentor, OH) with a large-diameter, padded perineal post. The dorsa of both feet are covered with abdominal pads wrapped in Coban (3M, St. Paul, MN) to reduce the risk of pressure sores and prevent slippage and secured in foam-lined boots. The nonsurgical leg is abducted 45° to 55°, allowing the C-arm to be brought between the legs. The surgical hip

is flexed 10° to 15°, the foot is internally rotated approximately 25° to bring the axis of the femoral neck parallel to the floor, and the thigh is adducted to 0° against the perineal post. The surgical site is prepped, and the C-arm and surgical site are draped using sterile technique. A surgical time-out is called prior to making incision.

Traction is applied to the operative extremity to open the superior joint space approximately 1 cm. The central compartment is accessed via standard anterolateral (AL) and midanterior (MA) portals, and an interportal capsulotomy is created using a straight beaver blade (Samurai; Stryker Sports Medicine, Greenwood, CO). Adjustable-length 8.0-mm Transport cannulas (Stryker Sports Medicine) are inserted through the AL and MA portals to facilitate instrument passage and switching the arthroscope between portals. A comprehensive diagnostic arthroscopy is performed. When a labrum tear is encountered, the location of the tear on the clockface of the acetabulum is recorded, and the tear is probed to evaluate whether the tear is amenable to repair (Fig 1, Video 1).

Once the decision to repair the acetabular labrum has been made, a distal anterolateral accessory (DALA) portal is typically made to improve the angle of approach to the acetabular rim. The capsulolabral recess is developed with electrocautery (50° CoolCut wand, Arthrex, Naples, FL) and judicious use of the shaver, preserving the capsule for later repair. A 4.0-mm round, hooded burr can be used to remove any pincer lesions and gently debride the acetabular rim to stimulate a healing response. The C-arm is then brought in, and an anteroposterior (AP) image of the hip is taken.

On an AP view of the hip, the x-ray beam is tangential to the superior acetabular dome, where the

From Penn State Sports Medicine, State College, Pennsylvania, U.S.A.

The authors report that they have no conflicts of interest in the authorship and publication of this article. Full ICMJE author disclosure forms are available for this article online, as [supplementary material](#).

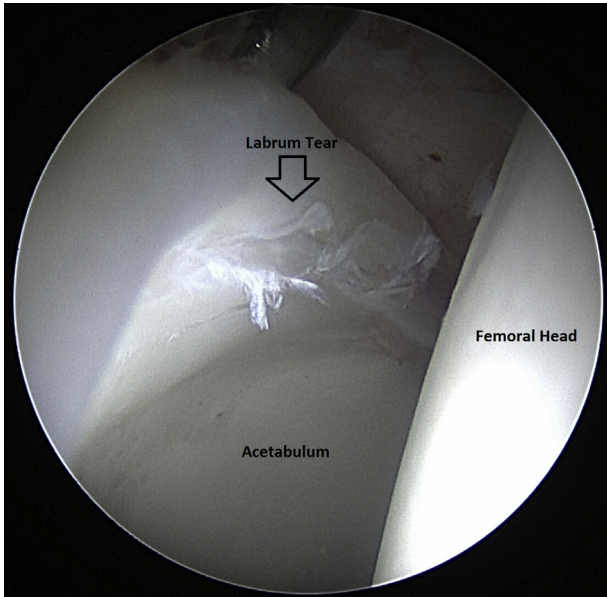
Received October 30, 2018; accepted December 10, 2018.

Address correspondence to Paul Kenneth Herickhoff, M.D., Penn State Sports Medicine, 1850 East Park Ave, Ste 112, State College, PA 16803, U.S.A. E-mail: [pherickhoff@pennstatehealth.psu.edu](mailto:pherickhoff@pennstatehealth.psu.edu)

© 2019 by the Arthroscopy Association of North America. Published by Elsevier. This is an open access article under the CC BY-NC-ND license (<http://creativecommons.org/licenses/by-nc-nd/4.0/>).

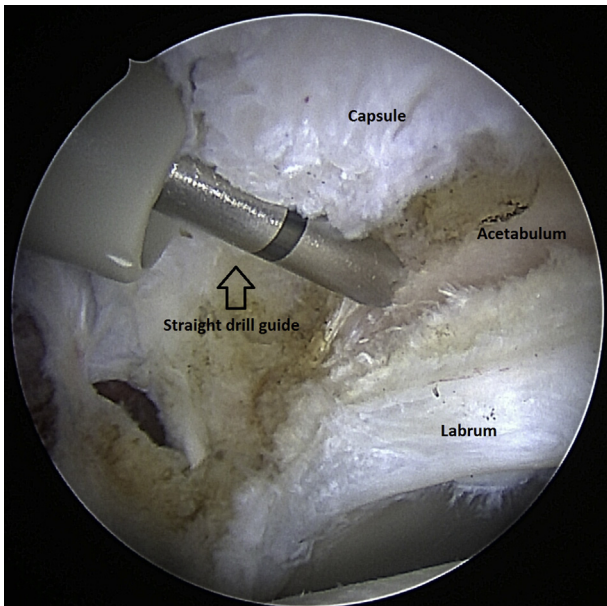
2212-6287/181304

<https://doi.org/10.1016/j.eats.2018.12.001>

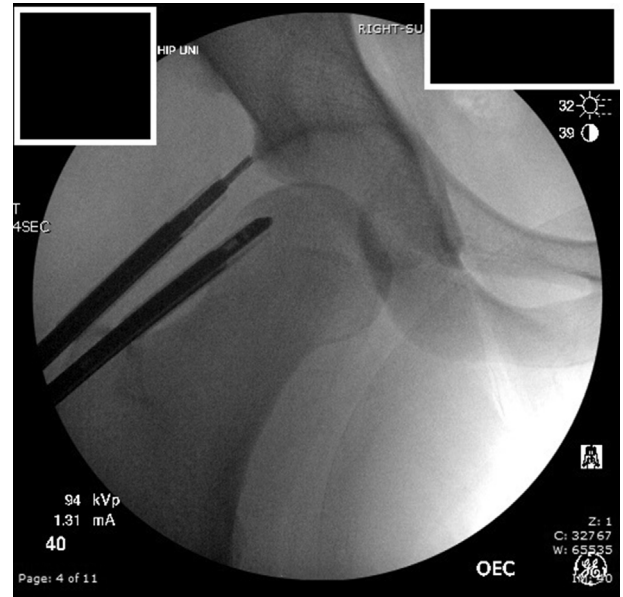

**Fig 1.** Right hip arthroscopic view from the anterolateral portal. The acetabular labrum is torn through the chondrolabral junction from the 12 o'clock to the 2 o'clock position.

subchondral bone is easily seen as a curved, dark line, known as the sourcil. Depending on the patient's lumbar lordosis, pelvic tilt, and acetabular tilt, the most superior portion of the acetabulum may or may not be directly opposite the cotyloid fossa at the 12 o'clock position described by Philippon et al.<sup>3</sup> For this example,



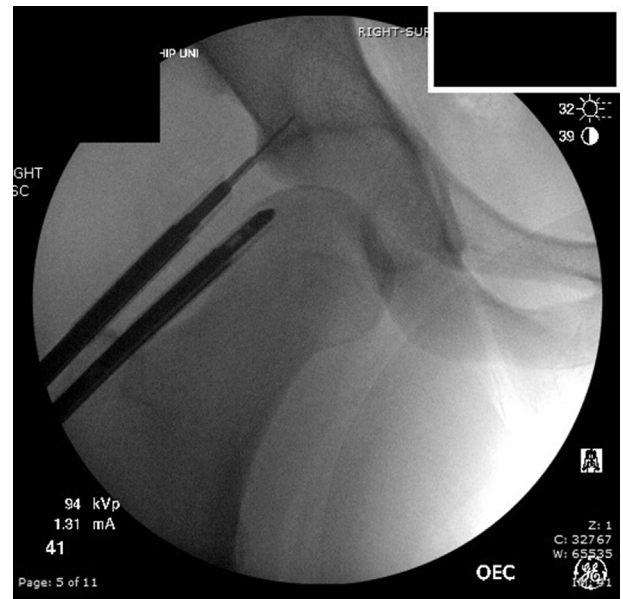**Fig 2.** Right hip arthroscopic view from the midanterior portal. A straight drill guide enters the hip through the distal anterolateral accessory portal. The tip of the drill guide is located at the 12 o'clock position, 2.3 to 2.6 mm from the acetabular rim.



**Fig 3.** Anteroposterior fluoroscopic view of the right hip shows a straight drill guide, inserted from a distal anterolateral accessory portal and positioned at the 12 o'clock position on the acetabular rim, slightly divergent from the subchondral bone.

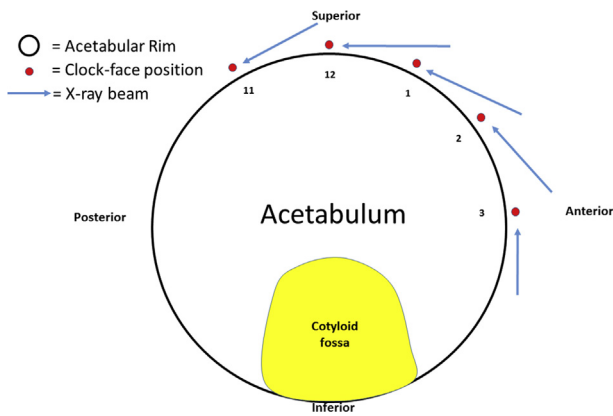
assume the most cephalad portion of the acetabular rim is at the 12 o'clock position.

To place a suture anchor at the 12 o'clock position, a straight drill guide for the Nanotack anchor (Stryker Sports Medicine) is placed through the DALA portal with the tip of the guide at the extracapsular labral insertion,



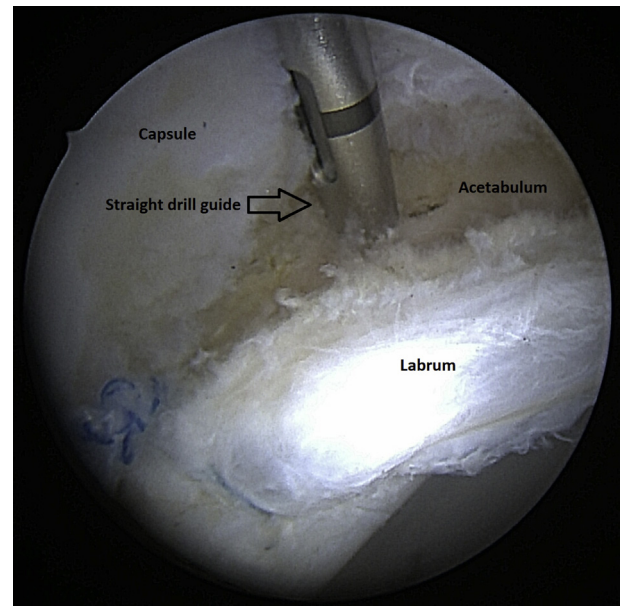
**Fig 4.** Anteroposterior fluoroscopic view of the right hip shows a 1.4-mm diameter, 17 mm long drill bit inserted through a distal anterolateral accessory portal into the acetabular rim at the 12 o'clock position, slightly divergent from the subchondral bone.





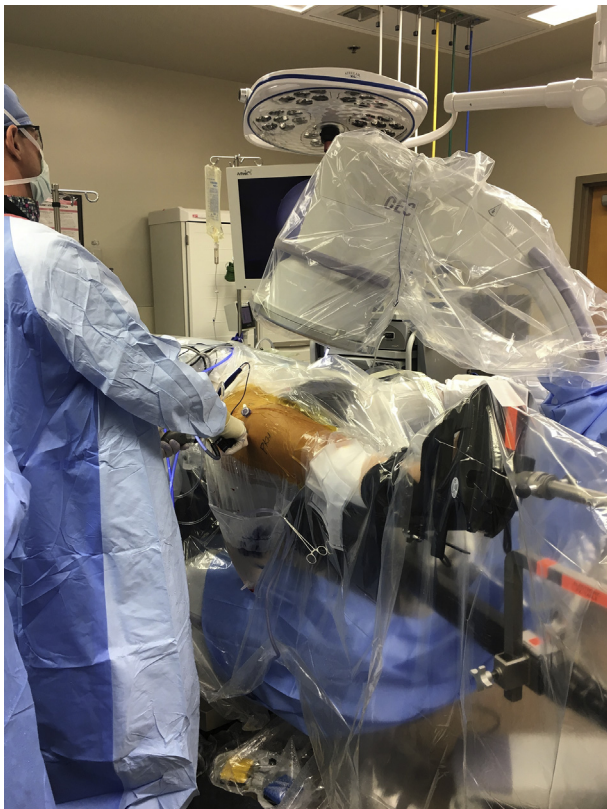**Fig 5.** This pictorial representation of the acetabulum depicts x-ray beams tangential to the acetabular rim at the 11 o'clock to 3 o'clock positions, enabling the surgeon to fluoroscopically visualize the subchondral bone at these locations.

2.3 to 2.6 mm from the edge of the acetabular rim<sup>4</sup> (Fig 2). The angle of the guide is adjusted so that the drill guide is parallel to or slightly divergent from the sourcil on fluoroscopy (Fig 3). A 1.4-mm pilot hole is then drilled while viewing the articular surface through the MA portal. Fluoroscopy is used to confirm the position of the drill bit in the subchondral bone (Fig 4). While keeping the drill guide in place, the drill is removed and a

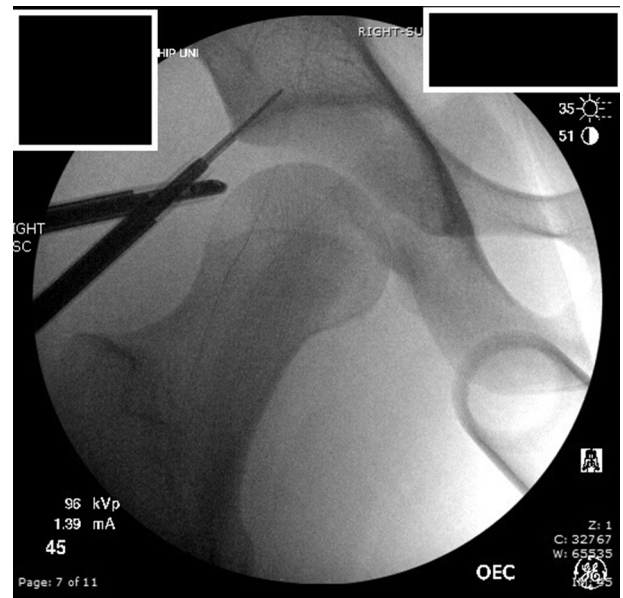

**Fig 7.** Right hip arthroscopic view from the anterolateral portal. A straight drill guide enters the hip through the distal anterolateral accessory (DALA) portal. The tip of the drill guide is located at the 1 o'clock position, 2.3 to 2.6 mm from the acetabular rim.

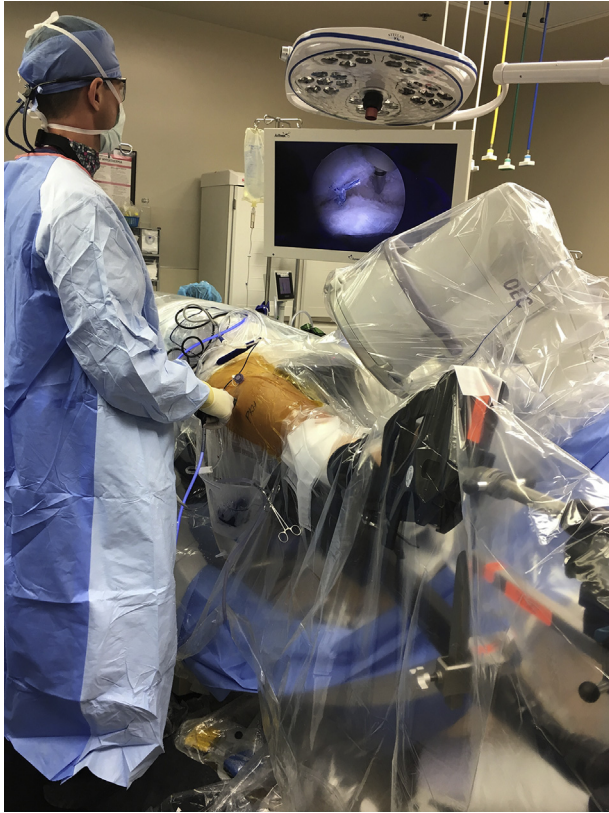
Nanotack suture anchor (Stryker Sports Medicine) is inserted and impacted past the laser line. The anchor is deployed by pulling on the purple tabs. The drill guide is removed, and the stability of the anchor is verified by pulling on the suture limbs. The suture limb closest to the labrum is then passed through the labrum using a curved



**Fig 6.** Right hip arthroscopy room setup. The C-arm is rotated backward 30° to view the subchondral bone at the 1 o'clock position on the acetabulum.

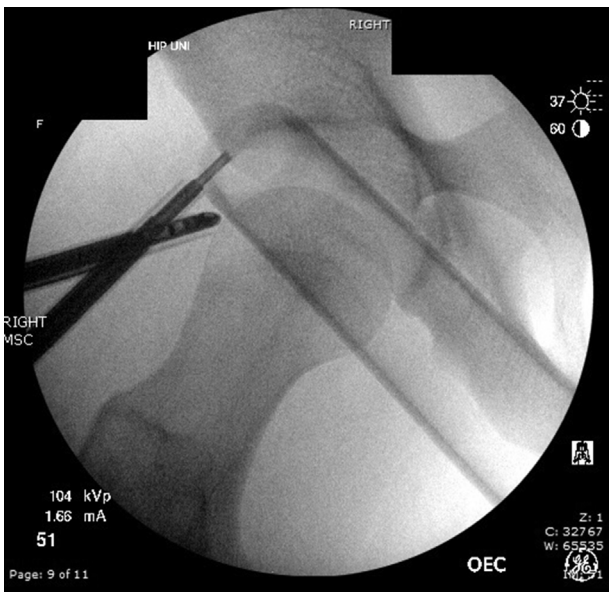


**Fig 8.** Fluoroscopic view of the right hip with the C-arm rotated 30° backward, showing the drill bit slightly divergent from the subchondral bone at the 1 o'clock position on the acetabulum.

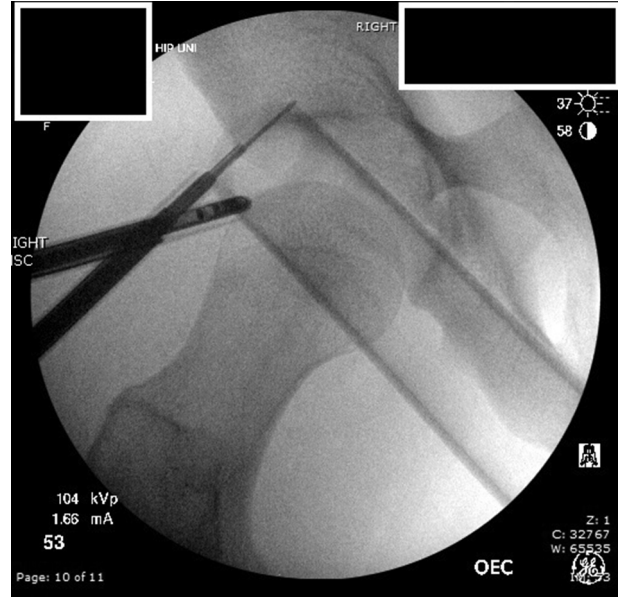

**Fig 9.** Right hip arthroscopy room setup. The C-arm is rotated backward 60° to view the subchondral bone at the 2 o'clock position on the acetabulum.

suture passer (Nanopass; Stryker Sports Medicine), in either a labral base stitch or circumferential stitch pattern. The sutures are then tied and cut.

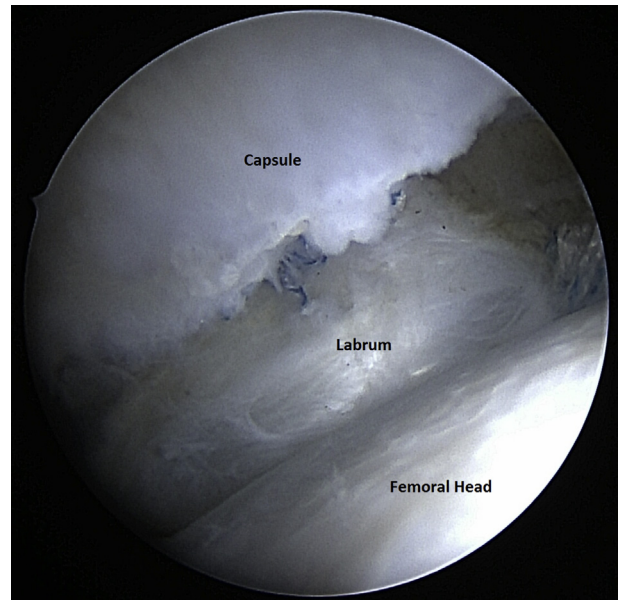


**Fig 10.** Fluoroscopic view of the right hip with the C-arm rotated 60° backward, showing the straight drill guide parallel to the subchondral bone at the 2 o'clock position on the acetabulum.



**Fig 11.** Fluoroscopic view of the right hip with the C-arm rotated 60° backward, showing the 1.4-mm diameter, 17 mm long drill bit parallel to the subchondral bone at the 2 o'clock position on the acetabulum.

More anteriorly located suture anchors can be placed by rotating the C-arm backward approximately 30° for each clockface position. The subchondral bone is visualized at the location where the x-ray beam is tangential to the acetabular rim (Fig 5). For example, to place an anchor at the 1 o'clock position, the C-arm is rotated backward 30° from the vertical (Fig 6). The subchondral



**Fig 12.** Right hip arthroscopic view from the anterolateral portal. Inspection of the acetabular labrum repair with traction released shows excellent restoration of the suction seal between the labrum and femoral head.



**Table 1.** Advantages and Limitations of Fluoroscopy-Guided Suture Anchor Placement

Advantages	Limitations
Reduces the risk of intrapelvic and intra-articular drilling and suture anchor placement	Metal in traction table may obstruct fluoroscopic views of posterior acetabular rim
Applicable in most acetabular labral repairs	Additional radiation to operating room staff
No additional equipment required	
Easy to learn	
Can instruct the surgeon whether a DALA portal or curved drill guides are required	

bone at the 1 o'clock position is visualized on fluoroscopy, the drill guide (Fig 7) is positioned parallel or slightly divergent from the subchondral bone, and the pilot hole is drilled (Fig 8). The acetabular subchondral bone at the 2 and 3 o'clock positions can similarly be visualized by rotating the C-arm backward an additional 30° for each clockface position (Fig 9) and used to guide anchor placement (Figs 10 and 11). To place suture anchors at the 11 o'clock position, the C-arm is rotated 30° forward from the vertical, and suture anchors are placed in a similar fashion. After the labrum repair is complete, traction on the hip is released and the repair is inspected from the peripheral compartment (Fig 12).

## Discussion

A narrow safe angle exists for placing suture anchors into the acetabular rim during arthroscopic acetabular labrum repair. Hernandez and McGrath<sup>4</sup> calculated a safe angle of 20.1° to 27.6° at the anterior, superior, and anterosuperior acetabular rim. Cadaveric studies have reported a 50% risk of acetabular fossa perforation with suture anchor placement at the 4 o'clock position,<sup>5</sup> 4% to 5% risk of articular perforation at the 3 o'clock position, and a 7.69% risk of psoas tunnel (intrapelvic) perforation between the 2 and 4 o'clock positions.<sup>6</sup> Improperly placed suture anchors can be seen on postoperative MRI scans and can be a source of pain after surgery.<sup>7</sup> Previous publications have illustrated the use of fluoroscopy to place suture anchors into the superior acetabulum; however, fluoroscopy-guided suture anchor placement at other locations around the acetabular rim, to our knowledge, has not previously been described.

The surgical technique described herein provides a safety check when drilling and inserting suture anchors into the anterior and superior acetabular rim and relies on the simple concept of using tangential fluoroscopic images to visualize the subchondral bone at the locations where suture anchors are to be placed (Fig 5). Similar to the sourcil being visible on an AP fluoroscopic image of the hip because it is tangential to the x-ray beam, the subchondral bone at other locations of

the acetabulum are seen by rotating the C-arm backward and forward.

Matsuda et al.<sup>2</sup> reported 5 cases of suture anchor-induced chondral damage in the hip. These authors suggested several techniques to prevent this complication, including using small-diameter, short suture anchors and visualizing the central compartment while drilling and placing suture anchors. In an anatomical study, Gereli et al.<sup>8</sup> showed the risk of perforation to the pelvic cavity started with when drilling past 20 mm. We agree with these recommendations; we routinely view the acetabular cartilage while drilling, and our preferred Nanotack suture anchor has a small, 1.4-mm diameter drill bit, drilling to a depth of 17 mm.

In a cadaveric study, Stanton and Banffy<sup>9</sup> concluded that the DALA portal allows suture anchors to be placed at a greater distance from the articular surface than the AL and MA portals. Conversely, cadaveric studies by Degen et al.<sup>6</sup> and Foster et al.<sup>5</sup> reported no statistically significant differences in articular surface or psoas tunnel perforation when hip anchors were placed in the anterior acetabular rim with a straight drill guide from the MA or the DALA portals. Our fluoroscopy-guided technique can instruct surgeons when suture anchors can be safely placed through the MA and AL portals and when it is necessary to create a DALA portal to improve the angle of approach to the acetabular rim.

The advantages of this surgical technique include that it is easy to learn, can be used with straight or curved drill guides, and does not require any additional equipment. A limitation of this technique is that radio-opaque metal hinges found in many commercially available hip arthroscopy traction tables may obstruct fluoroscopic views of the posterior acetabular rim. Therefore, for posterior labrum tears, fluoroscopy-guided suture anchor placement may not be possible. Since the acetabular labrum is most commonly torn in the anterosuperior quadrant,<sup>10</sup> however, this technique is germane to most hip arthroscopy labrum repairs. A second limitation is the small amount of additional radiation to operating room staff resulting from the increased use of fluoroscopy. A summary of the advantages and limitations of this technique is listed in Table 1.

## References

1. Mehta N, Chamberlin P, Marx RG, et al. Defining the learning curve for hip arthroscopy: A threshold analysis of the volume-outcomes relationship. *Am J Sports Med* 2018;036354651774921.
2. Matsuda DK, Bharam S, White BJ, Matsuda NA, Safran M. Anchor-induced chondral damage in the hip. *J hip Preserv Surg* 2015;2:56-64.
3. Philippon MJ, Stubbs AJ, Schenker ML, Maxwell RB, Ganz R, Leunig M. Arthroscopic management of femoroacetabular impingement: Osteoplasty technique and literature review. *Am J Sports Med* 2007;35:1571-1580.
4. Hernandez JD, McGrath BE. Safe angle for suture anchor insertion during acetabular labral repair. *Arthroscopy* 2008;24:1390-1394.
5. Foster AD, Ryan J, Ellis T, Flom J. Safe suture anchor insertion for anterior and posterior hip labral repair. *J Hip Preserv Surg* 2015;2:170-174.
6. Degen RM, Poultsides L, Mayer SW, et al. Safety of hip anchor insertion from the midanterior and distal anterolateral portals with a straight drill guide. *Am J Sports Med* 2017;45:627-635.
7. Li AE, Jawetz ST, Greditzer HG, Burge AJ, Nawabi DH, Potter HG. MRI evaluation of femoroacetabular impingement after hip preservation surgery. *Am J Roentgenol* 2016;207:392-400.
8. Gereli A, Kocaoglu B, Ulku KT, veli Ismailoglu A, Silay S, Karahan M. Are pelvic anatomical structures in danger during arthroscopic acetabular labral repair? Definition of safe bone depth. *Knee Surg Sports Traumatol Arthrosc* 2017;25:45-49.
9. Stanton M, Banffy M. Safe angle of anchor insertion for labral repair during hip arthroscopy. *Arthroscopy* 2016;32:1793-1797.
10. Seldes RM, Tan V, Hunt J, Katz M, Winiarsky R, Fitzgerald RH. Anatomy, histologic features, and vascularity of the adult acetabular labrum. *Clin Orthop Relat Res* 2001;(382):232-240.