

Case Report: Successful Rescue Therapy of Extensively Drug-Resistant *Acinetobacter baumannii* Osteomyelitis With Cefiderocol

Michael Dagher,¹ Felicia Ruffin,¹ Steven Marshall,^{2,3,4,5} Magdalena Taracila,^{2,3,4,5} Robert A. Bonomo,^{2,3,4,5} Rachel Reilly,⁶ Vance G. Fowler Jr.,¹ and Joshua T. Thaden¹

¹Division of Infectious Diseases, Duke University School of Medicine, Durham, North Carolina, USA, ²Louis Stokes Cleveland Department of Veterans Affairs Medical Center, Cleveland, Ohio, USA, ³Department of Medicine, Case Western Reserve University School of Medicine, Cleveland, Ohio, USA, ⁴Departments of Pharmacology, Molecular Biology and Microbiology, Biochemistry, and Proteomics and Bioinformatics, Case Western Reserve University School of Medicine, Cleveland, Ohio, USA, ⁵United States of America CWRU-Cleveland VAMC Center for Antimicrobial Resistance and Epidemiology (Case VA CARES), Cleveland, Ohio, USA, and ⁶Department of Orthopedic Surgery, Duke University School of Medicine, Durham, North Carolina, USA

Cefiderocol is a novel catechol siderophore cephalosporin antibiotic developed to treat resistant gram-negative infections. We describe its successful use as rescue therapy, combined with surgical debridement, to treat a patient with osteomyelitis due to extensively drug-resistant *Acinetobacter baumannii*. Bacterial whole-genome sequencing identified the strain and antibiotic resistance determinants.

Key words. *Acinetobacter baumannii*; antimicrobial resistance; cefiderocol; osteomyelitis.

Antimicrobial resistance is a major challenge in modern medicine, and new antibiotics are being developed to combat this problem. One such antibiotic is cefiderocol, a novel siderophore cephalosporin with catechol side chain that leads to bacterial uptake through the iron-transport system [1] and enhanced stability to β -lactamases. Cefiderocol has demonstrated in vitro efficacy against antibiotic-resistant gram-negative organisms [2], including *Acinetobacter baumannii* [3]. Here we describe successful treatment of osteomyelitis stemming from a polymicrobial infection that included extensively drug-resistant (XDR) *A. baumannii*. This patient received cefiderocol on a compassionate basis before its recent approval for use in

complicated urinary tract infections by the US Food and Drug Administration (FDA) [4].

CASE PRESENTATION

This is a case of a 57-year-old native Tanzanian gentleman, living in the United States, who developed a polymicrobial osteomyelitis that grew XDR *A. baumannii*. His medical history was significant for type 2 diabetes mellitus and hypertension that were well controlled with diet, metformin, amlodipine, and losartan. Ten days before presentation at our institution, he sustained an open comminuted left tibia and fibula fracture while traveling in his native Tanzania. He underwent external fixation followed by 2 surgical debridements at a local Tanzanian hospital. At that time, he was started on an unknown antibiotic that was presumed to be a tetracycline based on history from the patient.

Upon return to the United States, he presented to our institution due to worsening left leg pain. He was afebrile. Laboratory data were remarkable for leukocytosis (WBC, 12 400 cells/mm³) and elevated inflammatory markers (C-reactive protein [CRP], 4.59 mg/dL; erythrocyte sedimentation rate [ESR], 107 mm/h). X-ray imaging confirmed an open comminuted pilon fracture of the left tibia and fibula. The patient was started on piperacillin/tazobactam and admitted to the hospital (Figure 1).

The patient was taken to the operating room on hospital day (HD) 1 for revision of external fixation and surgical debridement. Frank purulence was not encountered, though necrosis along the tendons and muscle bellies of the flexor digitorum longus and flexor hallucis longus muscles was present. He underwent debridement down to the bone at the open fracture site. Tissue cultures from the fracture site grew vancomycin-susceptible *Enterococcus faecalis* and *Corynebacterium striatum*, as well as *A. baumannii* resistant to all routinely tested antibiotics at the Duke Clinical Microbiology Laboratory, including penicillins (ampicillin-sulbactam), cephalosporins (ceftazidime), aminoglycosides (amikacin, gentamicin, tobramycin), fluoroquinolones (ciprofloxacin, levofloxacin), carbapenems (meropenem), tetracyclines (minocycline), and sulfonamides (trimethoprim-sulfamethoxazole).

The patient underwent 3 additional operative debridements on HD3, HD6, and HD13. Intraoperative findings on HD3 and HD6 included stable wound appearance with healthy bleeding tissue. Repeat tissue cultures from HD3 and HD6 again demonstrated growth of *E. faecalis*, *C. striatum*, and *A. baumannii*, while tissue cultures from the final debridement on HD13 were free of bacterial growth. He returned to the operating room on HD15 for vastus lateralis muscle flap placement and definitive

Received 27 January 2020; editorial decision 16 April 2020; accepted 28 April 2020.

Correspondence: Joshua T. Thaden, MD, PhD, Division of Infectious Diseases, Duke University Medical Center, Room 301 Alexander H. Sands Building, 303 Research Drive, P.O. Box 102359, Durham, NC 27710 (joshua.thaden@duke.edu).

Open Forum Infectious Diseases®

© The Author(s) 2020. Published by Oxford University Press on behalf of Infectious Diseases Society of America. This is an Open Access article distributed under the terms of the Creative Commons Attribution-NonCommercial-NoDerivs licence (<http://creativecommons.org/licenses/by-nc-nd/4.0/>), which permits non-commercial reproduction and distribution of the work, in any medium, provided the original work is not altered or transformed in any way, and that the work is properly cited. For commercial re-use, please contact journals.permissions@oup.com DOI: 10.1093/ofid/ofaa150

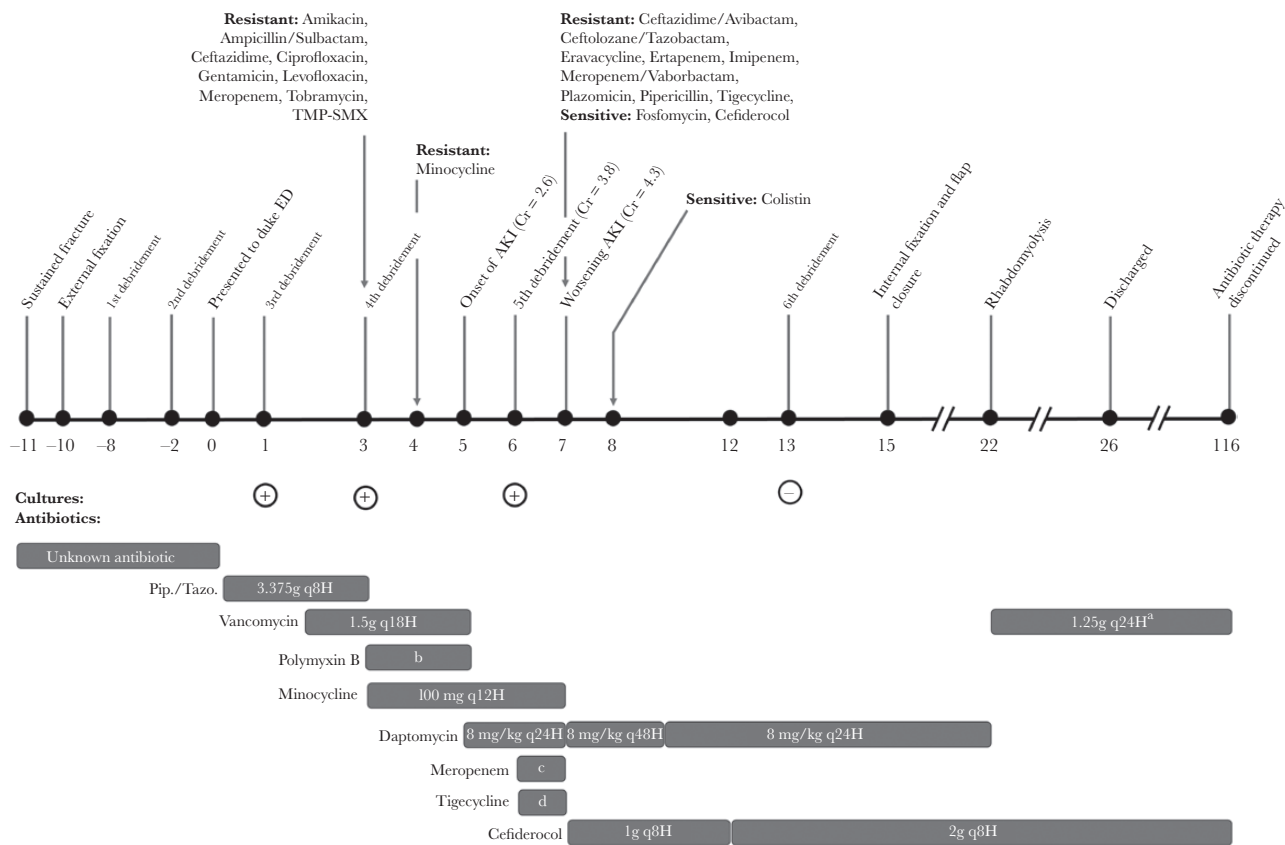


Figure 1. Timeline of events. ^aOutpatient dose gradually increased to 2 g q24H to maintain vancomycin levels of 10–15 mcg/mL. ^b2.5 mg/kg loading dose then 1.5mg/kg q12H. ^c8 mg/kg q24H. ^d2 g q12H. ^e100 mg loading dose then 50 mg q12H. Abbreviations: AKI, acute kidney injury; Cr, creatinine; ED, emergency department; Pip./Tazo., piperacillin-tazobactam; TMP-SMX, trimethoprim-sulfamethoxazole.

internal fixation. The tissue in the wound bed appeared healthy, and samples for tissue culture were not collected.

Antibiotic therapy was complicated by *A. baumannii* resistance to all tested agents at Duke University, the shipping and processing time associated with sending the bacterial isolate to outside laboratories for further antibiotic testing, and the adverse events associated with the toxic agents initially required to treat this infection. The bacterial isolate was sent to the Mayo Clinic for colistin susceptibility testing and to the Cleveland VA for cefiderocol, ceftazidime-avibactam, ceftolozane-tazobactam, eravacycline, fosfomycin, meropenem-vaborbactam, plazomicin, and tigecycline testing (Table 1).

Before the receipt of outside laboratory antibiotic susceptibility data, the patient was managed primarily with a combination of intravenous (IV) vancomycin, IV polymyxin B, and IV minocycline (Figure 1). On HD5, the patient developed acute kidney injury (AKI). His serum creatinine rose from a baseline of 1.3 mg/dL to a maximum of 4.3 mg/dL on HD7. Therefore, minocycline and polymyxin B were discontinued and replaced with tigecycline and meropenem. Despite intensive antibiotic therapy, cultures from the fifth surgical debridement on HD6 continued to grow XDR *A. baumannii*.

When the complete susceptibility profile of *A. baumannii* was available on HD7, it was found to only be susceptible to fosfomycin, colistin, and cefiderocol. Compassionate use cefiderocol was pursued under an emergency Investigational New Drug application to the US FDA, approved by the drug manufacturer (Shionogi), and started on HD7. Daptomycin was continued for treatment of *E. faecalis* and *C. striatum*. By HD12, the patient's kidney function had improved. He was receiving cefiderocol (2 g q8H) infused over 3 hours. After 6 days of cefiderocol therapy, the patient's sixth and final debridement on HD13 revealed sterile tissue cultures, the first indication of a positive microbiological response.

The patient's renal function returned to baseline and, aside from an episode of rhabdomyolysis secondary to daptomycin, he recovered smoothly and was discharged on HD26 with vancomycin IV and cefiderocol through a peripherally inserted central catheter. The patient reported no drug-related side effects or infusion site reactions. Weekly monitoring of laboratory studies showed no leukopenia, leukocytosis, AKI, or liver injury. He improved by all measures. He had no evidence of active infection on physical exam. Inflammatory markers normalized, with ESR 12 mm/h and CRP 0.29 mg/dL. Radiographic studies

Table 1. Antimicrobial Susceptibility Testing in XDR *Acinetobacter baumannii*

Antibiotic	Antibiotic Susceptibility Testing		
	Value	Unit (Method)	Interpretation ^a
Amikacin	>32	mcg/mL (MIC)	Resistant
Amoxicillin + clavulanate	>16/8	mcg/mL (MIC)	Resistant
Ampicillin	>16	mcg/mL (MIC)	Resistant
Ampicillin + sulbactam	>16/8	mcg/mL (MIC)	Resistant
Aztreonam	>16	mcg/mL (MIC)	Resistant
Cefazolin	>16	mcg/mL (MIC)	Resistant
Cefepime	>16	mcg/mL (MIC)	Resistant
Cefiderocol	23	mm (ZOI)	Susceptible
Ceftazidime	>16	mcg/mL (MIC)	Resistant
Ceftazidime + avibactam	15	mm (ZOI)	Resistant
Ceftolozane + tazobactam	10	mm (ZOI)	Resistant
Ceftriaxone	>32	mcg/mL (MIC)	Resistant
Cefuroxime	>16	mcg/mL (MIC)	Resistant
Ciprofloxacin	>2	mcg/mL (MIC)	Resistant
Colistin	≤2	mcg/mL (MIC)	Susceptible
Eravacycline	15	mm (ZOI)	Resistant ^b
Ertapenem	6	mm (ZOI)	Resistant
Fosfomicin	17	mm (ZOI)	Susceptible
Gentamicin	>8	mcg/mL (MIC)	Resistant
Imipenem	6	mm (ZOI)	Resistant
Levofloxacin	>4	mcg/mL (MIC)	Resistant
Meropenem	>8	mcg/mL (MIC)	Resistant
Minocycline	14	mm (ZOI)	Intermediate
Meropenem + vaborbactam	6	mm (ZOI)	Resistant
Nitrofurantoin	>64	mcg/mL (MIC)	Resistant
Piperacillin	6	mm (ZOI)	Resistant
Tetracycline	>8	mcg/mL (MIC)	Resistant
Tigecycline	6	mm (ZOI)	Resistant ^b
Tobramycin	>8	mcg/mL (MIC)	Resistant
Trimethoprim + sulfamethoxazole	>2/38	mcg/mL (MIC)	Resistant

Abbreviations: MIC, minimum inhibitory concentration; XDR, extensively drug-resistant; ZOI, zone of inhibition.

^aThese interpretations are based on Clinical and Laboratory Standards Institute standard breakpoints unless otherwise specified.

^bNo Clinical and Laboratory Standards Institute breakpoints are currently published for these agents. Interpretation was based on Food and Drug Administration identified susceptibility test interpretive criteria for *Enterobacteriaceae*.

after 102 days of cefiderocol therapy demonstrated interval fracture healing with progressive sclerosis and callus formation at the fracture site. Antibiotics were discontinued 116 days after he was initially admitted to the hospital. His course of cefiderocol totaled 109 days. Follow-up clinic visits 21, 65, and 128 days after cessation of antibiotics demonstrated no evidence of persistent or relapsed infection.

Whole-genome sequencing (WGS) was performed on the XDR *A. baumannii*. The genomic library was prepared with the Illumina NexteraXT kit and sequenced with the Illumina NextSeq 550 platform. Assembly and annotation of sequencing reads were performed with PATRIC [5]. Identification of antibiotic resistance genes was confirmed using ResFinder [6]. Multilocus sequence types (MLSTs) were 195 (Oxford scheme) and 2 (Pasteur scheme). Twelve putative antibiotic resistance genes were identified (Table 2). Of note, this strain carried OXA-23, an acquired class D β-lactamase associated with carbapenem resistance [7, 8]. The presence of OXA-66 β-lactamase could also play a role in carbapenem resistance, as it has been associated with nonsusceptibility to imipenem [9–11]. The presence of *armA* is associated with resistance to aminoglycosides. Gene *tetB* encodes an acquired efflux pump conferring resistance to minocycline. No mutations in the fluoroquinolone resistance genes *gyrA*, *parC*, or *parE* were detected. No mutations in endogenous porins or efflux pumps known to influence resistance were detected.

DISCUSSION

To our knowledge, this case is the first to document use of cefiderocol as rescue treatment adjuvant to surgical debridement for osteomyelitis containing XDR *A. baumannii*. Cefiderocol was successfully employed where no other commercially available drug options existed. A similar case report demonstrated successful use of cefiderocol to treat chronic osteomyelitis due to XDR *Pseudomonas aeruginosa*

Table 2. Antibiotic Resistance Determinants in XDR *Acinetobacter baumannii*; Antibiotic Resistance Genes Were Detected by Whole-Genome Sequencing

Gene	Resistance Mechanism	Conferred Resistance	References
<i>aph3''-Ib</i>	Enzymatic antibiotic inactivation	Aminoglycosides	[20–22]
<i>aph3'-Ia</i>	Enzymatic antibiotic inactivation	Aminoglycosides	[20, 22]
<i>aph6-Id</i>	Enzymatic antibiotic inactivation	Aminoglycosides	[20–22]
<i>armA</i>	Antibiotic target (16S ribosome) methylation	Aminoglycosides	[20–22]
<i>blaADC-73</i>	β-lactamase	β-lactams	[20, 23, 24]
<i>blaOXA-23</i>	β-lactamase	β-lactams, including carbapenems	[7, 8, 20–23]
<i>blaOXA-66</i>	β-lactamase	β-lactams, including carbapenems	[9–11, 20–22]
<i>blaTEM-1D</i>	β-lactamase	β-lactams	[20–22, 25]
<i>sul2</i>	Antibiotic target (di-hydro-pterolate synthase) alteration	Sulfonamides	[20–22]
<i>mphE</i>	Enzymatic antibiotic inactivation	Macrolides	[20, 22, 26]
<i>msrE</i>	Antibiotic target (ribosome) protection	Macrolides	[20, 22, 26]
<i>tetB</i>	Antibiotic efflux pump	Tetracyclines	[20–22]

Abbreviation: XDR, extensively drug-resistant.

and extended-spectrum β -lactamase-producing *Klebsiella pneumoniae* [12]; however, our case is promising in light of recent results from the CREDIBLE-CR study, which investigated the use of cefiderocol vs best available therapy to treat carbapenem-resistant gram-negative infections [13]. In patients with *A. baumannii* infections, CREDIBLE-CR demonstrated a decreased rate of clinical cure and an increased rate of clinical failure in patients treated with cefiderocol.

The success of cefiderocol likely stemmed from the unique structure of the siderophore cephalosporin with a catechol side chain, which confers stability against hydrolytic enzymes such as OXA β -lactamases [14] and allows for enhanced cellular uptake [1]. This mechanism of uptake via the bacterial iron-transport system may play a role in cefiderocol's efficacy against biofilm-associated infections such as osteomyelitis. Iron is crucial for biofilm formation, and siderophore production is upregulated in biofilms [15]. Furthermore, both uptake and in vitro activity of cefiderocol increase when bacterial iron acquisition systems are upregulated [1]. Thus cefiderocol may be particularly useful against biofilm-forming bacteria by capitalizing on their enhanced iron uptake.

Successful reports of cefiderocol rescue therapy in resistant gram-negative bacteremia secondary to pneumonia [3] and endocarditis [16] have been described. This case lends support to the idea that cefiderocol can penetrate bone tissue in sufficient concentrations when administered as 2 g 3 times daily. The success of this dosing schedule is consistent with other cephalosporins, as their bactericidal activity is linked to the proportion of time the plasma concentration exceeds the MIC [17].

This case also highlights the improved side effect profile of cefiderocol relative to alternative therapies for XDR *A. baumannii*, such as polymyxins, particularly regarding nephrotoxicity. CREDIBLE-CR reported lower rates of drug-related AKI in patients receiving cefiderocol relative to best available therapy [13], adding to previous research demonstrating its safety [18, 19]. In addition, this case and multiple additional reports have described the safe and successful use of cefiderocol to treat serious infections caused by gram-negative bacteria [3, 12, 16].

CONCLUSIONS

This case illustrates the successful treatment of osteomyelitis caused in part by XDR *A. baumannii* with surgical debridement and cefiderocol when no viable alternative antibiotics existed. Although more clinical and pharmacokinetic data are needed to understand the degree to which cefiderocol can penetrate bone and treat osteomyelitis, this case demonstrates that cefiderocol can be considered as rescue therapy in conjunction with surgical debridement for highly antibiotic-resistant gram-negative bacterial osteomyelitis.

Acknowledgments

Financial support. V.G.F. was supported by K24-AI093969 from the National Institutes of Health. V.G.F. reports grant/research support from MedImmune, Cerexa/Forest/Actavis/Allergan, Pfizer, Advanced Liquid Logics, Theravance, Novartis, Cubist/Merck, Medical Biosurfaces, Locust, Affinergy, Contrafact, Karius, Genentech, Regeneron, Basilea; has served as a paid consultant for Pfizer, Novartis, Galderma, Novadigm, Durata, Debiopharm, Genentech, Achaogen, Affinium, Medicines Co., Cerexa, Tetrphase, Trius, MedImmune, Bayer, Theravance, Cubist, Basilea, Affinergy, Janssen, xBiotech, Contrafact, Regeneron, Basilea, Destiny; reports membership in Merck Co-Chair V710 Vaccine; has received educational fees from Green Cross, Cubist, Cerexa, Durata, Theravance, Debiopharm; has received royalties from UpToDate.

Potential conflicts of interest. All authors: no reported conflicts of interest. All authors have submitted the ICMJE Form for Disclosure of Potential Conflicts of Interest. Conflicts that the editors consider relevant to the content of the manuscript have been disclosed.

References

1. Ito A, Nishikawa T, Matsumoto S, et al. Siderophore cephalosporin cefiderocol utilizes ferric iron transporter systems for antibacterial activity against *Pseudomonas aeruginosa*. *Antimicrob Agents Chemother* **2016**; 60:7396–401.
2. Dobias J, Déneraud-Tendon V, Poirel L, Nordmann P. Activity of the novel siderophore cephalosporin cefiderocol against multidrug-resistant gram-negative pathogens. *Eur J Clin Microbiol Infect Dis* **2017**; 36:2319–27.
3. Trecarichi EM, Quirino A, Scaglione V, et al; IMAGES Group. Successful treatment with cefiderocol for compassionate use in a critically ill patient with XDR *Acinetobacter baumannii* and KPC-producing *Klebsiella pneumoniae*: a case report. *J Antimicrob Chemother* **2019**; 74:3399–401.
4. US Food and Drug Administration. Highlights of Prescribing Information: Fetroja (Cefiderocol). US Food and Drug Administration; **2019**.
5. Wattam AR, Davis JJ, Assaf R, et al. Improvements to PATRIC, the all-bacterial bioinformatics database and analysis resource center. *Nucleic Acids Res* **2017**; 45:D535–42.
6. Zankari E, Hasman H, Cosentino S, et al. Identification of acquired antimicrobial resistance genes. *J Antimicrob Chemother* **2012**; 67:2640–4.
7. Evans BA, Amyes SG. OXA β -lactamases. *Clin Microbiol Rev* **2014**; 27:241–63.
8. Smith CA, Antunes NT, Stewart NK, et al. Structural basis for carbapenemase activity of the OXA-23 β -lactamase from *Acinetobacter baumannii*. *Chem Biol* **2013**; 20:1107–15.
9. Gonzalez F, Culebras E, Head J, et al. Outbreak of (OXA-66 carbapenemase) multidrug-resistant *Acinetobacter baumannii* in a Spanish tertiary-care hospital: epidemiology and study of patient movements. *Int J Infect Dis* **2010**; 14: e42–3.
10. Hu WS, Yao SM, Fung CP, et al. An OXA-66/OXA-51-like carbapenemase and possibly an efflux pump are associated with resistance to imipenem in *Acinetobacter baumannii*. *Antimicrob Agents Chemother* **2007**; 51:3844–52.
11. Zander E, Chmielarczyk A, Heczko P, et al. Conversion of OXA-66 into OXA-82 in clinical *Acinetobacter baumannii* isolates and association with altered carbapenem susceptibility. *J Antimicrob Chemother* **2013**; 68:308–11.
12. Alamarat ZI, Babic J, Tran TT, et al. Long-term compassionate use of cefiderocol to treat chronic osteomyelitis caused by extensively drug-resistant *Pseudomonas aeruginosa* and extended-spectrum-beta-lactamase-producing *Klebsiella pneumoniae* in a pediatric patient. *Antimicrob Agents Chemother* **2020**; 64:e01872–19.
13. Shionogi Inc. Antimicrobial Drugs Advisory Committee: Cefiderocol Briefing Document (NDA#209445). Florham Park, NJ: Shionogi Inc; **2019**.
14. Aoki T, Yoshizawa H, Yamawaki K, et al. Cefiderocol (S-649266), a new siderophore cephalosporin exhibiting potent activities against *Pseudomonas aeruginosa* and other gram-negative pathogens including multi-drug resistant bacteria: structure activity relationship. *Eur J Med Chem* **2018**; 155:847–68.
15. Kang D, Kirienko NV. Interdependence between iron acquisition and biofilm formation in *Pseudomonas aeruginosa*. *J Microbiol* **2018**; 56:449–57.
16. Edgeworth JD, Merante D, Patel S, et al. Compassionate use of cefiderocol as adjunctive treatment of native aortic valve endocarditis due to extremely drug-resistant *Pseudomonas aeruginosa*. *Clin Infect Dis* **2019**; 68:1932–4.
17. Craig WA. Interrelationship between pharmacokinetics and pharmacodynamics in determining dosage regimens for broad-spectrum cephalosporins. *Diagn Microbiol Infect Dis* **1995**; 22:89–96.
18. Portsmouth S, van Veenhuyzen D, Echols R, et al. Cefiderocol versus imipenem-cilastatin for the treatment of complicated urinary tract infections caused

- by gram-negative uropathogens: a phase 2, randomised, double-blind, non-inferiority trial. *Lancet Infect Dis* **2018**; 18:1319–28.
19. Saisho Y, Katsube T, White S, Fukase H, Shimada J. Pharmacokinetics, safety, and tolerability of cefiderocol, a novel siderophore cephalosporin for gram-negative bacteria, in healthy subjects. *Antimicrob Agents Chemother* **2018**; 62:e02163–17.
 20. Jia B, Raphenya AR, Alcock B, et al. CARD 2017: expansion and model-centric curation of the comprehensive antibiotic resistance database. *Nucleic Acids Res* **2017**; 45:D566–73.
 21. Taitt CR, Leski TA, Stockelman MG, et al. Antimicrobial resistance determinants in *Acinetobacter baumannii* isolates taken from military treatment facilities. *Antimicrob Agents Chemother* **2014**; 58:767–81.
 22. van Hoek AH, Mevius D, Guerra B, et al. Acquired antibiotic resistance genes: an overview. *Front Microbiol* **2011**; 2:203.
 23. Hajjar Soudeih M, Dahdouh E, Daoud Z, Sarkis DK. Phenotypic and genotypic detection of β -lactamases in *Acinetobacter* spp. isolates recovered from Lebanese patients over a 1-year period. *J Glob Antimicrob Resist* **2018**; 12:107–12.
 24. Hujer KM, Hamza NS, Hujer AM, et al. Identification of a new allelic variant of the *Acinetobacter baumannii* cephalosporinase, ADC-7 beta-lactamase: defining a unique family of class C enzymes. *Antimicrob Agents Chemother* **2005**; 49:2941–8.
 25. Pomba-Féria C, Caniça M. A novel sequence framework (bla(TEM-1G)) encoding the parental TEM-1 beta-lactamase. *FEMS Microbiol Lett* **2003**; 220:177–80.
 26. Fernández-Cuenca F, Martínez-Martínez L, Pascual Á; Grupo GRAM; Miembros del Grupo GRAM. Evolution of the antimicrobial resistance rates in clinical isolates of *Pseudomonas aeruginosa* causing invasive infections in the south of Spain. *Enferm Infecc Microbiol Clin* **2020**; 38:150–4.