

# Rehabilitation of orbital cavity after orbital exenteration using polymethyl methacrylate orbital prosthesis

Sumeet Jain, Parul Jain<sup>1</sup>

Department of Prosthodontics, Sri Aurobindo College of Dentistry, <sup>1</sup>Consultant Novel Dental N Implant Clinic, Indore, Madhya Pradesh, India

## Abstract

Squamous cell carcinoma of the eyelid is the second most common malignant neoplasm of the eye with the incidence of 0.09 and 2.42 cases/100 000 people. Orbital invasion is a rare complication but, if recognized early, can be treated effectively with exenteration. Although with advancements in technology such as computer-aided design and computer-aided manufacturing, material science, and retentive methods like implants, orbital prosthesis with stock ocular prosthesis made of methyl methacrylate retained by anatomic undercuts is quiet effective and should not be overlooked and forgotten. This clinical report describes prosthetic rehabilitation of two male patients with polymethyl methacrylate resin orbital prosthesis after orbital exenteration, for squamous cell carcinoma of the upper eyelid. The orbital prosthesis was sufficiently retained by hard and soft tissue undercuts without any complications. The patients using the prosthesis are quite satisfied with the cosmetic results and felt comfortable attending the social events.

**Key Words:** Artificial eye, maxillofacial prosthesis, orbital exenteration, orbital neoplasm, polymethyl methacrylate

## Address for correspondence:

Dr. Sumeet Jain, Department of Prosthodontics, Sri Aurobindo College of Dentistry, SAIMS Campus, Sanwer Road, Bhorasala Post, Indore - 453 555, Madhya Pradesh, India. E-mail: dentistsumeet@gmail.com

**Received:** 21<sup>st</sup> February 2015, **Accepted:** 16<sup>th</sup> September, 2015

## INTRODUCTION

The loss of an eye is a traumatic event, and the disfigurement associated with it causes considerable physical and emotional disturbances. There are three different surgical procedures for removal of an eye and its varying contents viz., orbital evisceration, enucleation, and exenteration.<sup>[1]</sup> Orbital exenteration is the most radical procedure, which involves removal of the contents of the orbit. Common indications for exenteration include neoplasms such as squamous cell carcinoma, melanoma, painful or disfiguring blind eye, and

infection trauma.<sup>[2]</sup> Ablative surgical procedure incurs major financial burden, and hence the patient may seek a prosthetic treatment that is economical. An orbital prosthesis or artificial eye presents a feasible and practical alternative when esthetic and functional demands are beyond the capacity of local reconstructive efforts.<sup>[3]</sup> This clinical report presents the prosthetic rehabilitation of two male patients with carcinoma of the eye with a custom made polymethyl methacrylate (PMMA) orbital prosthesis after exenteration.

This is an open access article distributed under the terms of the Creative Commons Attribution-NonCommercial-ShareAlike 3.0 License, which allows others to remix, tweak, and build upon the work non-commercially, as long as the author is credited and the new creations are licensed under the identical terms.

**For reprints contact:** reprints@medknow.com

**How to cite this article:** Jain S, Jain P. Rehabilitation of orbital cavity after orbital exenteration using polymethyl methacrylate orbital prosthesis. J Indian Prosthodont Soc 2016;16:100-4.

Access this article online	
Quick Response Code:	Website: www.j-ips.org
	DOI: 10.4103/0972-4052.167944

**CASE REPORTS**

**Case 1**

A 91-year-old male patient, presented with the loss of the left eye [Figure 1] after orbital exenteration due to squamous cell carcinoma of left upper eyelid. At the time of tumor resection, the orbit was lined with a split-thickness skin graft taken from the thigh. The patient did not receive pre- or post-operative radiation treatment.

During the examination, the patient was concerned with his facial disfigurement and wanted an acceptable solution as early as possible. Various prosthetic treatment modalities ranging from acrylic resin orbital prosthesis to implant retained silicone prostheses were explained and discussed with the patient. Due to socioeconomic reasons, the patient chose orbital prosthesis made of acrylic resin. The fabrication of PMMA resin orbital prosthesis was planned, and it was decided to use available anatomic undercuts to retain the prosthesis.

**Procedure**

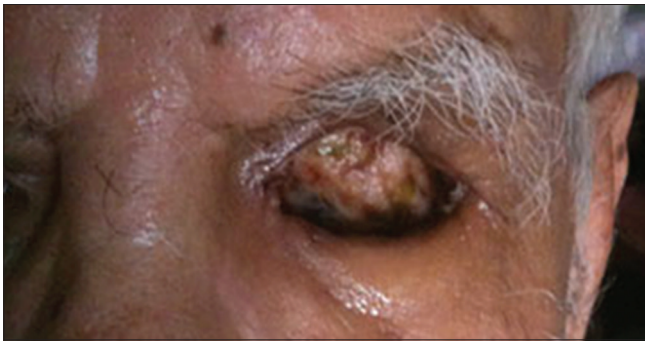
The patient was draped, and petroleum jelly was applied to the patient's eyebrows. An impression of the defect and adjacent tissues was made using a putty consistency polyvinyl siloxane [Figure 2]. After pouring the cast in type III dental stone, orbital wax pattern was hand sculpted in a circumferential

design adapting it to the perimeter of the defect with No. 2 dental modeling wax based on reversion of anthropometric landmarks and measurements taken from contralateral side.

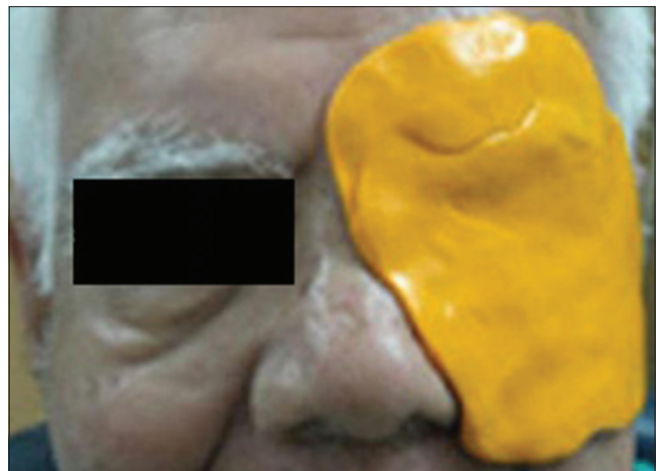The color of iris and sclera was matched with the adjacent eye; the selected artificial stock eye was adjusted in size. Correct position of the iris was also ensured by measuring the distance from facial midline and pupillary light reflex in the good eye and duplicating this measurement for the prosthesis. Moreover, different aids were used in aligning the artificial eye, after which it was positioned in the defect [Figure 3].

A trial of waxed prosthesis [Figure 4] was done using anatomic landmarks as a reference and was approved by the patient. Tissue texture and relevant contours were evaluated on the patients' face. The final impression of the wax pattern was made with light body consistency polyvinyl siloxane [Figure 5] to get the maximum adaptation with the underlying tissue and available undercuts.

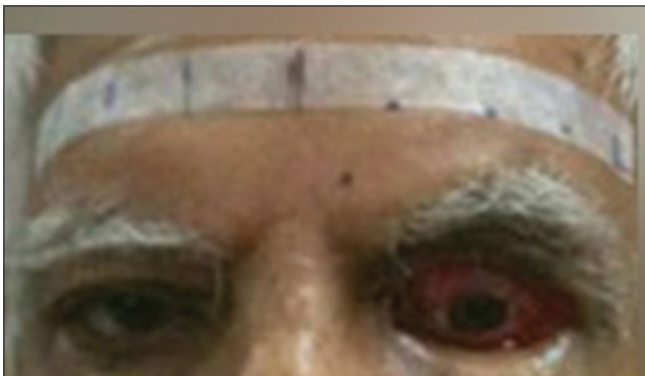The wax prosthesis was then invested [Figure 6], and the mold was prepared. After wax elimination, the prosthesis was processed using a clear PMMA resin material. Intrinsic coloring was done using an acrylic based paint, to match the skin color



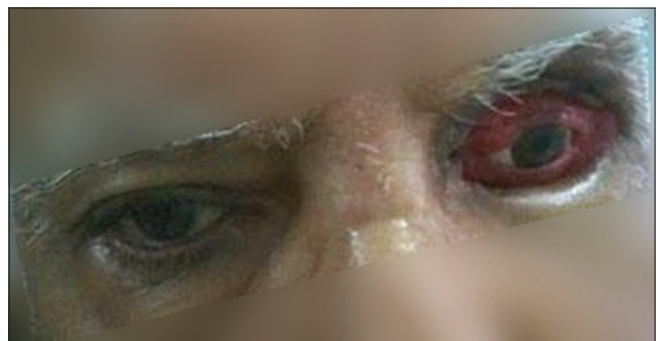
**Figure 1:** Frontal view of case 1 with left orbital defect



**Figure 2:** Impression making of defect



**Figure 3:** Vertical marks placed on forehead for orienting pupil in prosthesis



**Figure 4:** Try-in of orbital wax pattern with ocular component

around the patient's defect. Curing was carried out. The resin prosthesis was retrieved, finished, and polished.

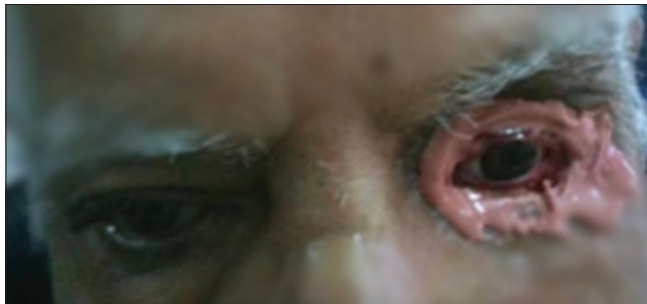
The prosthesis was evaluated in the patient face. Extrinsic coloration was done to further match with the skin tone of the patient and was made water-resistant by painting it with a monopoly. The eyeglasses were used to hide and mask the junction of the borders of the prosthesis with the surrounding areas. The prosthesis was then delivered [Figure 7].

The placement of the prosthesis was demonstrated to the patients and was then delivered.


Instructions regarding care and use were given to the patient. The first postinsertion visit was scheduled on the next day to ensure the health of tissues and to relieve the prosthesis for pressure areas in the tissues.

### Case 2

A 62 years male lost his left eye due to squamous cell carcinoma of the left upper eyelid [Figure 8a]. The orbit was lined with a split-thickness skin graft taken from thigh after orbital exenteration. He did not receive pre- or post-operative radiation treatment. During the examination, the patient was dissatisfied with his appearance. Various prosthetic treatment options were suggested and discussed with the patient. He chose PMMA orbital prosthesis. Prosthetic rehabilitation was done following the same line of treatment as in case I and PMMA resin orbital prosthesis using stock ocular prosthesis was delivered [Figure 8b]. The available anatomic undercut were used to retain the prosthesis.



**Figure 5:** Final impression of wax pattern with light bodied silicone impression material



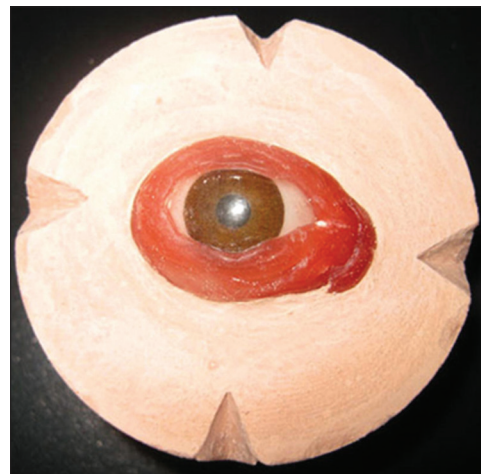**Figure 7:** Frontal view of case 1 with left orbital prosthesis and eyeglasses

At follow-up evaluation after 4 weeks, both patients were satisfied with the cosmetic results and felt comfortable attending social events with an orbital prosthesis. Patients were then asked to come for recall visit every 3 months for evaluation and observation of any recurrence.

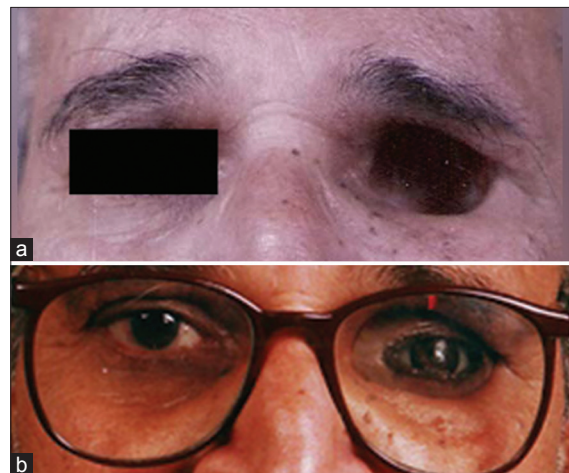### DISCUSSION

The fabrication of orbital prosthesis is delicate and complicated due to the fact that the orbital prosthesis contains within it a separate ocular prosthesis, which must be correctly matched to the remaining eye in size and contour, and positioned exactly in three-dimensional space to simulate the correct gaze and interlid opening. An orbital prosthesis should be aesthetic, long-lasting, lightweight, inexpensive, and most importantly retentive. Choice of retentive aid and material depend upon the size and type of defect, patient's esthetic demands, their lifestyle, financial condition, etc.

Computer-aided design and computer-aided manufacturing



**Figure 6:** Invested waxed prosthesis



**Figure 8:** (a) Case 2 with left orbital defect, (b) case 2 with orbital prosthesis and eyeglasses

method has been used to create negative mould on which orbital prosthesis has been made.<sup>[4]</sup> This method may be advantageous as more effective and simpler approach to measuring and evaluating the position of the iris and pupil than the conventional method but the main disadvantage of this method is that it requires special setup, armamentarium, and is costly.

The orbital prosthesis can be made from a variety of materials such as PMMA resin, polyurethane elastomer, silicone elastomer, or urethane-backed medical grade silicone.<sup>[5]</sup> In our case report of two cases, owing to socioeconomic constraint, PMMA resin was used for making orbital prosthesis. The advantages of this prosthesis are that it is noninvasive, tissue tolerant, aesthetic, comfortable to use, and easy to fabricate and clean. However, PMMA resin is more rigid and lacks translucency when compared with silicones. The color stability of PMMA resin can be increased by using monopoly<sup>[6]</sup> as a photoprotective agent on the top layer of the prostheses. Monopoly is a syrup of PMMA that was made by combining 10 parts of type I class I heat curing acrylic resin monomer to 1 part of the type I class I clear acrylic resin polymer by weight. The monomer is poured into a glass beaker and placed in a pan of boiling water. When the monomer is warm, the polymer is shifted slowly into monomer while it is stirred continuously with a glass rod. After 10 min, the solution obtains the viscosity of light oil. After the monopoly has cooled to room temperature, it is poured in a dark glass bottle and refrigerated. It is also available commercially.

The graft placed at the time of surgery provides a stable tissue base for support of prostheses, retention by tolerating the tissue adhesives and helps in maintaining hygiene.<sup>[7]</sup> In addition with the graft there is better adaptation of the margins of resin prostheses to the defect.

Available stock ocular prostheses are either made of PMMA or glass. PMMA is more durable, has longer life expectancy, color performance, better tissue compatibility, easily available, and inexpensive so was used in present cases whereas glass is more vulnerable to surface damage and deterioration.<sup>[8]</sup> This ready-made ocular prostheses are advantageous as they do not require an artist to complete the painting of iris and sclera, saving both time and money, but the disadvantage is that they only come in three shapes, three sizes of each shape and in three basic iris colors.<sup>[8]</sup>

Different methods have been used to retain orbital prosthesis such as skin adhesives, hard and soft tissue undercuts, attachment of the prosthesis to the eyeglass frame, magnets,<sup>[9]</sup> or extraoral osseointegrated implants.<sup>[10]</sup> The commonly used conventional method to retain orbital prosthesis is either the eyeglass frame or soft and hard tissue retentive undercut. The

glass frame has also been used widely to retain other facial prosthesis like nasal prosthesis,<sup>[11]</sup> but in our cases glass frame was used to hide the margins of the prosthesis, whereas available hard and soft tissue undercuts were used to retain prosthesis.

Implants although enhances the retention of the facial prostheses and improve patients' self-confidence and acceptance with treatment<sup>[12]</sup> but implant success in orbital defect (35%)<sup>[10]</sup> was significantly lower than nasal (71%)<sup>[12]</sup> and auricular (100%). Orbital sites owing to the monocular vision and the associated decrease in depth perception are most difficult for patients to clean, and assess the quality of their hygiene.<sup>[13]</sup> They have the highest rate of peri-implant tissue reaction, and the survival of implants placed in the irradiated bone is questionable, and financial constraints from a major setback for patients to opt for the implant-retained prosthesis.

A study by Jebreil<sup>[14]</sup> reported that most patients needed their orbital prostheses renewed every 6–9 months. The reasons given by the patients were a change in color, the marginal breakdown of the prosthesis, change in the defect, and the surgical reconstruction of the defect. The use of adhesives, routine cleaning, ultraviolet light, and air pollution all contributed in some way to the degradation of color and marginal integrity.

Therefore, selection of a reasonable maxillofacial prosthetic material and economically feasible retentive aid should be the goal of rehabilitating defects resulting from diseases like squamous cell carcinoma so that the patient resumes regular daily activity more comfortably and confidently.

## CONCLUSION

The custom made PMMA resin orbital prosthesis has been a boon to the average middle-class patients who cannot afford the expensive treatment options available. This procedure is affordable and can be carried out with the basic, clinical setup.

This method has provided good esthetics, acceptance, and satisfaction from patient's point of view. It also goes a long way in fulfilling the psychological rehabilitation of a person with average socioeconomic status, where a patient expects maximum positive results with minimum expenses.

## Declaration of patient consent

The authors certify that they have obtained all appropriate patient consent forms. In the form the patient(s) has/have given his/her/their consent for his/her/their images and other clinical information to be reported in the journal. The patients understand that their names and initials will not be published and due efforts will be made to conceal their identity, but anonymity cannot be guaranteed.

### Financial support and sponsorship

Nil.

### Conflicts of interest

There are no conflicts of interest.

### REFERENCES

1. Bartlett SO, Moore DJ. Ocular prosthesis: A physiologic system. *J Prosthet Dent* 1973;29:450-9.
2. Rasmussen ML, Prause JU, Johnson M, Kamper-Jørgensen F, Toft PB. Review of 345 eye amputations carried out in the period 1996-2003, at Rigshospitalet, Denmark. *Acta Ophthalmol* 2010;88:218-21.
3. Raffo GT. Enucleation and evisceration. In: Tasman W, Jaeger E, editors. *Duane's Clinical Ophthalmology*. 2<sup>nd</sup> ed., Vol. 5. Philadelphia, PA: Lippincott; 1995. p. 1-25
4. Bi Y, Wu S, Zhao Y, Bai S. A new method for fabricating orbital prosthesis with a CAD/CAM negative mold. *J Prosthet Dent* 2013;110:424-8.
5. Kiat-amnuay S, Lemon JC, Wesley PJ. Technique for fabricating a lightweight, urethane-lined silicone orbital prosthesis. *J Prosthet Dent* 2001;86:210-3.
6. Beumer J, Curtis TA, Marunick MT. *Maxillofacial Rehabilitation: Prosthodontic and Surgical Considerations*. 2<sup>nd</sup> ed. St. Louis: Ishiyaku Euroamerica; 1996. p. 404.
7. Parr GR, Goldman BM, Rahn AO. Maxillofacial prosthetic principles in the surgical planning for facial defects. *J Prosthet Dent* 1981;46:323-9.
8. Patil SB, Meshramkar R, Naveen BH, Patil NP. Ocular prosthesis: A brief review and fabrication of an ocular prosthesis for a geriatric patient. *Gerodontology* 2008;25:57-62.
9. Pruthi G, Jain V, Rajendiran S, Jha R. Prosthetic rehabilitation after orbital exenteration: A case series. *Indian J Ophthalmol* 2014;62:629-32.
10. Nishimura RD, Roumanas E, Moy PK, Sugai T, Freymiller EG. Osseointegrated implants and orbital defects: U.C.L.A. experience. *J Prosthet Dent* 1998;79:304-9.
11. Jain S, Maru K, Shukla J, Vyas A, Pillai R, Jain P. Nasal prosthesis rehabilitation: A case report. *J Indian Prosthodont Soc* 2011;11:265-9.
12. Nishimura RD, Roumanas E, Moy PK, Sugai T. Nasal defects and osseointegrated implants: UCLA experience. *J Prosthet Dent* 1996;76:597-602.
13. Nishimura RD, Roumanas E, Sugai T, Moy PK. Auricular prostheses and osseointegrated implants: UCLA experience. *J Prosthet Dent* 1995;73:553-8.
14. Jebreil K. Acceptability of orbital prostheses. *J Prosthet Dent* 1980;43:82-5.