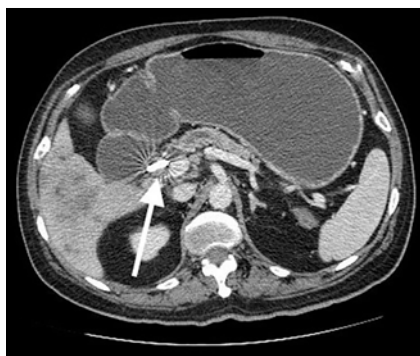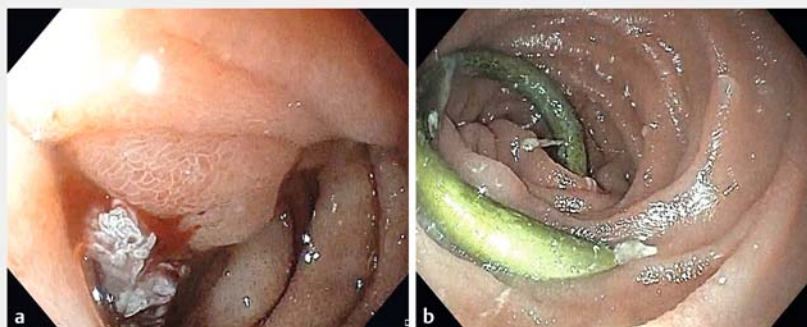


## Endoscopic retrieval of a blocked double-pigtail plastic biliary stent through an endoscopic ultrasound-guided gastrojejunostomy in a patient with gastric outlet obstruction

OPEN  
ACCESS



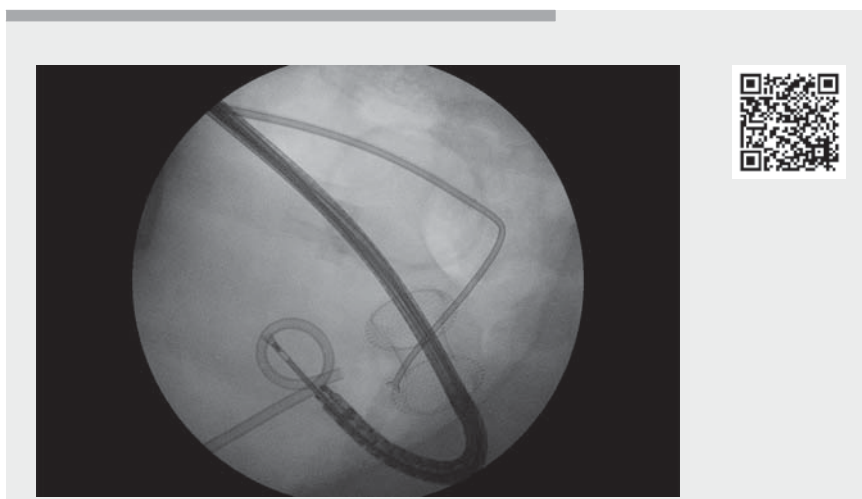
► **Fig. 1** Computed tomography image showing the dilated stomach with a plastic stent (arrow) hinged at the distal end of the common bile duct.



► **Fig. 2** Endoscopic images showing: **a** duodenal infiltration with luminal narrowing secondary to a periampullary cancer; **b** the plastic stent seen through the afferent limb of endoscopic ultrasound-guided gastrojejunostomy.

A 57-year-old man with metastatic periampullary carcinoma and a history of previous endoscopic retrograde cholangiopancreatography (ERCP) and placement of a double-pigtail plastic stent for distal common bile duct (CBD) obstruction presented with severe cholangitis and blockage of the stent. Emergency left-sided percutaneous transhepatic biliary drainage (PTBD) was performed. A computed tomography scan prior to the PTBD showed gastric outlet obstruction with a distally migrated double-pigtail stent, hinged in the distal CBD (► **Fig. 1**). During removal of the plastic stent, an infiltrative narrowing was seen, which started at the junction of the first and second parts of the duodenum, and extended to the papilla (► **Fig. 2 a**). A pediatric upper gastrointestinal endoscope (GIF XP170N; Olympus Medical Systems, Tokyo, Japan) was negotiated across the narrowing; however, the stent could not be retrieved.

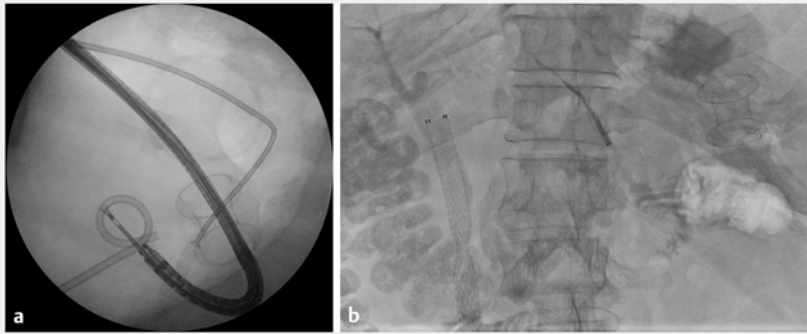
Endoscopic ultrasound-guided gastrojejunostomy (EUS-GJ) and subsequent retrieval of the stent through the afferent limb of the gastrojejunostomy was therefore planned (► **Video 1**). An oroenteric catheter was placed across the narrowing into the proximal jejunum. The EUS-GJ



► **Video 1** Video showing the retrieval of a migrated double-pigtail plastic stent through the afferent limb of an endoscopic ultrasound-guided gastrojejunostomy.

was created using the free-hand technique with a 20×10-mm Hot-Axios lumen-apposing metal stent (LAMS) delivery system (Boston Scientific, Marlborough, Massachusetts, USA), by puncturing the jejunum after it had been distended with saline and methylene blue. On the third day after the EUS-GJ, an upper gastrointestinal endoscope was passed across into the afferent limb of gastroje-

junostomy. The plastic stent (► **Fig. 2 b**) was grasped using a rat-tooth forceps and removed with gentle traction to avoid displacing the gastrojejunostomy stent (► **Fig. 3 a**). After successful retrieval of the plastic stent, the PTBD catheter was internalized and a 10×80-mm self-expanding metal stent (Niti-S; Taewoong Medical, Seoul, South Korea) was placed in the CBD (► **Fig. 3 b**).



► **Fig. 3** Fluoroscopic images showing: **a** the stent grasped using a rat-tooth forceps passed through the gastrojejunostomy; **b** a self-expanding metal stent in the common bile duct, having been placed through the percutaneous transhepatic biliary drainage tract, and the lumen-apposing metal stent used to create the endoscopic ultrasound-guided gastroenterostomy.

Gastric access using a LAMS has been described for the performance of ERCP in patients with a gastric bypass [1]. LAMS dislodgement is known to occur in up to 10%–20% of such cases [2, 3]. In order to avoid dislodgement, in this case, the endoscope was negotiated carefully across the LAMS and the stent was retrieved with gentle traction. Because of its double-pigtail nature, the stent could not be pushed into the deeper duodenum through an antegrade approach via PTBD. While retrieval of a migrated biliary stent through an enteral stent has been described [4], there are no previous reports of a biliary endoprosthesis being retrieved through an EUS-GJ.

Endoscopy\_UCTN\_Code\_TTT\_1AS\_2AB

### Competing interests

The authors declare that they have no conflict of interest.

### The authors

**Sridhar Sundaram, Kiran Mane, Unique Tyagi, Aadish Kumar Jain, Utkarsh Chhanchure, Prachi Patil, Shaesta Mehta**

Department of Digestive Diseases and Clinical Nutrition, Tata Memorial Hospital, Mumbai, India

### Corresponding author

**Sridhar Sundaram, MD**

Department of Digestive Diseases and Clinical Nutrition, Tata Memorial Hospital, Homi Bhabha National Institute, Parel, Mumbai 400012, India  
drsridharsundaram@gmail.com

### References

- [1] Wang TJ, Thompson CC, Ryou M. Gastric access temporary for endoscopy (GATE): a proposed algorithm for EUS-directed transgastric ERCP in gastric bypass patients. *Surg Endosc* 2019; 33: 2024–2033
- [2] Ngamruengphong S, Nieto J, Kunda R et al. Endoscopic ultrasound-guided creation of a transgastric fistula for the management of hepatobiliary disease in patients with Roux-en-Y gastric bypass. *Endoscopy* 2017; 49: 549–552
- [3] Tyberg A, Nieto J, Salgado S et al. Endoscopic ultrasound (EUS)-directed transgastric endoscopic retrograde cholangiopancreatography or EUS: mid-term analysis of an emerging procedure. *Clin Endosc* 2017; 50: 185–190
- [4] Vallabh H, Shah-Khan S, Hsueh W et al. Removal of migrated biliary stent by use of an enteral stent in a patient with gastric outlet obstruction caused by nonresectable pancreatic adenocarcinoma with prior loop gastrojejunostomy. *VideoGIE* 2017; 2: 195–196

### Bibliography

*Endoscopy* 2022; 54: E806–E807

DOI 10.1055/a-1824-4786

ISSN 0013-726X

published online 6.5.2022

© 2022. The Author(s).

This is an open access article published by Thieme under the terms of the Creative Commons Attribution-NonDerivative-NonCommercial License, permitting copying and reproduction so long as the original work is given appropriate credit. Contents may not be used for commercial purposes, or adapted, remixed, transformed or built upon. (<https://creativecommons.org/licenses/by-nc-nd/4.0/>)

Georg Thieme Verlag KG, Rüdigerstraße 14, 70469 Stuttgart, Germany



### ENDOSCOPY E-VIDEOS

<https://eref.thieme.de/e-videos>



*Endoscopy E-Videos* is an open access online section, reporting on interesting cases

and new techniques in gastroenterological endoscopy. All papers include a high quality video and all contributions are freely accessible online. Processing charges apply (currently EUR 375), discounts and waivers acc. to HINARI are available.

This section has its own submission website at

<https://mc.manuscriptcentral.com/e-videos>