




Case Report

Ventral cervico-thoracic meningeal cyst resulting in myelopathy: Case report and literature review

Shiwei Huang¹, David Freeman¹, Walter Galicich², Thomas Bergman²

¹Department of Neurosurgery, University of Minnesota, ²Department of Neurosurgery, Hennepin County Medical Center, Minneapolis, Minnesota, United States.

E-mail: *Shiwei Huang - huan2256@umn.edu; David Freeman - dfreeman@umn.edu; Walter Galicich - walter.galicich@hcmcd.org; Thomas Bergman - thomas.bergman@hcmcd.org



*Corresponding author:

Shiwei Huang,
Department of Neurosurgery,
University of Minnesota,
Minneapolis, Minnesota,
United States.

huan2256@umn.edu

Received : 23 August 2021
Accepted : 21 September 2021
Published : 11 October 2021

DOI
10.25259/SNI_850_2021

Quick Response Code:



ABSTRACT

Background: Spinal meningeal (dural) cysts rarely cause spinal cord compression and/or myelopathy.

Case Description: A 38-year-old male presented with 6 weeks of worsening bilateral lower extremity paresthesias and an unsteady gait. Notably, the patient was involved in a snowmobile accident 7 years ago that resulted in trauma to his thoracic spine for which he had undergone a corpectomy and posterior fusion. A full spine MRI was obtained to evaluate his new paresthesias and myelopathy, which revealed a large extra-axial fluid collection consistent with a meningeal cyst extending from C2 to T4. This caused severe spinal cord compression, maximal at the T1-3 level. The patient underwent a T1-3 laminectomy initially accompanied by partial cyst resection/drainage, but ultimately he returned and required a subsequent cystoperitoneal shunt. Following the final surgery, the patient's symptoms gradually resolved over 6 months postoperatively.

Conclusion: Spinal meningeal cysts rarely cause back pain and/or neurological symptoms. MRI is the diagnostic study of choice for defining this entity. Operative intervention must be tailored to the symptoms, location, extent, and type of the cyst. If cysts recur after partial resection and drainage, cystoperitoneal shunt placement is warranted.

Keywords: Cystoperitoneal shunt, Myelopathy, Spinal meningeal cyst

INTRODUCTION

Spinal meningeal cysts are diverticula of the spinal meninges, nerve root sheath, or arachnoid. There are three types: Type I - extradural meningeal cyst without nerve root fibers, Type II - extradural meningeal cyst with spinal nerve fibers, Type III intradural meningeal cysts [Table 1].^[1,3] Although some may arise due to trauma or inflammatory reactions, most are discovered incidentally. They are found most commonly in the lower thoracic and/or lumbosacral regions which may occasionally contribute to back pain and/or neurological deficits.^[3,4] Here, we report the case of a 38-year-old male who presented with a progressive myelopathy/paresis attributed to a post-traumatic C2-T4 ventral intradural meningeal cyst (Type III) that was effectively treated with laminectomy and cystoperitoneal shunting.

This is an open-access article distributed under the terms of the Creative Commons Attribution-Non Commercial-Share Alike 4.0 License, which allows others to remix, tweak, and build upon the work non-commercially, as long as the author is credited and the new creations are licensed under the identical terms.

©2021 Published by Scientific Scholar on behalf of Surgical Neurology International

Table 1: Spinal meningeal cyst classification.

| | |
|----------|--|
| Type I | Extradural meningeal cysts that do not contain nerve roots |
| Type Ia | Extradural meningeal cyst |
| Type Ib | Sacral meningocele |
| Type II | Extradural meningeal cysts contain nerve roots |
| Type III | Intradural meningeal cyst |

CASE DESCRIPTION

Seven years prior to the presentation, the patient had undergone a T12 corpectomy with T11-L1 posterior fusion following a snowmobile accident that resulted in a fracture-dislocation at T12. Now at age of 38 years, he newly presented with a 6-weeks of progressive dysesthesias from the waist down and a mild paraparesis/unsteady gait. On examination, he had subtle left leg weakness (attributed to his old trauma), but also reported newly decreased sensation to fine touch, pain, and temperature sensation from T5 level downward.

Diagnostic studies

The electromyogram showed a chronic peripheral neuropathy and left peroneal mononeuropathy, which did not fully explain the patient's symptoms. However, the full spine MRI revealed a large extra-axial fluid collection consistent with an arachnoid cyst extending from C2 to T4 that resulted in spinal cord compression, maximal between the T1-3 level [Figure 1]. There was an accompanying hyperintense T2 intramedullary signal within the thoracic spinal cord at these levels consistent with spinal cord edema.

Surgery

The patient initially underwent a T1-3 laminectomy for cyst resection. Once the dura was opened and the spinal cord was mobilized laterally, a few arachnoid bands were encountered and lysed, but no clear arachnoid cyst was visualized [Figure 2a]. However, the intraoperative ultrasound sagittal and axial views demonstrated a pulsatile fluid-filled mass located ventral to the spinal cord. An incision was made in the deep portion of the thickened dura, upon which immediate return of CSF appearing fluid was encountered. Notably, a separate layer of dura was also found immediately dorsal to the vertebrae indicating we indeed entered the cyst space [Figure 2b]. The dorsal cyst layer was fenestrated and opened both cranially and caudally, and a small piece of the cyst wall was sent for pathology that confirmed it was dura. Throughout the entire procedure, the somatosensory evoked potentials and motor evoked potentials signals were stable.

Post-operative course

Post-operatively, the patient had improvements in his symptoms over the next 3 days and was discharged.

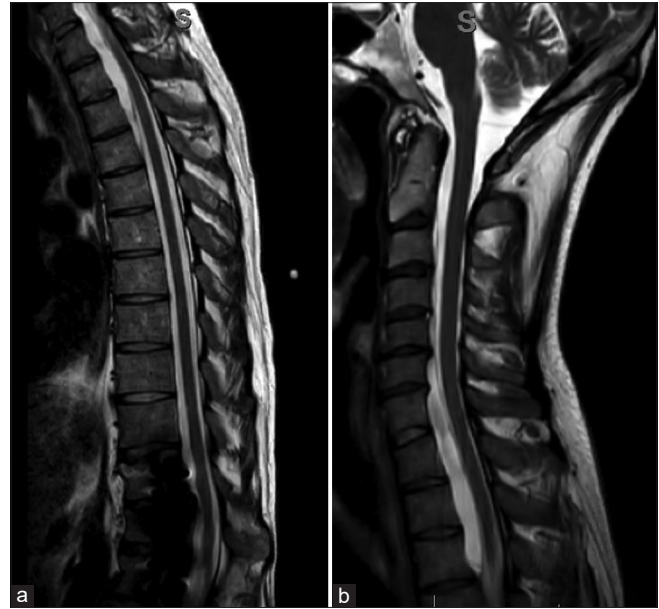

Figure 1: (a) Pre-operative imaging sagittal T2-weighted magnetic resonance image (MRI) of the thoracolumbar spine revealed a large ventral extra-axial cystic lesion causing spinal canal stenosis worst at T1-3. (b) Preoperative imaging sagittal T2-weighted MRI of the cervicothoracic spine revealed the cystic lesion extends to C2 level.

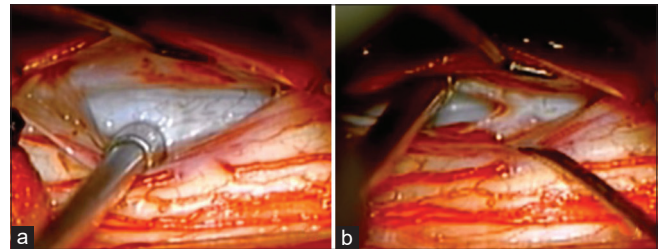


Figure 2: (a) Intraoperative photograph showed a large extradural meningeal cyst arising from the ventral aspect of the spinal canal. (b) The dural layer immediately ventral to the spinal cord was opened and revealed the "normal" layer of dura immediately dorsal to the vertebral body.

Nevertheless, the patient returned 2 months later with recurrent symptoms. The repeat MRI demonstrated recurrence of the fluid collection. As the prior laminectomy with cyst fenestration had failed, the repeat surgery included a cystoperitoneal shunt placement [Figure 3]. On a routine follow-up 6 months later, the patient reported full symptomatic relief.

DISCUSSION

Etiology of spinal meningeal cysts

Spinal meningeal cysts are defined as diverticula or pouches of arachnoid or dura that result in CSF accumulation. Their etiology is unknown. One popular proposed mechanism is

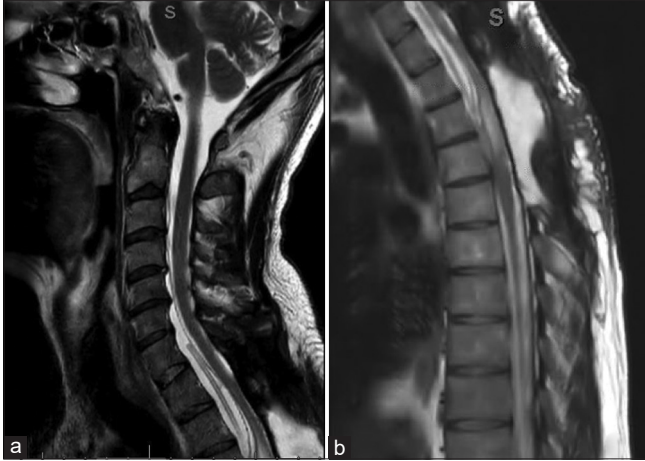

Figure 3: (a) Postoperative sagittal T2-weighted MRI cervical spine revealed improved central stenosis, decreased size of meningeal cyst with shunt catheter in place. (b) Postoperative sagittal T2-weighted MRI thoracic spine showed similar findings.

that a small defect, either congenital or traumatic, results in a cleft in the inner layer of the dura with the outer layer remaining intact. CSF fills the resultant “potential space” between the inner and outer dural layers. Hydrostatic dissection by CSF pulsations subsequently enlarges this potential space and forms a meningeal cyst.^[4,6] In this patient’s case, the snowmobile accident likely caused the formation of the spinal meningeal cyst.

Spinal meningeal cyst types

There are three types of spinal meningeal cyst classification (Type 1a/1b, II, and III) [Table 1].^[3]

Location of meningeal cysts

The majority of meningeal cysts are discovered accidentally. Approximately 80% of the cysts occur in the lower thoracic and/or lumbar spinal, and only 20% occur ventrally.^[3]

MR diagnosis of meningeal cysts

MR usually reveals the fluid in these cysts is consistent with CSF, although it can be more hyperintense than CSF on T2 due to the lack of CSF pulsations.^[5]

Neurological symptoms of meningeal cysts

Most meningeal cysts are asymptomatic, but when symptoms occur the most frequent symptoms are low back pain followed by radiculopathy. Very rarely do these lesions cause cord compression resulting in myelopathy, and rare cases of quadriplegia or paraplegia have been reported.^[6]

Management of meningeal cysts

The treatment of meningeal cysts may include fenestration, shunting (i.e., cystoperitoneal shunts), or complete surgical excision. Although patients may have initial symptoms relief following fenestration or decompression of the cysts, many will experience recurrence of symptoms. Management of recurrent meningeal cysts includes cyst shunting to ensure long-term CSF outflow from the cyst.^[1,2]

CONCLUSION

Spinal meningeal cysts rarely cause back pain and/or myelopathy, especially in the cervical-thoracic region. Notably, these lesions may be refractory to conventional surgical fenestration techniques and often warrant cystoperitoneal shunting.

Declaration of patient consent

Patient’s consent not required as patients identity is not disclosed or compromised.

Financial support and sponsorship

Nil.

Conflicts of interest

There are no conflicts of interest.

REFERENCES

1. Aoyama T, Miyaoka Y, Ogiwara T, Ito K, Seguchi T, Hongo K. Long segment spinal dural cyst: A case report. *World Neurosurg* 2016;88:686.e13-7.
2. Kunz U, Mauer UM, Waldbaur H. Lumbosacral extradural arachnoid cysts: Diagnostic and indication for surgery. *Eur Spine J* 1999;8:218-22.
3. Nabors MW, Pait TG, Byrd EB, Karim NO, Davis DO, Kobrine AI, *et al.* Updated assessment and current classification of spinal meningeal cysts. *J Neurosurg* 1988;68:366-77.
4. Netra R, Min L, Hui MS, Wang JC, Bin Y, Ming Z. Spinal extradural meningeal cysts: An MRI evaluation of a case series and literature review. *J Spinal Disord Tech* 2011;24:132-6.
5. Prevedello DM, Tatsui CE, Koerbel A, Grande CV, Cordeiro JG, Araujo JC. Ventral extradural spinal meningeal cyst causing cord compression: Neurosurgical treatment. *Arq Neuropsiquiatr* 2005;63:855-8.
6. Sato K, Nagata K, Sugita Y. Spinal extradural meningeal cyst: Correct radiological and histopathological diagnosis. *Neurosurg Focus* 2002;13:ecp1.

How to cite this article: Huang S, Freeman D, Galicich W, Bergman T. Ventral cervico-thoracic meningeal cyst resulting in myelopathy: Case report and literature review. *Surg Neurol Int* 2021;12:510.