

Pleomorphic rhabdomyosarcoma of the liver with a hepatic cyst in an adult

Case report and literature review

Jingyang Yin, MM, Zuojin Liu, MD, Kang Yang, MM*

Abstract

Rationale: Rhabdomyosarcoma (RMS), a malignant tumor with striated muscle differentiation, is the most common type of soft-tissue sarcoma in children and adolescents, but rarely occurs in adults, and especially in human livers. Moreover, this disease has a very poor prognosis. Here we report a case of primary RMS of the liver in a 66-year-old woman. This case is rare with respect to the location and clinical course of the tumor. The tumor had enlarged rapidly, ruptured, and eventually caused the patient's death after a long history of a stable abdominal mass that indicated a hepatic cyst.

Patient concerns: Before admission, a patient with a 5-year history of an abdominal mass was admitted to another hospital with symptoms of aggravated epigastric pain for the past 10 days. She was diagnosed with a hepatic cyst that had ruptured and hemorrhaged and was infected. This initial diagnosis was based on operative and pathologic findings.

Diagnoses: Pleomorphic RMS of the liver with a hepatic cyst was diagnosed and confirmed by imaging, surgery, and histopathological evaluation.

Interventions: Following admission, an emergency laparotomy was performed to treat the intra-abdominal hemorrhaging while further examinations were performed. Post-surgical histopathological evaluation found pleomorphic RMS tissue in the large mass that occupied the right lobe of the liver. No adjuvant chemotherapy was administered.

Outcomes: The patient died from malnutrition and multiple organ failure 141 days after her initial admission.

Lessons: Rhabdomyosarcomas in the liver are highly malignant tumors; therefore, early diagnosis and timely surgical resection are necessary to improve a patient's prognosis. We recommend that greater attention should be paid to a differential diagnosis of RMS for patients with hepatic masses that have ruptured. Moreover, preoperative imaging studies and percutaneous biopsy would be helpful for making a more specific diagnosis, and adjuvant chemotherapy should be administered for further treatment and for the purposes of future research.

Abbreviations: AFP = alpha-fetoprotein, CT = computed tomography, RMS = rhabdomyosarcoma.

Keywords: hepatic, liver, neoplasm, pleomorphic, rhabdomyosarcoma

1. Introduction

Rhabdomyosarcoma (RMS) is a rare malignancy that commonly occurs in childhood and constitutes more than 50% of all soft-tissue sarcomas. In contrast, RMS is exceedingly infrequent in adults; soft-tissue sarcomas make up less than 1% of all adult malignancies, and RMS accounts for 3% of all soft-tissue sarcomas.^[1] Moreover, the incidence of RMS of the liver is

extremely low. Only 20 cases of RMS of the liver have been reported through 2017,^[2–18] the majority of these were embryonal, and 5 cases were pleomorphic RMS. These studies suggested that rupture and necrosis often occur in cases of hepatic RMS. RMS is difficult to manage because of its high malignancy rate and the absence of standard treatment guidelines due to its rarity. Here we present a special case of a 66-year-old woman

Editor: N/A.

Other Information: Informed consent: The patient and guardians provided informed consent for the publication of this case report.

Competing Interests: The authors declare that they have no competing interests to declare, and all authors confirm the study's accuracy.

Funding: This work was supported by the Natural Science Foundation of China (No. 81470899).

The authors have no conflicts of interest to disclose.

Department of Hepatobiliary Surgery, The Second Affiliated Hospital of Chongqing Medical University, Chongqing, China.

* Correspondence: Kang Yang, Department of Hepatobiliary Surgery, The Second Affiliated Hospital of Chongqing Medical University. No. 74 Linjiang Road, Yuzhong District, Chongqing, China, 400010 (e-mail: johnniu00@outlook.com).

Copyright © 2018 the Author(s). Published by Wolters Kluwer Health, Inc.

This is an open access article distributed under the terms of the Creative Commons Attribution-Non Commercial License 4.0 (CCBY-NC), where it is permissible to download, share, remix, transform, and buildup the work provided it is properly cited. The work cannot be used commercially without permission from the journal.

Medicine (2018) 97:29(e11335)

Received: 23 February 2018 / Accepted: 28 May 2018

<http://dx.doi.org/10.1097/MD.0000000000011335>

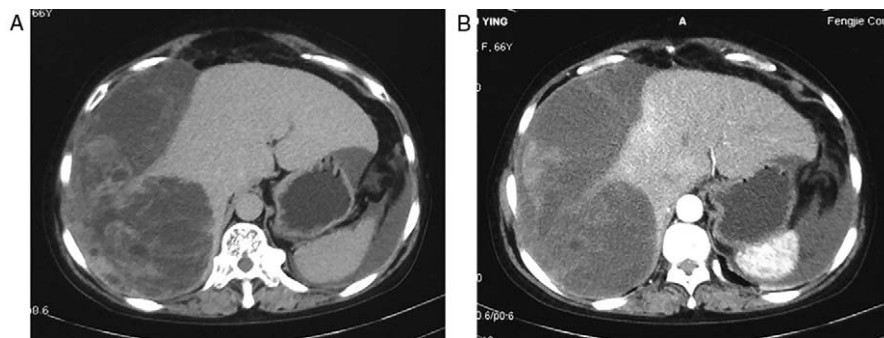


Figure 1. Contrast-enhanced computed tomography (CT) performed at the patient's first hospital admission. (A, B) Shows a giant mass in the right lobe, considered to be a benign occupying lesion, most likely a ruptured, hemorrhaging cyst. CT=computed tomography.

eventually diagnosed as having a hepatic cyst with pleomorphic RMS, which was initially regarded as a simple hepatic cyst. This study proposes that timely and accurate diagnosis and aggressive treatment may help improve the prognosis for these patients.

2. Case presentation

2.1. Patient information

One month before admission to our department (a provincial hospital), a 66-year-old woman with a 5-year history of an abdominal mass was admitted to another county hospital with symptoms of aggravated epigastric pain for the past 10 days. In response to the manifestation of an upper abdominal mass and persistent pain due to distention of her abdomen, a computed tomography (CT) scan was performed (Fig. 1). A hepatic cyst partial resection of the right hepatic lobe and windowing decompression of the right anterior lobe were performed based on the diagnosis of a ruptured hepatic cyst. Postoperative histopathological analysis confirmed the initial diagnosis. However, following the operation, the patient still felt the abdominal distention and even increased; therefore, a percutaneous puncture was made to her pelvic cavity in an attempt to drain the ascites and hematomas, which alleviated distention slightly.

Next, the patient was transferred to our institution, with the diagnosis of cyst rupture and hemorrhage. An emergency physical examination revealed upper abdominal tenderness and distention, with a mass of approximately 20×20 cm, and pitting edema of the lower limbs. A faint yellow fluid was found in the puncture drainage tube from the pelvic cavity.

Ethical approval was not required, because this is an observational and descriptive study without interventions for control study. The patient and her guardians provided informed consent, and her individual anonymity was well protected.

2.2. Clinical findings

Serum levels of alpha-fetoprotein (AFP) and AFP plastid ratio were within normal limits. Moreover, the following serum tumor markers were found: serum ferritin, 1,288.50 ng/mL; CA-125, 285.00 U/mL; CA-199, 55.82 U/mL, and CA-50, 68.52 U/mL. Contrast-enhanced CT scans of the abdomen and chest showed a 20×15 cm mass occupying the right lobe of the liver (Fig. 2).

2.3. Diagnostic assessment

Although the patient's first diagnosis was a hepatic cyst with rupture, hemorrhage, and infection, based on radiology findings and her history of surgeries, the initial diagnosis could not be

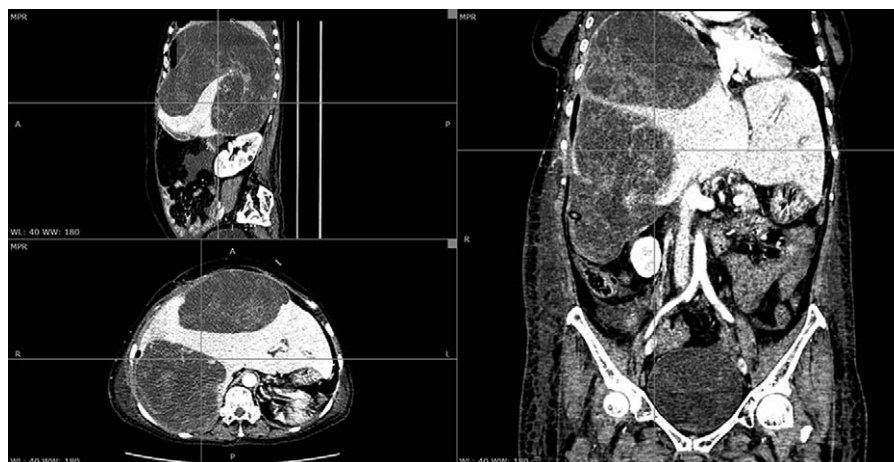


Figure 2. Computed tomography (CT) taken upon admission to our department showing a 20×15 cm extensive heterogeneous hypodense cystic lesion involving the right hepatic lobe, superior to the anterior edge of the liver. CT=computed tomography.

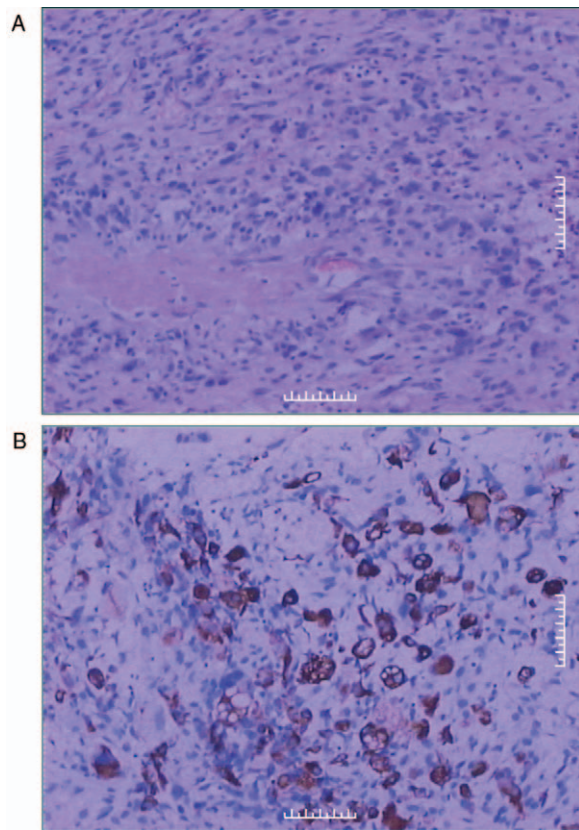


Figure 3. Micrographs of pathologic and immunohistochemical analysis: Loosely arranged, haphazardly oriented, large, round or pleomorphic cells with hyperchromatic and heteromorphic nuclei (A). Identical pleomorphic tumor that stained positively for desmin by using immunohistochemistry (B).

completely accepted based on the size of the mass and the presence of serum tumor markers. Therefore, primary hepatocellular carcinoma, sarcoma, mesenchymal hamartoma, and secondary metastasis were considered. Positron emission tomography did not identify focal hypermetabolic lesions elsewhere in the body, and percutaneous biopsy was needed for a more definitive diagnosis.

2.4. Therapeutic interventions

Previous operations had not eliminated the abdominal mass completely, as evidenced by the aggravation of the patient's symptoms. Symptomatic treatments were administered to address her poor general condition before further examination was performed. An emergency laparotomy to effect hemostasis and a right hepatic lobectomy were performed to treat intra-abdominal hemorrhage 3 days after admission, without a pre-operative biopsy. Intraoperatively, about 1000 mL of cloudy hemorrhagic ascites was found in the abdominal cavity. A large high-pressure mass was found, which measured approximately 20×15 cm adhered tightly to the omentum, mesentery, and intestines anteriorly, and to the abdominal wall and diaphragm posteriorly. Cloudy brown fluid containing bile was extracted from the mass, which suggested that the mass was a hepatic cyst hydrops with hemorrhage and infection. Unfortunately, no intraoperative image was captured during the emergency surgery. Postoperative histopathological evaluation demonstrated loosely arranged, haphazardly oriented, large, round or pleomorphic cells with hyperchromatic and heteromorphic nuclei. Immunohistochemical analysis was positive for vimentin, desmin (Fig. 3), Ki-67, myosin, CD34 (vessel positive), and VIII factor (vessel positive), and negative for cytokeratin. Based on these findings, the diagnosis was established to be a hepatic cyst with RMS of the liver. Following the surgery, a percutaneous puncture was performed to drain the residual ascites and hematomas. A postoperative CT scan taken 18 days after the resection showed a heterogeneous hypodense cystic-solid lesion in the right subphrenic space and did not exclude the possibility of recurrence (Fig. 4). The patient and her guardians refused chemotherapy and other adjuvant therapies due to their passive view of disease and concerns about a low quality of life.

2.5. Follow-up and outcomes

The patient was discharged from our hospital in relatively stable condition and turned to Chinese traditional medicine and herbs for treatment. She died approximately 141 days after her initial hospital admission for malnutrition and multiple organ failure. With respect to the disease presentation and the manifestations

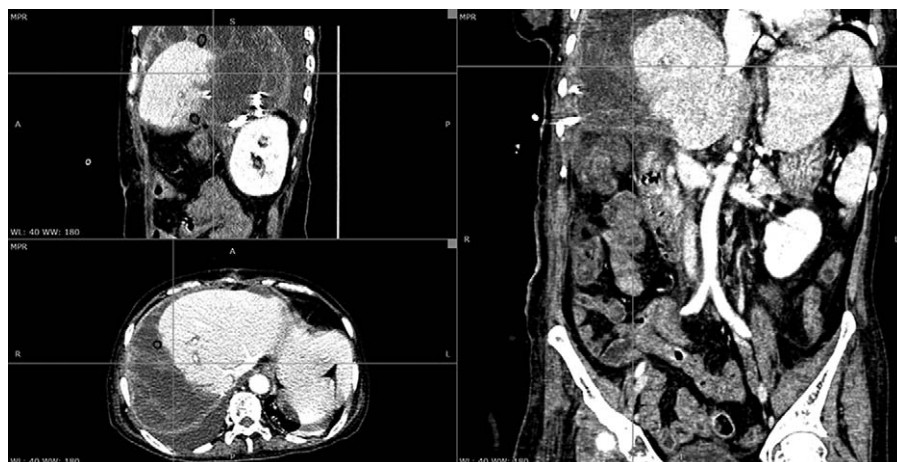


Figure 4. Computed tomography (CT) taken 8 days after an emergency resection showing a heterogeneous hypodense cystic-solid lesion in the right subphrenic space, without excluding the possibility of recurrence. CT=computed tomography.

Table 1
Reported cases of rhabdomyosarcoma in the liver through 2017.

| Authors | Number of cases | Age (years)/sex | Extent of occupy | Histological classification | Treatment | outcome |
|-----------------------------|-----------------|-----------------|--|-----------------------------|--|--|
| Miller et al (1956) | 1 | NA | NA | NA | Total right hepatic lobectomy | NA |
| Goldman et al (1969) | 1 | 65/Male | Autopsy: right lobe contained an ovoid tumor measured 35×15×10 cm | Embryonal/ alveolar | Symptomatic treatment without any surgery procedure or chemotherapy | Died 3 months from initial presentation of pain of right upper abdomen NA |
| Babut et al (1976) | 1 | NA | NA | NA | NA | NA |
| Watanabe et al (1983) | 1 | 70/Male | Autopsy: yellowish-brown multinodular tumors up to 5 cm in diameter at right lobe. cut surface was almost completely occupied by tumors without capsule | Pleomorphic | Symptomatic treatment without any surgery procedure or chemotherapy | Died 8months from the initial symptoms |
| Shibata et al (case 21,987) | 1 | 68/Male | Right lobe | Alveolar | NA | NA |
| Horowitz et al (1987) | 3 | 1.4/Male | Right and left lobe of liver | Embryonal | Biopsy followed by chemotherapy: cyclophosphamide IV and doxorubicin IV alternating with vincristine IV and dactinomycin IV weekly maintenance for a total of 12 months of treatment. | Died at 15 months from the date of diagnosis for the lung and brain involvement |
| | | 2.4/Male | Left lobe with diaphragm rupture | Embryonal | Left lobectomy followed by chemotherapy: cyclophosphamide IV and doxorubicin IV alternating with vincristine IV and dactinomycin IV weekly maintenance for a total of 18 months of treatment. And radiotherapy of 34 Gy in 24 fractions over 33 days. | Died at 76 months from the date of diagnosis |
| | | 7/Male | Left lobe extending into right lobe | Embryonal | Biopsy followed by chemotherapy: (a) Doxorubicin with decarbazine daily on days 1–5. (b) cyclophosphamide IV or PO daily on days 1–5 then vincristine IV on day 6 with dactinomycin IV on day 6. every 3 weeks×3 followed by (b) every 3 week×3 for a total of 4 months. | Died at 15 months from the date of diagnosis due to abdomen involvement |
| McArdle et al (1989) | 1 | 53/Male | Large mass occupied all of the right lobe | Embryonal | Surgical resection | Died 3 months from initial presentation |
| Burrig et al (1994) | 1 | 69/Male | NA | Pleomorphic | NA | NA |
| Meyer et al (1996) | 2 | NA/Female | NA | Pleomorphic | Hemihepatectomy + adjuvant chemotherapy; hemihepatectomy | Still alive after operation for at least 15 or 9 years |
| Akasofu et al (1999) | 1 | 52/Male | Autopsy: 19×12×11 cm tumor occupied almost the entire right lobe, which was not encapsulated and had invaded the right adrenal gland, diaphragm, bilateral hepatic ducts, and inferior vena cava | NA | Symptomatic treatment without any surgery procedure or chemotherapy | Died 2.5 months from initial presentation for disseminated intravascular coagulation |
| Tutar et al (2007) | 1 | 6/Male | 8×6 cm cystic mass in the medial portion of the left liver lobe | Embryonal | Surgical resection | NA |
| Huang et al (2003) | 1 | 8/Male | Large solid tumor in the right lobe of the liver | Pleomorphic | Extended right hepatectomy | Died for tumor recurrence with massive internal hemorrhage |

| Authors | Number of cases | Age (years)/sex | Extent of occupy | Histological classification | Treatment | outcome |
|----------------------------|-----------------|-----------------|---|-----------------------------|---|--|
| Schoofs et al (2011) | 1 | 59/Female | NA | Alveolar | Primary surgical resection+ chemotherapy (doxorubicin/ifosfamide) | 2 months after resection surgery Initial good response to chemotherapy and stable disease at 12 months after diagnosis, died 31 months after the first presentation secondary to complicated abundant abdominal recurrent disease |
| Aassab et al (2012) | 1 | 25/Male | 136mm lesion in the right lobe of liver measuring | Embryonal | Biosy followed by chemotherapy: Doxorubicin (given on day 1 of a 21-day cycle), ifosfamide (given on days 1–3 of a 21-day cycle) and vincristine (given on days 1 and 8 of a 21-day cycle). Chemotherapy was repeated every 3 weeks for 3 cycles | Died after 3 months from completion of chemotherapy due to disease progression |
| Haider et al (2013) | 1 | 17/Male | 20×13cm mass arising from left lobe with few satellite lesions in right lobe, largest in segment V measuring 3cm and small left paravertebral lymph nodes at the level of renal hila | Embryonal | VAC chemotherapy×3 cycles followed by MAID chemotherapy×6 cycles followed by gemcitabine-paclitaxel chemotherapy | Died of rapid progression at 31 months from the date of diagnosis |
| Rajamahendran et al (2014) | 1 | 16/Male | 15×11×9cm mass lesion involving right lobe of liver involving segments 5–8 | Embryonal | Right hepatectomy followed by carboplatin and ifosfamide chemotherapy | Patient expired on 30th postoperative day due to acute respiratory distress |
| Awara et al (2016) | 1 | 67/Male | 14.5×12.3×9.1 cm lesion involving left hepatic lobe. Large component of lesion is seen bulging in left subhepatic space | Embryonal | Left hepatic lobectomy followed by adjuvant chemotherapy: 50 mg/m ² doxorubicin (day 1), 2.5 g/m ² ifosfamide (days 1–3), and 1.4 mg/m ² vincristine (days 1 and 8), 3 cycles were given at interval of 3 weeks | At 24 months of follow-up, patient is free from local recurrence and distant metastasis. |
| Present case report | 1 | 66/Female | Large mass which measured about 20 cm×15cm appears high pressure, adhering tightly with omentum majus, mesenterium, intestines at anterior board, adhering abdominal wall, diaphragm at the rear. Epinephelos brown fluid containing bile can be extracted from the mass. | Pleomorphic | Emergency laparotomy of hemostasis and right hepatic lobectomy without adjuvant chemotherapy | Died 3 months from surgery for malnutrition and multiple organ failure, within a great possibility of recurrence even metastasis. Total course was 4 months from the first admitted |

Gy= Gray, IV= intravenous, MAID= mesna, adriamycin, ifosfamide and dacarbazine, NA =not available, PO =peros, VAC= vinblastine, adriamycin, cisplatin.

found in postoperative CT, we suspected that there was a great possibility of recurrence, even with metastasis; however, no autopsy was performed to ascertain this.

3. Discussion

RMS is a rare malignancy. Age has been identified as an independent predictor of prognosis, with children < 1 year and > 10 years-of-age having lower rates of survival.^[19] Childhood RMS occurs with a predilection for the head, neck, and genitourinary tracks, while adult RMS arises predominantly in the extremities.^[20] Embryonal RMS is the most common subtype of RMS in younger age groups; alveolar RMS is the most common subtype over the age of 10 years, and pleomorphic RMS is a disease of the elderly.^[18,19] RMSs are uncommon in the liver; previously reported cases of liver RMS are summarized in Table 1. These cases showed that RMSs in the liver are highly malignant with a very poor prognosis, even after surgery and/or chemotherapy.

Pleomorphic RMS of the liver, as seen in the present case, is rare due to its presentation and the location of the neoplasms. Moreover, RMS of the liver usually manifests as a giant cystic or solid mass associated with rupture and hemorrhage, according to imaging examinations and/or intraoperative findings in previously reported cases.^[2-4,14-16] Our patient was initially diagnosed with and treated for a hepatic cyst that had ruptured and hemorrhaged, and was infected. This was verified by the patient's first surgical procedure and histopathology testing performed before RMS was confirmed at our hospital. The diagnosis of hepatic cyst with RMS was supported by the long history of a stable abdominal mass and the histopathology findings. It is possible that RMS of the liver could have a long incubation period before the appearance of sudden enlargement, necrosis, rupture, or other severe symptoms; however, this possibility has not yet been reported; thus, this case provides important information. A limitation in the management of this case was the fact that no adjuvant chemotherapy was administered for further treatment.

Childhood RMS is a distinct entity that differs from typical adult soft-tissue sarcomas in terms of its natural course and its higher sensitivity to chemo- and radiotherapy. More than 70% of children with localized RMS can be cured with multidisciplinary treatment protocols that include chemotherapy.^[21] Gross total resection with negative margins, chemotherapy, and radiotherapy are recommended by the Intergroup Rhabdomyosarcoma Study Group and, together, is the generally accepted treatment protocol for childhood RMS. Surgical resection and radiotherapy are used for the management of the primary tumor site, while chemotherapy is used to prevent metastasis. Chemotherapeutic drugs that have been used to treat patients with RMS of the liver include vincristine, actinomycin-D, cyclophosphamide doxorubicin, ifosfamide, etoposide, and topotecan.^[2,4,13,15,17]

RMSs in adults, especially those in the liver, are difficult to manage because of their rarity and the absence of a standard treatment protocol or guidelines. Standard treatments could be established, such as surgery, radiotherapy, and adjuvant chemotherapy with consideration given to the traditional treatment of childhood RMS. Surgery is a mainstay of treatment for pleomorphic RMS and has been correlated with an improved survival rate.^[22] Other studies have shown that the rate of response to chemotherapy in adults throughout the course of treatment is similar to that typically observed among children,

and when adults are treated aggressively by using the pediatric protocol, the prognosis can be similar to that in children.^[2,19] Some benefits resulting from adjuvant chemotherapy have been demonstrated in adults with soft-tissue sarcoma; however, the level of benefit has not been as high as that reported for children with RMS.^[23] We, therefore, suggest that adults and children with RMS should receive similar treatment, and that treatment protocols adopted from pediatric programs but tailored to adults could increase adults' chances of receiving appropriate and efficacious treatment.^[19]

4. Conclusions

RMS of the liver is a rare and highly malignant neoplasm with a poor prognosis, even after surgical and chemotherapy interventions, as is shown by the review of previously reported cases. However, we propose that early diagnosis, prompt and complete resection, and appropriate radiotherapy and chemotherapy are the keys to managing this disease and that these measures could prolong a patient's life. Similar measures have been successful in treating cases of RMS in children. In addition, from studying this rare case of RMS of the liver, we believe that this condition needs to be considered as a differential diagnosis when patients present with a ruptured hepatic mass. Moreover, appropriate preoperative imaging studies and percutaneous biopsy will be helpful for making this diagnosis. However, further studies are needed to develop the optimal treatment protocol for improving the prognosis of patients with this rare but deadly cancer.

Acknowledgments

We would like to thank the members of the Pathology and Radiology Departments of our hospital for their hard work. We would like to thank Editage (www.editage.com) for English language editing.

Author contributions

Conceptualization: Kang Yang.

Data curation: Jingyang Yin.

Formal analysis: Kang Yang.

Funding acquisition: Zuojin Liu.

Investigation: Jingyang Yin.

Project administration: Zuojin Liu.

Resources: Zuojin Liu, Kang Yang.

Software: Jingyang Yin.

Visualization: Jingyang Yin.

Writing – original draft: Jingyang Yin.

Writing – review & editing: Kang Yang.

References

- [1] Goldblum JR, Weiss SW, Folpe AL. *Enzinger and Weiss's Soft Tissue Tumors E-Book*. 2013;Elsevier Health Sciences,
- [2] Arora A, Jaiswal R, Anand N, et al. Primary embryonal rhabdomyosarcoma of the liver. *BMJ Case Rep* 2016;2016:bcr2016218292.
- [3] McArdle JP, Hawley I, Shevlan J, et al. Primary rhabdomyosarcoma of the adult liver. *Am J Surg Pathol* 1989;13:961–5.
- [4] Haider N, Nadim MS, Piracha MN. Primary embryonal rhabdomyosarcoma of the liver in a young male. *J Coll Physicians Surg Pak* 2013;23:750–1.
- [5] Goldman RL, Friedman NB. Rhabdomyosarcomahepatoma in an adult and embryonal hepatoma in a child. *Am J Clin Pathol* 1969;51:137–43.
- [6] Burring KF, Knauer S. Rhabdomyosarcoma of the liver in adulthood. Case report and review of the literature. *Pathologe* 1994;15:54–7.

- [7] Babut JM, Ferrand B, Bracq H, et al. [Liver rhabdomyosarcoma in children. Report of one case (author's transl)]. *Ann Chir* 1976;30:251–5.
- [8] Huang FC, Eng HL, Chen CL, et al. Primary pleomorphic rhabdomyosarcoma of the liver: a case report. *Hepatogastroenterology* 2003;50:73–6.
- [9] Meyer-Pannwitz U, Kummerfeldt K, Broelsch CE. Primary pleomorphic rhabdomyosarcoma of the liver. *Langenbecks Archiv Chirurgie* 1996;381:75–81.
- [10] Miller TR, Pack GT. Total right hepatic lobectomy for rhabdomyosarcoma. *AMA Arch Surg* 1956;73:1060–2.
- [11] Schoofs G, Braeye L, Vanheste R, et al. Hepatic rhabdomyosarcoma in an adult: a rare primary malignant liver tumor. Case report and literature review. *Acta Gastroenterol Belg* 2011;74:576–81.
- [12] Shibata T, Hayakawa K, Yamashita K, et al. Two cases of primary hepatic rhabdomyosarcoma in adults. *Rinsho hoshasen. Clin Radiogr* 1987;32:653–6.
- [13] Rajendran R. Embryonal rhabdomyosarcoma of liver in a 16 year old malerare case report. *HPB (Oxford, England)* 2015;17:96.
- [14] Watanabe A, Motoi M, Mizobuchi K, et al. An adult case with rhabdomyosarcoma of the liver. *Jpn J Med* 1983;22:240–4.
- [15] Horowitz ME. Hepatic undifferentiated (embryonal) sarcoma and rhabdomyosarcoma in children. Results of therapy. *Cancer* 1987;59:396–402.
- [16] Akasofu M, Kawahara E, Kaji K, et al. Sarcomatoid hepatocellular carcinoma showing rhabdomyoblastic differentiation in the adult cirrhotic liver. *Virchows Archiv* 1999;434:511–5.
- [17] Aassab R. Primary embryonal botryoid-type rhabdomyosarcoma of the liver in adult: case report and review of the literature Rhabdomyosarcome embryonnaire hépatique chez un adulte: à propos d'un cas et revue de littérature. *J Africain Cancer* 2012;4:124–6.
- [18] Tutar NU, Cevik B, Olgun I, et al. Primary embryonal botryoid-type rhabdomyosarcoma of the liver. *Eur J Radiol Extra* 2007;61:5–7.
- [19] Joshi D, Anderson JR, Paidas C, et al. Age is an independent prognostic factor in rhabdomyosarcoma: a report from the Soft Tissue Sarcoma Committee of the Children's Oncology Group. *Pediatr Blood Cancer* 2004;42:64–73.
- [20] Hawkins WG, Hoos A, Antonescu CR, et al. Clinicopathologic analysis of patients with adult rhabdomyosarcoma. *Cancer* 2001;91:794–803.
- [21] Pizzo PA, Poplack DG. Principles and Practice of Pediatric Oncology. Lippincott Williams & Wilkins 2015.
- [22] Ferrari A, Dileo P, Casanova M, et al. Rhabdomyosarcoma in adults. *Cancer* 2003;98:571–80.
- [23] Frustaci S, Gherlinzoni F, De Paoli A, et al. Adjuvant chemotherapy for adult soft tissue sarcomas of the extremities and girdles: results of the Italian randomized cooperative trial. *J Clin Oncol* 2001;19:1238–47.