



## Case Report

# Sporadic desmoid fibromatosis of the neck after dorsal spondylosis of the cervical spine

Holger Schlag, Jonathan Neuhoff, Jens Castein, Chirstoph Hoffmann, Frank Kandziora

Centre for Spinal Surgery and Neurotraumatology, BG Unfallklinik Frankfurt am Main gGmbH, Germany.

E-mail: \*Holger Schlag - h.schlag@gmx.net; Jonathan Neuhoff - jonathan.neuhoff@bgu-frankfurt.de; Jens Castein - jens.castein@bgu-frankfurt.de; Chirstoph Hoffmann - christoph.hoffmann@bgu-frankfurt.de; Frank Kandziora - frank.kandziora@bgu-frankfurt.de



### \*Corresponding author:

Holger Schlag,  
Centre for Spinal Surgery  
and Neurotraumatology, BG  
Unfallklinik Frankfurt am Main  
gGmbH, Germany.

[h.schlag@gmx.net](mailto:h.schlag@gmx.net)

Received : 15 December 2021

Accepted : 12 January 2022

Published : 18 February 2022

### DOI

10.25259/SNI\_1240\_2021

### Quick Response Code:



## ABSTRACT

**Background:** Rare soft-tissue tumors, termed desmoid fibromatosis (DF), are comprised proliferated spindle cell fibroblasts and myofibroblasts embedded in a prominent collagenous stroma. They can occur either sporadically, due to prior trauma or surgery, or may have a genetic component. Clinically, DF has a high infiltrative growth/local recurrence rate, but does not metastasize.

**Case Description:** A 58-year-old male underwent a C5-C7 laminectomy/instrumented fusion. Two years later, he presented with a large gross swelling on the right side of the neck. The lesion was removed and proved to histologically consist of DF. Within the first postoperative 12 months, tumor did not recur.

**Conclusion:** Sporadic DF may follow trauma or prior surgery. Symptomatic tumors are treated by surgical *en bloc* resection (preferably R0). If lesions are inoperable, partially resected, or recur, different hormonal/chemotherapeutic systematic treatment options are available (e.g., tamoxifen or tyrosine kinase inhibitors). In the future, better molecular understanding of DF likely offers additional therapeutic approaches (e.g., immune checkpoint inhibitors).

**Keywords:** Desmoid fibrosis, Soft-tissue tumor, Spine surgery

## INTRODUCTION

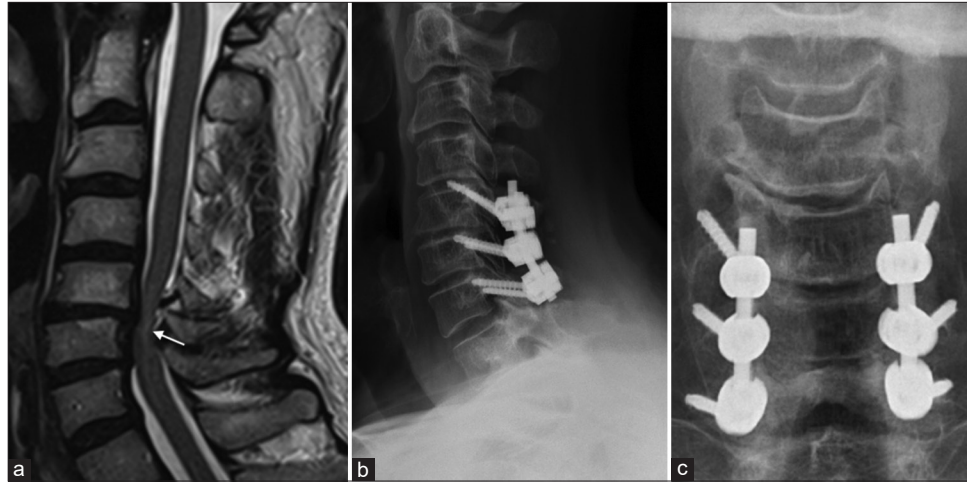
Desmoid fibromatosis (DF) (also known as desmoid-type fibromatosis) is defined by the World Health Organization as a rare type of soft-tissue tumor that occurs with a frequency of 3–4 cases/million per year. DF arises from fibroblasts/myofibroblasts of the muscle connective tissue, fascia, and aponeurosis and demonstrates infiltrative growth and a high local recurrence rate; however, they do not metastasize.<sup>[1,7]</sup> DF can be classified as extra-abdominal (trunk and limbs), located on the abdominal wall, or intra-abdominal. Sporadic DF often affects young adults between 35 and 40 years of age, with a clear female preponderance (i.e., during/after pregnancy or following trauma or surgery). Here, we present a 58-year-old male whose DF occurred 2 years after spine surgery.<sup>[7]</sup>

## CASE DESCRIPTION

A 58-year-old male underwent a C5-C7 laminectomy/rod-screw-instrumented fusion for multilevel spondylotic cervical myelopathy [Figure 1].

This is an open-access article distributed under the terms of the Creative Commons Attribution-Non Commercial-Share Alike 4.0 License, which allows others to remix, transform, and build upon the work non-commercially, as long as the author is credited and the new creations are licensed under the identical terms.

©2022 Published by Scientific Scholar on behalf of Surgical Neurology International



**Figure 1:** A sagittal T2-weighted magnetic resonance imaging (a) of cervical spondylotic myelopathy patient shows the change of spinal cord signal intensity (white arrow). Postoperative cervical spinal X-ray showing lateral (b) and anteroposterior (c) view after decompressive cervical laminectomy and C4-6 lateral mass fusion.

Two years postoperatively, the patient newly presented with a progressive right-sided painful swelling of the posterolateral neck; the lesion was fixed to the skin/deep neck structures. The MR revealed a  $5.2 \times 4.5 \times 3.7$  cm mass; the lesion on the T1 study was iso-hypointense, on the T2-weighted image showed slight hyperintensity, and inhomogeneous enhancement with contrast [Figure 2].

### Surgery for DF

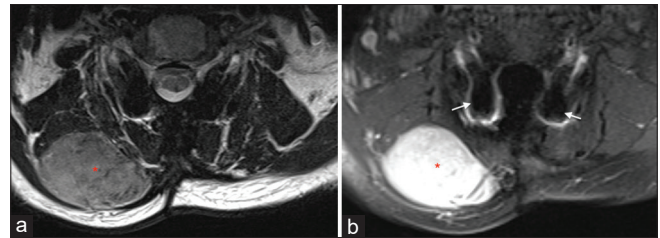
The patient underwent surgical *en bloc* resection of the mass that was located between the trapezius and splenius capitis muscles; it was well demarcated from the surrounding tissues. The 24 h postoperative MR confirmed complete tumor resection.

### Histology and Immunohistochemistry of DF

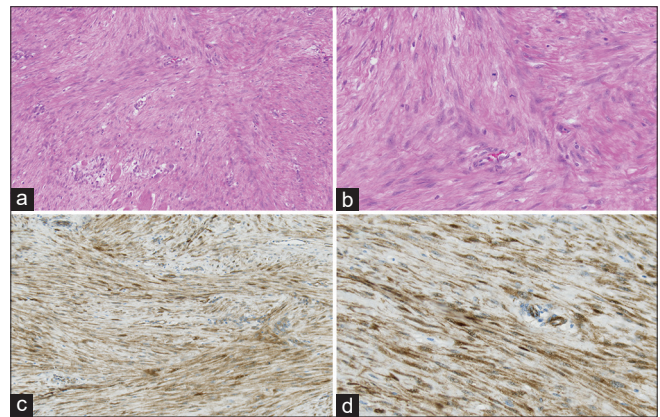
Histologically, the DF showed spindle cell fibroblast proliferation embedded in a collagenous stroma with rim infiltration of the skeletal muscle. Immunohistochemistry showed a cytoplasmic and nuclear expression of  $\beta$ -catenin [Figure 3]. Molecular pathology revealed a CTNNB1 mutation (c.121A>G; p.T41A) typical for DF. A second histological examination by a national reference center for soft-tissue tumors confirmed the diagnosis of a DF.

### Twelve-month postoperative course

At 6 months and 12 postoperative months, the patient was clinically asymptomatic. Further, the 12-month postoperative magnetic resonance imaging (MRI) showed no tumor recurrence [Figure 4].



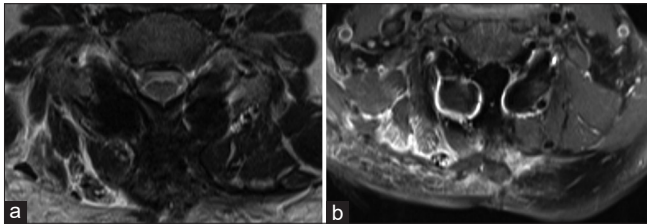
**Figure 2:** Axial T2-weighted (a) and contrast-enhanced axial T1-weighted (b) magnetic resonance imaging of the neck showing tumor mass (red asterisk) anatomically located between the trapezius muscle and the splenius capitis muscle. Metal-related artifacts in MRI (b) caused by lateral mass screws (white arrow).



**Figure 3:** (a) Histopathologic specimen demonstrating spindle cell fibroblast proliferates embedded in a collagenous stroma network with rim infiltration of skeletal muscle (H&E,  $\times 10$ ) and (b) nonatypical mitotic figures in desmoid fibromatosis (H&E,  $\times 20$ ). (c) ( $\times 10$ ) and (d) ( $\times 20$ ): cytoplasmic and nuclear expression of  $\beta$ -catenin, which is typical for desmoid fibromatosis.

**Table 1:** Postoperative development of desmoid tumor after previous spinal surgery (n=11).

References	Age/sex	Spinal pathology	Type of spinal surgery (index procedure)	Instrumentation	Period between index procedure and diagnosis of desmoid fibromatosis
Gonatas, 1961	45 F	Cervical disc	Cervical laminectomy	No	Not known
Wyler et al., 1973	39 F	Pain	C8-T2 dorsal rhizotomy	No	1 year
Maurer et al., 1996	18 F	L1 fracture	Open reduction and internal fixation	Yes	1 year
Lynch et al., 1999	49 F	Meningioma	Thoracic laminectomy T9-11	No	6 months
Guzey et al., 2006	50 F	Spondylolisthesis	Lumbar fixation	Yes	14 months
Sonmez et al., 2011	55 F	Schwannoma	T10-L1 laminectomy	No	6 months
Sevak et al., 2012	48 F	Schwannoma	Cervicothoracic laminectomy	Yes	2 years
Puvanesarajah et al., 2013	57 F	Vertebral hemangioma	Transpedicular approach, corpectomy T4	Yes	10 months
Rispoli et al., 2015	57 F	Neurinoma	Thoracic laminectomy T2-T3	No	2 years
Bohl et al., 2019	56 F	Scoliosis	T4-pelvis spinal fixation	Yes	2 years
Mujtaba et al., 2020	42 F	Meningioma (WHO I)	Thoracic laminectomy T1-T2	No	6 years



**Figure 4:** Axial T2-weighted (a) and contrast-enhanced axial T1-weighted (b) magnetic resonance imaging of the neck showed no evidence of tumor recurrence (12 months follow-up).

## DISCUSSION

The occurrence of DF after spinal surgery has been reported sporadically and typically ranges from 10 months to 7 postoperative years<sup>[2,5,6,9-16]</sup> [Table 1]. In our case, a DF developed 23 months after dorsal surgery of the cervical spine. MRI is the study of choice to assess the size, location, and type of soft-tissue mass consistent with DF low signal intensity in T2-weighted series and moderate contrast uptake is typical for fibrotic and collagenous tumor parts. However, MRI signal patterns can change during the course of the disease.<sup>[4]</sup> The histopathological examination of DF, obtained either by surgery or needle biopsy, typically shows proliferated spindle cell fibroblasts and myofibroblasts embedded in a prominent collagenous stroma and vascular network. Further, additional immunohistochemical and molecular pathological tests are crucial for diagnostic accuracy. A locally displacing growth can lead to different symptoms by compression of the surrounding tissue. For technical, functional, or cosmetic reasons, this surgical goal (R0) is sometimes not achievable and an R1 resection is then acceptable. The evidence of adjuvant radiotherapy after R1 resection is low and can only be recommended with limitations.<sup>[3]</sup> Recurrent lesions may be surgically excised, although an alternative is radiotherapy

(i.e., dose of 56 Gy distributed over 28 daily single doses a 2 Gy leads to local growth control in inoperable tumors).<sup>[8]</sup> Systemic therapy options should be used in particular if there is aggressive tumor growth which cannot be treated by surgery due to its anatomical location or if early recurrence of tumor growth occurs after surgery.<sup>[3]</sup> There are also chemotherapeutic and immunotherapeutic options for treating DF. Nevertheless, there is no standardized protocol for treating DF. Therefore, their diagnosis/treatment must be carefully assessed on a case-by-case basis.

## CONCLUSION

Here, we presented a 58-year-old male who, 2 years following a C5-C7 laminectomy/fusion, presented with a right posterolateral neck mass that was diagnosed as a DF. Following gross total *en bloc* excision, the lesion did not recur within 12 postoperative months.

### Declaration of patient consent

Patient's consent not required as patients identity is not disclosed or compromised.

### Financial support and sponsorship

Nil.

### Conflicts of interest

There are no conflicts of interest.

## REFERENCES

1. Bauer BM, Williams NL, Zuckerman LM. Development of multifocal extra-abdominal desmoid fibromatosis after

- surgical resection. *Clin Case Rep* 2019;7:2515-9.
2. Bohl MA, Leveque JC, Bayles S, Sethi R. Postoperative development of desmoid tumor after surgical correction of adult spinal deformity: Case report and review of literature. *World Neurosurg* 2019;128:4-10.
  3. Desmoid Tumor Working G. The management of desmoid tumours: A joint global consensus-based guideline approach for adult and paediatric patients. *Eur J Cancer* 2020;127:96-107.
  4. Dinauer PA, Brixey CJ, Moncur JT, Fanburg-Smith JC, Murphey MD. Pathologic and MR imaging features of benign fibrous soft-tissue tumors in adults. *Radiographics* 2007;27:173-87.
  5. Gonatas NK. Extra-abdominal desmoid tumors. Report of six cases. *Arch Pathol* 1961;71:214-21.
  6. Guzey FK, Emel E, Bas NS, Ozkan N, Turgut H, Sel B. Aggressive postoperative lumbar fibromatosis after the placement of instrumentation for treatment of spondylolisthesis. Case report. *J Neurosurg Spine* 2006;4:338-41.
  7. Kasper B, Baumgarten C, Bonvalot S, Haas R, Haller F, Hohenberger P, *et al.* Management of sporadic desmoid-type fibromatosis: A European consensus approach based on patients' and professionals' expertise-a sarcoma patients EuroNet and European organisation for research and treatment of cancer/soft tissue and bone sarcoma group initiative. *Eur J Cancer* 2015;51:127-36.
  8. Keus RB, Nout RA, Blay JY, de Jong JM, Hennig I, Saran F, *et al.* Results of a phase II pilot study of moderate dose radiotherapy for inoperable desmoid-type fibromatosis-an EORTC STBSG and ROG study (EORTC 62991-22998). *Ann Oncol* 2013;24:2672-6.
  9. Lynch JJ, Parvizi J, Scheithauer BW, Krauss WE. Development of postoperative fibromatosis after resection of an intraspinal meningioma. Case report. *J Neurosurg* 1999;90 Suppl 1:121-4.
  10. Maurer F, Horst F, Pfannenberger C, Wehrmann M. Multifocal extra-abdominal desmoid tumor-diagnostic and therapeutic problems. *Arch Orthop Trauma Surg* 1996;115:359-62.
  11. Mujtaba B, Call C, Rowland F, Spear RP, Amini B, Valenzuela R, *et al.* Desmoid fibromatosis following surgical resection of spinal meningioma. *Radiol Case Rep* 2020;15:697-701.
  12. Puvanesarajah V, Lina IA, Liauw JA, Hsu W, Burger PC, Witham TF. Desmoid tumor formation following posterior spinal instrumentation placement. *Evid Based Spine Care J* 2013;4:137-42.
  13. Rispoli R, di Chirico A, Tinella E, Peciarolo A, Ascani S, Caputo N, *et al.* Desmoid tumor following dorsal laminectomy: Case report. *Clin Case Rep Rev* 2016;1:251-2.
  14. Sevak S, Blount AL, Cottingham S, DeLano M, Woude DL, Stevenson J, *et al.* Fibromatosis of the cervical region following laminectomy: A case report and literature review. *Spine (Phila Pa 1976)* 2012;37:E456-9.
  15. Sonmez E, Altinors N, Gulsen S, Ozen O. Extraabdominal desmoid tumor appearing following resection of thoracolumbar schwannoma. *Turk Neurosurg* 2011;21:246-8.
  16. Wyler AR, Harris AB. Recurrent desmoid tumor following cervical laminectomy. Case report. *J Neurosurg* 1973;39:114-6.

**How to cite this article:** Schlag H, Neuhoff J, Castein J, Hoffmann C, Kandziora F. Sporadic desmoid fibromatosis of the neck after dorsal spondylodesis of the cervical spine. *Surg Neurol Int* 2022;13:64.