



Myxoma of urinary bladder (case report)

Mohammad Abdelfattah Alserhan^a, Omar Yaseen alshkaibi^{a,b}, Laith faisal Khasawneh^a,
Firas azar khori^a, Jamal Mohammad rahaymeh^c, Ashraf sulieman Almajali^{a,*}

^a The Prince Hussein Urology Institute (PHUI), The King Hussein Medical Centre, (KHMC), Amman, Jordan

^b Prince Eman Laboratory Institute (PELI), The King Hussein Medical Centre, (KHMC), Amman, Jordan

^c Anesthesia Department (AD), The King Hussein Medical Centre, (KHMC), Amman, Jordan

ARTICLE INFO

Keywords:

Myxoma
Urine bladder
Benign tumors
Malignant

ABSTRACT

Bladder myxoma is a very rare tumor that happens in a benign manner. The mesenchymal origin is typically the supply of these tumors. This tumor is usually diagnosed by the excisional biopsy due to the difficulty of diagnosis preoperatively as different bladder tumors' types.

During this paper, we tend to represent a case report of this terribly rare mesenchymal growth within the urinary bladder which is an unusual location for myxoma tumors to occur.

A 48-year-old feminine was hospitalized because of obscure abdominal pain. The patient underwent partial cystectomy, and the histopathology reported the presence of myxoma of urinary bladder.

Introduction

Most of the tumors arising within urinary bladder are of epithelial origin, the non-epithelial tumors account for about 5% of urinary bladder tumors.¹

Myxoma is a soft tissue tumor characterized by the presence of a dense extracellular myxoid matrix. It is usually occurring in variable locations and they are not of the aggressive type, they affect the skeletal and cardiac muscles.²

Most of these tumors arise silently of the urinary bladder until they grow to a large size before they produce obstructive symptoms and sometimes misdiagnosed as malignant tumors.

Complete Excision of the tumor is necessary to rule out any malignant features.

These tumors have a low incidence of local recurrence, usually present as a single mass, and are more common in females.³

Case presentation

A 48-year-old female previously healthy and no previous surgical operations with a family history of chronic diseases like hypertension and diabetes mellitus in her father and mother. The patient presented to the general surgery clinic complaining of vague abdominal pain, with symptoms of frequency in urination, urgency with no history of hematuria. By exam; there was a localized lower abdominal tenderness

without other significant findings. Then patient underwent an abdomen CT scan and pelvic MRI (Fig. 1) and was diagnosed to possess pelvic mass attached to the bladder as was revealed by the images. Later on, the patient was referred to a urology clinic to rule out bladder origin, cystoscopy was performed, which revealed the presence of a bulge at the right post lateral aspect of the urinary bladder with no intraluminal masses with normal-appearing mucosa, the patient underwent partial cystectomy with excision of the mass and patient discharged 2 days after operation and therefore the pathological features of the mass were benign intramuscular myxoma with cystic degeneration, the mass size was 7 × 5*4,5 cm, and on gross examination of the mass, it had been solid with no evidence of hemorrhage or necrosis, on sectioning it contains yellow gelatinous material. On histological examination there is no evidence of any malignant features like atypia, also it doesn't contain blood vessels which is a crucial feature of angiomyxoma. Fig. 2.

Patient was followed for one year in our urology clinic by 2, 4, and 6 weeks intervals then every 3 months till the end of one year follow-up. Methods of follow-up are taking history and physical examination, urine analysis and culture, urine bladder ultrasonography, and flexible cystoscopy in the clinic without any indication for urine bladder CT since ultrasonography and cystoscopy are enough.

Discussion

Although myxoma commonly occurs in skeletal and cardiac muscles

* Corresponding author. The Prince Hussein Urology Institute (PHUI), The Royal Medical Services, Amman, Jordan.

E-mail address: almajaliashraf@yahoo.com (A. Almajali).

<https://doi.org/10.1016/j.eucr.2021.101765>

Received 1 June 2021; Received in revised form 28 June 2021; Accepted 30 June 2021

Available online 6 July 2021

2214-4420/© 2021 The Author(s).

Published by Elsevier Inc.

This is an open access article under the CC BY-NC-ND license

(<http://creativecommons.org/licenses/by-nc-nd/4.0/>).

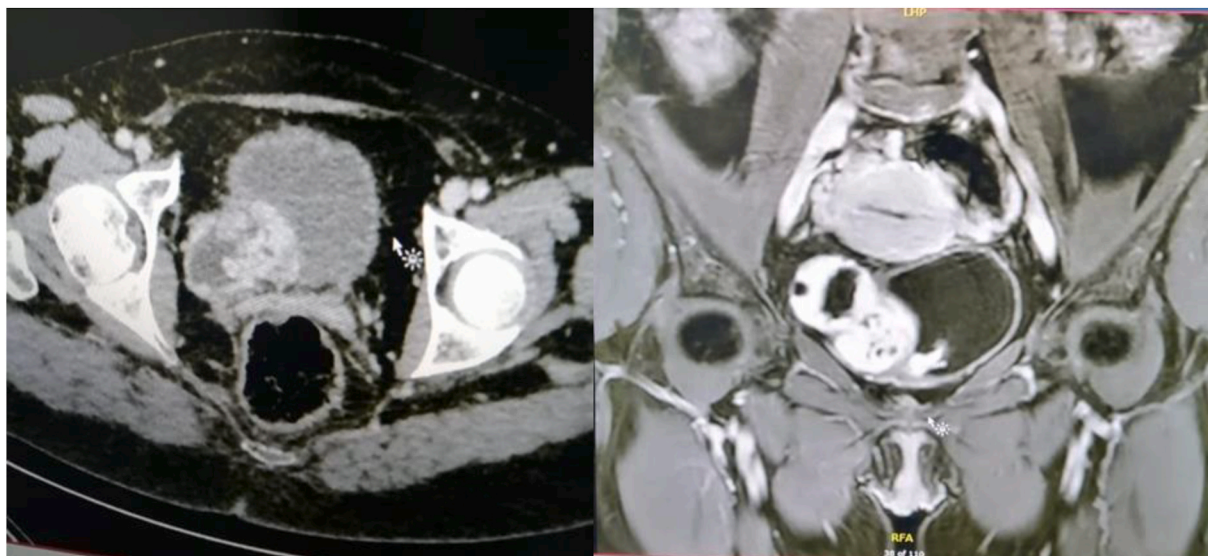


Fig. 1. Abdominal CT and pelvic MRI of the patient.

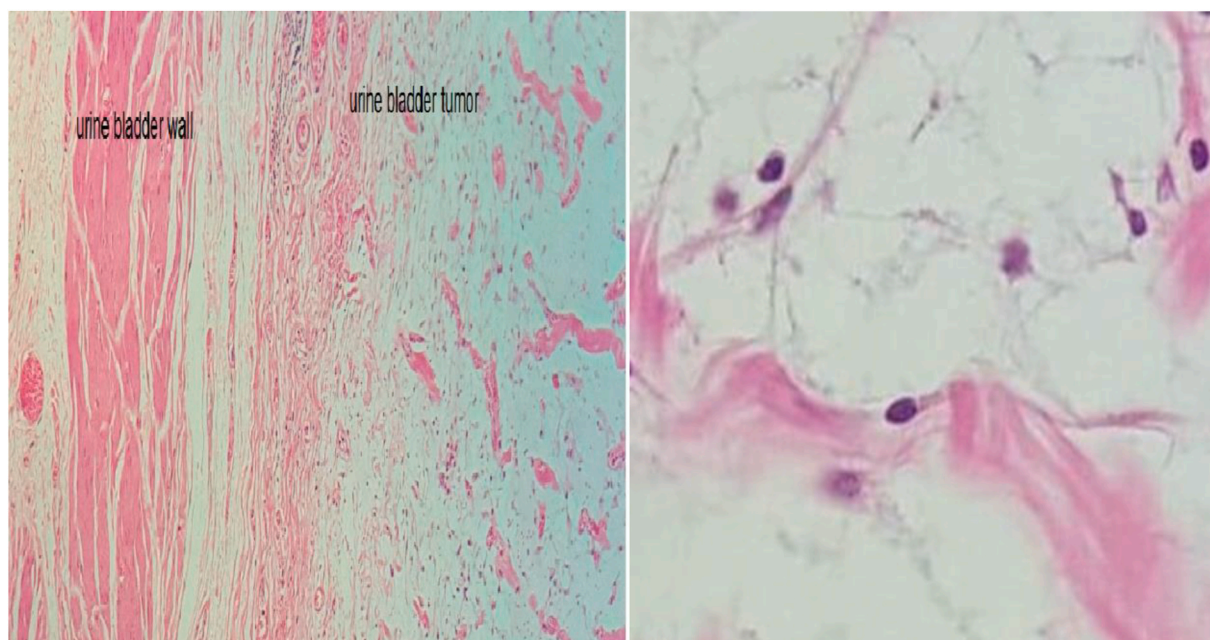


Fig. 2. Histopathologic images of the tumor.

(50% of benign cardiac tumors are represented by myxoma, 75% of cases of cardiac myxoma occurs in left atrium, followed by the right atrium (18%), the right and left ventricles (3% in each), and the valves (1%). Multiple myxoma represents 5% of the cases, half of which are of bilateral origin, on the other hand, the recurrence rate of skeletal myxoma is exceptional while in cardiac myxoma is rare and observed in 3% of patient due to inadequate resection or malignant change, and many recurrences are at a different site and multifocal disease occurs frequently in the familial setting),⁴ rarely occur in the genitalia like paratesticular region,² the genitourinary tract is an unusual location for this tumor; only one case had been reported in the literature which was missed diagnosed for sacro-sciatic hernia and the treatment was unsuccessful by herniorrhaphy on the contrary of our case in which the diagnosis was in a good time such as the correct treatment.³ Many cases have been reported in the kidney; whereas, nephrectomy has been reported due to suspicion to malignancy, in the follow up of the patients

there had been no sign of malignancy, such as metastasis and recurrence.⁵

Conclusion

Although myxoma commonly occurs in skeletal and cardiac muscle, the genitourinary tract is an unusual location for this tumor; only one case had been reported in the literature, many cases have been reported in the kidney.

It's important to distinguish this benign myxoma tumor from other malignant lesions which sometimes have myxoid features.

Funding

This research did not receive any specific grant from funding agencies in the public, commercial, or not-for-profit sectors.

Declaration of competing interest

The authors declare any conflict of interest.

Acknowledgements

Thanks to Ahmad Mahmood Alhiari MD who provided language help to the manuscript, and to Abdullah Mohammed rababaah MD who provided writing assistance during this manuscript.

References

1. Wong-You-Cheong JJ, Woodward PJ, Manning MA, Sesterhenn IA. From the Archives of the AFIP: neoplasms of the urinary bladder: radiologic-pathologic correlation.

- Radiographics*. 2006 Mar-Apr;26(2):553–580, 10.1148/rg.262055172. PMID: 16549617.
2. Yoshimura K, Inoue H, Koide T, Ohnishi S. Paratesticular myxoma. *Urol Int*. 1994;52(4):231–232, 10.1159/000282617. PMID: 8030175.
 3. Ball CB. Case of myxoma of the bladder. *Trans RAM Ireland*. 1896;14:320. <https://doi.org/10.1007/BF03170698>.
 4. Aiello VD, de Campos FP. Cardiac myxoma. *Autops Case Rep*. 2016;6(2):5–7. <https://doi.org/10.4322/acr.2016.030>. . Published 2016 Jun 30.
 5. Aidaoud N, Hallak A, Rousan LA, Halalsheh O, Darayseh B, Al-Abbadi MA. Myxoma of the renal pelvis masquerading pelviureteric stenosis: conservative limited resection with renal preservation: case presentation and literature review. *BMC Urol*. 2020 Jun 30;20(1):80, 10.1186/s12894-020-00657-8. PMID: 32605652; PMCID: PMC7324961.