

Polymicrogyria and Congenital Parvovirus B19 Infection

Grant S. Schulert, M.D., Ph.D.,¹ William F. Walsh, M.D.,^{1,2}
and Jörn-Hendrik Weitkamp, M.D.^{1,2}

ABSTRACT

Fetal parvovirus B19 infection causes anemia, hydrops, and pregnancy loss but is generally not considered teratogenic. Nevertheless, disturbances of neuronal migration have been described with congenital parvovirus infection. We evaluated a term infant with congenital parvovirus disease and polymicrogyria. We compared this case with four other reports of central nervous system disease after birth to parvovirus-infected mothers. After an extensive diagnostic evaluation, this infant was found to have congenital parvovirus disease with severe anemia and nonimmune hydrops as well as extensive polymicrogyria. Although rare, this report and literature review suggest that parvovirus B19 has the potential to disrupt normal neurodevelopment. We suggest that infants with severe congenital parvovirus infection have close developmental surveillance and if symptomatic undergo neuroimaging to assess for disorders of neuromigration.

KEYWORDS: Parvovirus, polymicrogyria, teratogen, congenital infection

Parvovirus B19 is a small DNA virus of the Parvoviridae family. The most common presentation of parvovirus B19 infection is erythema infectiosum, or fifth disease, characterized by a prodromal phase of fever and flulike symptoms followed by a cutaneous eruption several days later. Parvovirus also has a specific tropism for erythroid precursor cells, causing temporary suppression of erythropoiesis in most patients and triggering aplastic crisis in a subset.¹ Infection is a particular concern in pregnant women. Although most infections during pregnancy have no adverse fetal effects, one study reported a fetal death rate of 6.3% in women with confirmed parvovirus infection before 20 weeks' gestation.² This is likely due in large part to arrest of red cell production leading to severe anemia, congestive heart failure, and nonimmune hydrops (reviewed by Kumar and Abughali³). Parvovirus B19 is generally not consid-

ered teratogenic, although ocular anomalies, cleft lip/palate, musculoskeletal anomalies, hepatocellular damage, myocarditis, congenital cardiomyopathy, and myositis have been described in newborns with congenital parvovirus infection.^{1,3} In addition, disturbance of cerebral neuronal migration has recently been stated with congenital parvovirus infection; however, postnatal B19-specific DNA and immunoglobulin (Ig) M antibodies were negative.⁴ Here we report the case of a neonate with markedly abnormal central nervous system (CNS) findings including extensive polymicrogyria following DNA-confirmed perinatal parvovirus B19 infection.

CASE REPORT

This patient was born at 39 weeks' gestation to a 44-year-old, gravida 3 mother with two healthy living

¹Department of Pediatrics; ²Division of Neonatology, Monroe Carell Jr. Children's Hospital at Vanderbilt, Nashville, Tennessee.

Address for correspondence and reprint requests: Jörn-Hendrik Weitkamp, M.D., 2215 B Garland Ave, 1125 MRB IV/Light Hall, Nashville, TN 37232-0656 (e-mail: hendrik.weitkamp@vanderbilt.edu).

Am J Perinatol Rep 2011;1:105-110. Copyright © 2011 by

Thieme Medical Publishers, Inc., 333 Seventh Avenue, New York, NY 10001, USA. Tel: +1 (212) 584-4662.

Received: April 21, 2011. Accepted after revision: June 20, 2011. Published online: August 2, 2011.

DOI: <http://dx.doi.org/10.1055/s-0031-1285984>.

ISSN 2157-6998.

children. Her pregnancy was complicated by advanced maternal age and in vitro fertilization with donor oocyte. She developed preterm labor at 22 weeks' gestation. A cerclage was placed and she received indomethacin for tocolysis up to 32 weeks' gestation. Prenatal ultrasounds were reportedly normal until 39 weeks when enlarged cerebral ventricles and enlarged heart chambers were noted. A nonstress test showed late fetal heart rate decelerations and lack of variability, and a male infant was delivered via caesarean section for nonreassuring fetal status. Polyhydramnios was noted upon artificial rupture of membranes at delivery. The Apgar scores were 8 at 1 minute and 8 at 5 minutes. A complete blood count was notable for an hemoglobin of 4.0 g/dL and a hematocrit of 12%. Findings on initial physical exam included marked pallor, scalp edema, tachypnea, a two-vessel cord, bilateral hydroceles and a 3/6 systolic heart murmur that radiated to the axilla with strong pulses and normal distal perfusion.

A comprehensive diagnostic evaluation was performed and is listed in Table 1. Of note, serology for parvovirus B19 showed a positive IgG but a negative IgM; however, polymerase chain reaction (PCR) detection in the infant's blood for parvovirus B19 DNA was positive.

On the second postnatal day, the infant had several abnormal movements suggestive of seizures. An electroencephalogram was obtained that showed no seizure activity but generalized cerebral dysfunction. Cranial ultrasound showed mild dilatation of the lateral and third ventricles, and brain magnetic resonance imaging (MRI) showed extensive polymicrogyria on the right, involving the cortex of the frontal, temporal, and parietal lobes (Fig. 1). The process affected most of

the right convexity, as well as the parasagittal frontal cortex. On the left, there was mild polymicrogyria in the insula.

The patient required several packed red blood cell transfusions but was discharged to home in ambient air on the 20th postnatal day. Since discharge, the patient has continued to have anemia as well as periods of neutropenia and has required multiple outpatient transfusions. He underwent bone marrow biopsy, which showed a normocellular marrow with trilineage hematopoiesis, consistent with congenital parvovirus infection. Neurodevelopmentally, he has had episodes of staring and decreased responsiveness and was started on anticonvulsant therapy to prevent seizures.

DISCUSSION

This report suggests that parvovirus B19 has the potential to disrupt normal neurodevelopment. Parvovirus is a significant pathogen affecting pregnant women, as up to 10% of women with documented infection have fetal loss. It is generally thought that most perinatal mortality is due to transient suppression of erythropoiesis leading to severe anemia and hydrops. Although malformations have been associated with congenital parvovirus infection, it is controversial whether parvovirus has teratogenic effects. Here, we report a term infant with clinically overt parvovirus B19 infection and extensive polymicrogyria. This patient had high IgG titers for parvovirus but was negative for IgM; however, parvovirus IgM typically remains positive for only 2 to 4 months after infection.⁴ In this case, the mother of the infant did not have a known parvovirus exposure, but reported pregnancy complications 4 months prior to delivery.

Table 1 Diagnostic Evaluation

Evaluation	Result
Chest radiograph	Cardiomegaly, small bilateral pleural effusions
Abdominal ultrasound	Small volume ascites
Echocardiogram	3 small muscular VSDs, small to moderate PDA
Direct antiglobulin test	Negative
Reticulocyte count	0.8%
Flow cytometry for fetal cells in maternal blood	Fetal cells < 0.04%
Karyotype	46XY
FISH for 22q11 microdeletion	Negative
Noonan's syndrome gene sequencing	Normal
High-resolution chromosomal microarray	Two small deletions of unknown clinical significance
Rubella IgM and IgG	IgM negative, IgG positive
CMV IgM and IgG	IgM negative, IgG negative
CMV viral culture	No growth
LCMV IgM and IgG	IgM negative, IgG positive
Toxoplasma IgM and IgG	IgM negative, IgG positive
Parvovirus	IgM negative, IgG positive, PCR positive

CMV, cytomegalovirus; FISH, fluorescence in situ hybridization; IG, immunoglobulin; LCMV, lymphocytic choriomeningitis virus; PCR, polymerase chain reaction; PDA, patent ductus arteriosus; VSD, ventricular septal defect.

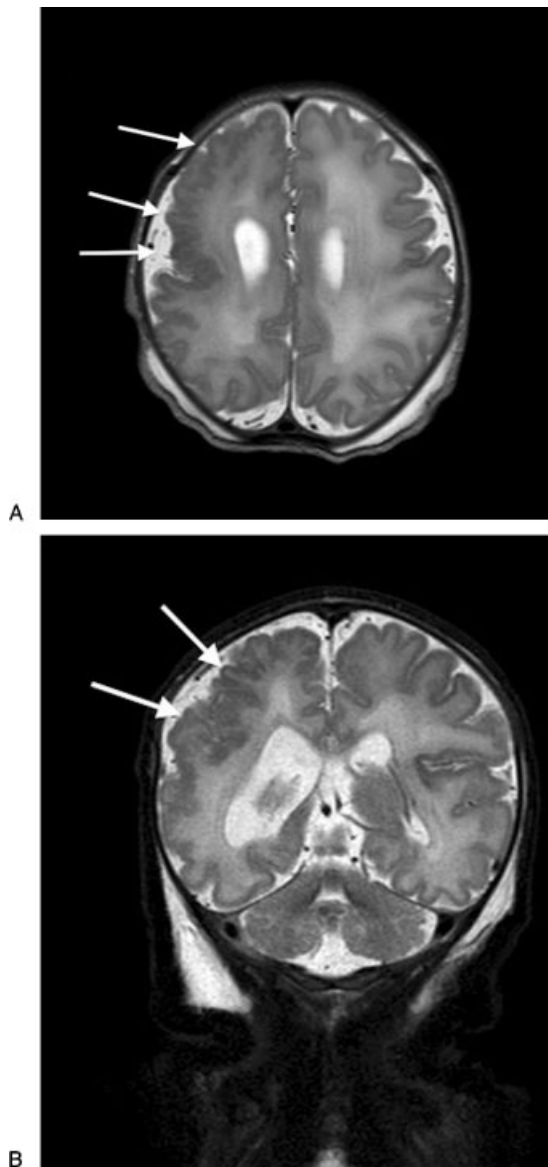


Figure 1 Patient brain magnetic resonance imaging (MRI). Axial (A) and coronal (B) T2-weighted postnatal MRI images of patient's brain demonstrating extensive polymicrogyria involving right frontal, temporal, and parietal lobes.

Therefore, a negative parvovirus IgM test in the infant after delivery was expected. In contrast to IgM, parvovirus PCR is highly sensitive and can detect virus for at least 6 months after infection.

Polymicrogyria is a malformation of cortical development, resulting from abnormalities during late neuronal migration or early cortical organization between 3 and 5 months' gestation.^{5,6} Although there is clinical and radiographic heterogeneity in patients classified as having polymicrogyria, more than half have global developmental delay and develop epilepsy.⁶ Polymicrogyria has been described secondary to ischemic insults and congenital infections, particularly human cytomegalovirus (CMV). This infant tested negative

for CMV. Polymicrogyria is associated with chromosomal deletions involving the X-chromosome and Di-George syndrome and is mapped to several genes involved in neuronal migration. None of those genes were included in the small deletions identified in the patient, nor were any other genes associated with CNS abnormalities.

Uncertainty remains regarding the timing of infection. The infant had profound anemia and a low reticulocyte count at birth (0.8%). One would expect discontinuation of viral replication in erythroid progenitor cells after appearance of parvovirus IgG antibodies and therefore bone marrow recovery and appearance of reticulocytes. Therefore, this infant may have had peripartum parvovirus infection plus unrelated polymicrogyria. Alternatively, parvovirus infection may have occurred earlier in intrauterine life with an effect on the brain followed by bone marrow suppression at birth from another cause. However, congenital red-cell aplasia and persistent anemia has been described after congenital B19 infection.⁷ In addition, this patient has recently been diagnosed with Diamond Blackfan anemia, a condition associated with parvovirus B19 infection.⁸

There is significant controversy in the literature as to whether parvovirus B19 is teratogenic. Rare case reports have described infants with intrauterine parvovirus infection that have neurological anomalies (Table 2). These infants had features of parvovirus disease including anemia and nonimmune hydrops; CNS findings were generally made upon autopsy. Where a known maternal parvovirus infection was identified, it was in the second trimester. Notably, several of these patients had ventricular enlargement, which was also found in the patient described here. We are aware of only one other report of B19-associated polymicrogyria; however, neither virus-specific IgM nor DNA was detected in the infant postnatally.⁴ Antenatal MRI demonstrated dilation of the left lateral ventricle at 22 weeks' gestation, and follow-up MRI after birth showed marked left frontal polymicrogyria, very similar to the patient described here.

The overall risk of congenital anomalies in neonates with intrauterine parvovirus infection is low. One large study of pregnant women with parvovirus infection found that only one of the surviving infants had a congenital anomaly.¹¹ Nevertheless, infants who suffer more severe infections may be at higher risk. Nagel et al examined 16 children treated with intrauterine transfusion for severe parvovirus infection and found that 32% had delayed psychomotor development ranging from mild to severe.¹² On the other hand, a similar study of patients who received prenatal transfusion found that all had neurodevelopmental scores within two standard deviations of the mean.¹³ However, neither of these studies reported neuroimaging findings.

Table 2 Reports of Infants with Congenital Parvovirus B19 Infection and Central Nervous System Abnormalities

Reference	Gestational Age at Birth (wk)	Gestational Age at Exposure (wk)	Clinical Findings	CNS Findings	Prenatal Diagnostics	Postnatal Diagnostics	Outcome
Katz et al (1996) ⁹	34	Unknown	Anemia, multisystem organ failure	Cortical dysplasia, architectural disruption of cerebral cortex, ventricular dilation	IgM + (fetal serum)	ND	Died
Katz et al (1996) ⁹	28	Unknown	Hydrops, multisystem organ failure, respiratory failure	Hydrocephalus, dilation of lateral and third ventricle	IgM + (maternal and fetal serum)	ND	Died
Isumi et al (1999) ¹⁰	27	15	Hydrops	Calcifications in cerebral cortex, multinucleated giant cells	IgM + (maternal serum), PCR + (amniotic fluid)	IgM -, IgG +	Died
Pistorius et al (2008) ⁴	41	16	Anemia, hydrops	Enlargement of left frontal horn, left frontal polymicrogyria	IgM + (maternal and fetal serum), PCR + (amniotic fluid)	IgM -, IgG +, PCR -	Survived
This report	39	Unknown	Anemia, hydrops, congenital heart disease	Dilation of the lateral and third ventricles, extensive polymicrogyria	ND	IgM -, IgG +, PCR +	Survived

CNS, central nervous system; Ig, immunoglobulin; ND, not done; PCR, polymerase chain reaction.

We are aware that the polymicrogyria in this patient may have resulted from other causes as listed in the extensive evaluation summarized in Table 1. The infant showed other, more subtle abnormalities such as three small muscular ventricular septal defects and a single-vessel cord. These may not be evident in low-resolution prenatal ultrasound screening, and hydrops may have developed closer to term. Although the mother developed preterm labor at 22 weeks and received prolonged indomethacin treatment for latency, no adverse effects on CNS development have been described in this relatively common scenario.¹⁴ Therefore, parvovirus infection is the most likely contributor in this case. It is possible that a combination of circumstances is required for the phenotype to occur, such as parvovirus B19 infection in a fetus with genetic risk factors at a critical time of CNS development. It is unknown whether parvovirus could cause a direct cytopathic effect on neuronal cells or if CNS injury would be secondary to complications of infection such as profound anemia, chronic hypoxia, or the inflammatory host response. A teratogenic effect is also supported by earlier animal studies suggesting that parvovirus infection in mice can lead to CNS malformations.¹⁵ Although larger studies suggest that the overall risk for congenital anomalies in patients with parvovirus infection is low, we speculate that the risk may be greater in patients with more profound infection who develop severe anemia and hydrops. Although CNS malformations appear to be a rare complication of congenital parvovirus B19 infection, it may be reasonable to suggest close developmental surveillance and neuroimaging in symptomatic children exposed to parvovirus in utero.

REFERENCES

1. Young NS, Brown KE. Parvovirus B19. *N Engl J Med* 2004; 350:586-597
2. Enders M, Weidner A, Zoellner I, Searle K, Enders G. Fetal morbidity and mortality after acute human parvovirus B19 infection in pregnancy: prospective evaluation of 1018 cases. *Prenat Diagn* 2004;24:513-518
3. Kumar ML, Abughali NF. Perinatal parvovirus B19 infection. *NeoReviews* 2005;6:32-37
4. Pistorius LR, Smal J, de Haan TR, et al. Disturbance of cerebral neuronal migration following congenital parvovirus B19 infection. *Fetal Diagn Ther* 2008;24:491-494
5. Guerrini R, Parrini E. Neuronal migration disorders. *Neurobiol Dis* 2010;38:154-166
6. Leventer RJ, Jansen A, Pilz DT, et al. Clinical and imaging heterogeneity of polymicrogyria: a study of 328 patients. *Brain* 2010;133(Pt 5):1415-1427
7. Brown KE, Green SW, Antunez de Mayolo J, et al. Congenital anaemia after transplacental B19 parvovirus infection. *Lancet* 1994;343:895-896
8. Heegaard ED, Hasle H, Clausen N, Hornsleth A, Kerndrup GB. Parvovirus B19 infection and Diamond-Blackfan anaemia. *Acta Paediatr* 1996;85:299-302

9. Katz VL, McCoy MC, Kuller JA, Hansen WF. An association between fetal parvovirus B19 infection and fetal anomalies: a report of two cases. *Am J Perinatol* 1996;13:43-45
10. Isumi H, Nunoue T, Nishida A, Takashima S. Fetal brain infection with human parvovirus B19. *Pediatr Neurol* 1999; 21:661-663
11. Miller E, Fairley CK, Cohen BJ, Seng C. Immediate and long term outcome of human parvovirus B19 infection in pregnancy. *Br J Obstet Gynaecol* 1998;105:174-178
12. Nagel HTC, de Haan TR, Vandebussche FPHA, Oepkes D, Walther FJ. Long-term outcome after fetal transfusion for hydrops associated with parvovirus B19 infection. *Obstet Gynecol* 2007;109:42-47
13. Dembinski J, Haverkamp F, Maara H, Hansmann M, Eis-Hübinger AM, Bartmann P. Neurodevelopmental outcome after intrauterine red cell transfusion for parvovirus B19-induced fetal hydrops. *BJOG* 2002;109:1232-1234
14. Savage AH, Anderson BL, Simhan HN. The safety of prolonged indomethacin therapy. *Am J Perinatol* 2007;24: 207-213
15. Johnson RT. Viral infections and malformations of the nervous system. *Birth Defects Orig Artic Ser* 1971; 7:56-63