

# Lethal Subarachnoid and Intracerebral Haemorrhage Associated with Temporal Arteritis. A Case Report

Réka Gál<sup>1</sup>, Rodica Bălașa<sup>2</sup>, Zoltán Bajkó<sup>2</sup>, Smaranda Maier<sup>2</sup>, Iunius Simu<sup>3\*</sup>, Adrian Bălașa<sup>4</sup>

<sup>1</sup> Mureș County Clinical Emergency Hospital Târgu Mureș, Neurology Clinic II, Târgu Mureș, România

<sup>2</sup> University of Medicine and Pharmacy Târgu Mureș, Department of Neurology, Târgu Mureș, România

<sup>3</sup> University of Medicine and Pharmacy Târgu Mureș, Department of Radiology, Târgu Mureș, România

<sup>4</sup> University of Medicine and Pharmacy Târgu Mureș, Department of Neurosurgery, Târgu Mureș, România

## ABSTRACT

Giant cell arteritis is a systemic inflammatory vasculitis, typically involving the superficial temporal arteries, but with possible ischemic and hemorrhagic cerebrovascular complications.

The case is reported of a patient with a clinical picture of giant cell arteritis, who had multiple occupational exposures to various infectious agents.

His initial favourable progress was followed by an atypical outcome. Despite immunosuppressive treatment, he developed fatal subarachnoid and intracerebral haemorrhages, possibly due to rupture of a microaneurysm of the posterior cerebral artery.

**Keywords:** giant cell arteritis, subarachnoid haemorrhage

Received: 30 April 2017 / Accepted: 13 October 2017

## INTRODUCTION

Giant cell arteritis (GCA), also known as temporal arteritis or Horton disease, is a rare type of chronic inflammatory systemic vasculitis of unknown aetiology, involving medium and large-sized arteries. It typically involves the superficial temporal arteries, with an estimated annual incidence worldwide of 1/3,000-1/25,000 among adults over 50 years of age [1]. In elderly patients, a new-onset headache might suggest a diagnosis of GCA. Age and female sex are established risk factors, but infections and a genetic component may also play a role in the development of this disease. GCA manifests as granulomatous inflammation, predominantly involving the extracranial arteries, most commonly the occipital, proximal vertebral, ophthalmic and posterior ciliary arteries, but occasionally including the aorta and subclavian vessels, too [1, 2].

Possible complications of the disease, which are not well understood, include visual impairment, and severe

cerebrovascular events accompanied by a high mortality rate. Primary arteritis of the central nervous system (PACNS) may present clinically as GCA, generally with severe, progressive course of the disease [2]. Therapy usually leads to satisfactory resolution of the condition.

## CASE PRESENTATION

A 65-year-old retired veterinarian, previously in good health, was admitted to the Neurology Clinic I, Mureș County Clinical Emergency Hospital, Târgu Mureș, complaining of severe, right-sided periorbital and frontotemporal pulsating headache and severe visual impairment. The onset of symptoms was five months earlier. The headache included nocturnal exacerbations, and initially was accompanied by diplopia, and later by progressive bilateral visual impairment. This worsened over the course of one month, resulting in complete loss of vision in the right eye, and concomitant jaw claudication and odynophagia.

\* Correspondence to: Iunius Simu, University of Medicine and Pharmacy Târgu Mureș, Department of Radiology, Gheorghe Marinescu street 38, 540139, Târgu Mureș, România. E-mail: iuniuspaul.simu@gmail.com

He denied any use of vasoactive substances or other drugs. Musculoskeletal complaints or constitutional signs, such as significant weight loss, anorexia, chronic fatigue or night sweats were not present. Previously, in the first three months of the disease the patient had been treated in his territorial hospital with oral analgesics, metamizole sodium, 100mg, three times a day, and gabapentin, 300mg, twice daily and low-dose corticotherapy, intravenous dexamethasone, 8mg/day for seven days.

On admission he was alert, had a recorded temperature of 37.2°C, and was in a stable hemodynamic and respiratory state. Physical examination showed a tortuous course and tenderness of the right superficial temporal artery, with allodynia of the scalp. Neurological examination revealed right eye amaurosis and severe amblyopia of the left eye, with loss of direct and consensual pupillary reflexes of the right eye. There were no other neurological focal signs.

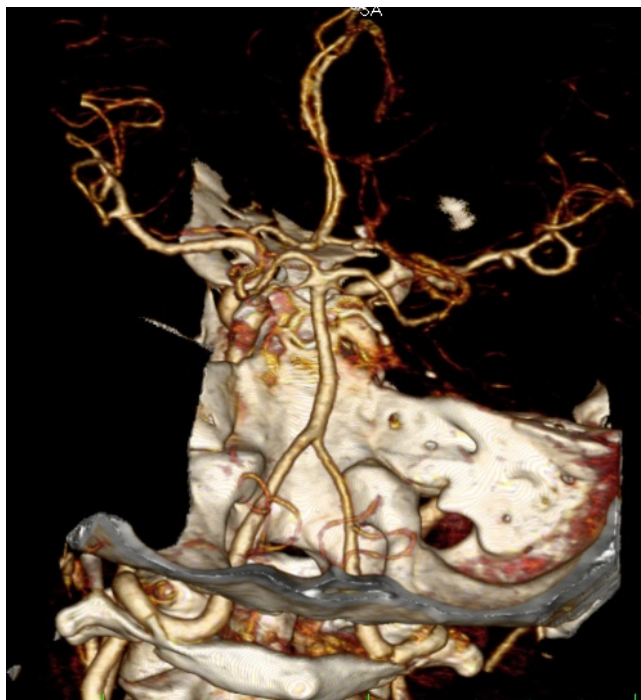
Laboratory tests showed a mildly increased erythrocyte sedimentation rate (ESR) of 46 mm/hour, a positive C-reactive protein-test, and a slight leukocytosis, with no elevated autoimmune markers such as cryoglobulins, circulating immune complexes, anti-double-stranded DNA, anticardiolipin antibodies and anti-neutrophil cytoplasmic antibodies.

Duplex sonography of the temporal, vertebral and carotid arteries and CT angiography of the extra- and intracranial vessels (Figure 1) did not reveal any abnormalities.

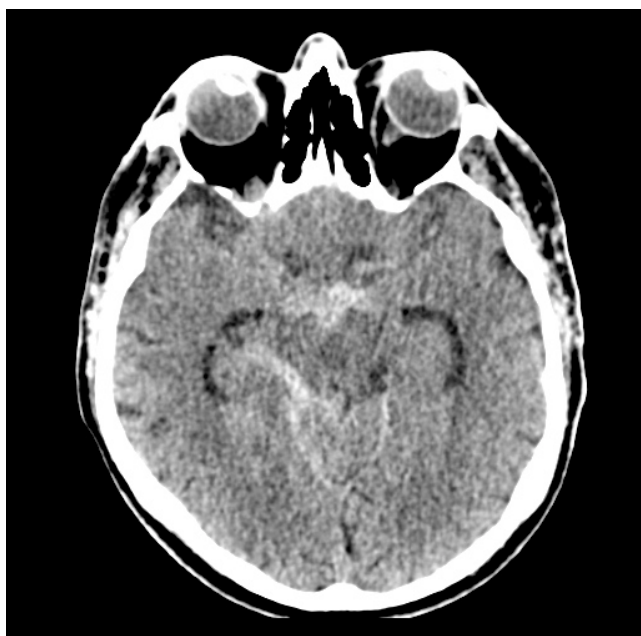Optical coherence tomography was performed, but primary ophthalmological diseases were ruled out. Magnetic resonance imaging of the brain was negative for any intracranial space occupying or vascular lesion. Routine cerebrospinal fluid tests and serological testing for infections including toxoplasmosis, brucellosis, syphilis, lyme borreliosis, toxocariasis, human immunodeficiency virus (HIV), hepatitis C and B virus, did not reveal any pathological changes.

Combined immunosuppressive therapy was initiated with intravenous corticosteroids, Methylprednisolone, 500mg daily for 16 days, initially, followed by progressive down-titration with oral prednisone, 60 mg daily, and oral azathioprine, 50 mg twice daily. Consequently, his diurnal headache stopped, the intensity of nocturnal hemicranias was reduced, and the ESR decreased to 16 mm/hour. The patient tolerated the steroid therapy, with no significant elevation of blood pressure, or other side effects.

After 16 days of treatment, the patient suddenly presented a transient alteration of consciousness, followed by left hemiparesis and anisocoria. A cranial CT-scan revealed a subarachnoid haemorrhage in the basal cisterns (Figure 2). A few hours later a second CT-scan showed extensive right sided intra- and ex-



**Fig. 1.** CT angiography of the intracranial vessels, with no visible aneurysmal dilatation of the basilar, vertebral and posterior cerebral arteries.



**Fig. 2.** Subarachnoid haemorrhage in the basal cisterns.

tra-axial bleeding, associated with secondary cerebellar and brainstem infarction (Figure 3). The patient's consciousness deteriorated rapidly, resulting in death within a few hours. The patient did not undergo a post-mortem examination on the request of his family.

The neurosurgeons' opinion was that most likely cause of the haemorrhages was the rupture of a microaneurysm of the posterior cerebral artery.

## ■ DISCUSSION

On admission, the patient presented with four out of the five diagnostic criteria for GCA: age over 50 years at the onset of the disease, new-onset headache, temporal artery tenderness and elevated ESR. Considering the clinical symptoms and the history of previous steroid therapy, temporal artery biopsy was postponed as the probability of a false-negative histological result was deemed to be high.

The most frequent clinical manifestations of GCA are the result of cranial ischemic phenomena, including severe unilateral or bilateral headaches which respond poorly to analgesics, tenderness of the scalp and the superficial temporal arteries, jaw claudication, dysphagia, diplopia and transient or permanent visual impairment [1]. Permanent loss of vision, secondary to ischemic optic neuropathy caused by retinal artery occlusion, is one of the most worrying complications of GCA. It may be reversible if an early diagnosis is made, but the risk of permanent blindness increases with any delay in diagnosis and treatment.

It is typical for GCA patients with visual ischemic complications to have lower biological inflammatory markers, making an early diagnosis more difficult. Risk factors for developing permanent visual loss include a history of amaurosis fugax, claudicative pains, cerebrovascular events and thrombocytosis. Non-specific constitutional signs and symptoms, and the presence of polymyalgia rheumatica have been associated with a reduced risk. The presence of visual impairment increases the risk of ischemic strokes and mortality in GCA patients [1, 2].

Ischemic or hemorrhagic cerebrovascular events along with progressive cognitive impairment, mood changes or seizures are considered unusual vascular complications of GCA. Cerebrovascular ischemic events occur in 3-4% of patients with GCA, due to a high-grade stenosis or occlusion of the extracranial vertebral and carotid arteries. As the arteries enter the dura mater, elastic fibres disappear from the media and adventitia, and their intradural portion has a very thin wall. Thickening of the elastic tissue in the wall of extracranial arteries explains the predominant involvement of these vessels. An autoimmune reaction against arterial elastic fibres may occur but without the involvement of the intracranial circulation [3, 4].

However, there are reports, when GCA is the first sign of cerebral vasculitis. When systemic vasculitis mimics classic GCA, temporal artery involvement is usually associated with extracranial visceral clinical features and increased levels of serological markers, suggestive of a systemic disease [3, 4]. Due to the pa-

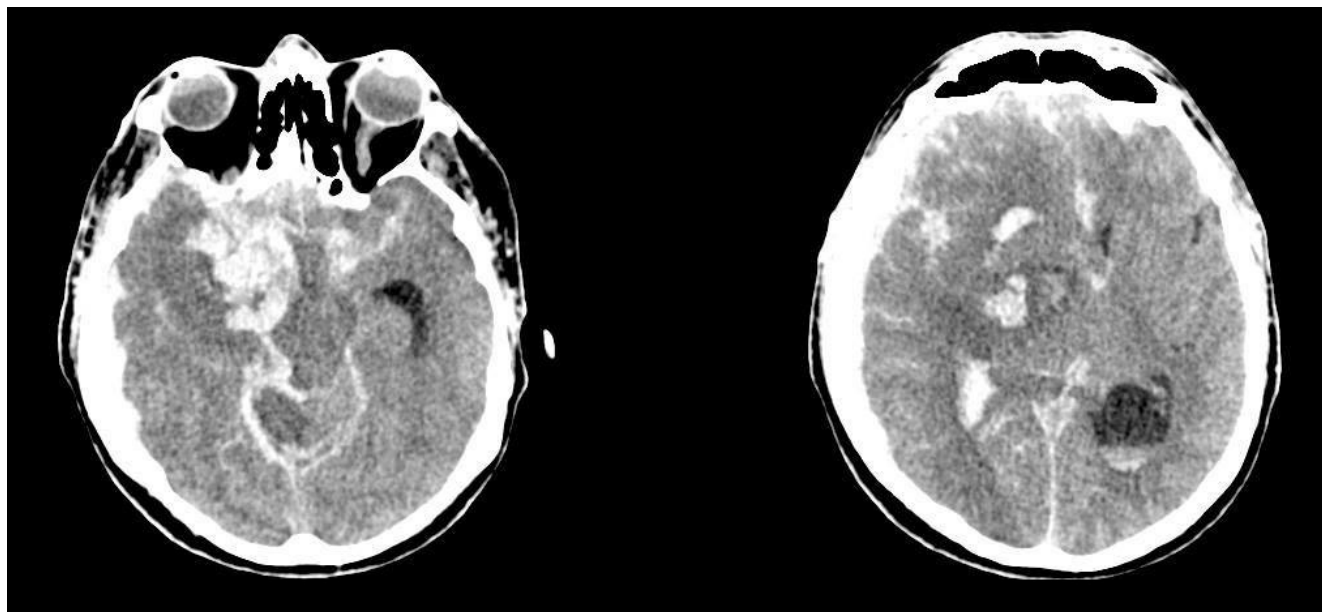


Fig. 3. Extensive intraparenchymal and extra-axial right hemispheric haemorrhage a few hours later.



tient's prolonged professional exposure to various infectious agents, tests were undertaken to rule out possible causes of secondary cerebral vasculitis. However, tests were not conducted for some of the potential infectious etiological agents such as bartonella, mycobacterium tuberculosis, any of the rickettsiae, or any fungal and protozoal infections.

Patients with exclusive signs of cerebral vasculitis probably have primary angiitis of the central nervous system (PACNS). PACNS has a complex pathology, and it is a diagnostic challenge. It usually has a poor prognosis and a fatal outcome due to severe intracranial complications. It has no significant differences in histopathologic features compared to GCA. The typically patchy involvement of the arterial wall (skip lesions) is characteristic of both PACNS and GCA. Brain biopsy or angiography is necessary for a definitive diagnosis [3]. Manifestations of PACNS are highly variable, virtually any neurologic deficit can be encountered, and unusual presentations must always be expected.

In a report of nine patients with histological evidence of GCA of the superficial temporal artery, associated with intracranial vasculitic findings, seven patients died of cerebrovascular complications when corticosteroids failed to stop the progression of the disease. Most of the cases were identified only at autopsy when histological evidence of cerebral vasculitis was found. Post-mortem findings in these cases suggested a serious involvement of the posterior fossa circulation, with more frequent reports of ischemic events in the vertebrobasilar territory [4]. However, the involvement of the vertebral arteries is limited to the first few millimetres of their intracranial course, before entering the dura, as mentioned above.

In rare cases, GCA involving intracranial vessels leads to the development of aneurysms, mainly in the posterior fossa circulation. In cases complicated by intraparenchymal and subarachnoid haemorrhage, necrotising vasculitis with transmural fibrinoid necrosis and severe vessel wall weakening appears to be a common histopathologic pattern [5, 6]. Intracranial haemorrhage followed by subarachnoid haemorrhage is the presenting feature of the disease in 11-12% of PACNS [3].

There are only a few reports of posterior fossa subarachnoid haemorrhage due to an unknown aneurysm rupture associated with GCA. These reports are mostly concerning young adults. In these cases, microscopic

post-mortem evaluation of the arterial specimens revealed granulomatous arteritis, with multinucleated giant cells [6, 7, 8]. In one case of a 19-year-old woman, aneurysm of the right vertebral artery was found, which ruptured leading to a fatal subarachnoid haemorrhage. Autopsy revealed focal necrosis of the media and intimal thickening exclusively in the vertebral and basilar arteries [7].

There are also reports of PACNS associated with intracerebral or subarachnoid complications, with a slight predominance of intraparenchymal bleeding [6].

Death due to GCA, in uncomplicated cases, is rare. In most cases, both GCA and PACNS respond to corticosteroid treatment with a quick improvement of clinical symptoms. Studies evaluating the possible causes of death in GCA found that fatal ischemic lesions started before or relatively shortly after initiation of steroid treatment [9]. Initiation, as well as the sudden withdrawal of steroid therapy, might have a deleterious effect on clinical evolution, and could be considered "a double-edged sword" [10]. However, there are only a few reports regarding the harmful aspect of steroid use, suggesting there is probably a coincidental relationship between severe complications and corticotherapy.

Hemorrhagic cerebrovascular complications after steroid use have not been reported.

## ■ CONCLUSIONS

Hemorrhagic cerebrovascular complications associated with GCA are less frequent than ischemic cerebrovascular events. Characteristically, both predominantly involve the vertebrobasilar region, usually with a severe outcome in patients where the onset of GCA is accompanied by visual impairment.

Fatal cerebrovascular complications might occur in patients where initial general and typical clinical manifestations such as a headache, jaw claudication, and visual impairment show considerable improvement under treatment.

The current case highlights the complexity of the atypical presentation of this pathology, which is yet to be fully understood.

## ■ CONFLICT OF INTEREST

None to declare.

## ■ REFERENCES

1. Csépany T, Illés Zs: Giant cell arteritis. *Clinical neuroimmunology*, 2<sup>nd</sup> edition. Budapest: Medical Tribune Scientific Devizió. 2014, pp. 133-143.
2. Calvo-Romero J. Giant cell arteritis. *Postgrad Med J*. 2003;79:511–515.
3. Calabrese LH, Duna GF, Lie JT. Vasculitis in the central nervous system. *Arthritis Rheum*. 1997;40(7):1189-1201.
4. Carlo S, Caterina G, Dylan V, Gene H. Giant Cell Arteritis: Involvement of intracranial arteries. *Arthritis Rheum*. 2006;55(6):985-9.
5. Kumar R, Wijidicks E F, Brown R D Jr, Parisi J E, Hammnod C A. Isolated angiitis of the CNS presenting as subarachnoid haemorrhage. *J Neurol Neurosurg Psychiatry*. 1997;62(6): 649–651.
6. Salvarani C, Brown RD Jr, Calamia KT et al. Primary central nervous system vasculitis presenting with intracranial haemorrhage. *Arthritis Rheum*. 2011;63(11):3598-606.
7. Thal DR, Barduzal S, Franz K, Hermann G, Bode F, Lambrecht E, Schlote W. Giant cell arteritis in a 19-year-old woman associated with vertebral artery aneurysm and subarachnoid haemorrhage. *Clin Neuropathol*. 2001;20(2):80-86.
8. Love S, Renowden S, Carter M. Ruptured vertebrobasilar aneurysm associated with giant cell arteritis in a young boy. *Clin Neurol Neurosurg*. 2008;110(1):92-96.
9. Säve-Söderbergh J, Malmvall BE, Andersson R, Bengt-Ake B. Giant Cell Arteritis as a cause of death, Report of nine cases. *JAMA*. 1986;255(4):493-496.
10. Staunton H, Stafford F, Leader M, O’Riordain et al. Deterioration of giant cell arteritis with corticosteroid therapy. *Arch Neurol*. 2000;57(4):581-584.