

POSTER PRESENTATION

Open Access

Normal regional pulse wave velocity predicts absence of aortic luminal growth in patients with Marfan syndrome: a comprehensive MRI-study

Eleanore Kroner^{2*}, Arthur Scholte², Patrick Koning¹, Pieter J van den Boogaard¹, Rob J van der Geest¹, Lucia J M Kroft¹, Hildo J Lamb¹, Yvonne Hilhorst-Hofstee⁴, Maarten Groenink³, Teodora Radonic³, Barbara J Mulder³, Ernst E van der Wall², Jeroen J Bax², Albert de Roos¹, Johan H Reiber¹, Jos J Westenberg¹

From 15th Annual SCMR Scientific Sessions
Orlando, FL, USA. 2-5 February 2012

Summary

By using a comprehensive MRI-approach in patients with Marfan syndrome, increased regional pulse wave velocity in the ascending aorta can predict in 42% of the cases aortic luminal growth in the ascending aorta, while normal PWV can predict in 89% absence of luminal growth.

Background

The leading cause of premature death in patients with Marfan syndrome (MFS) is aortic dissection after progressive dilatation due to local increased wall stiffness, occurring most prominently in the ascending aorta. Aortic pulse wave velocity (PWV) is a marker of wall stiffness [Nollen, et al. *Eur Heart J* 2004]. Regional PWV can be accurately determined from in-plane multi-directional velocity-encoded (VE) MRI [Westenberg, et al. *JMRI* 2010]. The study objective was to test whether regional PWV can predict regional aorta dilatation at 2-year follow-up (FU) in MFS.

Methods

In twenty-one MFS patients (mean age 36 ± 15 years, 11 male) regional PWV and aortic luminal areas were assessed by 1.5T MRI (Philips, The Netherlands). At 2-year FU, the incidence of luminal growth was determined.

In detail, a contrast-enhanced MR angiogram of the full aorta was obtained by first-pass imaging of a 25mL contrast bolus Dotarem (0.5mmol/mL, infusion rate

2mL/s), with 3D T1-weighted gradient-echo. Image analysis was performed using in-house developed software with automated centerline detection [de Koning et al., *MRM* 2003] and 3D deformable modeling [Makowski et al., *LNCS* 4072 2006]. Cross-sectional luminal areas were measured at 200 equidistantly-spaced sample points along the centerline. The aorta was divided into five segments (Figure 1A): ascending aorta (S1), aortic arch (S2), thoracic descending aorta (S3), suprarenal abdominal aorta (S4) and infrarenal abdominal aorta (S5).

Next, regional PWV was obtained for each segment by wave propagation analysis (Figure 1B) from multi-slice two-directional velocity-encoded MRI, covering the full aorta by three double-oblique sagittal slices with velocity sensitivity 150 cm/s in anterior-posterior and feet-head (in-plane) direction. Regional PWV was calculated by the length of each segment and the transit-time of the flow velocity wave propagating through this segment [Westenberg et al., *JMRI* 2010]. Regional PWV was compared with age-related normal values [Westenberg et al., *JMRI* 2011] and considered increased when exceeding age-related PWV by two standard errors.

For twenty-one patients, regional PWV at baseline was compared with cross-sectional luminal area growth from baseline to FU. A mean luminal area increase $>14.6\text{mm}^2$ (i.e., two voxels) was considered significant growth.

Results

In twenty-one MFS patients, a mean aorta trajectory of $44 \pm 4\text{cm}$ was evaluated. Significant luminal growth at FU was reported in 47 out of 105 aortic segments (45%)

²Cardiology, Leiden University Medical Center, Leiden, Netherlands
Full list of author information is available at the end of the article

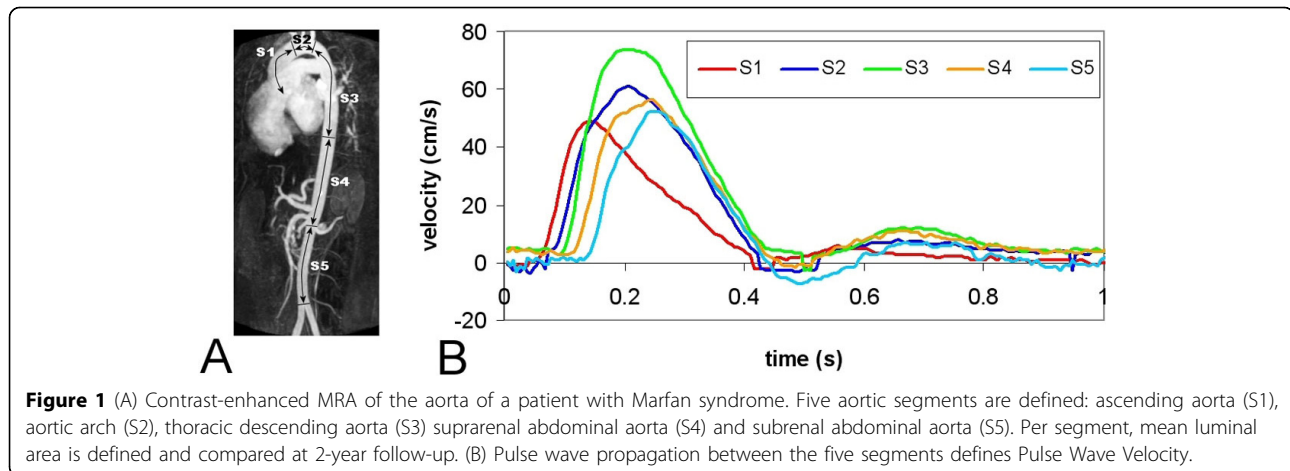


Figure 1 (A) Contrast-enhanced MRA of the aorta of a patient with Marfan syndrome. Five aortic segments are defined: ascending aorta (S1), aortic arch (S2), thoracic descending aorta (S3) suprarenal abdominal aorta (S4) and subrenal abdominal aorta (S5). Per segment, mean luminal area is defined and compared at 2-year follow-up. (B) Pulse wave propagation between the five segments defines Pulse Wave Velocity.

Table 1 predictive performance of regional PWV-assessment on luminal growth at 2-year follow-up

Aortic region	Incidence of luminal increase	Sensitivity	Specificity
S1	12	42%	89%
S2	15	27%	83%
S3	11	27%	70%
S4	7	29%	36%
S5	2	100%	35%

and regional PWV at baseline was increased in 42 segments. The incidence of luminal growth per segment and the sensitivity and specificity for PWV predicting luminal growth are presented in Table 1.

Conclusions

Increased regional PWV in the ascending aorta in MFS patients predicts in 42% of the cases aortic luminal growth, while normal PWV predicts in 89% absence of luminal growth. Specificity decreases for more distal segments.

Funding

Netherlands Heart Foundation (Project 2006B138).

Author details

¹Radiology, Leiden University Medical Center, Leiden, Netherlands.

²Cardiology, Leiden University Medical Center, Leiden, Netherlands.

³Cardiology, Academic Medical Center, Amsterdam, Netherlands. ⁴Clinical Genetics, Leiden University Medical Center, Leiden, Netherlands.

Published: 1 February 2012

doi:10.1186/1532-429X-14-S1-P131

Cite this article as: Kroner et al.: Normal regional pulse wave velocity predicts absence of aortic luminal growth in patients with Marfan syndrome: a comprehensive MRI-study. *Journal of Cardiovascular Magnetic Resonance* 2012 **14**(Suppl 1):P131.

Submit your next manuscript to BioMed Central and take full advantage of:

- Convenient online submission
- Thorough peer review
- No space constraints or color figure charges
- Immediate publication on acceptance
- Inclusion in PubMed, CAS, Scopus and Google Scholar
- Research which is freely available for redistribution

Submit your manuscript at
www.biomedcentral.com/submit

