

# Anterior Cranial Fossa Dural Arteriovenous Fistula with Pial Arterial Supply

## Abstract

Anterior cranial fossa (ACF) dural arteriovenous fistulas (DAVFs) are mainly fed by the ethmoidal arteries and sometimes have pial arterial feeders. DAVFs with pial arterial supply in ACF are extremely rare because most of the reported cases of DAVFs with pial arterial supply are located at the transverse sigmoid sinus and tentorium. A 68-year-old male presented with dizziness. Angiography showed cortical venous reflux (CVR) through an ACF DAVF fed by both bilateral ethmoidal arteries and by the right orbitofrontal artery as a pial feeder. The ethmoidal feeders were disconnected by craniotomy. The pial arterial feeder from the anterior cerebral artery was not found during surgery, and disconnection of the draining vein was not performed. CVR showed a significant reduction after the surgery. After 2 years of follow-up, angiography revealed an increased shunt flow from the pial feeder. Endovascular treatment using n-butyl-2-cyanoacrylate was performed, resulting in the complete occlusion of the fistula. DAVFs with pial supply are reported to carry a high risk of perioperative complications because of the restriction of the venous outflow and retrograde thrombosis of the pial artery. Endovascular pial feeder occlusion after surgical dural arterial feeder disconnection might achieve a safe and effective outcome. With close follow-up, the recurrence of increased shunt flow may be an appropriate timing for additional treatment. This rare condition may offer a new insight into the mechanisms of pial feeder development.

**Keywords:** Anterior cranial fossa, combined therapy, dural arteriovenous fistula, pial supply

## Introduction

Intracranial dural arteriovenous fistulas (DAVFs) are abnormal connections between the arteries and veins or venous sinuses of the dura mater. DAVFs in the anterior cranial fossa (ACF) are rare but known to be aggressive entities, appearing as intracerebral or subarachnoid hemorrhages.<sup>[1-3]</sup> Open surgical shunt disconnection was traditionally the main treatment for ACF DAVFs,<sup>[2]</sup> but endovascular treatment using recently available microcatheters and liquid embolic materials is also becoming a safe and effective treatment.<sup>[4-6]</sup>

The blood supply of DAVFs is mainly from the dural arteries, but 11.3%–23.8% of DAVFs were reported to have pial arterial supplies.<sup>[7,8]</sup> Several studies have reported that pial arterial supply in DAVFs is a risk factor of procedure-related complications, either ischemic stroke or hemorrhage.<sup>[7,9,10]</sup> In previously reported cases of DAVFs with pial arterial supply, the lesion was located

at the transverse sigmoid sinus or tentorium, and DAVFs with pial arterial feeders in the ACF are extremely rare.<sup>[11]</sup>

Here, we report a case of an ACF DAVF with a feeder from the orbitofrontal artery. Combination of craniotomy and endovascular treatment led to safe obliteration of the fistula. We also discuss the etiology of this rare condition and the treatment strategy including timing of the disconnection of the abnormal dural and pial feeders.

## Case Report

A 68-year-old male was admitted to our hospital complaining of dizziness, without any appreciable past medical history. Magnetic resonance imaging (MRI) revealed cortical venous dilation, and angiography showed a DAVF draining into the superior sigmoid sinus (SSS) at the ACF. The DAVF was fed by both bilateral ethmoidal arteries and by the right orbitofrontal artery arising from the anterior cerebral artery (ACA) [Figures 1a and 2].

This is an open access journal, and articles are distributed under the terms of the Creative Commons Attribution-NonCommercial-ShareAlike 4.0 License, which allows others to remix, tweak, and build upon the work non-commercially, as long as appropriate credit is given and the new creations are licensed under the identical terms.

For reprints contact: reprints@medknow.com

Akinari Yamano<sup>1,2</sup>,  
Kazuhiro  
Nakamura<sup>2</sup>,  
Daisuke Watanabe<sup>1</sup>,  
Kuniyuki Onuma<sup>2</sup>,  
Masayuki Sato<sup>1</sup>,  
Yuji Matsumaru<sup>1</sup>,  
Kiyoyuki Yanaka<sup>2</sup>,  
Eiichi Ishikawa<sup>1</sup>,  
Akira Matsumura<sup>1</sup>

<sup>1</sup>Department of Neurosurgery, Faculty of Medicine, University of Tsukuba, <sup>2</sup>Department of Neurosurgery, Tsukuba Memorial Hospital, Tsukuba City, Ibaraki, Japan

### Address for correspondence:

Dr. Eiichi Ishikawa,  
Department of Neurosurgery,  
Faculty of Medicine,  
University of Tsukuba,  
Tsukuba City, Ibaraki, Japan.  
E-mail: e-ishikawa@md.tsukuba.ac.jp

### Access this article online

Website: www.asianjns.org

DOI: 10.4103/ajns.AJNS\_288\_19

### Quick Response Code:



**How to cite this article:** Yamano A, Nakamura K, Watanabe D, Onuma K, Sato M, Matsumaru Y, et al. Anterior cranial fossa dural arteriovenous fistula with pial arterial supply. Asian J Neurosurg 2020;15:176-9.

**Submission:** 15-09-2019      **Accepted:** 11-12-2019  
**Published:** 25-02-2020

Right frontal craniotomy was performed to obliterate the fistula. After opening the dura mater, a dilated red draining vein running from the anteromedial surface of the frontal lobe to the SSS was observed. Ethmoidal fistulas were also observed at the ACF floor, and intradural ligation of the dural feeders was performed. A pial arterial feeder from the right ACA was not detected in the surgical view. Indocyanine green videoangiography showed a significant shunt flow reduction. Considering the possibility of the draining vein being involved in the normal circulation, ligation of the draining vein was not performed.

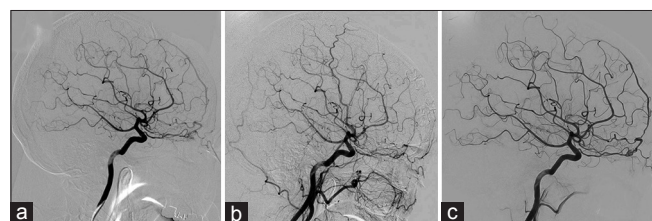
Postoperative angiography showed a remarkable decrease in the shunt flow and the cortical venous reflex (CVR) [Figure 1b]. Two years after the craniotomy, tight observation with MR angiography showed an increase in the CVR.

Angiography performed to reevaluate the DAVF revealed increasing shunt flow from the right orbitofrontal artery draining into the SSS. Dural arterial supply was not observed [Figure 1c]. Three-dimensional rotational angiography showed corkscrew-like vessels between the right orbitofrontal artery and the dilated cortical vein in the right ACF [Figure 3a-d], which was not seen previously on angiography. Therefore, endovascular treatment was performed to obliterate the abnormal pial arterial connection. 25% n-butyl-2-cyanoacrylate (NBCA) was slowly infused into the fistula through a Marathon microcatheter (ev3, Irvine, CA, USA). The microcatheter was removed after adequate penetration of the fistula and subtle reflux of NBCA were confirmed [Figure 4a and b]. Angiography right after the embolism showed no filling of the fistula and no CVR [Figure 4c].

After the treatment, the dizziness dramatically improved, and the patient was discharged from the hospital without any complications. MRI conducted 6 months after the treatment showed no signs of recurrence.

## Discussion

ACF DAVFs usually have only a dural arterial supply. However, in our case, the ACF DAVF had both a dural and a pial supply. To the best of our knowledge, only



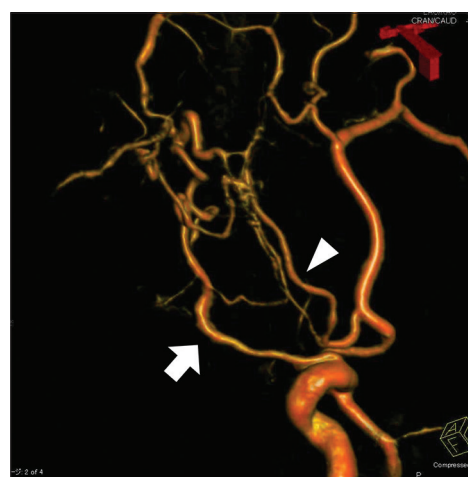
**Figure 1:** (a) Lateral view of the first angiography. Right internal carotid angiography showing cortical venous reflux rising to the superior sagittal sinus. (b) Right common carotid angiography after the open surgery showing a significant reduction in the flow volume to the superior sagittal sinus. (c) Right internal carotid angiography 2 years after the surgery showing an increased flow of the cortical venous reflux due to the fistula being fed by the right orbitofrontal artery

one case of ACF DAVF with pial arterial supply has been reported.<sup>[11]</sup>

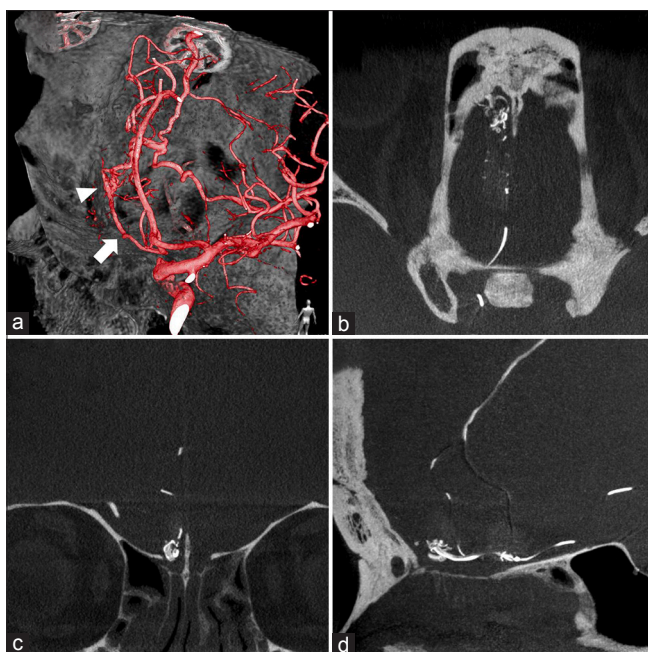
There are two types of pial arterial supplies in DAVFs.<sup>[8]</sup> One is a type of supply from the physiological dural branches of the pial artery, and the other is the so-called “pure” pial supply type. The former is from preexisting piodural arterial connections, and these connections often exist around the tentorium cerebelli, such as the artery of Davidoff and Schechter. The latter is not thought to be from the preexisting arteries. That supply has a different angioarchitecture from physiological arteries: it shows corkscrew-like vessels, no evidence of a straight dural course, nor any known anatomic correlates.<sup>[8]</sup> In our case, the feeder from the orbitofrontal artery is assumed to be of the “pure” pial supply type.

The “pure” pial supply is hypothesized to have newly emerged as a result of induced angiogenesis.<sup>[8]</sup> The pathophysiology of this angiogenesis is not yet proven. Sinus thrombosis and an arterial steal phenomenon due to high shunt flow are reported to have some relevance.<sup>[12-14]</sup> Vascular endothelial growth factor-mediated angiogenesis induced by sinus thrombosis or venous dilatation as a sign of venous hypertension might have some role in the pathophysiology of the pial supply.<sup>[15-17]</sup> The bilateral ethmoidal arteries were the main feeders of the DAVF in our case. After those feeders were disconnected by craniotomy, the shunt flow decreased significantly. However, the shunt flow increased again after 2 years and came from the pial feeders. The progress of “pure” pial supply development is presumed to be the background of this pathophysiology: corkscrew-like pial feeders from the orbitofrontal artery had developed after the surgery, resulting in an increase in the shunt flow.

Recent studies have reported the high risk of perioperative complications in DAVFs with pial arterial supply.<sup>[7,9,10]</sup>



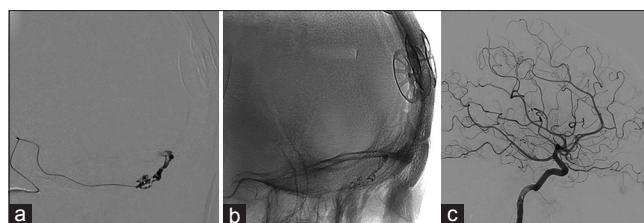
**Figure 2:** Three-dimensional rotational angiography from the right internal carotid artery showing the anterior cranial fossa dural arteriovenous fistula fed by the anterior/posterior ethmoidal arteries (arrow) and the orbitofrontal artery (arrowhead)



**Figure 3:** (a) Three-dimensional rotational angiography from the right internal carotid artery showing “pure” pial arterial supply (arrowhead) fed by the orbitofrontal artery (arrow). Axial (b), coronal (c), and sagittal (d) views indicating corkscrew-like vessels located in the anterior cranial fossa

Wu *et al.* and Sato *et al.* reported cases of intraoperative hemorrhage during Onyx embolization.<sup>[9,10]</sup> The hemorrhage occurred in two of six patients<sup>[10]</sup> with pial supply, which was significantly higher than in patients without pial supply. These hemorrhagic complications were assumed to happen secondary to the restriction of the venous outlet caused by the treatment itself, which may be similar to the mechanism of intraoperative hemorrhage in arteriovenous malformations.<sup>[9,10]</sup> On the other hand, Hetts *et al.* described the high risk of perioperative ischemic stroke in DAVFs with pial supply. Several mechanisms might be involved in this complication, such as retrograde reflux of liquid embolic materials to the pial vessels, periprocedural hypercoagulability, retrograde thrombosis of the pial arteries, and venous infarction with hemorrhage.<sup>[7]</sup>

The concept of ACF DAVF surgery is disconnection of the fistula, which emerges from the ACF and merges into a dilated draining vein. Ideally, the shunt must be disconnected at the fistula, but the fistula itself was obscured by the frontal lobe or the varix in some cases.<sup>[18]</sup> In those cases, disconnection was performed at the vein just distal to the fistula.<sup>[18]</sup> In our case, the initial craniotomy ended with little shunt flow through the remaining feeder from the orbitofrontal artery. The dilated cortical vein was thought to have an important role in normal circulation. If we had performed the disconnection of the draining vein at the initial craniotomy, hemorrhagic or ischemic complication could have occurred, as in those past series. Substantial reduction of the shunt flow was achieved, confirmed by indocyanine green videoangiography, so no further treatment was necessary at that point. Tight follow-up is



**Figure 4:** (a) Embolic materials infusing through the microcatheter placed nearby the fistula. (b) The fistula, proximal part of the cortical venous reflex, and distal part of the feeder had disappeared. (c) Right internal carotid angiography shows no signs of remaining shunt flow

essential to detect reworsening of the DAVF condition. Although the best timing for the additional treatment remains known, reworsening of the CVR seems to be the most appropriate timing for additional endovascular treatment. Endovascular treatment using NBCA was safely accomplished because the ethmoidal feeders had already been disconnected during the previous surgery. Because reflux of the NBCA to the ophthalmic arteries never happens with this strategy and because the anatomic feature of the DAVF was changed to a single-feeder DAVF, the risk of ischemic or hemorrhagic complication was reduced. With evaluation and comprehension of the anatomic features and hemodynamics of the shunt flow, a tailored strategy combining open surgery and endovascular treatment at the appropriate timing could be a solution to reduce the high ratio of perioperative complications in patients with DAVFs supplied by both dural and pial arteries.

## Conclusion

DAVFs are usually supplied only by dural arteries but sometimes involve pial arteries. Because of a high risk of perioperative complications, hemorrhagic or ischemic, or both, such DAVFs should be carefully treated considering the anatomic features and hemodynamics of the shunt flow in each case.

## Declaration of patient consent

The authors certify that they have obtained all appropriate patient consent forms. In the form the patient(s) has/have given his/her/their consent for his/her/their images and other clinical information to be reported in the journal. The patients understand that their names and initials will not be published and due efforts will be made to conceal their identity, but anonymity cannot be guaranteed.

## Acknowledgments

The authors would like to thank Dr. Alexander Zaboronok, Department of Neurosurgery, and Ms. F. Miyamasu of the Medical English Communications Center of the Faculty of Medicine, University of Tsukuba, for manuscript revision.

## Financial support and sponsorship

Nil.

## Conflicts of interest

There are no conflicts of interest.

## References

- Halbach VV, Higashida RT, Hieshima GB, Wilson CB, Barnwell SL, Dowd CF. Dural arteriovenous fistulas supplied by ethmoidal arteries. *Neurosurgery* 1990;26:816-23.
- Kakarla UK, Deshmukh VR, Zabramski JM, Albuquerque FC, McDougall CG, Spetzler RF. Surgical treatment of high-risk intracranial dural arteriovenous fistulae: Clinical outcomes and avoidance of complications. *Neurosurgery* 2007;61:447-57.
- Brown RD Jr., Wiebers DO, Nichols DA. Intracranial dural arteriovenous fistulae: Angiographic predictors of intracranial hemorrhage and clinical outcome in nonsurgical patients. *J Neurosurg* 1994;81:531-8.
- Defreyne L, Vanlangenhove P, Vandekerckhove T, Deschrijver I, Sieben G, Klaes R, *et al.* Transvenous embolization of a dural arteriovenous fistula of the anterior cranial fossa: Preliminary results. *AJNR Am J Neuroradiol* 2000;21:761-5.
- Agid R, Terbrugge K, Rodesch G, Andersson T, Söderman M. Management strategies for anterior cranial fossa (ethmoidal) dural arteriovenous fistulas with an emphasis on endovascular treatment. *J Neurosurg* 2009;110:79-84.
- Mack WJ, Gonzalez NR, Jahan R, Vinuela F. Endovascular management of anterior cranial fossa dural arteriovenous malformations. A technical report and anatomical discussion. *Interv Neuroradiol* 2011;17:93-103.
- Hetts SW, Yen A, Cooke DL, Nelson J, Jolivald P, Banaga J, *et al.* Pial artery supply as an anatomic risk factor for ischemic stroke in the treatment of intracranial dural arteriovenous fistulas. *AJNR Am J Neuroradiol* 2017;38:2315-20.
- Osada T, Krings T. Intracranial dural arteriovenous fistulas with pial arterial supply. *Neurosurgery* 2019;84:104-15.
- Wu Q, Zhang XS, Wang HD, Zhang QR, Wen LL, Hang CH, *et al.* Onyx embolization for tentorial dural arteriovenous fistula with pial arterial supply: Case series and analysis of complications. *World Neurosurg* 2016;92:58-64.
- Sato K, Matsumoto Y, Endo H, Tominaga T. A hemorrhagic complication after Onyx embolization of a tentorial dural arteriovenous fistula: A caution about subdural extension with pial arterial supply. *Interv Neuroradiol* 2017;23:307-12.
- Tsutsumi S, Shimizu Y, Nonaka Y, Abe Y, Yasumoto Y, Ito M, *et al.* Arteriovenous fistula arising from the persistent primitive olfactory artery with dual supply from the bilateral anterior ethmoidal arteries. *Neurol Med Chir (Tokyo)* 2009;49:407-9.
- Matsubara S, Satoh K, Satomi J, Shigekiyo T, Kinouchi T, Miyake H, *et al.* Acquired pial and dural arteriovenous fistulae following superior sagittal sinus thrombosis in patients with protein S deficiency: A report of two cases. *Neurol Med Chir (Tokyo)* 2014;54:245-52.
- Mirza FA, Fraser JF. Multiple dural and pial arteriovenous fistulae in a twenty-four-year-old woman in the setting of superior sagittal sinus thrombosis: Case report and review of literature. *J Stroke Cerebrovasc Dis* 2016;25:e192-9.
- Lai CW, Agid R, van den Berg R, Ter Brugge K. Cerebral arteriovenous fistulas induced by dural arteriovenous shunts. *AJNR Am J Neuroradiol* 2005;26:1259-62.
- Li Q, Zhang Q, Huang QH, Fang YB, Zhang ZL, Xu Y, *et al.* A pivotal role of the vascular endothelial growth factor signaling pathway in the formation of venous hypertension-induced dural arteriovenous fistulas. *Mol Med Rep* 2014;9:1551-8.
- Wang SS, Li CH, Zhang XJ, Wang RM. Investigation of the mechanism of dural arteriovenous fistula formation induced by high intracranial venous pressure in a rabbit model. *BMC Neurosci* 2014;15:101.
- Zhu Y, Lawton MT, Du R, Shwe Y, Chen Y, Shen F, *et al.* Expression of hypoxia-inducible factor-1 and vascular endothelial growth factor in response to venous hypertension. *Neurosurgery* 2006;59:687-96.
- Lawton MT, Chun J, Wilson CB, Halbach VV. Ethmoidal dural arteriovenous fistulae: An assessment of surgical and endovascular management. *Neurosurgery* 1999;45:805-10.