

# “Over the Top” Augmentation for Partial Anterior Cruciate Ligament Tears Using Suspension Device for Tibial Fixation



Alejandro Espejo-Baena, M.D., Alejandro Espejo-Reina, M.D., M.Sc.,  
María Josefa Espejo-Reina, M.D., Jaime Dalla Rosa-Nogales, M.D.,  
Joaquina Ruiz-Del Pino, M.D., Ph.D., and María Belén Martín-Castilla, M.D.

**Abstract:** A technique for augmentation of the partial anterior cruciate ligament is presented. The patient is positioned supine with the knee flexed 90°. After addressing intra-articular injuries, the autologous semitendinosus tendon is harvested and measured in a doubled manner; after that, the tibial tunnel is performed in the outside-in direction, of the same diameter of the doubled graft. Both ends of the graft are sutured together, after inserting it through the loop of a suspension device, which is attached in its augmentation piece. A lateral femoral incision is made, to approach the joint through the “over the top” position. A looped thread is introduced inside the joint with the aid of a hook. This thread pulls the graft’s sutures through the “over the top” position. A femoral tunnel is then drilled in the lateromedial and caudocranial direction. The suspension device is attached to the anterior tibial cortex and the graft is pulled in the caudocranial direction to the femoral tunnel, where an interference screw is used for fixation.

**P**artial tears of the anterior cruciate ligament (ACL) occur in a range between 10% and 28% of the cases of ACL ruptures,<sup>1,2</sup> and its treatment remains controversial.

The references regarding the definition and classification of these injuries are scarce. According to Sonnery-Cottet and Colombet,<sup>1</sup> “a partial ACL tear is one that combines a positive Lachman’s test with a firm endpoint along with small differential laxity, hyperintense signal within the ACL fibers on MRI, and

arthroscopic findings of a partial tear.” Noyes et al.<sup>3</sup> defined the risk of progression to a complete ACL tear according to the percentage of ACL remaining (one-fourth tears infrequently progressed, one-half tears progressed in 50%, and three-fourth tears in 86%); Crain et al.<sup>4</sup> described 3 different settings of ACL partial tears with scarring to surrounding tissue and measured a significant increase of anterior translation with remnant cleaning, compared with a complete tear; DeFranco and Bach<sup>5</sup> defined a partial ACL tear as “an asymmetric Lachman-test result, a negative pivot-shift test, a low-grade KT-1000 arthrometer measurement  $\leq 3$  mm, and arthroscopic evidence of anterior cruciate ligament injury.” Magnetic resonance imaging is important in the diagnosis, but it does not provide a sufficiently defined lesion in many occasions. Authors’ criteria indicating a partial tear of the ACL include clinical (negative or trace-positive pivot shift test and negative or 1+ Lachman test) and/or arthroscopic findings (substantial healthy and potentially functional portion of at least 1 bundle, assessed by means of palpation with a probe and arthroscopic anterior drawer test).

The treatment of partial tears of the ACL should be individualized, according to the risk of progression to complete tear. Low-risk patients are those with low physical demand, without associated injuries, without

*From the Department of Trauma and Orthopaedic Surgery, Hospital Vithas Parque San Antonio (A.E-B., A.E-R., J.D.R-N., M.B.M-C.); Clínica Espejo (A.E-B., A.E-R.); Emergency Department (J.R-D.P.) and Department of Trauma and Orthopaedic Surgery (M.B.M-C.), Hospital Universitario Virgen de la Victoria, Málaga; and Department of Trauma and Orthopaedic Surgery, Hospital Comarcal de Antequera (M.J.E-R.), Antequera, Spain.*

*The authors report that they have no conflicts of interest in the authorship and publication of this article. Full ICMJE author disclosure forms are available for this article online, as [supplementary material](#).*

*Received December 17, 2017; accepted March 12, 2018.*

*Address correspondence to Alejandro Espejo-Reina, M.D., M.Sc., Clínica Espejo, Paseo Reding 9, 1 C, 29016 Málaga, Spain. E-mail: [espejoreina@clinicadoctorespejo.com](mailto:espejoreina@clinicadoctorespejo.com)*

© 2018 Published by Elsevier on behalf of the Arthroscopy Association of North America. This is an open access article under the CC BY-NC-ND license (<http://creativecommons.org/licenses/by-nc-nd/4.0/>).

2212-6287/171530

<https://doi.org/10.1016/j.eats.2018.03.006>

**Table 1.** Step-by-Step Details of the Technique

1. Patient positioning and intra-articular exploration:
  - a. Supine with limb in an L-shaped leg holder at 90° of flexion
  - b. General or regional anesthetic
  - c. Transtendinous and anteromedial portals
  - d. Arthroscopic partial ACL rupture identification
2. Graft harvesting and preparation:
  - a. Semitendinosus autologous tendon
  - b. A G-Lok device with a 15-mm loop is used (a longer loop can be employed if a short graft or a long tunnel is measured), and it is attached to its augmentation piece (G-Lok XL) to increase the contact area with the tibia
  - c. Both ends sutured together forming a closed loop
3. Intra-articular preparation:
  - a. Remnant cleaning
  - b. Footprint of ACL identification
4. Tibial tunnel
  - a. Outside-in direction
  - b. Same diameter of the graft (usually 6-7 mm)
  - c. 55° guide opening
  - d. Guide pin in the center of the footprint of the affected ACL bundle
5. "Over the top" approach and graft passage
  - a. 2-cm lateral incision
  - b. Posterior capsule opening with a hook with a carrier thread inserted through the eyelet on its tip
  - c. Carrier thread's loop is recovered through the tibial tunnel; traction threads from the graft are inserted through the carrier's loop and the graft is pulled until the suspension device is attached to the tibial cortex
6. Femoral fixation:
  - a. A guide pin is placed in the metaphysis of the femur in the caudocranial, posteroanterior, and lateromedial direction
  - b. A tunnel of the same diameter of the graft is performed
  - c. The traction threads of the graft are passed through the eyelet at the bottom of the guide pin, which is pulled from its tip from lateral to medial, passing the threads through the femoral tunnel
  - d. The graft is inserted through the tunnel and is fixed with a bioabsorbable screw 1 mm wider than the graft and the tunnel

ACL, anterior cruciate ligament.

**Table 2.** Advantages and Disadvantages

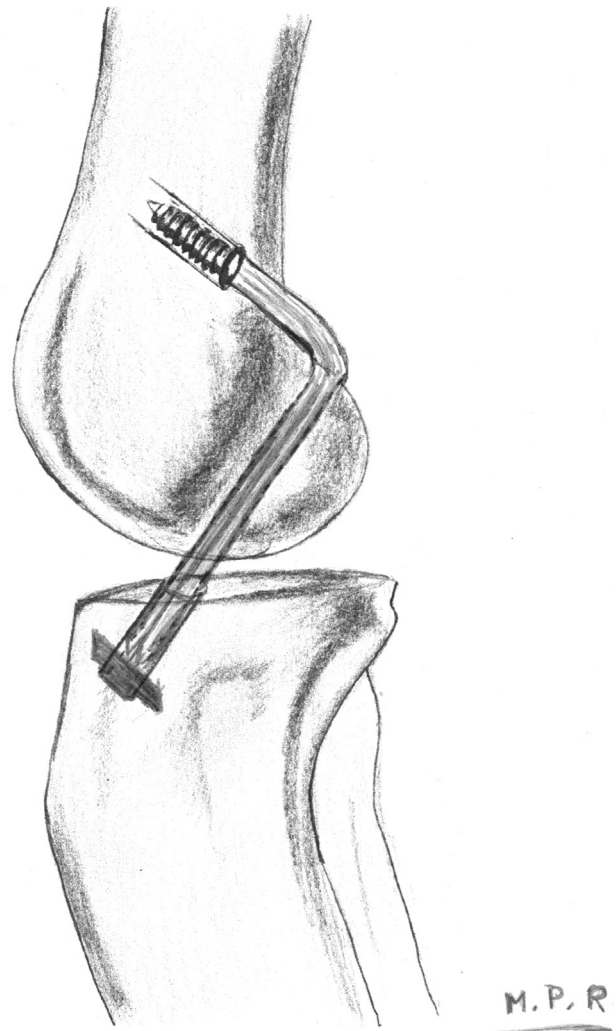
#### Advantages

- The main advantage of this technique is that the loop's length can be adapted to the graft's and tunnel's length, allowing ACL partial tear reconstruction with a single tendon graft (semitendinosus) by increasing the length of the loop
- The "over the top" pass of the graft easily preserves as much ACL intact remnants as possible; it is more difficult to be achieved when performing a tunnel on the femur, especially with the inside-out technique

#### Disadvantages

- The tibial fixation device must be combined with another device of additional length
- Tunnels are performed in the outside-in direction, so 2 incisions (1 femoral and 1 tibial) are needed
- The "over the top" pass of the graft is not an anatomic reconstruction of the torn bundle of the ACL

ACL, anterior cruciate ligament.



**Fig 1.** Diagram of the technique. Right knee. Tibial fixation is performed with a suspension device, and the femoral one is achieved with an interference screw in the "over the top" position.

subjective instability, and with negative or slightly positive laxity tests. Patients with clear subjective instability, with associated injuries, or with high-risk lifestyle should be operated.<sup>6-8</sup>

A partial ACL reconstruction is justified because the ACL remnants provide vascular and innervation supply that will improve proprioception and will help graft integration.<sup>9</sup> Furthermore, it has been shown that 15% of partial ACL tears produce degenerative changes at 8-year follow-up,<sup>10</sup> and according to the amount of ACL injured, one-fourth tears infrequently progress to complete ACL tears, one-half tears progress in 50%, and three-fourth tears in 86%.<sup>3</sup>

The main difference between techniques for partial ACL reconstruction is the femoral pass of the graft. It is

**Table 3.** Tips, Pearls, and Pitfalls

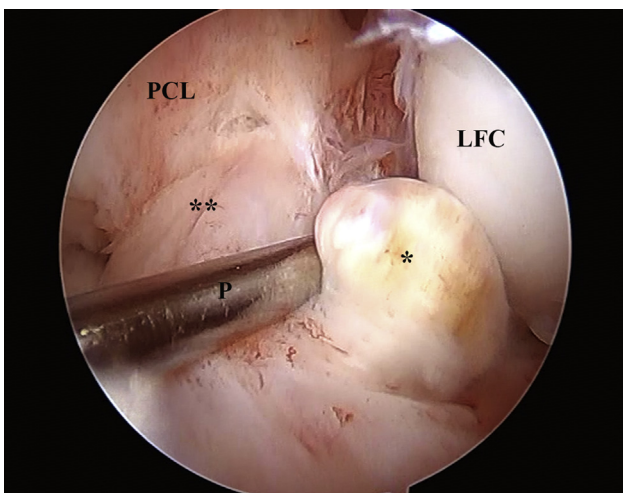
Tips and Pearls

- Although not essential, the authors recommend that the central portal should be used to ensure a clear view of the intercondylar notch
- The 2-cm lateral incision must be performed at a point proximal to the lateral epicondyle and posterior to the femoral metaphysis
- The surgeon should make blunt dissection of the posterior aspect of the femoral supracondylar region with a finger until touching the posterior capsule
- Once the graft is in place, one should check that the device is properly supported by the tibial cortex

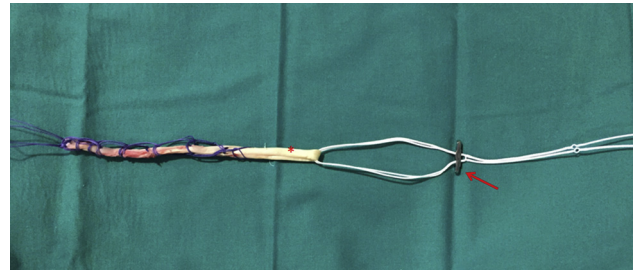
Pitfalls

- During its passage through the tunnels, the graft may become snagged. To avoid this, the posterior capsule should be opened widely with the hook. Curved scissors in a closed fashion can help with this maneuver
- In addition, one should check that the graft can be passed with ease through the diameter calibrator. If this is not possible, the authors recommend to enlarge the tunnel's diameter by passing 1 or 2 more times the drill bit through the tunnel or by using a drill bit 0.5 mm wider than the graft
- The tunnel is performed complete until the medial cortex of the femur is drilled, to allow for correct tensioning of the graft if it is too long

frequent to perform the femoral tunnel using an inside-out technique from the anteromedial portal on the footprint of the torn fascicle.<sup>2,11,12</sup> When using the anteromedial portal, the femoral tunnel is performed with the knee fully flexed; it hampers the view of the ACL's femoral insertion, particularly when a portion of the ACL is preserved. This inside-out technique requires slightly more extensive debridement of the intercondylar notch. For this reason, the use of the outside-in femoral tunnel method has been suggested.



**Fig 2.** Left knee flexed 90°. Arthroscopic view of the lesion (arthroscope via the central portal, probe through the anteromedial portal). Asterisk: torn posterolateral fascicle; double asterisk: intact anteromedial fascicle. (LFC, lateral femoral condyle; P, probe; PCL, posterior cruciate ligament.)



**Fig 3.** The graft is prepared with an adjustable cortical suspension device. Both ends of the graft are sutured together. Asterisk: doubled semitendinosus graft; arrow: button of the cortical suspension device attached to its augmentation piece.

This technique is performed with the knee flexed 90°, an optimal position to see the ligament insertions. Moreover, the nondamaged fibers of the ACL are well preserved because the drill bit does not pass through the intercondylar notch; it comes from the lateral aspect of the knee instead. This technique allows for selective reconstruction of the torn bundle and optimal preservation of the nondamaged bundle.<sup>1</sup>

A different possibility that has demonstrated good clinical outcomes is to perform a nonanatomic reinforcement of the ACL in "over the top" position.<sup>13</sup> Buda et al.<sup>14</sup> even found that this technique was easier to perform and had less complications in a comparative study.

The technique described in this Technical Note has the following features (Tables 1 and 2; Fig 1):

- A doubled semitendinosus tendon is used as a graft.
- The intact fibers of the ACL are preserved.
- Tibial fixation is achieved with a suspension device attached in its augmentation piece.
- The femoral pass of the graft is performed through the "over the top" position.
- A femoral tunnel is performed on the lateral supracondylar region in the caudocranial and lateromedial direction.
- Femoral fixation is achieved using an interference screw.

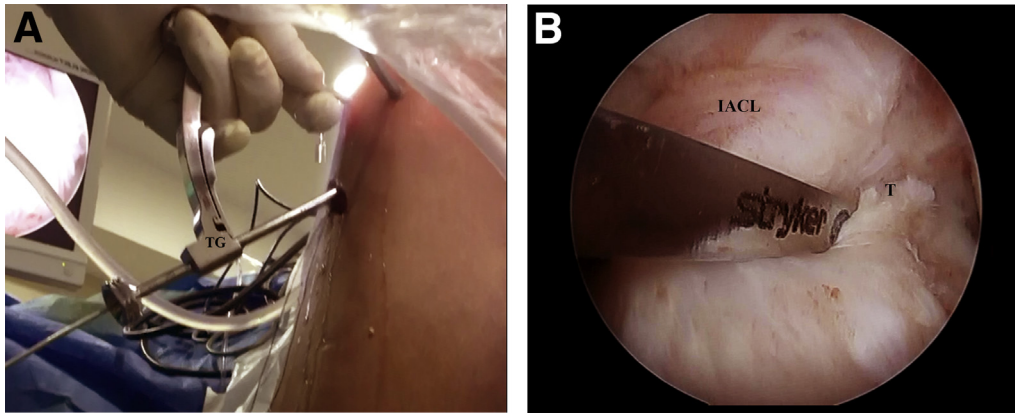
**Technique**

**Patient Positioning**

Spinal or general anesthetic is employed, and the patient is positioned supine. An ischemia cuff is placed around the thigh, and the limb is supported by an L-shaped leg holder with the knee placed at 90° of flexion.

**Arthroscopic Exploration**

A central transtendinous portal is performed to explore the joint (Table 3). The partial ACL damage is



**Fig 4.** Left knee flexed 90°. Setting of the tibial guide pin to perform the tibial tunnel. (A) Outside view. (B) Intra-articular view (arthroscope through the central portal; tibial guide through the anteromedial portal). (IACL, intact anterior cruciate ligament; T, torn fascicle of the anterior cruciate ligament; TG, tibial guide.)

identified (Video 1; Fig 2), and any associated injuries are addressed at this point with the aid of an anteromedial portal (if necessary, an additional anterolateral portal can be used). Meanwhile, ACL unstable remnants are removed using a shaver and a radio-frequency probe.

#### Graft Harvesting and Preparation

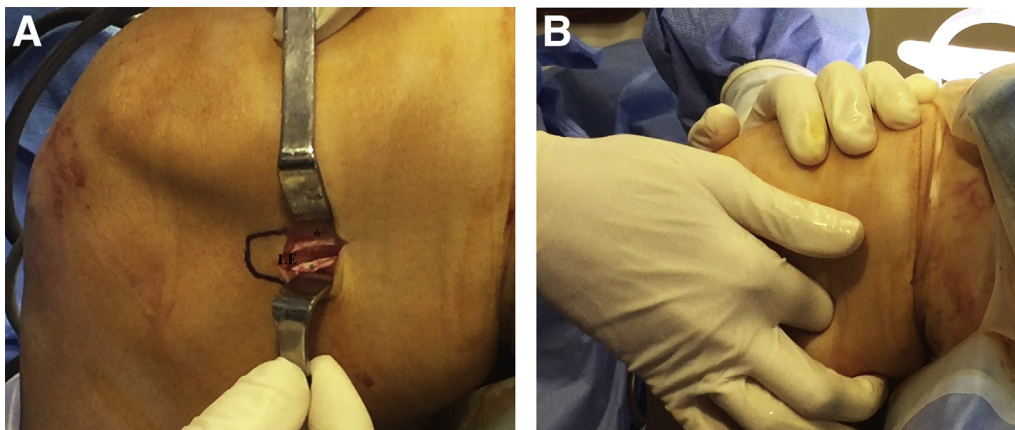
A 3-cm oblique skin incision is made anteromedially to the anterior tibial tuberosity to harvest the semitendinosus tendon (STT) and to perform the tibial tunnel. The gracilis tendon is identified using a soaked gauze, and it is pulled to bring the STT closer, which will be harvested with a standard tendon stripper after removing its expansions. The STT is prepared on an auxiliary table. First, its width is measured with a calibrator. The graft is passed through the loop of an adjustable suspension device (ProCinch; Stryker, Kalamazoo, MI) attached to its augmentation piece (ProCinch XL; Stryker); the ends of the graft are sutured together, leaving long threads

(Fig 3). The length of the loop of the suspension device is adjusted, according to the tunnel's and the graft's length.

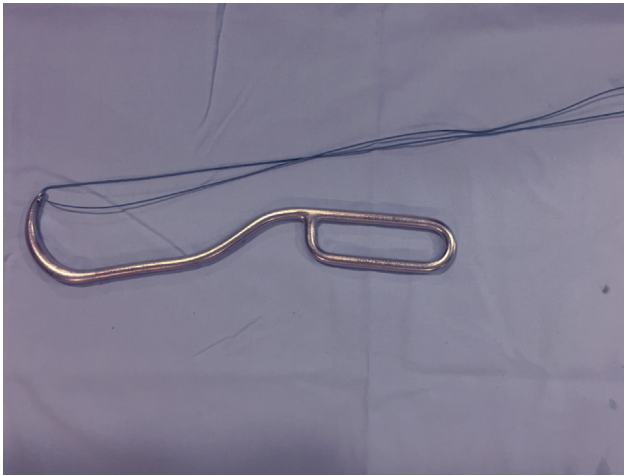
#### Tibial Tunnel Performance and "Over the Top" Position Opening

Using the same approach employed for the STT harvesting, a tibial tunnel is drilled with the aid of an ACL guide (Stryker Endoscopy) set at 55° (Fig 4). Depending on the affected bundle, a guide pin is set at the corresponding site of the tibial ACL footprint. A tunnel of the same diameter of the graft (usually 6-7 cm) is drilled using a cannulated drill bit.

A lateral 2-cm longitudinal incision is made at a point proximal to the lateral epicondyle and posterior to the femoral metaphysis, to approach the "over the top" position. The fascia lata is then dissected before entering the posterior aspect of the joint by means of digital dissection until the upper posterior aspect of the intercondylar notch is palpated (Fig 5). The posterior capsule is then opened under arthroscopic view



**Fig 5.** Left knee flexed 90°. Lateral femoral approach. (A) Supracondylar incision of the skin and the iliotibial band. Asterisk: iliotibial band. (B) Retrocapsular digital blunt dissection. (LE, lateral epicondyle.)



**Fig 6.** Hook with an eyelet in its tip for the "over the top" pass of the traction thread.

(transtendinous portal), with the aid of a hook (inserted over the lateral epicondyle) with an eyelet in its tip, through which a looped thread is inserted (Fig 6). The tip of the hook is placed medial to the ACL remnant when it corresponds to the posterolateral bundle, and laterally when the anteromedial one is intact (Fig 7). Once inside the joint, one end of the looped thread is withdrawn via the tibial tunnel with the aid of a grasper.

**Graft Pass, Femoral Tunnel Performance, and Fixation**

The graft is introduced from caudal to cranial. The graft's sutures are inserted through the looped thread, which is pulled from the lateral aspect of the knee and the graft is recovered through the lateral approach (Fig 8).

Using the same lateral femoral approach made to reach the "over the top" position, a guide pin is placed in the metaphysis of the femur in the caudocranial, posteroanterior, and lateromedial direction until the tip of the pin comes out of the skin; a tunnel of the same diameter of the graft is performed using a cannulated drill bit (Fig 9).

The graft's sutures are passed through the eyelet at the bottom of the guide pin, which is pulled from its tip from lateral to medial, passing said sutures through the femoral tunnel (Fig 10).

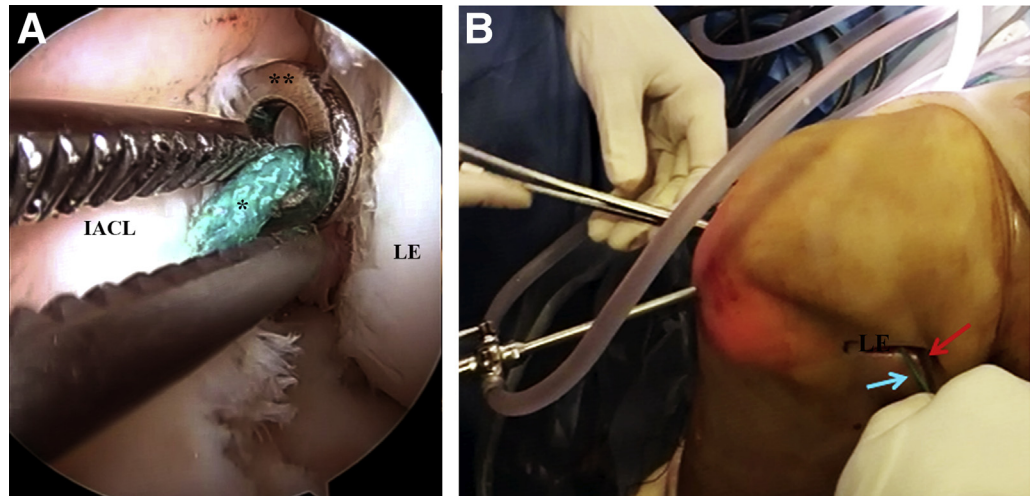
The suspension device with its expansion piece is attached to the anterior cortex of the tibia, and gentle traction of the graft's sutures is applied. Tibial fixation is achieved with the suspension device and its augmentation piece (ProCinch and ProCinch XL; Stryker) (Fig 11). An interference screw (Biosteon; Stryker) 1 mm wider than the graft is introduced in the femoral tunnel from lateral to medial while keeping traction (Fig 12). Different flexion angles of the knee are set when introducing the screw, according to the affected bundle: 10° of flexion is used when the anteromedial bundle is reconstructed, and 60° when the posterolateral one is involved.

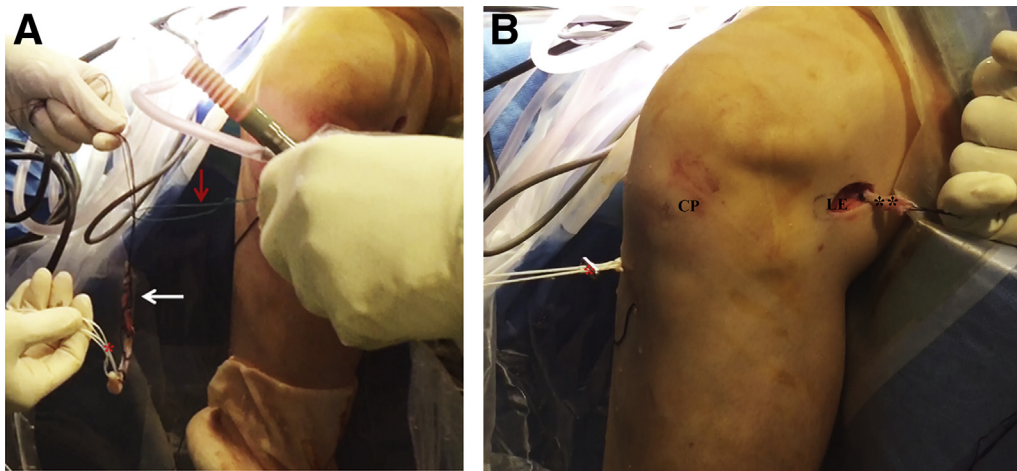
**Discussion**

Although the treatment of partial ACL tears remains controversial, there seems to be a specific indication for partial reconstruction in those patients with clear instability, associated injuries, and high-risk lifestyle.<sup>6-8</sup>

The technique described in this Technical Note has as the main features the femoral pass of the graft through the "over the top" position and the inverted fixation, using a suspension device for tibial fixation and an interference screw for the femoral one.

**Fig 7.** Left knee flexed 90°. "Over the top" pass of the traction thread. (A) Intra-articular view (arthroscope through the central portal; clamp through the anteromedial one); asterisk: traction thread; double asterisk: hook for the "over the top" pass. (B) Outside view; red arrow: "over the top" hook; blue arrow: traction thread. (IACL, intact anterior cruciate ligament; LE, lateral epicondyle.)



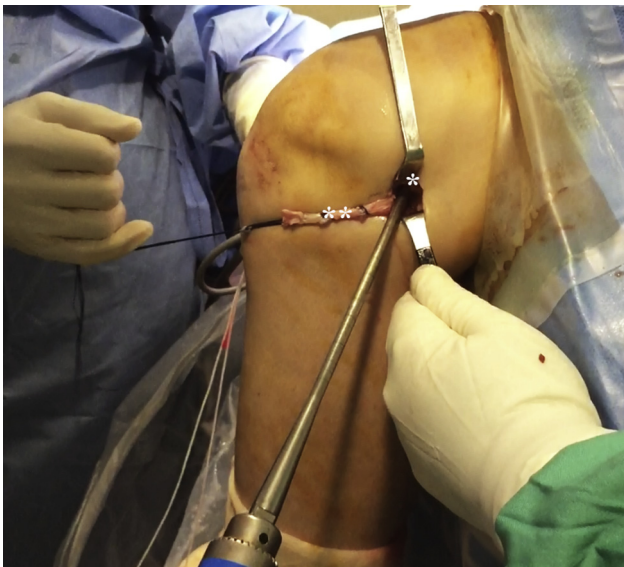

**Fig 8.** Left knee flexed 90°. Pass of the graft. (A) The graft's sutures are threaded through the looped thread; red arrow: looped thread; white arrow: graft; asterisk: adjustable cortical suspension device. (B) View of the graft passed through the tibia and the "over the top" position; asterisk: adjustable cortical suspension device attached to its expansion piece; double asterisk: doubled semitendinosus graft. (CP, central portal; LE, lateral epicondyle.)

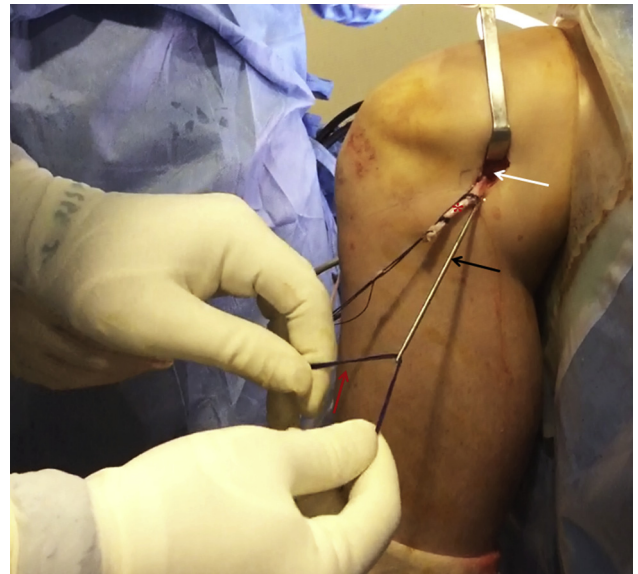
The "over the top" pass of the graft is justified by the need to preserve as much ACL intact remnant as possible; it is more difficult to achieve when performing a tunnel on the femur, especially with the inside-out technique.<sup>12</sup> Otherwise, good mid-term outcomes have been published using the "over the top" position for femoral fixation in partial ACL reconstructions.<sup>13,14</sup>

This technique is an evolution of the one previously used by the authors,<sup>13</sup> in which the graft's length

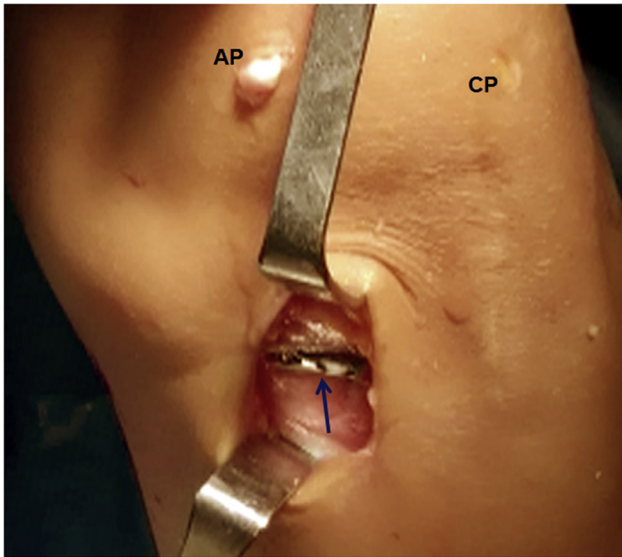
needed was sometimes longer than the length obtained. This fact could be avoided using a suspension device, whose loop's length can be increased if needed, enlarging the construct's length. The suspension device is placed in the tibial tunnel because of the absence of a femoral one. On the other hand, femoral fixation of the graft was previously performed using a metal staple, which could result in a less resistant



**Fig 9.** Left knee flexed 90°. Drilling of the supracondylar femoral tunnel in the caudocranial, lateromedial, and posterior-anterior direction. Asterisk: supracondylar entrance of the drill bit; double asterisk: graft.



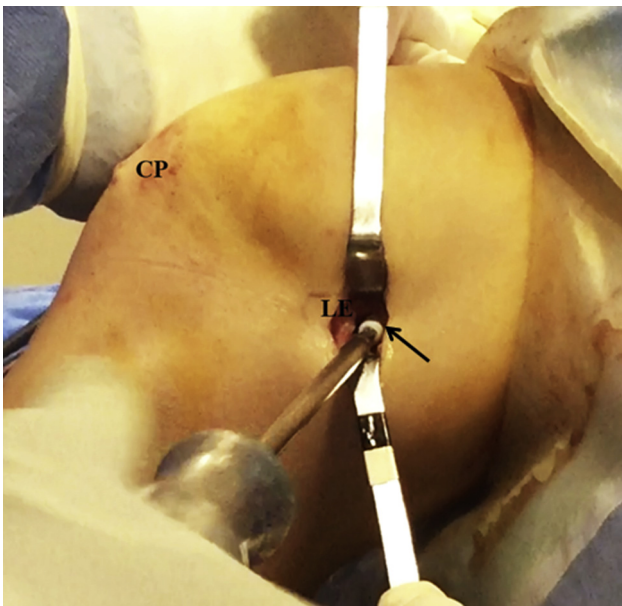
**Fig 10.** Left knee flexed 90°. The graft's sutures are threaded through the eyelet at the bottom of the guide pin which will pull them into the supracondylar femoral tunnel for the pass of the graft; red arrow: graft's sutures; black arrow: guide pin; white arrow: entrance of the femoral tunnel; asterisk: graft.



**Fig 11.** Left knee flexed 90°. Extra-articular view of the tibial anteromedial approach. Cortical suspension device with its augmentation piece, attached to the anteromedial tibial cortex. Arrow: cortical suspension device. (AMP, anteromedial portal; CP, central portal.)

construct; using an interference screw in the supracondylar region guarantees an adequate strength for femoral fixation.

Unlike the technique used by Buda et al.,<sup>14</sup> in which STT and gracilis tendons are used, in this technique,



**Fig 12.** Left knee flexed 10°. Supracondylar femoral fixation with an interference screw (arrow), performed through the lateral approach. (CP, central portal; LE, lateral epicondyle.)

only 1 tendon is sacrificed (STT), using it in a doubled fashion.

### References

1. Sonnery-Cottet B, Colombet P. Partial tears of the anterior cruciate ligament. *Orthop Traumatol Surg Res* 2016;102: S59-S67 (suppl).
2. Matsushita T, Kuroda R, Nishizawa Y, et al. Clinical outcomes and biomechanical analysis of posterolateral bundle augmentation in patients with partial anterior cruciate ligament tears. *Knee Surg Sports Traumatol Arthrosc* 2017;25:1279-1289.
3. Noyes FR, Mooar LA, Moorman CT III, McGinniss GH. Partial tears of the anterior cruciate ligament. Progression to complete ligament deficiency. *J Bone Joint Surg Br* 1989;71:825-833.
4. Crain EH, Fithian DC, Paxton EW, Luetzow WF. Variation in anterior cruciate ligament scar pattern: Does the scar pattern affect anterior laxity in anterior cruciate ligament-deficient knees? *Arthroscopy* 2005;21:19-24.
5. DeFranco MJ, Bach BR Jr. A comprehensive review of partial anterior cruciate ligament tears. *J Bone Joint Surg Am* 2009;91:198-208.
6. Temponi EF, de Carvalho LH Jr, Sonnery-Cottet B, Chambat P. Partial tearing of the anterior cruciate ligament: Diagnosis and treatment. *Rev Bras Ortop* 2015;50:9-15.
7. Lorenz S, Imhoff AB. Reconstruction of partial anterior cruciate ligament tears. *Oper Orthop Traumatol* 2014;26: 56-62.
8. Tjoumakaris FP, Donegan DJ, Sekiya JK. Partial tears of the anterior cruciate ligament: Diagnosis and treatment. *Am J Orthop (Belle Mead NJ)* 2011;40:92-97.
9. Nakamae A, Ochi M, Deie M, et al. Biomechanical function of anterior cruciate ligament remnants: How long do they contribute to knee stability after injury in patients with complete tears? *Arthroscopy* 2010;26:1577-1585.
10. Kannus P, Järvinen M. Conservatively treated tears of the anterior cruciate ligament. Long-term results. *J Bone Joint Surg Am* 1987;69:1007-1012.
11. Yazdi H, Torkaman A, Ghahramani M, Moradi A, Nazarian A, Ghorbanhoseini M. Short-term results of anterior cruciate ligament augmentation in professional and amateur athletes. *J Orthop Traumatol* 2017;18:171-176.
12. Rao AJ, Cvetanovich GL, Zuke WA, Go B, Forsythe B. Single-bundle augmentation for a partial tear of the anterior cruciate ligament. *Arthrosc Tech* 2017;6:e853-e857.
13. Serrano-Fernandez JM, Espejo-Baena A, Martin-Castilla B, de La Torre-Solis F, Mariscal-Lara J, Merino-Ruiz ML. Augmentation technique for partial ACL ruptures using semitendinosus tendon in the over-the-top position. *Knee Surg Sports Traumatol Arthrosc* 2010;18: 1214-1218.
14. Buda R, Ruffilli A, Parma A, et al. Partial ACL tears: Anatomic reconstruction versus nonanatomic augmentation surgery. *Orthopedics* 2013;36:e1108-e1113.