

MINI-REVIEW

Wide Complex Tachycardia Differentiation: A Reappraisal of the State-of-the-Art

Anthony H. Kashou, MD; Peter A. Noseworthy, MD; Christopher V. DeSimone, MD, PhD; Abhishek J. Deshmukh, MBBS; Samuel J. Asirvatham, MD; Adam M. May, MD

ABSTRACT: The primary goal of the initial ECG evaluation of every wide complex tachycardia is to determine whether the tachyarrhythmia has a ventricular or supraventricular origin. The answer to this question drives immediate patient care decisions, ensuing clinical workup, and long-term management strategies. Thus, the importance of arriving at the correct diagnosis cannot be understated and has naturally spurred rigorous research, which has brought forth an ever-expanding abundance of manually applied and automated methods to differentiate wide complex tachycardias. In this review, we provide an in-depth analysis of traditional and more contemporary methods to differentiate ventricular tachycardia and supraventricular wide complex tachycardia. In doing so, we: (1) review hallmark wide complex tachycardia differentiation criteria, (2) examine the conceptual and structural design of standard wide complex tachycardia differentiation methods, (3) discuss practical limitations of manually applied ECG interpretation approaches, and (4) highlight recently formulated methods designed to differentiate ventricular tachycardia and supraventricular wide complex tachycardia automatically.

Key Words: ECG ■ supraventricular tachycardia ■ ventricular tachycardia ■ wide complex tachycardia

Wide complex tachycardia (WCT) is a general term that broadly denotes the presence of ventricular tachycardia (VT) or supraventricular WCT (SWCT). As such, clinicians who encounter patients with a WCT must consider a broad variety of attributable causes including VT, SWCT with pre-existing or functional aberrancy, SWCT developing from impulse propagation using atrioventricular accessory pathways (ie, preexcitation), rapid ventricular pacing, and tachyarrhythmias coinciding with toxic-metabolic QRS duration widening (eg, hyperkalemia or antiarrhythmic drug toxicity). Yet, without question, the most critical task for the clinician is to determine whether the tachyarrhythmia has a ventricular or supraventricular origin. Accurate discrimination of VT and SWCT is incredibly vital as it impacts immediate patient care decisions, ensuing clinical workup, and long-term management strategies. Hence, proper patient management heavily relies on whether clinicians are equipped with and appropriately apply effective and reliable means to distinguish VT and SWCT.

After decades of rigorous research, the quest for an effective, simplified, and practical means to non-invasively differentiate WCTs has brought forth an ever-expanding plethora of manually applied ECG interpretation methods.^{1–10} While manual methods have proven their value in research settings, and can be readily adopted by clinicians, arriving at correct and timely VT or SWCT diagnoses remains a problematic undertaking—even among experienced electrocardiographers. Recently, research has shown that accurate WCT differentiation can even be accomplished by automated approaches implemented by computerized ECG interpretation (CEI) software programs.^{11,12}

In this review, we provide an in-depth analysis of traditional and contemporary methods to differentiate WCTs. In doing so, we: (1) review hallmark ECG characteristics used for VT and SWCT differentiation, (2) examine the conceptual and structural design of standard WCT differentiation methods, (3) highlight practical limitations of manually applied ECG

Correspondence to: Adam M. May, MD, 660 South Euclid Avenue, CB 8086, St. Louis, MO 63110. E-mail: may.adam@wustl.edu

For Sources of Funding and Disclosures, see page 9.

© 2020 The Authors. Published on behalf of the American Heart Association, Inc., by Wiley. This is an open access article under the terms of the Creative Commons Attribution-NonCommercial License, which permits use, distribution and reproduction in any medium, provided the original work is properly cited and is not used for commercial purposes.

JAHA is available at: This is an open access article under the terms of the Creative Commons Attribution-NonCommercial License, which permits use, distribution and reproduction in any medium, provided the original work is properly cited and is not used for commercial purposes.

Nonstandard Abbreviations and Acronyms

CEI	computerized ECG interpretation
LR	likelihood ratio
RWPT	R wave peak time
SWCT	supraventricular wide complex tachycardia
V_i	voltage excursion during the initial 40 ms of the QRS complex
V_t	voltage excursion during the terminal 40 ms of the QRS complex
VT	ventricular tachycardia
WCT	wide complex tachycardia

interpretation approaches, and (4) discuss recently devised methods designed to differentiate WCTs automatically.

HALLMARK ECG CRITERIA

In general, WCT differentiation methods comprise one or more ECG criteria that embody distinctive electrophysiologic properties of VT and SWCT. Available methods utilize ECG interpretation criteria that examine the: (1) relationship of atrial and ventricular depolarization, (2) morphological configuration of QRS complexes in specific ECG leads (ie, V1–V2 and V6), (3) WCT QRS duration, (4) chest lead concordance, (5) mean electrical axis (ie, QRS axis), (6) differences in ventricular activation velocity, and (7) dissimilarities compared with the baseline ECG. While all have proven their value in distinguishing VT and SWCT, no single criterion or collection of criteria promises diagnostic certainty.

Atrioventricular Dissociation

Wellens and colleagues¹ highlighted the importance of atrioventricular dissociation in 1978, which later matured into one of the most trusted ECG criteria to secure VT diagnoses. As a general rule, VT may be confirmed once atrioventricular dissociation is assuredly identified, especially when the ventricular rate exceeds the atrial rate. Unsurprisingly, several WCT differentiation methods include atrioventricular dissociation as a key VT diagnostic criterion.^{2,3,8,9} However, although atrioventricular dissociation may be quite valuable in establishing VT diagnoses, its absence does not rule out VT since it is often not electrocardiographically apparent, even among patients with known VT.

By definition, atrioventricular dissociation is present when a self-governing ventricular rhythm autonomously subsists the atrial rhythm. Classically, atrioventricular dissociation is characterized by a series of QRS

complexes uncoupled from “dissociated” P waves (Figure 1). When interpreting a 12-lead ECG displaying VT, atrioventricular dissociation may be recognized as interspersed P waves nestled between or hidden amidst overlapping QRS complexes and T waves. Less commonly, atrioventricular dissociation manifests as “capture” or “fusion” beats—each of which depict varying degrees to which a supraventricular impulse contributes to ventricular depolarization. In the case of a capture beat, an ideally timed supraventricular impulse seizes ventricular depolarization entirely and produces a single QRS complex resembling the patient’s baseline rhythm. In the case of a fusion beat, ventricular depolarization wavefronts emanating from supraventricular and ventricular sources collide and create a hybrid QRS complex that shares the ventricular depolarization characteristics of the VT and baseline rhythm.

Historically, the identification of atrioventricular dissociation can be quite challenging. In general, atrioventricular dissociation may be recognized in roughly one fifth of VTs recorded by 12-lead ECG. For many cases, VT will coexist with an atrial arrhythmia (eg, atrial fibrillation) that lacks organized atrial depolarization (ie, P waves). On other occasions, atrioventricular dissociation simply cannot be recognized because of overlying QRS complexes and T waves that obscure dissociated P wave activity. Furthermore, it is essential to recognize that up to approximately half of VTs will demonstrate retrograde ventriculoatrial conduction,¹ wherein ventricular impulses conduct retrograde through the His-Purkinje system to depolarize the atria. In such cases, VTs will not exhibit atrioventricular dissociation; instead, they demonstrate a regular (eg, 1:1 ventriculoatrial conduction) or an erratic (eg, ventriculoatrial conduction with variable block) relationship.

Morphological Criteria

Meticulous examination of QRS configurations recorded in particular ECG leads (ie, V1–V2 and V6) may provide essential clues as to whether a WCT has a ventricular or supraventricular origin. The pioneering works put forth by Sandler and Marriott,¹³ Wellens et al¹, and Kindwall et al¹⁴—collectively known as the “classical morphological criteria”—have added considerable value towards the diagnostic evaluation of WCTs (Figure 1).

In general, the primary purpose of using the morphological criteria is to identify QRS configurations that are consistent or inconsistent with aberrant conduction. If a WCT demonstrates a QRS configuration incompatible with typical right or left bundle branch block patterns, VT is the most likely diagnosis. For example, VT would be the most likely diagnosis for a WCT demonstrating atypical right bundle block characteristics (eg,

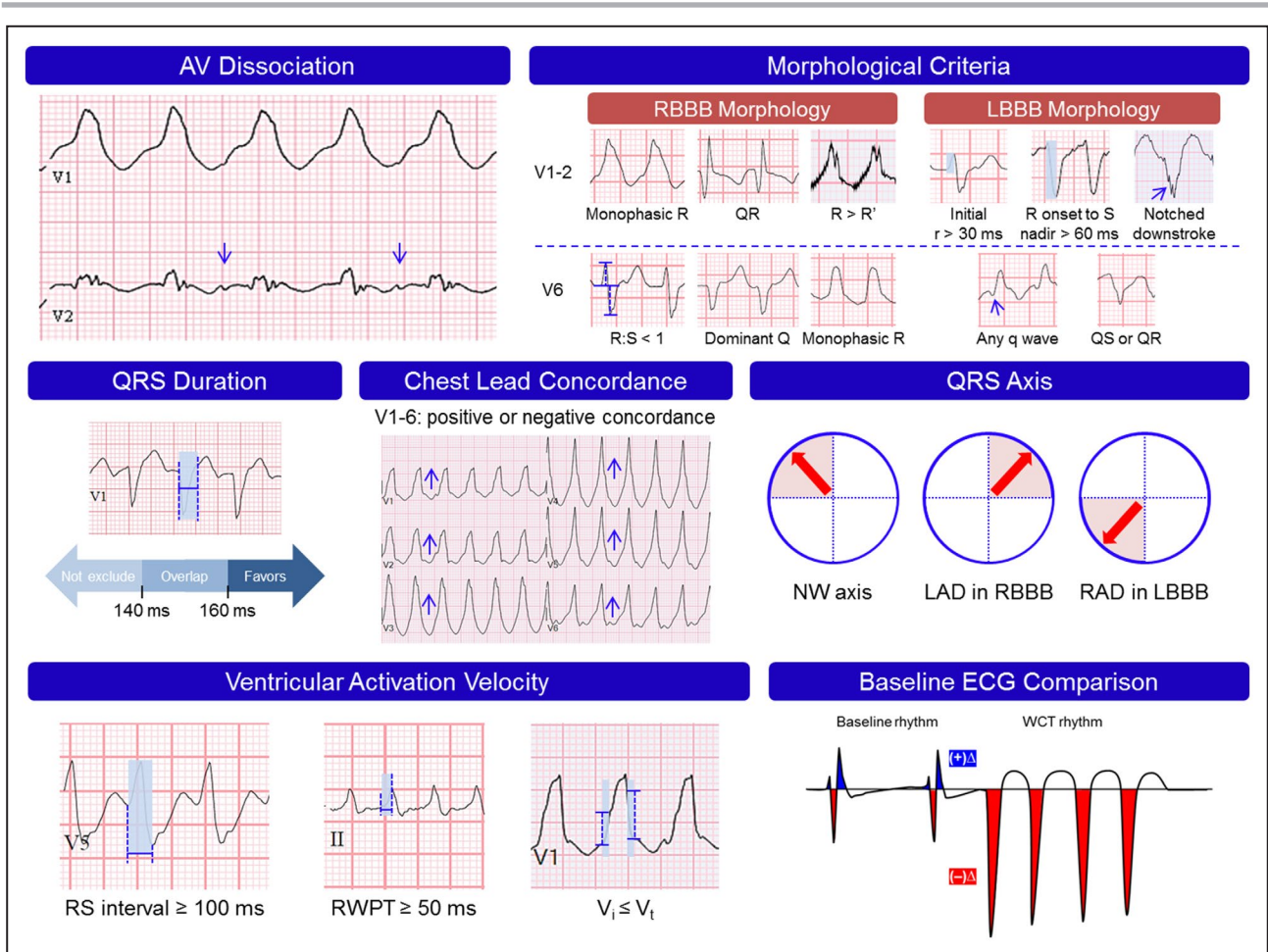


Figure 1. Hallmark ECG features of ventricular tachycardia (VT). AV indicates atrioventricular; LAD, left axis deviation; LBBB, left bundle branch block; NW, northwest; RAD, right axis deviation; RBBB, right bundle branch block; RWPT, R wave peak time; and WCT, wide complex tachycardia.

monophasic R wave in V1 or V2 and QS pattern in V6). Conversely, if a WCT displays QRS configurations representative of typical right and left bundle aberrancy, SWCT is the most likely diagnosis. For example, SWCT would be the most probable diagnosis for WCTs demonstrating a classic left bundle branch block pattern (eg, r wave onset to S wave nadir <60 ms in V1 or V2 and notched monophasic R wave in V6). There are only a few notable exceptions to this concept, including bundle branch reentry or fascicular VTs—each of which rapidly engage the His-Purkinje network and can result in fairly typical “aberrant” morphologies.

QRS Duration

Ordinarily, VT primarily relies on an inefficient means to depolarize the ventricular myocardium (ie, cardiomyocyte-to-cardiomyocyte conduction). As a result, VT commonly expresses longer QRS durations than SWCT. This distinction was verified initially by Wellens and colleagues,¹ and later spurred interest in proposed WCT QRS duration cutoffs

to define VT diagnoses: QRS >140 ms for WCTs with right bundle branch block pattern and QRS >160 ms for WCTs with left bundle branch block pattern.¹⁵ However, since VT and SWCT occupy broad and overlapping QRS duration ranges, the sole use of WCT QRS duration cutoffs to differentiate WCTs is unsatisfactory. A substantial proportion of SWCTs will display QRS durations >160 ms, especially among patients with ongoing antiarrhythmic drug use, electrolyte disturbances, dramatic conduction delays, or severe underlying structural heart disease or cardiomyopathies. On the contrary, many patients demonstrating idiopathic VT variants or VTs that arise from within or rapidly engage the His-Purkinje system demonstrate QRS durations <140 ms (Figure 1). In rarer cases, VTs may demonstrate substantial impulse propagation within the conduction system and express QRS durations <120 ms (eg, fascicular VT), thereby not fulfilling the technical definition of WCT (ie, heart rate ≥100 beats per minute and QRS duration ≥120 ms).

Chest Lead Concordance

Following the keen observations described originally by Marriott,¹⁶ chest lead concordance has endured as a strong distinguishing feature of VT. According to its strict definition, concordance is present when QRS complexes in all 6 precordial leads (V1–V6) uniformly display a monophasic pattern having the same polarity (ie, “R” for positive concordance and “QS” for negative concordance) (Figure 1). In general, WCTs demonstrating positive concordance most often arise from VT originating from the posterobasal left ventricle. On the other hand, WCTs demonstrating negative concordance are practically diagnostic for VT originating for the anterolateral left ventricle.

For practical use, chest lead concordance is a highly specific (specificity >90%) but rather insensitive (sensitivity <20%) diagnostic determinant for VT. Thus, VT may be confirmed with near certainty if concordance is present; however, if concordance is absent, VT cannot be ruled out. Furthermore, it is worth noting that SWCT may demonstrate concordance patterns in a variety of rare circumstances. For example, SWCTs with positive concordance may occur in the setting of patients demonstrating preexcitation from left posterior or left lateral accessory pathways. Alternatively, although VT is nearly always responsible for a WCT having negative concordance, unusual exceptions include rare SWCTs arising from extranodal accessory pathways (ie, Mahaim connections) or those developing among patients with flecainide toxicity or chest wall deformities.¹⁷

QRS Axis

Occasionally, WCT QRS axis offers an effective means to distinguish VT from SWCT. To illustrate, we must acknowledge that many of the dissimilarities between VT and SWCT relate to the site of origin and the summated direction of impulse propagation. This difference is often responsible for substantial differences in the resultant mean electrical vector, including its frontal plane orientation (ie, QRS axis). In general, most forms of SWCT with aberrancy (eg, left bundle branch block and right bundle branch block) produce a constrained range of mean electrical vectors permitted by their representative conduction abnormalities. On the other hand, VT may demonstrate a nearly limitless variety of mean electrical vectors, many of which residing outside of the expected range for SWCT. For example, a scar-related VT mapped to the anterolateral wall of the left ventricle may produce a WCT having an atypical right bundle branch block pattern and rightward and superior QRS axis—a mean electrical vector orientation not ordinarily observed for SWCTs with right bundle branch block aberrancy.

In 1988, Akhtar and colleagues¹⁵ verified that a rightward superior QRS axis (ie, northwest axis) between -90° and -180° is highly predictive of VT (Figure 1). Subsequently, several manually applied WCT differentiation methods, including Vereckei aVR algorithm,⁶ Jastrzebski VT score,⁸ and the limb lead algorithm,¹⁰ have knowingly incorporated an ECG criterion (ie, dominant R wave in lead aVR) that essentially employs QRS axis as a key diagnostic determinant. Several authors have also shown that the coexistence of left- or right-axis deviation with right or left bundle branch block, respectively, to be quite specific for VT.^{1,15,18}

Differences in Ventricular Activation Velocity

Careful inspection of the first components of the QRS complex, along with its comparison to its terminal segments, as a means to distinguish VT and SWCT, has been adopted by a wide variety of WCT differentiation criteria and algorithms.^{2,5–7,14,19} The basis for this examination stems from the fact that SWCT and VT ordinarily demonstrate marked differences in the manner to which they commandeer or engage the His-Purkinje network. For example, an SWCT with left bundle branch block aberrancy will commonly display rapid initial QRS deflections (eg, r wave duration <30 ms in V1 or V2, or an RS interval <100 ms for QRS complexes in the precordial leads [V1–V6]) that arise from rapidly depolarized myocardial segments stimulated by preserved components of the His-Purkinje network (ie, right bundle branch).^{2,14} Conversely, a VT wavefront that propagates and spreads from a site of origin remote from specialized conduction tissue, and thereby must utilize slower cardiomyocyte-to-cardiomyocyte conduction, is expected to demonstrate delayed or “slurred” initial components of the QRS complex (eg, R wave peak time [RWPT] in lead II ≥ 50 ms, or RS interval ≥ 100 ms in any of the precordial leads [V1–V6]).^{2,7} However, once the VT impulse engages the conduction system, and swiftly activates the remainder of the ventricular myocardium, the terminal components of the QRS complex will correspondingly demonstrate more rapid or “sharper” deflections compared with what was observed at the beginning of the QRS complex (eg, ratio of the voltage excursion during the initial [V_i] and terminal [V_t] 40 ms of the QRS complex <1) (Figure 1).^{5,6}

Comparison to the Baseline ECG

The value of comparing a patient’s WCT and baseline ECG should not be underestimated. In 1985, Dongas et al²⁰ confirmed that WCTs with unchanged QRS

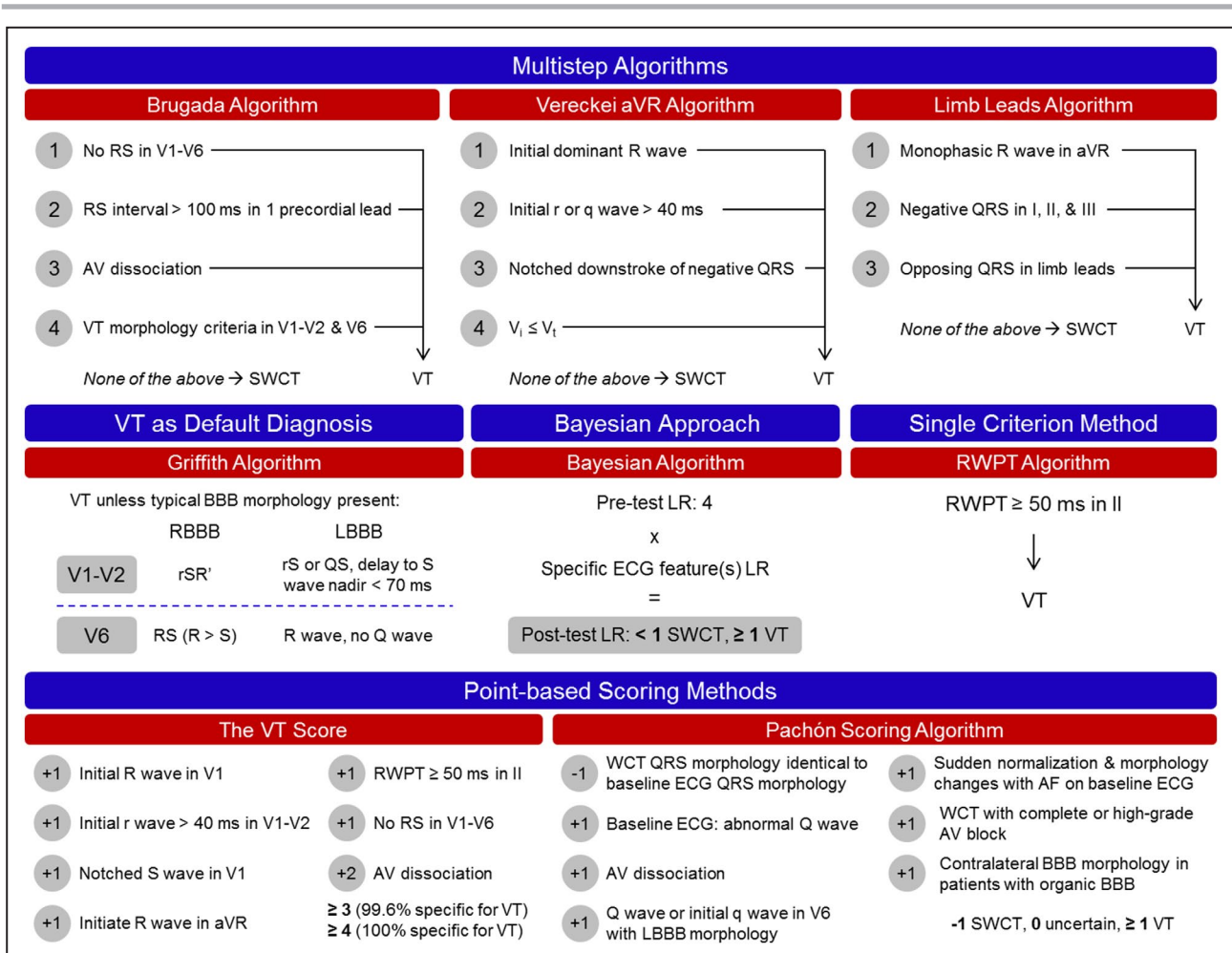


Figure 2. Various wide complex tachycardia (WCT) differentiation algorithmic designs and algorithms.

AF indicates atrial fibrillation; AV, atrioventricular; LBBB, left bundle branch block; LR, likelihood ratio; RBBB, right bundle branch block; RWPT, R wave peak time; SWCT, supraventricular wide complex tachycardia; and VT, ventricular tachycardia.

configurations in leads V1, II, and III compared with the preexisting bundle branch block during sinus rhythm were nearly always SWCT, while WCTs with noticeably different QRS configurations were usually VT. Later, in 1991, the multivariate analysis put forth by Griffith and colleagues²¹ verified that substantial deviation in QRS axis (ie, QRS axis change ≥40°) compared with the baseline ECG was one of the most predictive ECG features to diagnose VT. More recently, Pachon et al⁹ utilized comparisons of QRS morphology between the WCT and the baseline ECG as one of the weighty diagnostic determinants within their point-based algorithm.

Recently, we introduced novel WCT differentiation methods,^{11,12,22} which leverage the magnitude of change between the WCT and baseline ECG as a means to effectively distinguish VT and SWCT (Figure 1). We described how universally available computerized measurements derived from CEI software may be used to precisely quantify specific changes between the WCT and baseline rhythms.^{11,12,22} For example, the so-called WCT

Formula uses quantifiable QRS amplitude changes (eg, frontal and horizontal percent amplitude change) between paired WCT and baseline ECGs to establish an estimated VT probability.¹¹ Similarly, the VT prediction model utilizes measurable changes in the QRS axis, T axis, and QRS duration between paired WCT and baseline ECGs to determine VT likelihood.¹² Such methods may be readily embedded into automated ECG interpretation software systems to reduce the time necessary for an accurate diagnosis. However, it must be acknowledged that a distinct disadvantage of these novel approaches is that they require a baseline ECG (ie, an ECG recorded before or after the WCT event) for their implementation.

STRATEGIC BLUEPRINTS FOR TRADITIONAL METHODS

Decades of clinical research has brought forth a wide variety of thoughtfully designed methods to differentiate VT and SWCT. Separate from choosing the ideal

electrophysiological determinants to secure accurate WCT differentiation, algorithm creators were accountable for devising the organizational structure and operative mechanics that will enable their algorithm's generalized use. In the following sections, we: (1) review the most common algorithm designs, (2) discuss the overarching rationale behind their formulation, and (3) examine the unique advantages and limitations for each diagnostic approach.

Multistep Algorithms

Without question, the most commonly utilized approaches to differentiate WCTs are the multistep decision-tree algorithms, including the Brugada,² Vereckeï aVR,⁶ and limb lead algorithms¹⁰ (Figure 2). In general, multistep algorithms prompt users to address a series of sequentially applied inquiries, with each step requesting the ECG interpreter to determine whether a highly specific attribute of VT is present or absent. If an affirmative response is rendered at any particular algorithm step, the algorithm's application is complete and a VT diagnosis is secured. On the other hand, before SWCT is diagnosed, the ECG interpreter must navigate through the entire algorithm and confirm that each step warrants a negative response. In other words, SWCT diagnoses may only be reached once all highly specific attributes for VT, examined by the particular multistep algorithm, are absent.

In the early 1990s, Brugada and colleagues² were the first to conceptualize, organize, and then introduce a multistep decision-tree algorithm design for WCT differentiation. Their seminal work provided clinicians with clear and straightforward steps to reach a definitive diagnosis. The authors hoped that the multistep decision-tree design would help resolve more ambiguous cases in which the WCT shares features supportive of SWCT and VT.

Since their inception, multistep algorithms have served as an excellent means for clinicians to wholly commit to VT or SWCT diagnosis with reasonably good diagnostic accuracy. Nevertheless, there are notable limitations worth acknowledging. For example, one common problem is that clinicians are ordinarily left unapprised of the likelihood that their VT or SWCT diagnoses are accurate. Unless clinicians (1) are sufficiently informed of the performance metrics (eg, positive likelihood ratio [LR]) afforded by the algorithm step responsible for the diagnosis, and (2) accurately gauge the patient's pretest probability for VT or SWCT, they will not have a precise determination of whether their diagnosis is, in fact, correct. Another limitation is that multistep algorithms purposely examine a narrower scope of ECG attributes. Although restricting the number of criteria evaluated

by an algorithm helps ensure that it is readily recalled and easily implemented, this strategy ultimately increases the risk for overlooking other relevant diagnostic ECG findings. For instance, clinicians who choose to exclusively use the Vereckeï aVR algorithm⁶ may paradoxically threaten near-certain VT diagnoses for WCTs demonstrating clear atrioventricular dissociation.

VT as Default Diagnosis

In 1994, Griffith et al³ introduced an alternative WCT differentiation method (ie, Griffith algorithm). For this algorithm, the authors devised a reversed strategy: VT is the default diagnosis, and SWCT diagnoses may be reached only when the classical criteria of typical left or right bundle branch block is present (Figure 2). According to their algorithm, an SWCT diagnosis may be made for WCTs displaying findings consistent with typical left bundle branch block (ie, rS or QS wave in leads V1 and V2, r wave onset to S wave nadir <70 ms in leads V1 and V2, and monophasic R wave without a q wave in lead V6) or right bundle branch block (ie, rSR' morphology in lead V1, RS complex in lead V6, and R wave amplitude greater than S wave amplitude in lead V6). Thus, if a WCT does not demonstrate QRS configurations classic for SWCT because of aberrancy, VT is the elected diagnosis. Hence, instead of relying on highly specific ECG criteria to rule in VT, highly specific ECG criteria are used to rule in SWCT.

The distinct advantage gained by using the Griffith algorithm is that the majority of VTs will be correctly identified. However, although this reversed approach ensures strong diagnostic sensitivity for VT, it does so at the expense of its diagnostic specificity. In other words, since the Griffith algorithm deliberately limits the means to how an SWCT diagnosis is reached, a substantial number of SWCTs may be misclassified as VT—especially those that demonstrate nonclassical aberrancy or preexcitation.

Bayesian Approach

In 2000, Lau et al⁴ introduced a novel WCT differentiation method centered around the use of LRs to distinguish VT and SWCT. The so-called Bayesian algorithm couples a predetermined "pretest odds of VT" with the predictive indices (ie, LRs) of a wide assortment of ECG criteria to secure a "posttest odds of VT." For practical use, the Bayesian algorithm assumes a pretest odds (ie, positive LR of 4) and multiplies this value by a compilation of other LRs, each denoting the presence or absence of specific ECG criterion (eg, positive LR of 50 for a monophasic QS in lead V6) (Figure 2). Once the serial multiplication of LRs is complete, the posttest odds of VT (ie, LR) is established. If the final LR is ≥ 1 ,

VT is the diagnosis; if the final LR is <1 , SWCT is the diagnosis.

By conducting this mathematical procedure for a wide variety ECG features, the Bayesian algorithm deliberately evades the 2 significant limitations that commonly thwart hierarchical multistep algorithms: (1) imperfect ascertainment (ie, presence or absence of certain ECG criteria cannot be confirmed), and (2) incomplete consideration of all relevant ECG features (eg, outright VT diagnosis reached after just one algorithm step). However, this method mandates that the interpreter engage in an intricate series of mathematical computations, which may be quite challenging to accomplish while under duress. Additionally, because the Bayesian algorithm considers each ECG criterion to be an independent variable, the assigned LRs for individual variables are most likely overvalued. As a result, the final LR rendered by the Bayesian algorithm may not accurately reflect the true likelihood for VT or SWCT diagnoses.

Single Criterion Method

In 2008, Pava and colleagues⁷ proposed that a single, stand-alone criterion may distinguish VT and SWCT accurately. In their analysis, they described the procedure of measuring the RWPT in lead II as a simple-to-use, highly specific, and highly sensitive means to discriminate VT from SWCT. As described by the authors, the RWPT represents the time elapsed between the QRS complex onset and peak of the first positive or negative deflection. According to the algorithm's design, if a WCT demonstrates an RWPT ≥ 50 ms, VT is diagnosed; alternatively, if a WCT demonstrates an RWPT < 50 ms, SWCT is diagnosed (Figure 2).

Unlike using a sequential series or compilation of ECG criteria to differentiate WCTs, the principal advantage of using a stand-alone criterion is that it may be readily recalled and promptly implemented by clinicians wishing to secure rapid VT or SWCT diagnoses. However, notwithstanding the impressive diagnostic performance first reported for the RWPT criterion, it is now abundantly clear that solely relying upon highly specific but nonsensitive criteria to differentiate WCTs will substantially jeopardize clinicians' ability to recognize VT.^{8,10,23} It should be noted that similar diagnostic limitations would be readily observed for other criteria having exceptionally strong specificity but limited sensitivity for VT (eg, atrioventricular dissociation).

Point-Based Scoring Methods

In many cases, VT and SWCT cannot be confidently distinguished using 12-lead ECG interpretation alone. Occasionally, standard criteria to establish VT

diagnoses may not be unequivocally present or absent (eg, "Are those small deflections dissociated P waves or ECG artifact?"), and manual measurements essential for establishing the correct diagnosis may be at the margin of predefined thresholds (eg, "Is the RS interval convincingly < 100 ms or ≥ 100 ms?"). Additionally, there are occasions where criteria tend to be quite vulnerable to human error and imprecision (eg, measurement of V_r/V_t for minuscule QRS complexes in lead aVR). Furthermore, it is not rare for WCT to simultaneously possess ECG characteristics consistent with both VT and SWCT. Finally, we must also not overlook that many diagnostically challenging VT subtypes (eg, fascicular VT or bundle branch reentry) routinely escape ECG criteria emphasized by standard WCT differentiation methods.

As a result of the aforementioned diagnostic challenges, it is easy to see why subscribing to one or more WCT methods that wholly commit to an absolute VT or SWCT diagnosis is problematic. Consequently, several authors chose to devise an alternative approach to differentiating WCTs (ie, point-based algorithms) (Figure 2).^{8,9} Rather than absolutely committing to a definite SWCT or VT diagnosis for every WCT, point-based scoring methods purposely aim to identify WCTs with near-certain VT or SWCT diagnoses. For example, the point-based algorithm put forth by Jastrzebski et al⁸ (ie, the VT score) has demonstrated the capacity to confirm VT with near certainty for a substantial proportion of WCTs. According to their method's design, if a WCT possesses several highly specific criteria that summate into a high VT score, VT may be assuredly diagnosed (eg, positive predictive value of 100% for a VT score ≥ 4). A similar approach is used for the point-based algorithm described by Pachón and colleagues.⁹ According to their algorithm, a near-definite confirmation for VT (ie, positive predictive value of 100% for a score ≥ 2) or SWCT (ie, positive predictive value of 98% for a score -1) may be established for more than half of evaluated WCTs.⁹

PRACTICAL LIMITATIONS OF TRADITIONAL METHODS

The value of any diagnostic tool is dependent on the context in which it is used. Although individual WCT differentiation methods demonstrate their own unique shortcomings, the most emblematic weakness is that they wholly rely upon the ECG interpreter for their proper execution. In general, traditional ECG interpretation methods require clinicians to: (1) scrupulously examine patients' 12-lead ECG, and (2) carefully apply specific ECG criteria to establish a correct VT or SWCT diagnosis. Thus, manually

applied interpretation approaches are entirely dependent on the competency of the ECG interpreter, and therefore are quite vulnerable to improper application or abstained use. As a consequence, the generalized usage of manual ECG interpretation methods is unsurprisingly problematic—particularly for clinicians who must promptly diagnose and manage high-acuity patients.^{24–27}

Another relevant, but often overlooked, limitation stems from the fact that WCT differentiation methods were uniformly derived^{2,5–8,21} and independently validated^{8,23,25,26,28} using select investigational groups (ie, only patients who undergo an electrophysiology procedure) and controlled experimental conditions (ie, ECG interpretation performed by heart rhythm experts separated from the actual clinical settings in which the WCT presented). In fact, to date, only one validation study has assessed diagnostic performance using a broader collection of WCTs expected to be encountered in “real-life” clinical practice (ie, evaluating WCTs from patients with and without an accompanying electrophysiology study).²⁷ Consequently, it remains largely unknown whether the diagnostic performance of standard WCT differentiation algorithms or criteria would be sufficiently preserved when they are implemented in actual clinical practice. Unfortunately, a clear understanding of the overall practical value of conventional WCT differentiation methods will likely never be realized, as it would not be feasible to prospectively test their diagnostic performance within genuine clinical circumstances.

NOVEL METHODS AND FUTURE DIRECTIONS

Ideally, reliable WCT differentiation would occur immediately upon 12-lead ECG acquisition. Unfortunately, currently available CEI software programs have not yet achieved sufficient diagnostic accuracy for complex heart rhythms,²⁹ including WCT differentiation. As a result, clinicians must rely primarily on traditional manually applied ECG interpretation methods to render an accurate VT and SWCT diagnosis.

However, our recent work has challenged this limitation with several novel automated methods to distinguish VT and SWCT accurately.^{11,12} Through the use of readily available ECG data routinely processed by CEI software, well-established and mathematically formulated VT predictors (eg, frontal and horizontal percent amplitude change) may be used to yield accurate VT and SWCT predictions automatically. A central feature of these methods is that they provide clinicians an impartial estimation of VT likelihood (ie, 0.00% to 99.99% VT probability) through

the use of logistic regression modeling—a procedure that may operate independently of clinicians’ ECG interpretation competency. Prospective and forthcoming methods will similarly deliver unambiguous estimations of VT probability using machine learning modeling techniques (eg, artificial neural networks or random forests). By these means, clinicians will be able to integrate estimated VT probabilities with: (1) diagnoses reached by other WCT differentiation methods (eg, Brugada algorithm or the VT score), and (2) other particularly important diagnostic determinants (eg, history of structural heart disease or myocardial infarction). Once incorporated in CEI software platforms, automated methods may substantially help clinicians accurately distinguish VT and SWCT.

As we progress further into an era that will be dominated by automation and machine learning, the prospect of integrating sophisticated and highly accurate processes into computerized software to accurately differentiate WCTs is not far away. By solely analyzing 12-lead ECG recordings, machine learning techniques have already shown the ability to predict age and sex, as well as detect left ventricular systolic dysfunction and hypertrophic cardiomyopathy.^{30–33} Thus, it seems increasingly likely that automated processes that leverage the power of machine learning will one day help escape the limitations that plague traditional WCT differentiation approaches and enable highly accurate and timely WCT differentiation. It is through the development, refinement, and eventual integration of sophisticated automated approaches into CEI software we can hope to transform WCT differentiation into an antiquated diagnostic dilemma.

CONCLUSIONS

Decades of research have produced a rich literature base and an expanding myriad of diagnostic approaches to help clinicians accurately differentiate WCTs. Traditional manually applied WCT differentiation methods have proven their value in distinguishing the majority of WCTs; however, they uniformly depend on the ECG interpreter for their implementation, rendering them particularly susceptible to their improper execution or refrained utilization. Promising automated WCT differentiation methods that make use of CEI software programs are beginning to emerge, signaling the eventual introduction of novel alternative solutions to effectively distinguish VT and SWCT.

ARTICLE INFORMATION

Received March 19, 2020; accepted April 13, 2020.

Affiliations

From the Departments of Medicine (A.H.K.), and Cardiovascular Diseases (P.A.N., C.V.D., A.J.D., S.J.A.), Mayo Clinic, Rochester, MN; Cardiovascular Division, Washington University School of Medicine, St. Louis, MO (A.M.M.).

Sources of Funding

This work was supported by the Department of Cardiovascular Diseases at Mayo Clinic in Rochester, MN.

Disclosures

Adam May, Chris DeSimone, and Abhishek Deshmukh are obliged to disclose that they are “would-be” beneficiaries of intellectual property that is briefly discussed in the article. The remaining authors have no disclosures to report.

REFERENCES

- Wellens HJ, Bar FW, Lie KI. The value of the electrocardiogram in the differential diagnosis of a tachycardia with a widened QRS complex. *Am J Med.* 1978;64:27–33.
- Brugada P, Brugada J, Mont L, Smeets J, Andries EW. A new approach to the differential diagnosis of a regular tachycardia with a wide QRS complex. *Circulation.* 1991;83:1649–1659.
- Griffith MJ, Garratt CJ, Mounsey P, Camm AJ. Ventricular tachycardia as default diagnosis in broad complex tachycardia. *Lancet.* 1994;343:386–388.
- Lau EW, Pathamanathan RK, Ng GA, Cooper J, Skehan JD, Griffith MJ. The bayesian approach improves the electrocardiographic diagnosis of broad complex tachycardia. *Pacing Clin Electrophysiol.* 2000;23:1519–1526.
- Vereckei A, Duray G, Szenasi G, Altemose GT, Miller JM. Application of a new algorithm in the differential diagnosis of wide QRS complex tachycardia. *Eur Heart J.* 2007;28:589–600.
- Vereckei A, Duray G, Szenasi G, Altemose GT, Miller JM. New algorithm using only lead AVR for differential diagnosis of wide QRS complex tachycardia. *Heart Rhythm.* 2008;5:89–98.
- Pava LF, Perafan P, Badiel M, Arango JJ, Mont L, Morillo CA, Brugada J. R-wave peak time at DII: a new criterion for differentiating between wide complex QRS tachycardias. *Heart Rhythm.* 2010;7:922–926.
- Jastrzebski M, Sasaki K, Kukla P, Fijorek K, Stec S, Czarnecka D. The ventricular tachycardia score: a novel approach to electrocardiographic diagnosis of ventricular tachycardia. *Europace.* 2016;18:578–584.
- Pachón M, Arias MA, Salvador-Montañés Ó, Calvo D, Peñafiel P, Puchol A, Martín-Sierra C, Akerström F, Pachón N, Rodríguez-Padial L, et al. A scoring algorithm for the accurate differential diagnosis of regular wide QRS complex tachycardia. *Pacing Clin Electrophysiol.* 2019;42:625–633.
- Chen Q, Xu J, Gianni C, Trivedi C, Della Rocca DG, Bassiouny M, Canpolat U, Tapia AC, Burkhardt JD, Sanchez JE, et al. Simple electrocardiographic criteria for the rapid identification of wide QRS complex tachycardia: the new limb lead algorithm. *Heart Rhythm.* 2020;17:431–438.
- May AM, DeSimone CV, Kashou AH, Hodge DO, Lin G, Kapa S, Asirvatham SJ, Deshmukh AJ, Noseworthy PA, Brady PA. The WCT formula: a novel algorithm designed to automatically differentiate wide-complex tachycardias. *J Electrocardiol.* 2019;54:61–68.
- May AM, DeSimone CV, Kashou AH, Sridhar H, Hodge DO, Carter R, Lin G, Asirvatham SJ, Noseworthy PA, Deshmukh AJ. The VT prediction model: a simplified means to differentiate wide complex tachycardias. *J Cardiovasc Electrophysiol.* 2020;31:185–195.
- Sandler IA, Marriott HJ. The differential morphology of anomalous ventricular complexes of RBBB-type in lead V; ventricular ectopy versus aberration. *Circulation.* 1965;31:551–556.
- Kindwall KE, Brown J, Josephson ME. Electrocardiographic criteria for ventricular tachycardia in wide complex left bundle branch block morphology tachycardias. *Am J Cardiol.* 1988;61:1279–1283.
- Akhtar M, Shenasa M, Jazayeri M, Caceres J, Tchou PJ. Wide QRS complex tachycardia. Reappraisal of a common clinical problem. *Ann Intern Med.* 1988;109:905–912.
- Marriott HJ. Differential diagnosis of supraventricular and ventricular tachycardia. *Geriatrics.* 1970;25:91–101.
- Barold SS, Stroobandt RX, Herweg B. Limitations of the negative concordance pattern in the diagnosis of broad QRS tachycardia. *J Electrocardiol.* 2012;45:733–735.
- Miller JM, Das MK, Yadav AV, Bhakta D, Nair G, Alberte C. Value of the 12-lead ECG in wide QRS tachycardia. *Cardiol Clin.* 2006;24:439–451, ix–x.
- El Hajjaji I, Becker G, Kus T, Vinet A, Berkovitz A, Sturmer M. Novel criterion for the differential diagnosis of wide QRS complexes and wide complex tachycardia using the initial activation of QRS on leads V1 and V2: differential diagnosis of wide QRS based on V1-V2. *J Electrocardiol.* 2018;51:700–706.
- Dongas J, Lehmann MH, Mahmud R, Denker S, Soni J, Akhtar M. Value of preexisting bundle branch block in the electrocardiographic differentiation of supraventricular from ventricular origin of wide QRS tachycardia. *Am J Cardiol.* 1985;55:717–721.
- Griffith MJ, de Belder MA, Linker NJ, Ward DE, Camm AJ. Multivariate analysis to simplify the differential diagnosis of broad complex tachycardia. *Br Heart J.* 1991;66:166–174.
- May AM, DeSimone CV, Kashou AH, Hodge DO, Lin G, Kapa S, Asirvatham SJ, Deshmukh AJ, Noseworthy PA, Brady PA. The wide complex tachycardia formula: derivation and validation data. *Data Brief.* 2019;24:103924.
- Jastrzebski M, Kukla P, Czarnecka D, Kawecka-Jaszcz K. Comparison of five electrocardiographic methods for differentiation of wide QRS-complex tachycardias. *Europace.* 2012;14:1165–1171.
- Isenhour JL, Craig S, Gibbs M, Littmann L, Rose G, Risch R. Wide-complex tachycardia: continued evaluation of diagnostic criteria. *Acad Emerg Med.* 2000;7:769–773.
- Baxi RP, Hart KW, Vereckei A, Miller J, Chung S, Chang W, Gottesman B, Hunt M, Culyer G, Trimarco T, et al. Vereckei criteria used as a diagnostic tool by emergency medicine residents to distinguish between ventricular tachycardia and supra-ventricular tachycardia with aberrancy. *J Cardiol.* 2012;59:307–312.
- Szelenyi Z, Duray G, Katona G, Frituz G, Szego E, Kovacs E, Szenasi G, Vereckei A. Comparison of the “real-life” diagnostic value of two recently published electrocardiogram methods for the differential diagnosis of wide QRS complex tachycardias. *Acad Emerg Med.* 2013;20:1121–1130.
- May AM, Brenes-Salazar JA, DeSimone CV, Vaidya VR, Ternus BV, Hodge DO, Lin G, Mulpuru SK, Deshmukh AJ, Noseworthy PA, et al. Electrocardiogram algorithms used to differentiate wide complex tachycardias demonstrate diagnostic limitations when applied by non-cardiologists. *J Electrocardiol.* 2018;51:1103–1109.
- Jastrzebski M, Kukla P, Czarnecka D, Kawecka-Jaszcz K. Specificity of the wide QRS complex tachycardia algorithms in recipients of cardiac resynchronization therapy. *J Electrocardiol.* 2012;45:319–326.
- Schlapfer J, Wellens HJ. Computer-interpreted electrocardiograms: benefits and limitations. *J Am Coll Cardiol.* 2017;70:1183–1192.
- Attia ZI, Friedman PA, Noseworthy PA, Lopez-Jimenez F, Ladewig DJ, Satam G, Pellikka PA, Munger TM, Asirvatham SJ, Scott CG, et al. Age and sex estimation using artificial intelligence from standard 12-lead ECGs. *Circ Arrhythm Electrophysiol.* 2019;12:e007284.
- Attia ZI, Kapa S, Yao X, Lopez-Jimenez F, Mohan TL, Pellikka PA, Carter RE, Shah ND, Friedman PA, Noseworthy PA. Prospective validation of a deep learning electrocardiogram algorithm for the detection of left ventricular systolic dysfunction. *J Cardiovasc Electrophysiol.* 2019;30:668–674.
- Attia ZI, Kapa S, Lopez-Jimenez F, McKie PM, Ladewig DJ, Satam G, Pellikka PA, Enriquez-Sarano M, Noseworthy PA, Munger TM, et al. Screening for cardiac contractile dysfunction using an artificial intelligence-enabled electrocardiogram. *Nat Med.* 2019;25:70–74.
- Ko WY, Siontis KC, Attia ZI, Carter RE, Kapa S, Ommen SR, Demuth SJ, Ackerman MJ, Gersh BJ, Arruda-Olson AM, et al. Detection of hypertrophic cardiomyopathy using a convolutional neural network-enabled electrocardiogram. *J Am Coll Cardiol.* 2020;75:722–733.