

Safety of a Totally Implantable Central Venous Port System with Percutaneous Subclavian Vein Access

Dong-Yoon Keum, M.D., Jae-Bum Kim, M.D., Min-Cheol Chae, M.D.

Background: The role of totally implantable central venous port (TICVP) system is increasing. Implantation performed by radiologist with ultrasound-guided access of vein and fluoroscope-guided positioning of catheter is widely accepted nowadays. In this article, we summarized our experience of TICVP system by surgeon and present the success and complication rate of this surgical method. **Materials and Methods:** Between March 2009 and December 2010, 245 ports were implanted in 242 patients by surgeon. These procedures were performed with one small skin incision and subcutaneous puncture of subclavian vein. Patient's profiles, indications of port system, early and delayed complications, and implanted period were evaluated. **Results:** There were 82 men and 160 women with mean age of 55.74. Port system was implanted on right chest in 203, and left chest in 42 patients. There was no intraoperative complication. Early complications occurred in 11 patients (4.49%) including malposition of catheter tip in 6, malfunction of catheter in 3, and port site infection in 2. Late complication occurred in 12 patients (4.90%). **Conclusion:** Surgical insertion of TICVP system with percutaneous subclavian venous access is safe procedures with lower complications. Careful insertion of system and skilled management would decrease complication incidence.

Key words: 1. Port
2. Subclavian vein

INTRODUCTION

For repeated administration of chemotherapeutic agents, intravenous hydration, or parenteral nutrition to cancer patients or chronically ill patients, the role of the totally implantable central venous port (TICVP) system is greatly increasing to address concerns about quality of life [1]. Annually, more than 5 million central catheters are implanted in the US, and the proportion of implantable catheter systems has been increasing since Niederhuber et al. [2] first reported this system. Typically, surgeons or radiologists execute these procedures using varying methods. Surgeons cut down or percu-

taneously puncture the cephalic, subclavian, or jugular vein, whereas interventional radiologists access the subclavian or jugular vein with the guidance of venography, ultrasound, or fluoroscopy. Recently, ultrasound-guided access to the vein, especially the internal jugular vein, and fluoroscope-guided positioning of the catheter have become widely accepted to reduce complications such as pneumothorax, pinch-off phenomenon, hematoma, or malposition of the catheter tip [3]. However, because thoracic surgeons are familiar with the percutaneous puncture technique, cut down insertion of the central catheter, and the anatomy of the chest and neck vasculature, they can detect complications and manage them prompt-

Department of Thoracic and Cardiovascular Surgery, Keimyung University Dongsan Medical Center, Keimyung University School of Medicine
Received: February 17, 2012, Revised: October 30, 2012, Accepted: November 20, 2012

Corresponding author: Dong-Yoon Keum, Department of Thoracic and Cardiovascular Surgery, Keimyung University Dongsan Medical Center, Keimyung University School of Medicine, 56 Dalseong-ro, Jung-gu, Daegu 700-712, Korea
(Tel) 82-53-250-7059 (Fax) 82-53-250-7307 (E-mail) kdy@dsmc.or.kr

© The Korean Society for Thoracic and Cardiovascular Surgery. 2013. All right reserved.

© This is an open access article distributed under the terms of the Creative Commons Attribution Non-Commercial License (<http://creativecommons.org/licenses/by-nc/3.0>) which permits unrestricted non-commercial use, distribution, and reproduction in any medium, provided the original work is properly cited.

ly and accurately. They can also create a pocket port easily, given their training in pacemaker pocket creation. In Keimyung University Dongsan Medical Center, the TICVP system has been provided by a thoracic surgeon since March 2009. All of the procedures were performed with one small skin incision and subcutaneous puncture of a subclavian vein. In this article, we summarize our experience of the TICVP system and present the success and complication rate of this surgical method. The purpose of this study is to determine whether implanting a TICVP system with surgical methods is as safe as performing it with radiologic guidance.

MATERIALS AND METHODS

Between March 2009 and December 2010, 245 port systems were implanted into 242 patients by thoracic surgeons. The patients' age, sex, underlying diseases, indications of the implantable port system, immediate and delayed complications, and total period of implantation of the port system were evaluated. All of the study protocols were accepted by the institutional review board of Keimyung University Dongsan Medical Center.

Before performing the procedure, the patient's coagulation status including prothrombin time, activated partial thromboplastin time, and platelet count were checked. No prophylactic intravenous antibiotics were given before the surgery. In the operating room, intravenous sedation was not performed and the patient was monitored with electrocardiography, pulse oximetry, and automatic cuff blood pressure. The neck and whole chest was prepared and draped. A circulating nurse was positioned near the patient's head and constantly checked the patient's condition during the operation. As a port site, the right anterior chest was preferred. However, if the patient had received mastectomy or radiation therapy on the right side, or had a previous port scar, the left anterior chest was chosen. Patients were asked to turn their head to the contra-lateral side. After subcutaneous injection of 1% lidocaine for local anesthesia, a 3 cm transverse incision was made just 2 cm distal to the lower margin of the clavicle at the deltopectoral groove level. Gentle dissection of the subcutaneous tissue was done with electrocautery until the fascia layer was reached. At this layer, a pocket for the port

was created with blunt and sharp dissection. To prevent skin tightness or necrosis, sufficient space for the port was provided with minor bleeding control. After preparing the port site, an additional subcutaneous injection of lidocaine was given in the area of the clavicular periosteum. An introducer needle was inserted at the deltoid tuberosity level while gently withdrawing the plunger of the syringe. Because the needle was inserted through previously dissected subcutaneous tissue, no additional incision was needed. Then the needle was inserted under and along the inferior border of the clavicle, making certain that the needle was virtually horizontal to the chest wall. Once under the clavicle, the needle was advanced toward the suprasternal notch until it entered the vein. When we failed infraclavicular subclavian vein access, we converted to a supraclavicular subclavian vein puncture just lateral to the sternocleidomastoid muscle (Fig. 1). After insertion of a J-tip wire, a Groshong catheter (BardPort; Bard Inc., Salt Lake, UT, USA) was introduced through the peel off sheath. After checking the venous return through the catheter and ensuring adequate heparinization, the catheter was cut to connect with the port (BardPort). The catheter was inserted to a depth of 13 to 16 cm of the catheter length through the subcutaneous puncture site (Fig. 2). After connecting the catheter and port, the port was placed in the pocket. Two anchoring sutures between the port hole and subcutaneous tissue were made to fix the port. After checking the patency of the port and flushing it with heparin, the wound was closed with tight obliteration of the dead space to prevent hematoma. After returning from the operating room, a routine chest X-ray was obtained to check the catheter position and to rule out postoperative complications like pneumothorax.

RESULTS

A series of 245 port systems were implanted into 242 patients, including 82 men and 160 women, with an age range of 14 to 86 years (mean, 55.74). In 240 of the patients, the TICVP system was implanted for chemotherapy and other oncologic management, while in 2 noncancerous patients, the system was implanted for parenteral nutrition or to secure an intravenous route. The pocket sites for the port were created

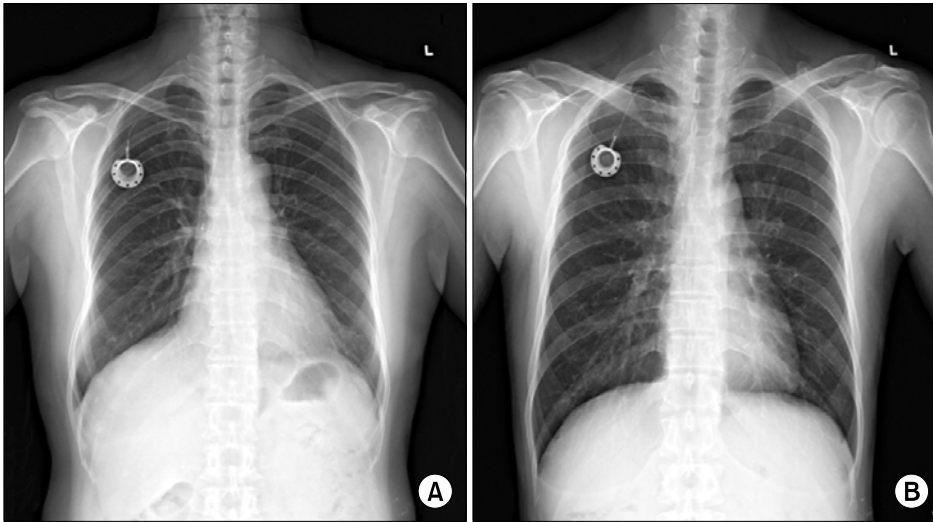


Fig. 1. (A) Chest pulmonary atresia (PA) view after insertion of the totally implantable central venous port system with infraclavicular subclavian venous access. (B) Chest PA view after supraclavicular access to the subclavian vein.

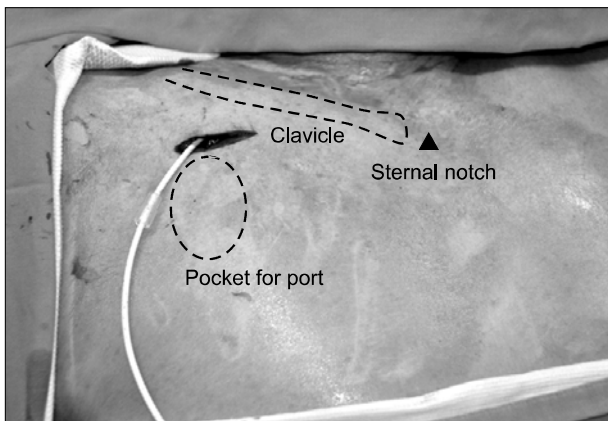


Fig. 2. Operative view of subcutaneous catheter insertion through a pocket incision for the port.

on the right side of the chest wall in 203 cases (85.3%). In 42 cases (14.7%), the left side of the chest wall was used due to previous scarring or wound problems in 10, right side mastectomy in 9, the patient's preference for the left side in 9, failure of right side subclavian venous puncture in 4, pain or edema in the right arm in 4, and other reasons in 6. Two patients (0.82%) underwent supraclavicular access of the subclavian vein after failure of infraclavicular access. Secondary insertion of the port system was performed in 6 patients, including 3 after it was surgically inserted with this method, 2 after radiology-guided insertion, and 1 inserted at another institution. The mean operating time was 22.6 ± 11.5 minutes (range, 10 to 80 minutes). There were no notable intra-

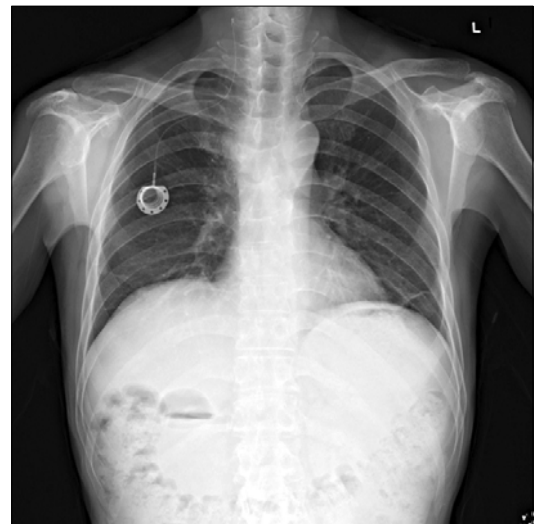


Fig. 3. Chest pulmonary atresia view showing the catheter tip located in the internal jugular vein.

operative complications. Accidental arterial puncture occurred in some cases, but there was no hematoma or hemothorax occurrence. Early complications within 30 days of surgery occurred in 11 patients (4.49%), including malposition of the catheter tip in 6, malfunction of the catheter in 3, and port site infection in 2. Among patients who experienced malposition of the catheter tip, 2 were explanted, but the others refused to remove the catheter (Fig. 3). There was no evidence of venous thrombosis during their catheter indwelling. At the time of chart review, 1 patient had survived with 864 catheter

Table 1. Complications after totally implantable central venous port system insertion with percutaneous subclavian vein access

Variable	Value
Intraoperative complication	None
Early postoperative complication	11 (4.49)
Catheter malposition	6
Port malfunction	3
Wound problem	2
Late complication	12 (4.90)
Venous thrombosis	4
Fever of unknown origin	4
Skin necrosis	3
Sepsis	1
Total	23 (9.39)

Values are presented as number (%) or number.

days without thrombosis. The port system was explanted in patients with port site infection or catheter malfunction. Late complications occurred in 12 patients (4.90%) including venous thrombosis in 4, fever of unknown origin in 4, skin necrosis in 3, and sepsis in 1 patient. These patients eventually required removal of the system (Table 1). We performed explantations in 25 patients (10.2%) including 6 explantations after completion of chemotherapy. During explantation, careful dissection was performed to avoid cutting off the catheter. Compression of the puncture site for a while and complete obliteration of the port site dead space was performed. The median duration of the TICVP system was 287.2 days, ranging from 3 to 980 days.

DISCUSSION

A totally implantable port system has been used increasingly since its introduction by Niederhuber et al. [1]. The types of access vein and port site have varied according to the surgeon's preference. With cut down procedures, the cephalic vein or external jugular vein was preferred, while for percutaneous access, the subclavian or internal jugular vein approach was more frequently used. Nowadays, to reduce perioperative complications and for accurate positioning of a catheter, ultrasound-, venography-, or fluoroscope-guided access are all widely accepted [4,5].

Due to its lower complication rate, interventional radiol-

ogists prefer the sonographic approach using the internal jugular vein than the external landmark-guided technique [6-8]. Some surgeons prefer the cut down procedure to the cephalic vein instead of the percutaneous approach of the subclavian vein to avoid the risk of pneumothorax [9]. However, for a long period of time, the subclavian vein has been a preferred route for placement of the central venous catheter. This route provides a lower chance of infection and good stability on the chest wall [10]. Because the left innominate vein forms an acute angle from the vena cava, and has the possibility of damaging the thoracic duct, the right subclavian vein is preferred over the left. Pneumothorax occurs at a rate of 1% to 2.5% incidence after interventional radiologic placement of the chest port [6-8], while occurring at an incidence of 2.4% to 4.3% after implantation by a surgeon [11,12]. Biffi et al. [13] found that there was no difference in early complications among the internal jugular, subclavian, and cephalic veins in their comparison of central venous insertion sites. They also found that ultrasound-guided subclavian insertion showed the lowest proportion of failure [13]. Meanwhile Teichgraber et al. [3] reported no incidence of pneumothorax after 3,160 cases with an ultrasound-guided internal jugular vein approach. In our study, no pneumothorax occurred. If surgeons are very familiar with chest and neck vasculature, and have good hands with subclavian vein access, the incidence of pneumothorax will decrease. In addition, if the needle should proceed toward the sternal notch slowly and directly without changing the axis, the chance of pneumothorax would be rare.

Radiologists worry about hematoma or arterial puncture without guidance. However, the slow and gentle advance of the needle during venipuncture, accurate checking on the venous blood return to the syringe, and rapid withdrawal of the needle after puncturing the artery can prevent these events. In our experience, even after arterial puncture, rapid removal of the puncture needle and compression of the adjacent soft tissue for 1 or 2 minutes could prevent hematoma formation in every event.

In early insertion periods (March to May, 2009), when puncture through right subclavian access failed, the insertion site was changed to the left side. As a skin incision on the right anterior chest had already been made, an additional incision and pocket making was needed in the left side. After

that period, the protocol was changed. Supraclavicular needle puncture to the subclavian vein just lateral to the sternocleidomastoid muscle was performed. With this route, the surgeon did not need to change the original patient's right side position. When trying to access the internal jugular vein, the surgeon should change position to the patient's head side. A tunneler was used to connect the catheter and port only in this state. Two operations (0.82%) were performed and no occurrence of pneumothorax with this method was observed. Lin et al. [14] reported their experience using external jugular vein cut down, when the cephalic vein approach failed. Below the cutdown site of the cephalic vein, they made a pocket for the port, where a new external jugular vein provided an excellent alternative route.

For secure and long-term maintenance of a TICVP system, the catheter tip position is crucial. The United States Food and Drug Administration has stated that the catheter tip should not be placed in or allowed to migrate into the heart [15]. When the catheter is positioned in the right atrium, it may cause cardiac-related complications such as perforation, tamponade, arrhythmia, or cardiac thrombosis. Furthermore, catheter tips placed in the superior vena cava (SVC) may cause port malfunction. Many authors agree with positioning the tip at the SVC-right atrial junction [16,17]. On standard chest radiograph, because the upper border of the SVC is at the level of the inferior border of the clavicle, or the angle of the right main bronchus and trachea, the catheter tip should be located below this level. The SVC-right atrium junction level on chest radiograph is somewhat different according to different authors. Defalque and Campbell [18] have mentioned that the ideal tip position is between the fifth and sixth thoracic vertebrae, whereas Rutherford et al. [19] mentioned that it is between the right lateral margin of the SVC and superior border of the cardiac silhouette, while another author described it as 1 cm inferior to the right superior cardiac border [20]. With preliminary evaluation of the optimal catheter tip length under fluoroscopic guidance prior to the operation, we attempted to keep the catheter length 13 to 16 cm from the subcutaneous insertion site in the operative field. As our procedures were performed without radiologic guidance, we tried to keep the catheter tip from entering the SVC area by a J-tip wire heading caudally, slowly proceeding the

catheter, and checking cardiac ectopy on the monitor. However, we found a malpositioned catheter tip located in the internal jugular or contralateral innominate vein in 6 patients (2.45%). In this situation, we could have changed the tip position by the endovascular snaring technique or by reinsertion of the catheter in the operating room. But no patient wanted these procedures.

There are many advantages to this procedure. 1) Since all of the procedures are performed in the operating room, the risk of infection will be lower than procedures done in the angiographic suite. 2) Because we form the pocket and perform subcutaneous cannulation of the catheter with one small skin incision, no additional incisions or subcutaneous tunneling is needed. 3) Because the implanted catheter length is short, the risk of catheter-associated complications like lumen occlusion and infection might decrease. 4) Operating time will be shorter than with the radiologic guidance approach. 5) The total cost is lower without guidance. However, since we did not perform a comparative study with a radiology assisted port insertion group, we have a limited ability to test these advantages.

For a surgically implanted system using a subclavian vein, complication rates of 5% to 24.6% have been reported and those radiologically implanted at the same site show a lower complication rate up to 20.7% [8,13]. We have a lower complication rate of 9.39% with no pneumothorax occurrence. However, considering the high incidence of malposition of the catheter tip, complementary cooperation with a radiologist would be needed.

CONCLUSION

Surgical insertion of a TICVP system with percutaneous subclavian venous access is a safe procedure with a lower complication rate and many clinical benefits. Careful insertion of the system and skilled management should decrease the incidence of complications.

CONFLICT OF INTEREST

No potential conflict of interest relevant to this article was reported.

REFERENCES

1. Kock HJ, Pietsch M, Krause U, Wilke H, Eigler FW. *Implantable vascular access systems: experience in 1500 patients with totally implanted central venous port systems.* World J Surg 1998;22:12-6.
2. Niederhuber JE, Ensminger W, Gyves JW, Liepman M, Doan K, Cozzi E. *Totally implanted venous and arterial access system to replace external catheters in cancer treatment.* Surgery 1982;92:706-12.
3. Teichgraber UK, Kausche S, Nagel SN, Gebauer B. *Outcome analysis in 3,160 implantations of radiologically guided placements of totally implantable central venous port systems.* Eur Radiol 2011;21:1224-32.
4. Silberzweig JE, Sacks D, Khorsandi AS, Bakal CW. *Reporting standards for central venous access. Technology Assessment Committee.* J Vasc Interv Radiol 2000;11:391-400.
5. Gebauer B, El-Sheik M, Vogt M, Wagner HJ. *Combined ultrasound and fluoroscopy guided port catheter implantation--high success and low complication rate.* Eur J Radiol 2009;69:517-22.
6. Simpson KR, Hovsepian DM, Picus D. *Interventional radiologic placement of chest wall ports: results and complications in 161 consecutive placements.* J Vasc Interv Radiol 1997;8:189-95.
7. Struk DW, Bennett JD, Kozak RI. *Insertion of subcutaneous central venous infusion ports by interventional radiologists.* Can Assoc Radiol J 1995;46:32-6.
8. Shetty PC, Mody MK, Kastan DJ, et al. *Outcome of 350 implanted chest ports placed by interventional radiologists.* J Vasc Interv Radiol 1997;8:991-5.
9. Jablon LK, Ugolini KR, Nahmias NC. *Cephalic vein cut-down verses percutaneous access: a retrospective study of complications of implantable venous access devices.* Am J Surg 2006;192:63-7.
10. Marcy PY, Figl A, Amoretti N, Ianessi A. *Arm port implantation in cancer patients.* Int J Clin Oncol 2010;15:328-30.
11. Nelson BE, Mayer AR, Tseng PC, Schwartz PE. *Experience with the intravenous totally implanted port in patients with gynecologic malignancies.* Gynecol Oncol 1994;53:98-102.
12. Harvey WH, Pick TE, Reed K, Solenberger RI. *A prospective evaluation of the Port-A-Cath implantable venous access system in chronically ill adults and children.* Surg Gynecol Obstet 1989;169:495-500.
13. Biffi R, Orsi F, Pozzi S, et al. *Best choice of central venous insertion site for the prevention of catheter-related complications in adult patients who need cancer therapy: a randomized trial.* Ann Oncol 2009;20:935-40.
14. Lin YC, Chu CH, Ou KW, et al. *Use of a totally implantable access port through the external jugular vein when the cephalic vein approach is not feasible.* Ann Vasc Surg 2011;25:217-21.
15. Scott WL. *Central venous catheters: an overview of Food and Drug Administration activities.* Surg Oncol Clin N Am 1995;4:377-93.
16. Schutz JC, Patel AA, Clark TW, et al. *Relationship between chest port catheter tip position and port malfunction after interventional radiologic placement.* J Vasc Interv Radiol 2004;15:581-7.
17. Vesely TM. *Central venous catheter tip position: a continuing controversy.* J Vasc Interv Radiol 2003;14:527-34.
18. Defalque RJ, Campbell C. *Cardiac tamponade from central venous catheters.* Anesthesiology 1979;50:249-52.
19. Rutherford JS, Merry AF, Occlshaw CJ. *Depth of central venous catheterization: an audit of practice in a cardiac surgical unit.* Anaesth Intensive Care 1994;22:267-71.
20. Aslamy Z, Dewald CL, Heffner JE. *MRI of central venous anatomy: implications for central venous catheter insertion.* Chest 1998;114:820-6.