

Posterolateral Corner Repair With Internal Bracing and Peroneal Nerve Neurolysis



Toufic R. Jildeh, M.D., Muhammad J. Abbas, B.S., Patrick Buckley, B.S., and Kelechi R. Okoroha, M.D.

Abstract: Posterolateral corner (PLC) reconstruction has been shown to be an effective treatment for PLC injuries. Acute anatomical repair of the PLC has the same potential to stabilize the knee; however, outcomes are less defined. Surgical repair minimizes graft harvest morbidity and allows for the maintenance of native tissue proprioception. Furthermore, augmentation with a flat-braided suture (SutureTape; Arthrex) portends additional repair strength and protection. The purpose of this Technical Note and video is to provide our preferred method of PLC repair in a patient with an acute knee dislocation and injury to the biceps femoris, lateral collateral ligament, iliotibial band, popliteofibular ligament, and the meniscocapsular attachment of the lateral meniscus.

Posterolateral corner (PLC) injuries are often caused by a varus blow to the flexed, anteromedial knee, producing a hyperextension and varus stress.¹ The prevalence of PLC injuries has been historically difficult to quantify due to difficulty in diagnosis.^{2,3} Improved understanding of the PLC's anatomy and function in addition to advancements in magnetic resonance imaging protocols have improved the accuracy of diagnosis.^{4,5} A prospective magnetic resonance imaging study by LaPrade et al.⁶ reported a 16% incidence of PLC injuries in patients with ligamentous knee injuries. Injury to the PLC seldom occurs in isolation (5.7%) and more commonly occurs in combination with injury to another ligament, such as the anterior cruciate ligament or posterior cruciate ligament.⁷⁻⁹

Despite the described techniques for reconstruction of the PLC, there is little consensus on the optimal treatment for an acute, severe PLC injury.¹⁰⁻¹³ Historically, PLC injuries were addressed with surgical repair; however, as authors began to report data on decreased failure rates with reconstruction of the PLC, the pendulum began to swing to reconstructive options.¹⁴⁻¹⁶ Levy et al.¹⁷ conducted a cohort study comparing PLC repair versus reconstruction in 28 patients with 2-year follow-up. The study found that although there was no significant difference in mean International Knee Documentation Committee subjective scores and mean Lysholm scores, there was a significant difference in failure rates (40% in repair group vs 6% in reconstruction group, $P = .04$). Early techniques for PLC repair were not performed with suture augmentation (internal bracing). In addition, a surgical repair minimizes the surgical morbidity associated with graft harvest and allows for the maintenance of the proprioceptive properties of the native tissues.^{18,19} Although no case series has been performed examining PLC repairs with augmentation, a few technical notes have documented surgeons' success with this technique.²⁰⁻²² Furthermore, biomechanical studies have documented that the use of nonabsorbable sutures, as an internal brace can strengthen repairs by up to 20% during critical healing periods postoperatively.²³

The purpose of this Technical Note and video is to provide our preferred method of PLC repair with suture augmentation in a case of an injury to the long and short head of the biceps femoris, lateral collateral

From the Department of Orthopedic Surgery, Mayo Clinic, Minneapolis, Minnesota (K.R.O.); and Department of Orthopaedic Surgery, Henry Ford Hospital, Detroit, Michigan (T.R.J., M.J.A., P.B.), U.S.A.

The authors report the following potential conflicts of interest or sources of funding: K.R.O. reports other from Stryker, Arthrex, Smith & Nephew, and Zimmer, outside the submitted work. Full ICMJE author disclosure forms are available for this article online, as [supplementary material](#).

Received January 25, 2021; accepted March 2, 2021.

Address correspondence to Kelechi R. Okoroha, M.D., Department of Orthopedic Surgery, Mayo Clinic, 600 Hennepin Ave., Suite 310, Minneapolis, MN 55403. E-mail: Krokoroha@gmail.com

© 2021 THE AUTHORS. Published by Elsevier Inc. on behalf of the Arthroscopy Association of North America. This is an open access article under the CC BY-NC-ND license (<http://creativecommons.org/licenses/by-nc-nd/4.0/>).

2212-6287/21119

<https://doi.org/10.1016/j.eats.2021.03.006>

ligament, iliotibial band, popliteofibular ligament, and the meniscocapsular attachment of the lateral meniscus (Table 1).

Surgical Technique (With Video Illustration)

Patient Setup

The patient is laid supine on the standard operative table in a standard arthroscopic setup. A physical examination is performed after induction with general endotracheal anesthesia (Video 1). A nonsterile tourniquet is applied.

Surgical Approach

A 10-blade scalpel is used to make a curvilinear incision centered over the lateral epicondyle, anterior to the fibular head (Fig 1). Subcutaneous tissues are then dissected, and skin flaps are elevated bilaterally. Hematoma is evacuated from the wound, and the peroneal nerve is identified (Fig 2A). The peroneal nerve may demonstrate evidence of a stretch injury with edema distally. A neurolysis is then performed using Metzenbaum scissors to release the peroneal nerve proximally and distally (Fig 2B). The nerve is tagged with a vessel loop.

The damaged structures are then sequentially identified and tagged. Torn structures may include the long and short head of the biceps femoris, lateral collateral ligament, iliotibial band, popliteofibular ligament, and the lateral meniscocapsular ligaments. Repair proceeds in a deep-to-superficial manner starting with the meniscocapsular injury. Three 1.8-mm Q-FIX Anchors (Smith & Nephew, London, UK) are placed 5 mm distal to the tibial joint line (Fig 3A). Anchor sutures are then passed through the meniscus and tied down sequentially to secure the repair (Fig 3B). The lateral collateral ligament (LCL) rupture is addressed next; a tag stitch is used to apply traction on to the LCL to identify the proximal insertion site of the ligament (Fig 4A). The distal insertion of the LCL is also identified on the fibular head. A 1.8-mm Q-FIX Anchor (Smith & Nephew) is drilled and placed at the LCL insertion on the fibula head (Fig 4C). Anchor sutures are passed through the LCL. A valgus force is applied to the knee and a tension slide technique is used to secure the

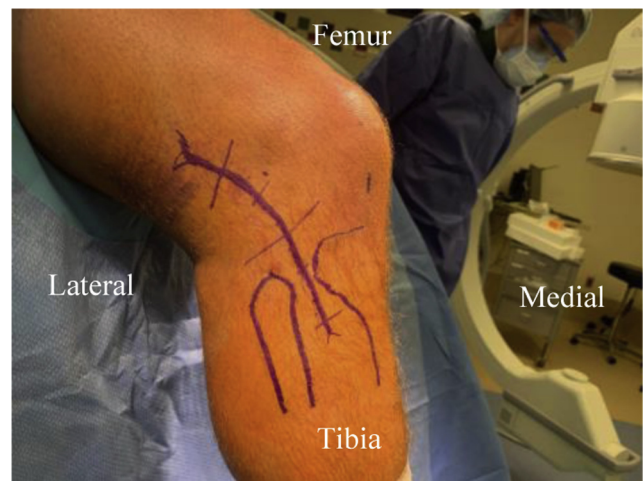

Fig 1. The patient is laid supine on the operating table in a standard arthroscopic setup. Anatomical landmarks are identified, and a 10-blade scalpel is used to create a curvilinear incision. Subcutaneous tissue is then dissected and skin flaps are elevated bilaterally.

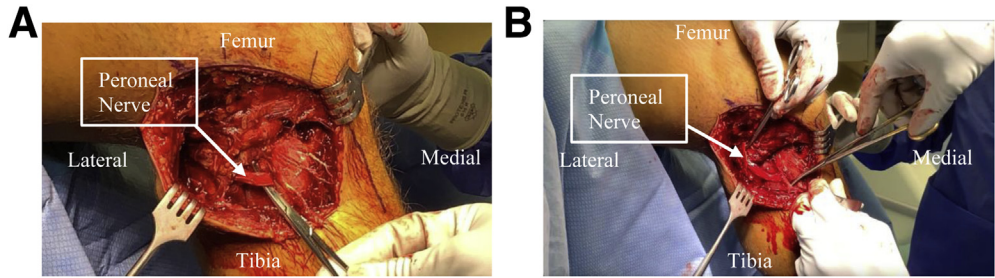
ligament down to bone (Fig 4D). The LCL repair is reinforced with nonabsorbable SutureTape (Arthrex, Naples, FL), which serves as an internal brace. SutureTape preloaded into an anchor (Arthrex) is then drilled and placed just proximal to the LCL insertion point on the lateral epicondyle. The free ends of the SutureTape are then passed into a knotless SwiveLock (Arthrex) anchor placed distal to the LCL insertion on the fibular head (Fig 4E). The SutureTape is found to lay nicely on the surface of the LCL, establishing the internal brace and strengthening the repair. Next, the biceps femoris tendon and popliteofibular ligament are identified and tagged. SutureTape (Arthrex) is whipstitched through the biceps femoris (Fig 5A) and additional fixation is achieved by incorporating these sutures through a SwiveLock (Arthrex) placed at the lateral aspect of the fibula (Fig 5B). An amniotic membrane (Katena Products Inc., Parsippany, NJ) is then applied to the peroneal nerve to promote the functional recovery of the nerve. Finally, a tear in the iliotibial band is repaired by placing one 1.8-mm Q-FIX anchor (Arthrex) at Gerdy's tubercle and passing the sutures through the iliotibial band in a Mason–Allen

Table 1. Advantages and Disadvantages of PLC Repair With Suture Tape Augmentation Versus Reconstruction

Advantages	Disadvantages
No graft harvest or allograft required	Narrow window after injury to perform surgery
Promotes rehabilitation by allowing for earlier mobilization and healing	Structures severely injured may not be amendable to repair
Augmentation with flat-braided suture allows for increased strength of the repair	Synthetic augmentation
Maintain native structures with proprioception	Paucity of literature on long-term outcomes
	SutureTape augmentation can result in overtensioning

PLC, posterior lateral corner.

Fig 2. (A) With the subcutaneous tissue dissected and skin flaps elevated bilaterally, the peroneal nerve is identified. (B) Metzenbaum scissors are used to release the peroneal nerve circumferentially, and a neurolysis is completed.



fashion (Fig 6). Fluoroscopy is used to confirm the repair and evaluate the joint under varus stress testing, which will demonstrate acceptable anatomic tibiofemoral gapping as compared with the preoperative examination.

Postoperative Care

The patient is non-weight-bearing on crutches and brace for 6 weeks postoperatively. Patients should wear a hinged-knee brace locked at full extension during walking and sleeping. The brace may be unlocked from 0 to 90° while sitting and performing physical therapy.

Discussion

This Technical Note is a detailed surgical technique of PLC repair using nonabsorbable suture augmentation. This technique allows for anatomic restoration of the anatomy without the need to harvest a graft while promoting early rehabilitation and improved healing/proprioception.

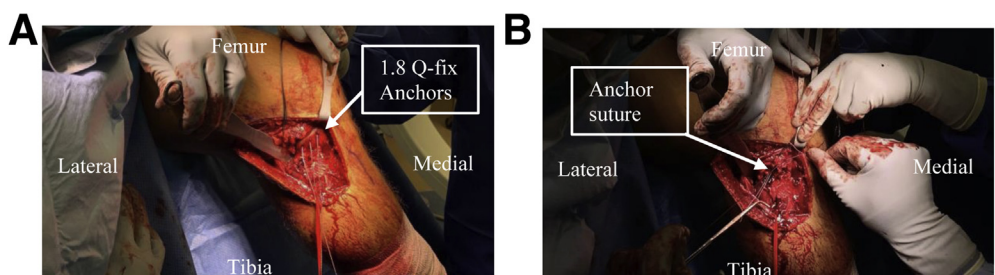
PLC repairs have reported greater failure rates compared with reconstruction (40% vs 6%, $P = .04$).¹⁷ As such, reconstruction has been the favored procedure for PLC injuries.²⁴ Yet, with the continued advancement of surgical technique and instrumentation, orthopaedic surgeons have demonstrated renewed interest in repair of ligamentous knee injuries.^{20-22,25} Specifically, suture augmentation of ligamentous repairs offers promising opportunities to improve outcomes and reduce failure rates. A cadaveric study performed by Mehl et al.²⁶ investigated rotational parameters of a native knee with intact ligaments as compared with knees with a

severed medial collateral ligament repaired with suture tape augmentation. The study demonstrated no significant increase in internal rotation or varus angle at any flexion angle. Suture augmentation allows for protection and stabilization of repaired structures while healing occurs in the early postoperative time frame while facilitating earlier motion.²³

A prospective study performed by Geeslin and LaPrade²⁷ evaluated the efficacy of a hybrid anatomic repair and reconstruction ($n = 16$) to complete reconstruction ($n = 10$) of PLC tears. Patients who underwent a hybrid repair reported better subjective outcomes than complete reconstruction at 2-year follow-up according to both the International Knee Documentation Committee score (89.4 vs 68.6; $P < .002$) and Cincinnati Knee Rating System (89.1 vs 69.1; $P < .004$). The authors expressed support of repair when possible, citing improved subjective stability but cautioned to be selective, in which instances repair should be attempted emphasizing the importance of acuity as an indication for surgical repair (mean time from injury to surgery was 17 days; range 3-42 days). Few studies have assessed the effect of surgical timing on outcomes in PLC injury; however, current understanding is that when injuries can be treated in a timely manner and when tissue quality is appropriate, repair can be performed with good results.²⁸⁻³⁰

When examining PLC injuries, it is important to recognize the presence of a peroneal nerve injury. The peroneal nerve frequently presents as a palsy due to the nerve's proximity to the fibular head and commonly injured biceps femoris. A retrospective chart review of

Fig 3. (A) To repair the meniscoscapsular separation, three 1.8-mm Q-FIX anchors are placed equidistant 5 mm distal to the tibial joint line. (B) Anchor sutures are then passed through the meniscus and tied down sequentially to secure the repair down to bone.



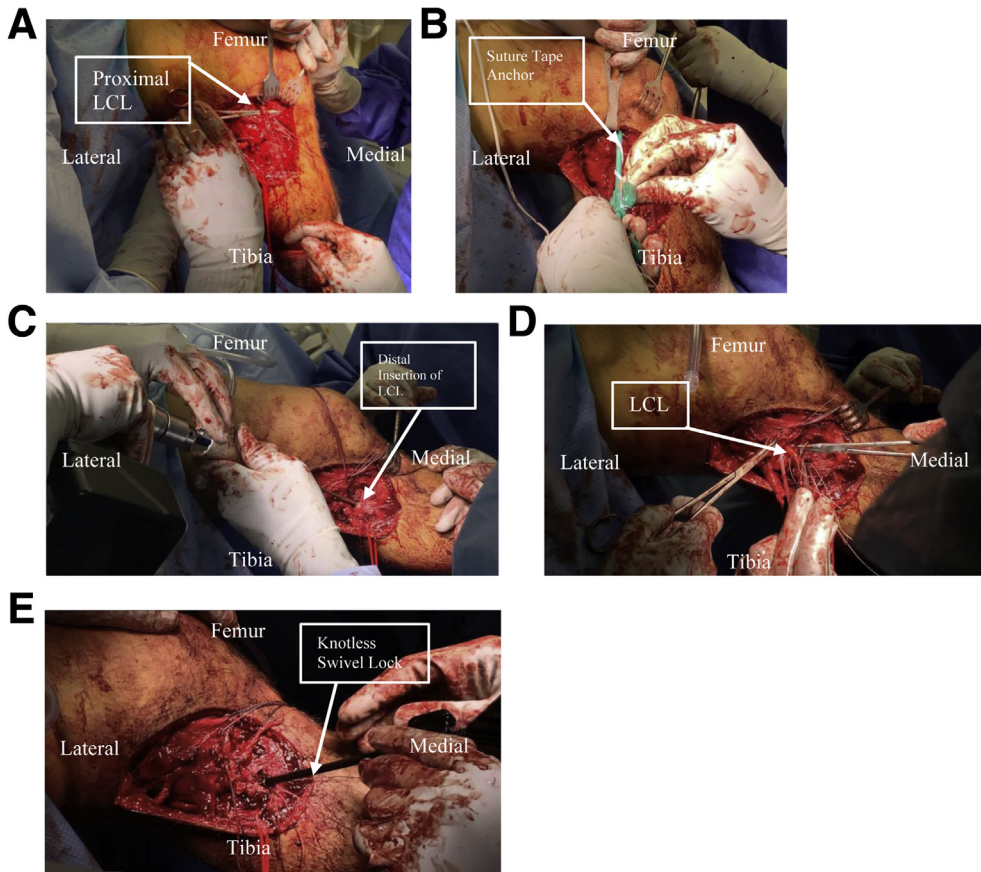


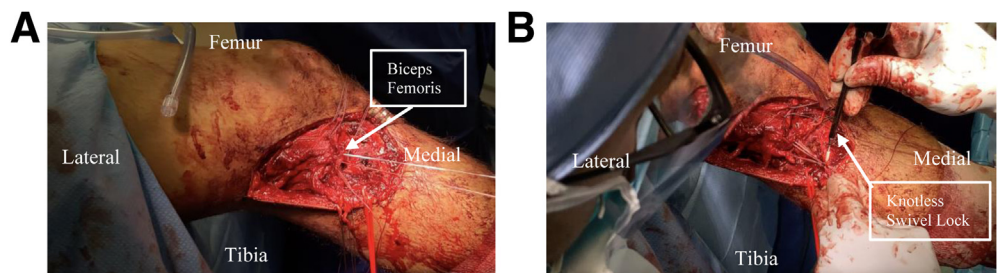
Fig 4. (A) A tag stitch is used to apply traction on to the LCL to identify the proximal insertion site of the ligament. (B) Proximal insertion of the LCL is identified and suture tape preloaded into an anchor is placed. (C) Distal insertion of the LCL is identified on the fibular head and a 1.8-mm Q-FIX anchor is set. (D) With knee held in valgus a tension slide technique is used to secure the ligament. (E) LCL repair is reinforced with the nonabsorbable SutureTape serving as an internal brace. To accomplish this, the previous loaded suture tape is passed into a knotless SwiveLock anchor, which is docked distal to the LCL insertion on the fibular head. (LCL, lateral collateral ligament.)

61 patients performed by Ridley et al.³¹ examined incidence and outcomes of peroneal nerve injuries in the setting of PLC injuries. The authors reported a total of 16 (26.2%) peroneal nerve injuries, of which 13 were described as complete palsy (10 stretch and 3 complete transection) and 3 were characterized as partial injuries. All 16 patients were initially treated with neurolysis. One half of the stretch injuries spontaneously resolved (defined as return of tibialis anterior and extensor hallucis longus motor strength 4/5 or better) at final follow-up (mean 32 months). Two complete transections underwent posterior tibialis transfer and one opted for ankle-foot orthoses. All 3 partial peroneal nerve injuries completely recovered at

final follow-up (mean 21 months) after neurolysis. The authors emphasized the importance of scrutiny of the peroneal nerve due to the significant impact of peroneal nerve injury on patient outcomes. The use of amniotic membrane to wrap around peripherally injured nerves has shown promising returns and improved outcomes.³²⁻³⁴

A retrospective review by Gaspar et al.³⁵ examined 8 patients with recurrent primary cubital tunnel syndrome, due to scar formation and perineural adhesions, who were treated with revision neurolysis and amniotic membrane wrapping. At an average of 30 months out from intervention (range 16-41 months), patients demonstrated improvement from their own

Fig 5. (A) Suture tape is whip stitched through the biceps femoris. (B) Additional fixation is achieved by incorporating biceps femoris suture and popliteofibular ligament suture through an additional SwiveLock placed at the lateral aspect of the fibula.



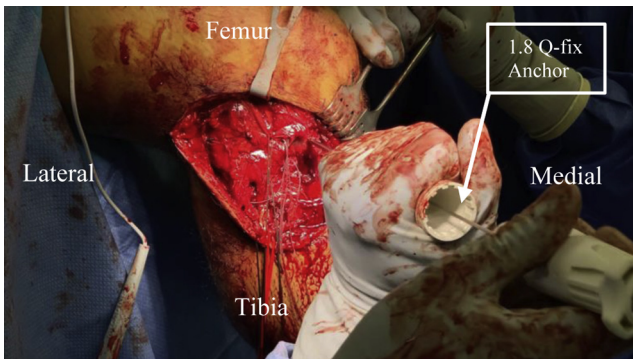


Fig 6. Iliotibial band tear is repaired by placing a 1.8-mm Q-FIX anchor at the lateral Gerdy's tubercle and passing the sutures through iliotibial band in a Mason–Allen fashion.

preoperative measurements of pain (3.8 ± 1.8 visual analog scale vs 7.3 ± 2.1 visual analog scale; $P < .0001$), grip strength (53 ± 20 pounds vs 28 ± 21 pounds; $P < .0001$), and Disabilities of the Arm, Shoulder and Hand Questionnaire (QuickDASH) score (50 ± 16 vs 80 ± 14 ; $P < .0001$). This study emphasizes the therapeutic benefit of amniotic membrane wrapping following neurolysis. Allograft amniotic perineural wrapping is an effective technique to prevent scar formation, which can lead to nerve entrapment, following neurolysis, without the risks associated with harvesting an autograft.

This surgical technique is not without limitations. Most notably, it is important to recognize that repair is not appropriate for every patient with a PLC injury. Timing is important when considering repair versus reconstruction, with reconstruction indicated in non-acute injuries. In addition, awareness that preoperative imaging and planning may not reflect surgical findings which could result in an intraoperative conversion from repair to reconstruction. Lastly, several studies referenced in recent literature indicate reconstruction is superior to repair in terms of failure rates, although these studies were performed without adjunct augmentation to support structures during healing.^{16,17}

Conclusions

In conclusion, this article presents a technique for PLC repair using a flat-braided suture augmentation. This technique allows for additional strength of the repair in the early postoperative phase, maintenance of native structures, which enhances proprioceptive outcomes, and eliminates the morbidity associated with graft harvesting.

References

- Amis AA, Bull AM, Gupte CM, Hijazi I, Race A, Robinson JR. Biomechanics of the PCL and related structures: Posterolateral, posteromedial and meniscofemoral ligaments. *Knee Surg Sports Traumatol Arthrosc* 2003;11:271-281.

- LaPrade RF, Terry GC. Injuries to the posterolateral aspect of the knee. Association of anatomic injury patterns with clinical instability. *Am J Sports Med* 1997;25:433-438.
- Nannaparaju M, Mortada S, Wiik A, Khan W, Alam M. Posterolateral corner injuries: Epidemiology, anatomy, biomechanics and diagnosis. *Injury* 2018;49:1024-1031.
- LaPrade RF, Gilbert TJ, Bollom TS, Wentorf F, Chaljub G. The magnetic resonance imaging appearance of individual structures of the posterolateral knee. A prospective study of normal knees and knees with surgically verified grade III injuries. *Am J Sports Med* 2000;28:191-199.
- Terry GC, LaPrade RF. The posterolateral aspect of the knee. Anatomy and surgical approach. *Am J Sports Med* 1996;24:732-739.
- LaPrade RF, Wentorf FA, Fritts H, Gundry C, Hightower CD. A prospective magnetic resonance imaging study of the incidence of posterolateral and multiple ligament injuries in acute knee injuries presenting with a hemarthrosis. *Arthroscopy* 2007;23:1341-1347.
- Shon OJ, Park JW, Kim BJ. Current concepts of posterolateral corner injuries of the knee. *Knee Surg Relat Res* 2017;29:256-268.
- Chahla J, Moatshe G, Dean CS, LaPrade RF. Posterolateral corner of the knee: Current concepts. *Arch Bone Joint Surg* 2016;4:97-103.
- Wentorf FA, LaPrade RF, Lewis JL, Resig S. The influence of the integrity of posterolateral structures on tibiofemoral orientation when an anterior cruciate ligament graft is tensioned. *Am J Sports Med* 2002;30:796-799.
- Djian P. Posterolateral knee reconstruction. *Orthop Traumatol Surg Res* 2015;101:S159-S170.
- Oshima T, Nakase J, Numata H, Takata Y, Tsuchiya H. Common peroneal nerve palsy with multiple-ligament knee injury and distal avulsion of the biceps femoris tendon. *Case Rep Orthop* 2015;2015:306260.
- Paget LDA, Kuijjer P, Maas M, Kerkhoffs G. Fast-tracked rehabilitation and return to sport of an elite rugby player with a complicated posterolateral corner injury and associated peroneal paralysis. *BMJ Case Rep* 2017;2017, bcr2017219666.
- Tomas-Hernandez J, Monyart JM, Serra JT, et al. Large fracture of the anteromedial tibial plateau with isolated posterolateral knee corner injury: Case series of an often missed unusual injury pattern. *Injury* 2016;47:S35-S40 (suppl 3).
- Baker CL Jr, Norwood LA, Hughston JC. Acute posterolateral rotatory instability of the knee. *J Bone Joint Surg Am* 1983;65:614-618.
- DeLee JC, Riley MB, Rockwood CA Jr. Acute posterolateral rotatory instability of the knee. *Am J Sports Med* 1983;11:199-207.
- Stannard JP, Brown SL, Farris RC, McGwin G Jr, Volgas DA. The posterolateral corner of the knee: repair versus reconstruction. *Am J Sports Med* 2005;33:881-888.
- Levy BA, Dajani KA, Morgan JA, Shah JP, Dahm DL, Stuart MJ. Repair versus reconstruction of the fibular collateral ligament and posterolateral corner in the multiligament-injured knee. *Am J Sports Med* 2010;38:804-809.
- Franciozi CE, Albertoni LJB, Gracitelli GC, et al. Anatomic posterolateral corner reconstruction with autografts. *Arthrosc Tech* 2018;7:e89-e95.

19. Serra Cruz R, Mitchell JJ, Dean CS, Chahla J, Moatshe G, LaPrade RF. Anatomic posterolateral corner reconstruction. *Arthrosc Tech* 2016;5:e563-e572.
20. Vermeijden HD, van der List JP, DiFelice GS. Primary repair of the lateral collateral ligament using additional suture augmentation. *Arthrosc Tech* 2020;9:e1073-e1077.
21. Dabis J, Wilson A. Repair and augmentation with internal brace in the multiligament injured knee. *Clin Sports Med* 2019;38:275-283.
22. Mackay GM, Blyth MJ, Anthony I, Hopper GP, Ribbans WJ. A review of ligament augmentation with the InternalBrace: The surgical principle is described for the lateral ankle ligament and ACL repair in particular, and a comprehensive review of other surgical applications and techniques is presented. *Surg Technol Int* 2015;26:239-255.
23. Vavken P, Proffen B, Peterson C, Fleming BC, Machan JT, Murray MM. Effects of suture choice on biomechanics and physal status after bioenhanced anterior cruciate ligament repair in skeletally immature patients: A large-animal study. *Arthroscopy* 2013;29:122-132.
24. Geeslin AG, Moulton SG, LaPrade RF. A systematic review of the outcomes of posterolateral corner knee injuries, part 1: Surgical treatment of acute injuries. *Am J Sports Med* 2016;44:1336-1342.
25. van der List JP, DiFelice GS. Primary repair of the medial collateral ligament with internal bracing. *Arthrosc Tech* 2017;6:e933-e937.
26. Mehl JT, Kia C, Murphy M, et al. Posteromedial ligament repair of the knee with suture tape augmentation: A biomechanical study. *Am J Sports Med* 2019;47:2952-2959.
27. Geeslin AG, LaPrade RF. Outcomes of treatment of acute grade-III isolated and combined posterolateral knee injuries: A prospective case series and surgical technique. *J Bone Joint Surg Am* 2011;93:1672-1683.
28. Khanduja V, Somayaji HS, Harnett P, Utukuri M, Dowd GS. Combined reconstruction of chronic posterior cruciate ligament and posterolateral corner deficiency. A two- to nine-year follow-up study. *J Bone Joint Surg Br* 2006;88:1169-1172.
29. LaPrade RF, Johansen S, Engebretsen L. Outcomes of an anatomic posterolateral knee reconstruction: Surgical technique. *J Bone Joint Surg Am* 2011;93:10-20 (suppl 1).
30. Levy BA, Boyd JL, Stuart MJ. Surgical treatment of acute and chronic anterior and posterior cruciate ligament and lateral side injuries of the knee. *Sports Med Arthrosc Rev* 2011;19:110-119.
31. Ridley TJ, McCarthy MA, Bollier MJ, Wolf BR, Amendola A. The incidence and clinical outcomes of peroneal nerve injuries associated with posterolateral corner injuries of the knee. *Knee Surg Sports Traumatol Arthrosc* 2018;26:806-811.
32. Fairbairn NG, Ng-Glazier J, Meppelink AM, Randolph MA, Winograd JM, Redmond RW. Improving outcomes in immediate and delayed nerve grafting of peripheral nerve gaps using light-activated sealing of neuroorrhaphy sites with human amnion wraps. *Plast Reconstr Surg* 2016;137:887-895.
33. Bourgeois M, Loisel F, Obert L, Pluvy I, Gindraux F. Can the amniotic membrane be used to treat peripheral nerve defects? A review of literature. *Hand Surg Rehabil* 2019;38:223-232.
34. Riccio M, Marchesini A, Pugliese P, De Francesco F. Nerve repair and regeneration: Biological tubulization limits and future perspectives. *J Cell Physiol* 2019;234:3362-3375.
35. Gaspar MP, Abdelfattah HM, Welch IW, Vosbikian MM, Kane PM, Rekant MS. Recurrent cubital tunnel syndrome treated with revision neurolysis and amniotic membrane nerve wrapping. *J Shoulder Elbow Surg* 2016;25:2057-2065.